



What is the Natural History of Patellar Dislocation in Skeletally Immature Patients?

A Long-Term Population-Based Study

Thomas L. Sanders, MD, Ayoosh Pareek, BS, Isabella T. Wu, BA,
Timothy E. Hewett, PhD, Michael J. Stuart, MD, Diane L. Dahm, MD,
and Aaron J. Krych, MD

Disclosures

- Thomas L. Sanders, M.D.
 - None
- Ayoosh Pareek, B.S.
 - None
- Isabella T. Wu, B.A.
 - None
- Timothy E. Hewett, Ph.D.
 - None
- Diane L. Dahm, M.D.
 - AAOS Arthroscopy and Sports Medicine Program Subcommittee: Board or committee member
 - Arthroscopy Association of North America, Research Committee 2008-Present
 - Arthroscopy Association of North America, Learning Center Committee 2012: Board or committee member
 - Spouse owns stock in TENEX health.: Stock or stock Options
 - Spouse receives royalties from TENEX health.: IP royalties
- Michael J. Stuart, M.D.
 - American Journal of Sports Medicine: Editorial or governing board
 - Arthrex, Inc: IP royalties; Paid consultant
 - Stryker: Research support
- Aaron J. Krych, M.D.
 - American Journal of Sports Medicine: Editorial or governing board
 - Arthrex, Inc: Paid consultant
 - Arthritis Foundation: Research support
 - Ceterix: Research support
 - Histogenics: Research support
 - International Cartilage Repair Society: Board or committee member
 - International Society of Arthroscopy, Knee Surgery, and Orthopaedic Sports Medicine: Board or committee member
 - Minnesota Orthopedic Society: Board or committee member
 - Musculoskeletal Transplantation Foundation: Board or committee member

Purpose

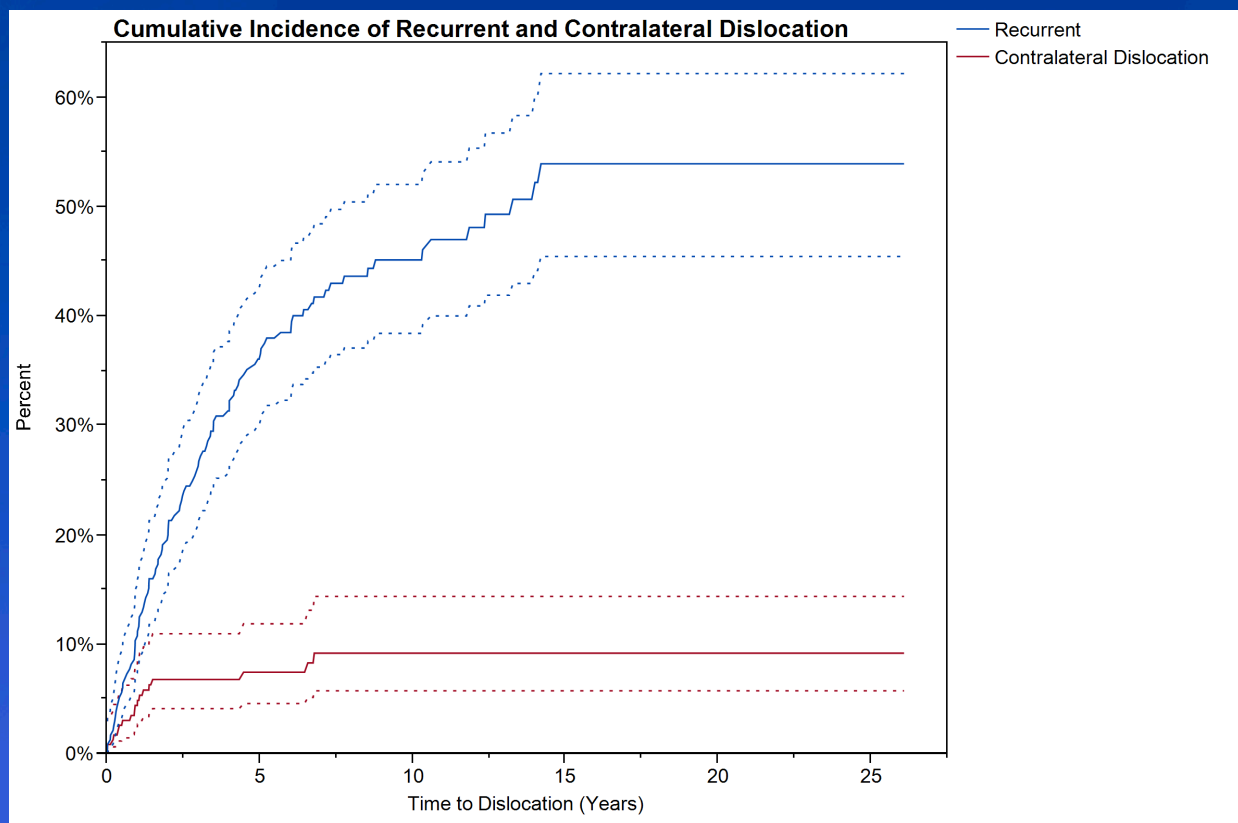
- In skeletally immature patients with acute lateral patellar dislocation:
 - Describe the long-term population-based rate of additional patellar instability events (ipsilateral recurrence and contralateral dislocation)
 - Describe the incidence of patellofemoral arthritis

Methods

- 232 skeletally immature individuals identified through a multi-disciplinary geographic cohort county database who were diagnosed with first episode lateral patellar dislocation between 1990-2010
- Subjects followed for a mean of 12.1 years
- Radiographs at time of injury were examined for evidence of patella alta, trochlear dysplasia, and osteochondral injury
- Medical records reviewed for additional patellar instability events, development of patellofemoral arthritis, and need for surgery

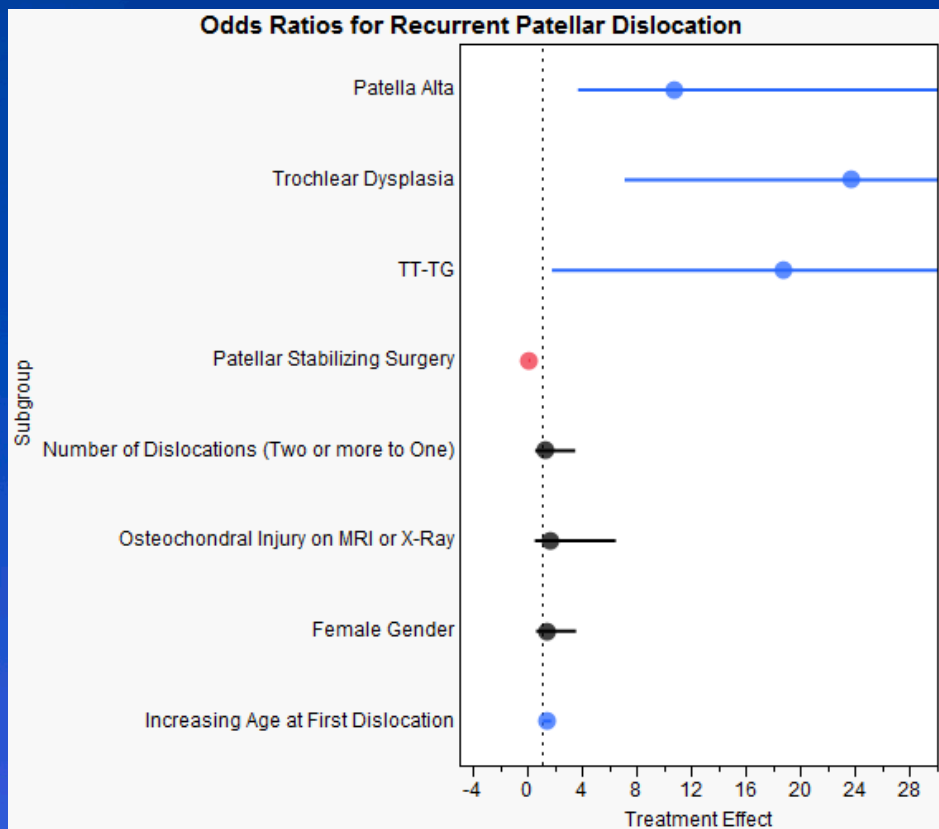
Results

- Figure 1. Cumulative incidence of recurrent patellar dislocation and contralateral patellar dislocation



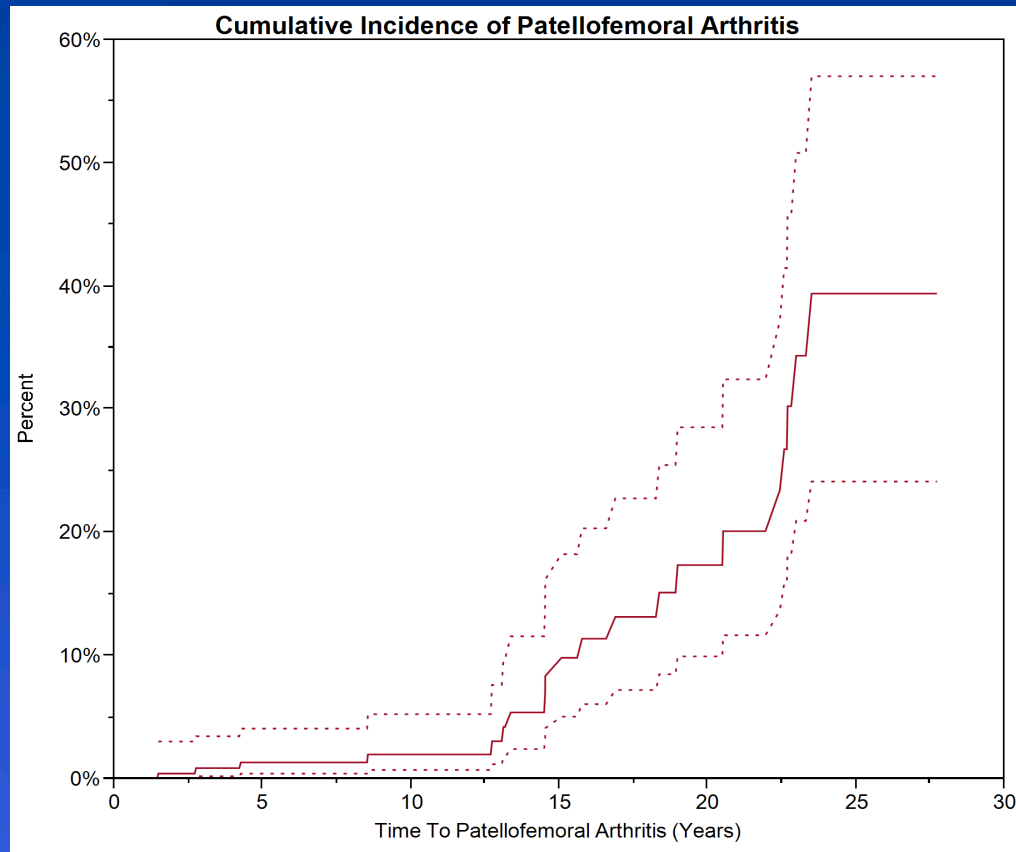
Results

- Figure 2. Factors predictive of recurrent patellar dislocation



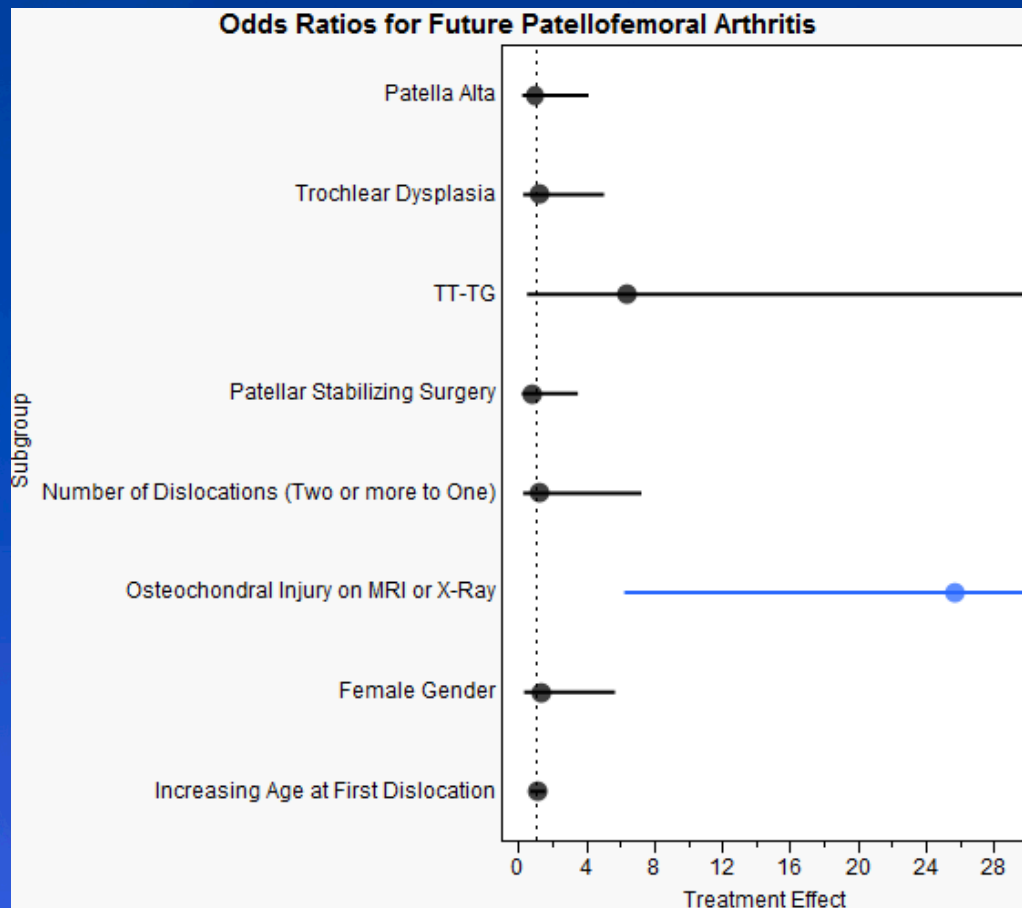
Results

- Figure 3. Cumulative incidence of patellofemoral arthritis



Results

- Figure 4. Factors predictive of patellofemoral arthritis



Conclusions

- Skeletally immature patients have a high rate of recurrent patellar instability that is associated with structural abnormalities such as patella alta and trochlear dysplasia.
- In contrast, the rate of subsequent contralateral dislocation is low.
- Osteochondral injury is associated with arthritis after patellar dislocation, but the overall incidence of end-stage arthritis in pediatric patients is low at 12-year follow-up.

References

- Anrbjornsson A, Egund N, Rydning O, Stockerup R, Ryd L. The natural history of recurrent dislocation of the patella. Long-term results of conservative and operative treatment. *J Bone Joint Surg Br.* 1992;74(1):140-2.
- Crosby E, Insall J. Recurrent dislocation of the patellar. Relation of treatment to osteoarthritis. *J Bone Joint Surg Am.* 1976;58(1):9-13.
- Fithian D, Paxton E, Stone M, Silva P, Davis D, Elias D, White L. Epidemiology and natural history of acute patellar dislocation. *Am J Sports Med.* 2004;32(5):1114-21.
- Jaquith B, Parikh S. Predictors of recurrent patellar instability in children and adolescents after first-time dislocation. *J Pediatr Orthop.* 2015 doi
- Lewallen L, Mcintosh A, Dahm D. Predictors of recurrent instability after acute patellofemoral dislocation in pediatric and adolescent patients. *Am J Sports Med* 2013;41(3):575-81.
- Vivod G, Verdonk P, Drobic M. Long-term clinical and radiographic outcome of patellofemoral realignment procedures: a minimum of 15-year follow-up. *Knee Surg Sports Traumatol Arthrosc.* 2014;22(11):2747-55.
- Vollnberg B, Koehlitz T, Jung T, Scheffler S, Hoburg A, Khandker D, Hamm B, Wiener E, Diederichs G. Prevalence of cartilage lesions and early osteoarthritis in patients with patellar dislocation. *Eur Radiol.* 2012;22(11):2347-56.
- Waterman B, Belmont P, Owens B. Patellar dislocation in the United States: role of sex, age, race, and athletic participation. *J Knee Surg.* 2012;25(1):51-7.