

# The Comparative Analysis of the Clinical Symptoms and MRI Findings after Osteochondral Autograft Transfer(OAT) for the Spontaneous Osteonecrosis of the Knee(SONK)

Dept. of Orthopaedic Surgery  
National Hospital Organization,  
Kyoto Medical Center , Kyoto , JAPAN

*Shogo Mukai    Yasuaki Nakagawa    Takahiko Saji*  
*Hiromitsu Yabumoto    Eri Tarumi    Shigeru Yamada*  
*Takashi Nakamura*



独立行政法人 国立病院機構  
京都医療センター

National Hospital Organization Kyoto Medical Center



**Our presentation have no conflict of interest.**

# Hypothesis

Osteochondral autograft transfer(OAT) for the spontaneous osteonecrosis of the knee (SONK) improve the clinical symptoms as well as the MRI findings

# Subjects

SONK patients consecutively treated by OAT during 2007 and 2012

22 patients    23 knees

(M 5   F 17)

Mean age 68.3 yr    (55 ~ 72)

Followed up for 3.3 years in the average

# Evaluation criteria

## ➤ Clinical symptoms

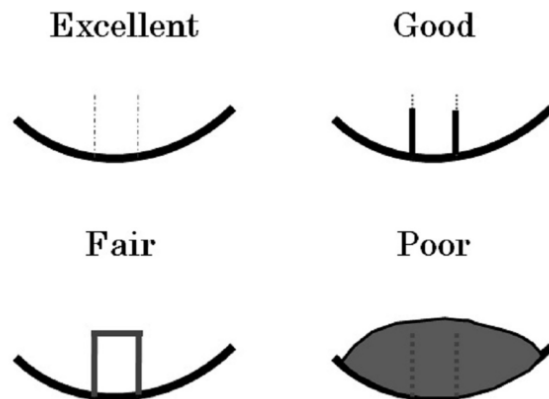
## Lysholm score

## ➤ MRI findings

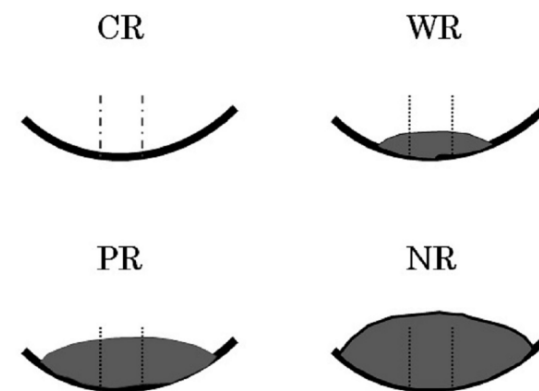
### ① Recurrence of osteonecrosis

Subchondral bone defect or cystic shadow

### ② Achieving Plug integration

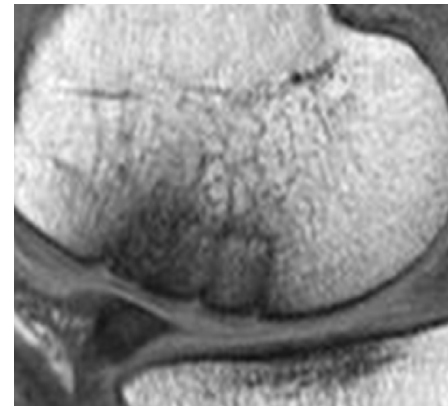
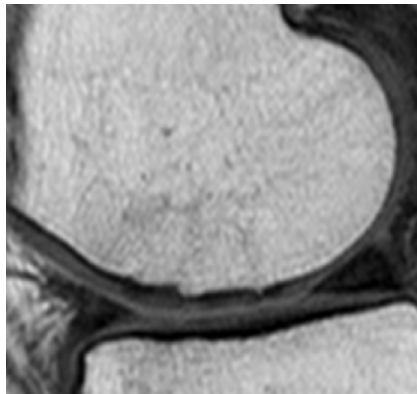


### ③ Resolving Bone marrow edema



# Comparative analysis

- ◆ Preoperative Lysholm score (@preope)
- ◆ Age @ operation
- ◆ OA grade @ operation
- ◆ Sex
- ◆ Lesion size
- ◆ Postoperative Lysholm score(@1year)
- ◆ MRI findings @ 1year
  - Plug integration score
  - Bone marrow edema score



# Results

➤ OA grade            KL I    8    KLII    9    KL III    4

➤ Lesion size        358 mm<sup>2</sup> (150 ~ 630 )

➤ No additional surgeries

➤ No recurrence on plain x-rays

      cystic shadow

      subchondral bone defect

➤ Lysholm score

      @ preop

      48.7

      (42 ~ 61)



      R<sup>2</sup>=0.36

      @ 1year

      88.3

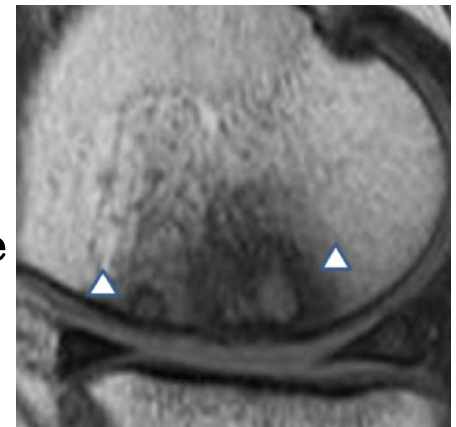
      (71 ~ 100)

# MRI findings

## ① Recurrence of ON

Small Cystic shadow with intact cartilage

**2 / 23 (8.7%)**



## ② Plug integration

Excellent

0

Good

10

Fair

6

Poor

7

**10 / 23 (43%)**

Integration rate

## ③ Bone marrow edema

CR (complete resolution)

3

WR (well resolution)

8

PR (partially resolution)

8

NR (non-resolution)

4

Bone marrow edema  
improvement rate

**19/23 (83%)**

20/23 persist

## Factors affecting Lysholm score @ 1year

Lysholm @1year	<i>rs</i>	<i>P</i>
Pre-Lysholm	0.69	0.0006 ★
Sex	0.129	0.60
Lesion size	-0.54	0.012 ★
Age	-0.18	0.42
Pre-OA grade	-0.23	0.31

(Spearman's rank coefficient )



# Correlation between MRI findings and Lysholm score @1year

Lysholm @1year

	<i>rs</i>	<i>P</i>
Bone marrow edema score	-0.11	0.095
Plug integration score	-0.21	0.349

(Spearman's rank coefficient )

# Discussion

## ➤ MRI findings Comparison with other reports

### ✓ Plug integration rate

for cartilage injury 75% Tetta 2010

50 % Link 2006

for SONK 43% this report

Relatively low rate

### ✓ Bone marrow edema outside of the plugs

for cartilage injury 51% Link 2006

for OCD or cartilage injury 60% Nemec 2009

for SONK 87% this report

Relatively high rate

## ➤ Lysholm score @ 1year

- ✓ Correlation with

  - Lesion size

  - Lysholm score @ preope

- ✓ No correlation with MRI findings

  - Relatively low rate of plug integration

  - Relatively high rate of bone marrow edema

Persistent bone marrow edema continue  
without significant relation with knee pain

Nemec 2009


Overall MOCART score showed  
no correlation with Tegner score

Tetta 2010

# Conclusion

## Treatment results of OAT on SONK

- Clinical symptoms significantly improved.
- Postoperative score correlated with preoperative score and lesion size .
- SONK lesion healed well on MRI.
- The recurrence rate was very low.
- Bone marrow edema improved in most cases.
- Relatively low rate of plug integration
- Relatively high rate of bone marrow edema



**No correlation between  
Clinical symptoms and MRI findings**

**Recommend as the first line procedures  
for small lesion**

## Reference

- |                 |                    |
|-----------------|--------------------|
| Link TM et al.  | Euro Radiol 2006   |
| Nemec SF et al. | Euro J Radiol 2009 |
| Tetta C et al.  | Euro J Radiol 2010 |