

Patient Reported Outcomes of Femoroacetabular Impingement in Adolescents with Open Physes and Duration of Symptoms: A Match-Paired Analysis

Benjamin G. Domb MD, Andrew R. Schab BS, , Tyler R. McCarroll MD, Roger Quesada-Jimenez MD, Ady Haim Kahana-Rojkind MD



Andrew R. Schab, BS.

M1, Rosalind Franklin University Chicago Medical School,
American Hip Institute Research Foundation

Disclosures

I (and/or my co-authors) have something to disclose.

Detailed disclosure information is available via:

AAOS Orthopaedic Disclosure Program on the AAOS website at
<http://www.aaos.org/disclosure>

Background:

Femoroacetabular Impingement in the Skeletally Immature

- FAI is prevalent amongst adolescents
- Some concern for regrowth after femoroplasty in skeletally immature
- Non-physeal arthroscopic approach generally safe
- Difficult to get approval from insurance carriers

Arthroscopic Surgery for Femoroacetabular Impingement in Skeletally Immature Athletes: Radiographic and Clinical Analysis

Arthroscopy
The Journal of Arthroscopic and Related Surgery

Christopher M. Larson, M.D., Rebecca Stone McGaver, M.S., A.T.C., Nicole R. Collette, B.S., M. Russell Giveans, Ph.D., James R. Ross, M.D., Asheesh Bedi, M.D., and Jeffrey J. Nepple, M.D.

Does Bony Regrowth Occur After Arthroscopic Femoroplasty in a Group of Young Adolescents?

Arthroscopy
The Journal of Arthroscopic and Related Surgery

Itay Perets, M.D., Asheesh Gupta, M.D., Edwin O. Chaharbakhshi, B.S., Lyall Ashberg, M.D., David E. Hartigan, M.D., Mary R. Close, B.S., and Benjamin G. Domb, M.D.

ORIGINAL ARTICLE

Complications of Hip Arthroscopy in Children and Adolescents

JOURNAL OF PEDIATRIC ORTHOPAEDICS

Benedict U. Nwachukwu, BA,† Eric D. McFeely, BA,* Adam Y. Nasreddine, MA,* James A. Krcik, MD,* Jeremy Frank, MD,* and Mininder S. Kocher, MD, MPH*†*

ORIGINAL ARTICLE

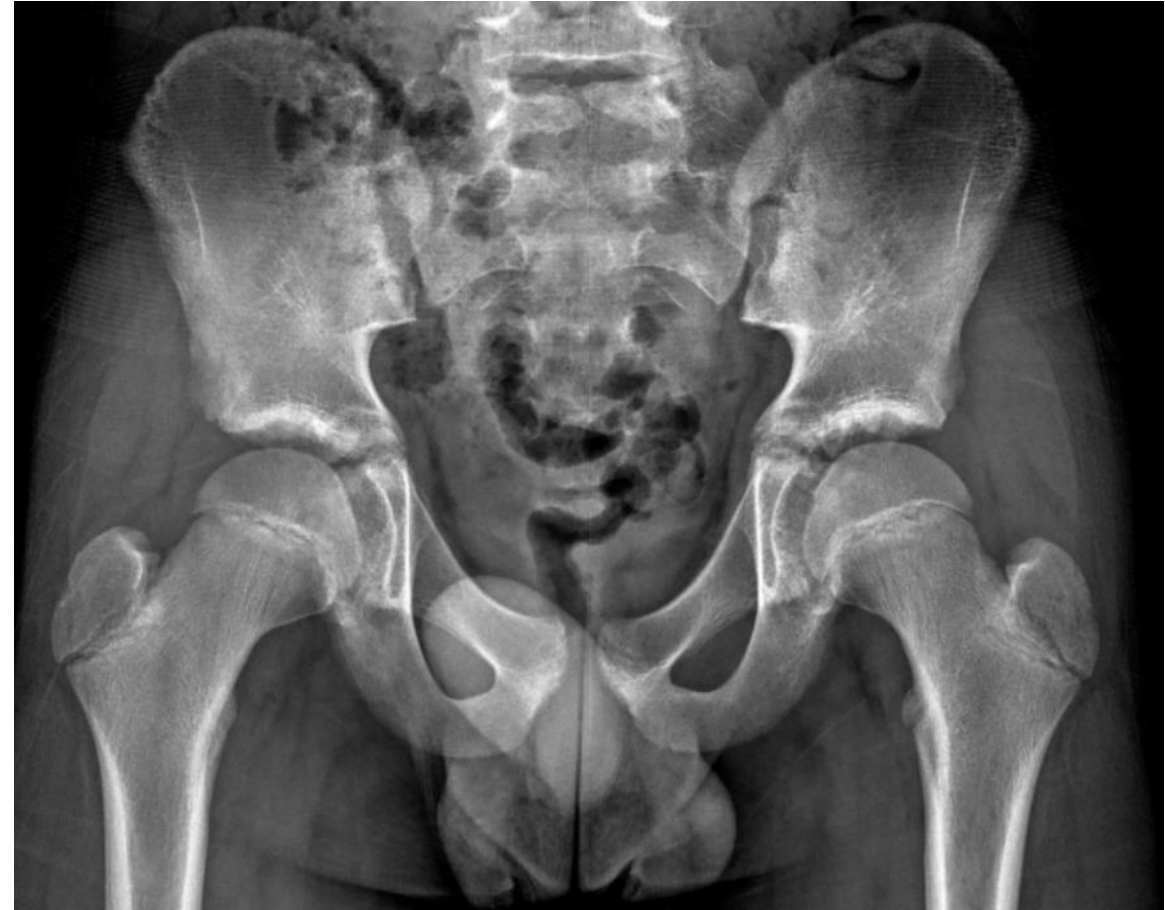Hip Arthroscopy in Children and Adolescents

JOURNAL OF PEDIATRIC ORTHOPAEDICS

Mininder S. Kocher, MD, MPH, Young-Jo Kim, MD, PhD, Michael B. Millis, MD, Rahul Mandiga, BS, Patrick Siparsky, BS, Lyle J. Micheli, MD, and James R. Kasser, MD

Purpose

- **Report** outcomes of hip arthroscopy in adolescents with open physis and compare their outcomes to adolescents with closed physis
- **Null Hypothesis:** Hips with open proximal femoral physis (OP) will demonstrate no difference in outcomes as compared to hips with closed proximal femoral physis (CP) after hip arthroscopy



Preoperative radiograph with open proximal femoral physis.

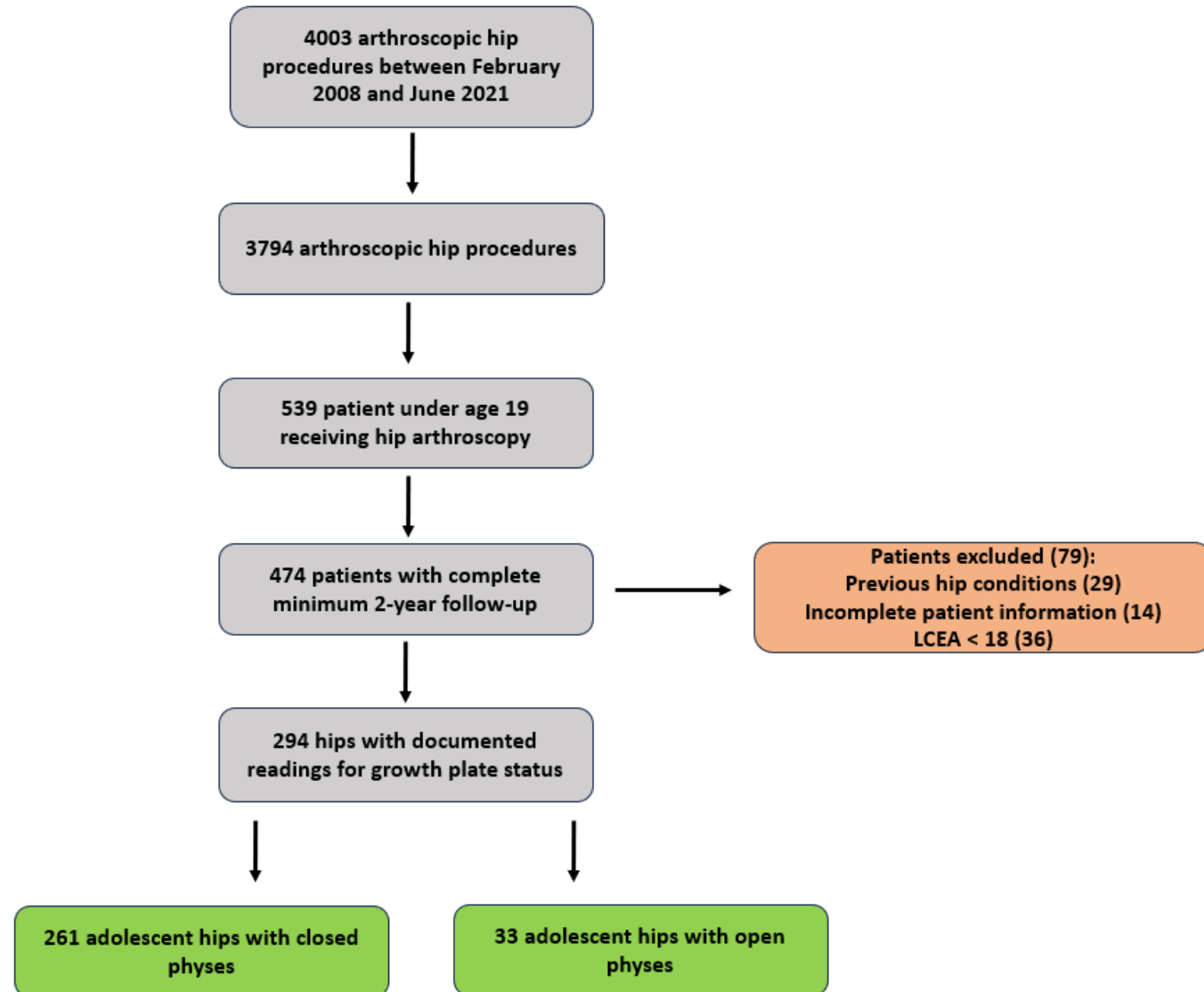
Methods: Patient Selection

- **Exclusion/Inclusion Criteria**

- Primary hip arthroscopy
 - FAI and labral tears
- Age at surgery: ≤ 18
- Minimum 2-year follow-up
- No ipsilateral conditions
- Risser < 4
- Proximal femoral physis > 1 mm

- **Matching Criteria (1:1 Ratio)**

- Age
- Sex
- BMI



Results: Statistical Analysis

- Similar demographics
- Significant improvement in both groups
- Preoperative PROs:
 - OP had higher scores
- Postoperative PROs:
 - OP and CP had similar scores
 - OP had lower satisfaction
- MCID, PASS, SCB
 - Similar achievement
- Similar rate of secondary hip arthroscopy
 - 4 (13.33%) rate
- No conversion to arthroplasty

Table 1. Patient Demographics

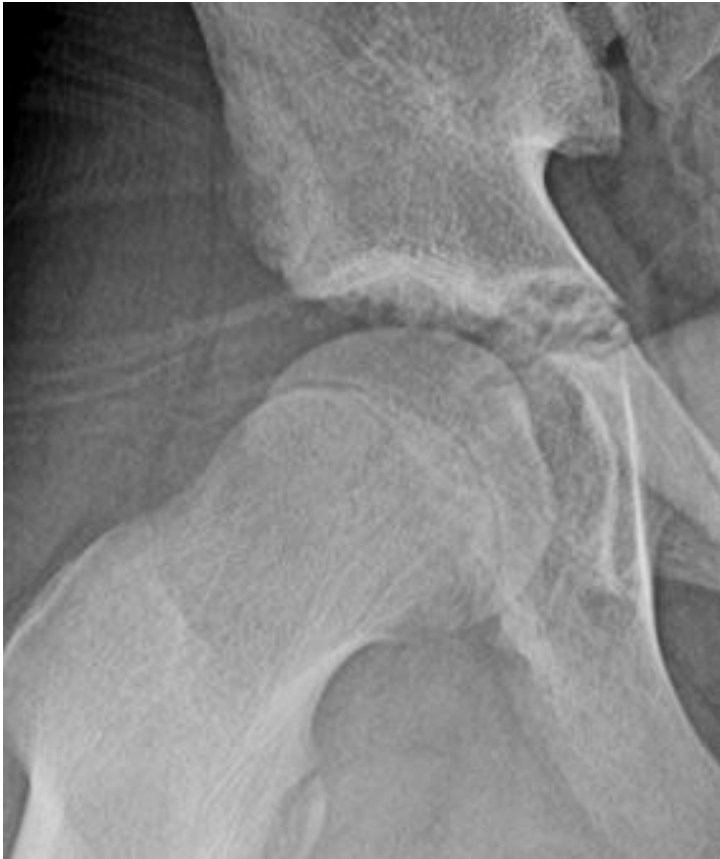	OP	CP	P Value
Total eligible*	33	252	
Total matched*	30	30	
Follow-up time, mo [†]	58.87 ± 33.79	70.51 ± 37.11	0.21
Age at surgery, yr [†]	14.96 ± 1.11	15.01 ± 1.23	0.94
Sex [‡]			0.78
Male	14 (46.67%)	15 (50.0%)	
Female	16 (53.33%)	15 (50.0%)	
Laterality [‡]			0.12
Left	18 (60.0%)	12 (40.0%)	
Right	12 (40.0%)	18 (60.0%)	
Duration of symptoms, mo [†]	10.29 ± 10.72	8.8 ± 7.1	0.59
Mechanism of injury [‡]			0.17
Acute	3 (10.0%)	7 (23.3%)	
Degenerative	27 (90.0%)	23 (76.7%)	
Height, in. [†]	65.5 ± 3.90	66.57 ± 3.56	0.30
Weight, lb. [†]	126.97 ± 26.33	135.92 ± 19.40	0.10
BMI (kg/m. ²) [†]	20.71 ± 3.34	21.62 ± 3.17	0.28

Table 6. Patient-Reported Outcomes

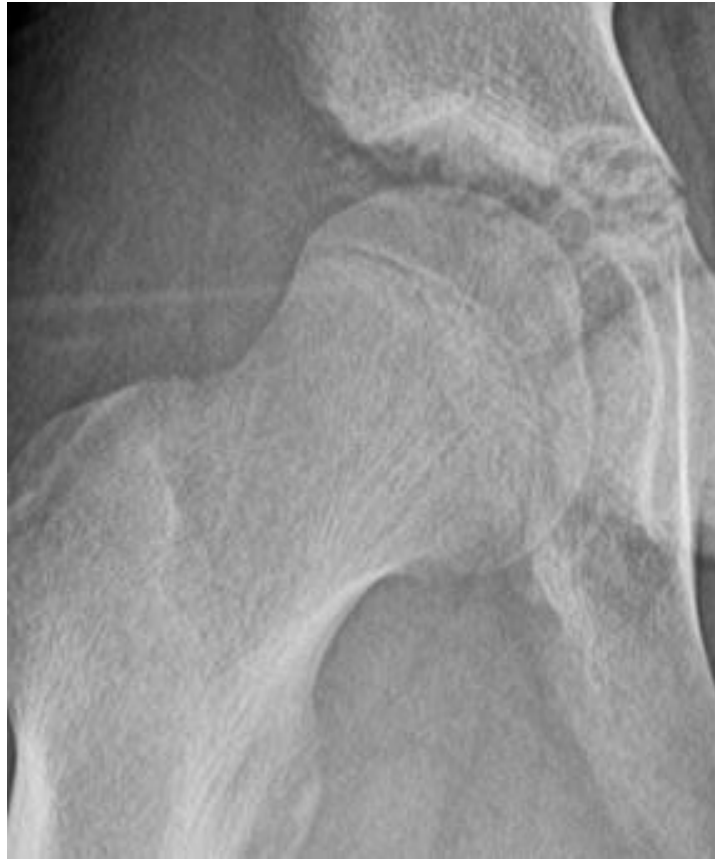	OP	CP	P Value
mHHS			
Preoperative	70.85 ± 12.09	60.99 ± 16.98	<0.01
Postoperative	88.96 ± 13.23	92.95 ± 8.41	0.19
Preoperative vs postoperative P value	< 0.01	< 0.01	
Δ	18.11 ± 18.74	31.96 ± 20.08	<0.05
NAHS			
Preoperative	73.76 ± 15.04	66.61 ± 16.16	0.07
Postoperative	89.92 ± 13.59	92.92 ± 7.82	0.30
Preoperative vs postoperative P value	< 0.01	< 0.01	
Δ	16.16 ± 20.54	26.31 ± 17.13	0.10
HOS-SSS			
Preoperative	55.19 ± 16.54	41.67 ± 20.30	<0.01
Postoperative	81.34 ± 23.84	86.12 ± 16.24	0.36
Preoperative vs postoperative P value	< 0.01	< 0.01	
Δ	26.15 ± 25.91	44.45 ± 23.82	<0.05
VAS			
Preoperative	4.21 ± 2.20	5.44 ± 2.28	<0.05
Postoperative	1.54 ± 1.71	0.85 ± 1.36	0.09
Preoperative vs postoperative P value	< 0.01	< 0.01	
Δ	-2.67 ± 2.78	-4.60 ± 2.72	<0.05
Satisfaction	8.23 ± 2.19	9.23 ± 1.19	<0.05

Results: Radiographic Findings

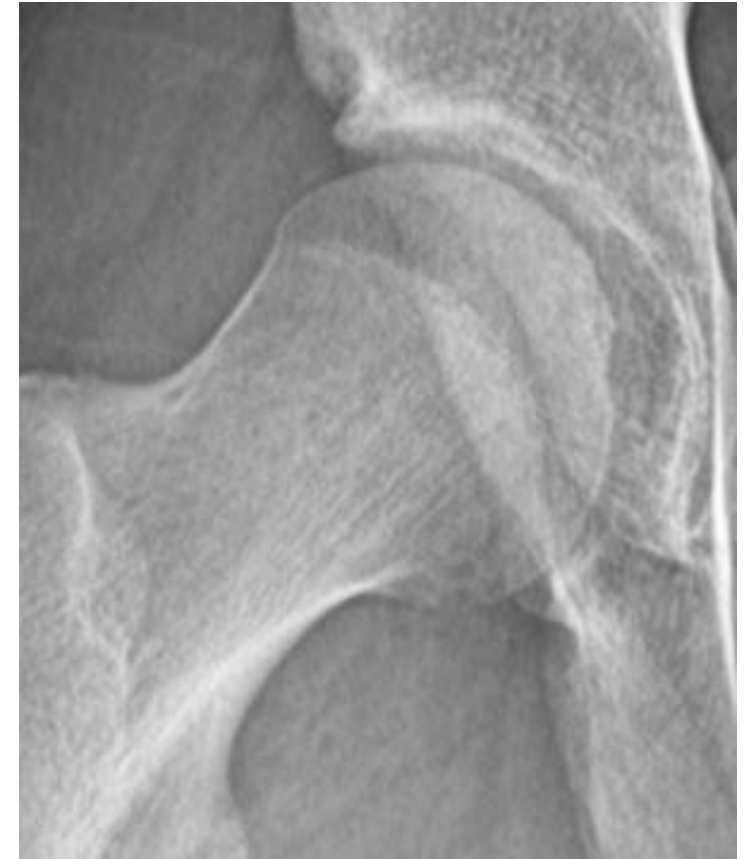- **Similar preoperative and postoperative findings - no signs of bony regrowth**



Preop



2 Week Postop



2 Year Postop

Conclusion

- Patients with open physis had similar satisfactory outcomes after hip arthroscopy to treat FAI and labral tears

References

- Perets I, Gupta A, Chaharbakhshi EO, et al. Does Bony Regrowth Occur After Arthroscopic Femoroplasty in a Group of Young Adolescents? *Arthrosc J Arthrosc Relat Surg Off Publ Arthrosc Assoc N Am Int Arthrosc Assoc*. 2017;33(5):988-995. doi:10.1016/j.arthro.2017.01.023
- Nwachukwu BU, McFeely ED, Nasreddine AY, et al. Complications of hip arthroscopy in children and adolescents. *J Pediatr Orthop*. 2011;31(3):227-231. doi:10.1097/BPO.0b013e31820cad5
- Kocher, Mininder S., et al. "Hip arthroscopy in children and adolescents." *Journal of Pediatric Orthopaedics* 25.5 (2005): 680-686.