UNIVERSITÄRE
SPORTORTHOPÄDIE

Derotational Distal Femoral Osteotomy for Patients with Recurrent Patellar Instability and Increased Femoral Antetorsion Improves Knee Function and Adequately Treats Both Torsional and Valgus Malalignment

Maximilian Hinz, MD, Matthias Cotic, Theresa Diermeier, MD, Florian B. Imhoff, MD, Georg Feuerriegel, MD, Klaus Wörtler, MD, Alexander Themessl, MD, Andreas B. Imhoff, MD, Andrea Achtnich, MD

Department of Sports Orthopaedics
Technical University of Munich
Munich, Germany

www.sportortho.university

athletesMD

Conflict of interest

UNIVERSITÄRE
SPORTORTHOPÄDIE

Andreas B. Imhoff is a consultant for Arthrex, Arthrosurface, and Medi
Bayreuth, and receives royalties from Arthrex and Arthrosurface.

The other authors have nothing to declare.

Background

- **Patellofemoral instability (PFI)** is **multifactorial** and risk factors include – but are not limited to - **coronal malalignment** and **femoral antetorsion (FA)** [1,2]
- **MPFL reconstruction is the surgical gold standard of care**, but **high patellar instability recurrence rates** have been reported in **complex cases**, necessitating patient-specific treatment [3-6]
- Biomechanically, isolated **MPFL reconstruction** is **insufficient** in the presence of **femoral antetorsion > 20°** [7,8]
- Consequently, **surgical techniques addressing femoral antetorsion** have been developed with excellent clinical outcomes [9]
- **Change** in **coronal alignment** – an important risk factor for patellofemoral instability – **has not** yet **been investigated** in **clinical studies** assessing the outcome following **derotational distal femoral osteotomies (D-DFO)** [10,11]

Purpose and hypotheses

UNIVERSITÄRE
SPORTORTHOPÄDIE

Purpose

The purpose of the present study was to evaluate the clinical, functional, and radiological outcome following D-DFO in patients with recurrent PFI and increased FA (> 20°) after a minimum follow-up of 24 months.

Hypotheses

1. D-DFO leads to a significant improvement in subjective knee function with a low rate of patellar redislocation and a significant reduction in FA.
2. In cases of preoperative straight coronal limb alignment, no significant change in coronal alignment—especially no severe, unintended valgus deformity — occurs postoperatively.
3. In cases of preoperative valgus limb alignment, an additional varization is achievable through the surgical procedure.

Material and methods

UNIVERSITÄRE
SPORTORTHOPÄDIE

Study design	– Retrospective case series
Material	– **30 knees with recurrent PFI an increased FA (> 20°) that underwent D-DFO** – Surgery date: 06/2011-12/2018 – Minimum follow-up: 24 months – Patient age: ≥ 18 years (at follow-up) – Patients with prior alignment-correcting procedures were excluded

Methods	– **Radiological analysis:**
	  – **Change in femorotibial angle** (FTA), mechanical medial proximal tibial angle (mMPTA) and mechanical lateral distal femoral angle (mLDFA) on pre- and postoperative weight-bearing whole-leg anteroposterior radiographs
	  – **Change in FA** via pre- and postoperative lower extremity magnetic resonance imaging
	– **Functional outcome:**
	  – Pain: VAS
	  – Function: Kujala score, Lysholm score, IKDC
	  – Sporting ability: Tegner Activity Scale

Results

UNIVERSITÄRE
SPORTORTHOPÄDIE

Surgical technique

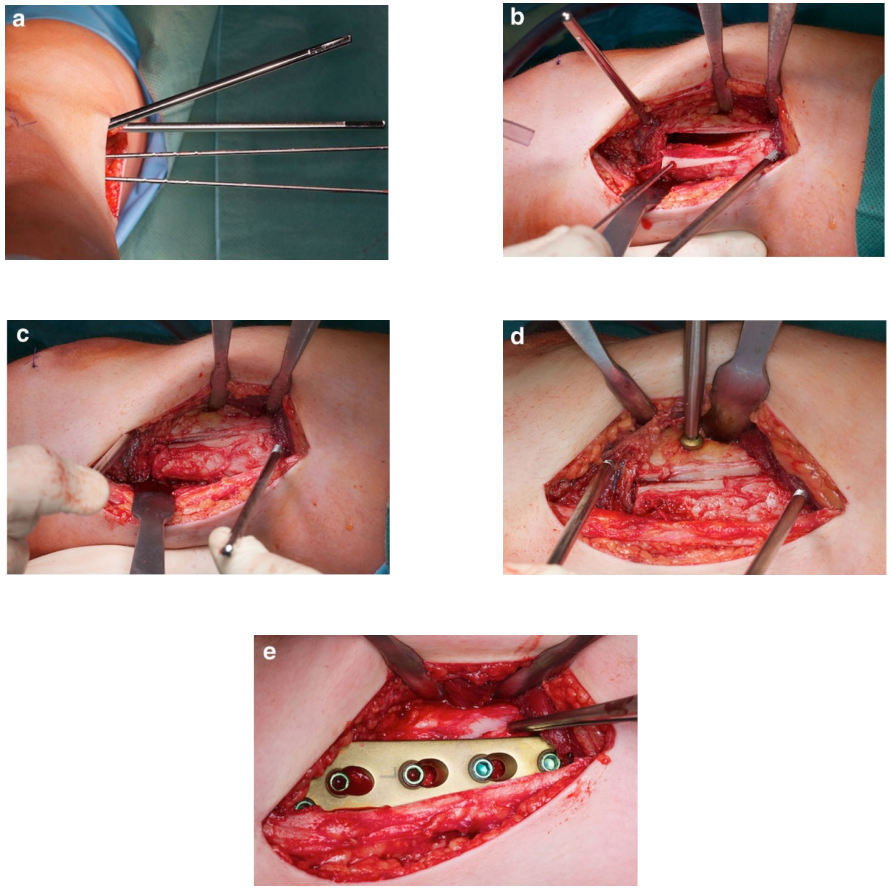

Hinterwimmer, KSSTA, 2014 [12]

Study population

Number of knees	30
Number of patients	27 (3 with bilateral D-DFO)
Sex	85.2% female
BMI	24.3 ± 4.7
Age at the time of surgery	23.5 (interquartile range: 19.8-29.0) years
Follow-up time	38.0 (31.8-52.5) months

Results

UNIVERSITÄRE
SPORTORTHOPÄDIE

Concomitant procedures

MPFL reconstruktion	21 (70.0%)
Lateral retinacular lengthening	3 (10.0%)
Trochleoplasty	3 (10.0%)
Double-level osteotomy	2 (6.7%)
Lateral patellar facetectomy	2 (6.7%)
Tibial tuberosity transfer	1 (3.3%)
Vastus medialis oblique transfer	1 (3.3%)

Results

UNIVERSITÄRE
SPORTORTHOPÄDIE

Functional outcome

– **Significant improvement** of **knee function** and **reduction in pain**

PROMs	Preoperative	Follow-Up	*p* value
VAS	2.0 (1.0-5.0)	0 (0-1.0)	< 0.05
Tegner Activity Scale	3.0 (3.0-4.0)	4.0 (3.0-5.0)	n.s.
Lysholm Score	58.6 ± 17.4	79.5 ± 16.6	< 0.05
IKDC	54.6 ± 18.7	74.1 ± 15.0	< 0.05
Kujala Score	55.6 ± 13.6	80.3 ± 16.7	< 0.05

Results

UNIVERSITÄRE SPORTORTHOPÄDIE

Radiological analysis

Isolated D-DFO (*n* = 14)	Preoperative	Postoperative	*p* value
FTA	-0.9 ± 2.2°	-1.9 ± 2.0°	n.s.
mLDFA	88.7 ± 2.9°	89.5 ± 2.9°	n.s.
mMPTA	87.8 ± 2.5°	87.6 ± 1.8°	n.s.

Combined derotational and varization DFO (*n* = 14)	Preoperative	Postoperative	*p* value
FTA	2,4 ± 1.2	0.3 ± 2.4	**< .05**
mLDFA	87.3 ± 2.5	89.0 ± 3.5	**< .05**
mMPTA	88.5 ± 1.4	88.0 ± 1.5	n.s.

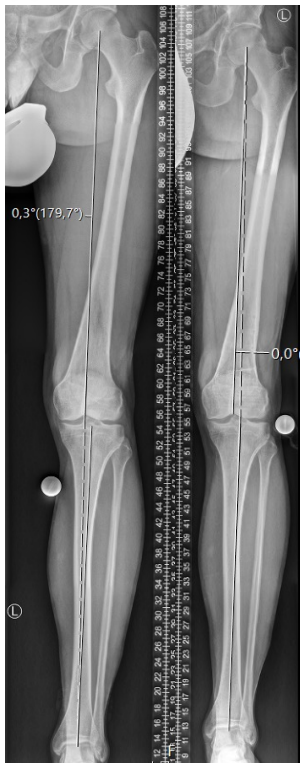

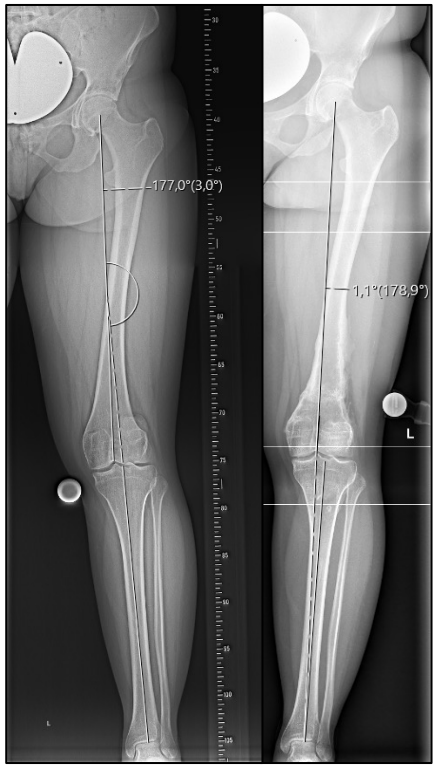

– Overall **significant reduction** in **FA** (28.2 ± 6.4° vs. 13.6 ± 5.2°; $p < 0.05$)

Limitations

1. Concomitant procedures as confounding factors
2. Retrospective case series
3. Long-term results unclear

Conclusion

UNIVERSITÄRE
SPORTORTHOPÄDIE

- Patients with recurrent PFI and an associated increased FA can be successfully treated with D-DFO
- A significant reduction in pain, improvement of subjective knee function, and an adequate correction of torsional and valgus alignment are achieved at short- to mid-term follow-up

> Knee Surg Sports Traumatol Arthrosc. 2022 Sep 16. doi: 10.1007/s00167-022-07150-9.
Online ahead of print.

Derotational distal femoral osteotomy for patients with recurrent patellar instability and increased femoral antetorsion improves knee function and adequately treats both torsional and valgus malalignment

Maximilian Hinz [1], Matthias Cotic [2], Theresa Diermeier [3], Florian B Imhoff [4], Georg C Feuerriegel [5], Klaus Woertler [5], Alexander Themessl [2], Andreas B Imhoff [2], Andrea Achtnich [2]

Affiliations + expand

PMID: 36109379
DOI: 10.1007/s00167-022-07150-9



References

UNIVERSITÄRE
SPORTORTHOPÄDIE

[1] Weber AE, Nathani A, Dines JS, Allen AA, Shubin-Stein BE, Arendt EA et al (2016) An algorithmic approach to the management of recurrent lateral patellar dislocation. J Bone Joint Surg Am 98:417–427

[2] Dejour DH, Mesnard G, Giovannetti de Sanctis E (2021) Updated treatment guidelines for patellar instability: “un menu à la carte.” J Exp Orthop 8:109

[3] Nelitz M, Williams RS, Lippacher S, Reichel H, Dornacher D (2014) Analysis of failure and clinical outcome after unsuccessful medial patellofemoral ligament reconstruction in young patients. Int Orthop 38:2265–2272

[4] Schneider DK, Grawe B, Magnussen RA, Ceasar A, Parikh SN, Wall EJ et al (2016) Outcomes after isolated medial patellofemoral ligament reconstruction for the treatment of recurrent lateral patellar dislocations: a systematic review and meta-analysis. Am J Sports Med 44:2993–3005

[5] Sappey-Marinier E, Sonnery-Cottet B, O’Loughlin P, Ouanezar H, Reina Fernandes L, Kouevidjin B et al (2019) Clinical outcomes and predictive factors for failure with isolated MPFL reconstruction for recurrent patellar instability: a series of 211 reconstructions with a minimum follow-up of 3 years. Am J Sports Med 47:1323–1330

[6] Feucht MJ, Mehl J, Forkel P, Achtnich A, Schmitt A, Izadpanah K et al (2020) Failure analysis in patients with patellar redislocation after primary isolated medial patellofemoral ligament reconstruction. Orthop J Sports Med 8:2325967120926178

[7] Kaiser P, Schmoelz W, Schoettle P, Zwierzina M, Heinrichs C, Attal R (2017) Increased internal femoral torsion can be regarded as a risk factor for patellar instability—a biomechanical study. Clin Biomech (Bristol, Avon) 47:103–109

[8] Kaiser P, Schmoelz W, Schöttle PB, Heinrichs C, Zwierzina M, Attal R (2019) Isolated medial patellofemoral ligament reconstruction for patella instability is insufficient for higher degrees of internal femoral torsion. Knee Surg Sports Traumatol Arthrosc 27:758–765

[9] Zhang Z, Cao Y, Song G, Li Y, Zheng T, Zhang H (2021) Derotational femoral osteotomy for treating recurrent patellar dislocation in the presence of increased femoral anteversion: a systematic review. Orthop J Sports Med 9:23259671211057130

[10] Nelitz M, Wehner T, Steiner M, Dürselen L, Lippacher S (2014) The effects of femoral external derotational osteotomy on frontal plane alignment. Knee Surg Sports Traumatol Arthrosc 22:2740–2746

[11] Flury A, Hoch A, Hodel S, Imhoff FB, Fucentese SF, Zingg PO (2022) No relevant mechanical leg axis deviation in the frontal and sagittal planes is to be expected after subtrochanteric or supracondylar femoral rotational or derotational osteotomy. Knee Surg Sports Traumatol Arthrosc. https://doi.org/10.1007/s00167-021-06843-x

[12] Hinterwimmer S, Minzlaff P, Saier T, Niemeyer P, Imhoff AB, Feucht MJ (2014) Biplanar supracondylar femoral derotation osteotomy for patellofemoral malalignment: the anterior closed-wedge technique. Knee Surg Sports Traumatol Arthrosc 22:2518–2521

UNIVERSITÄRE
SPORTORTHOPÄDIE

Thank you for your attention

Contact details:

Maximilian Hinz, MD

Department of Sports Orthopaedics

Technical University of Munich

maximilian.hinz@tum.de

athletesMD

www.sportortho.university