ISAKOS CONGRESS 2023
Boston
Massachusetts
June 18 – June 21
International Society of Arthroscopy, Knee Surgery and Orthopaedic Sports Medicine

HIGH CURE RATE IN HEMATOGENOUS TKA PJI AT A LONG-TERM FOLLOW-UP BY MEANS OF DAIR PROCEDURE

Daniel Pérez-Prieto, Albert Fontanellas Fes, Raúl Torres-Claramunt, Juan Francisco Sánchez-Soler, Joan Carles Monllau, Pedro Hinarejos-Gómez

Hospital del Mar, Barcelona

Parc de Salut Barcelona
MAR

DISCLOSURE

The author declare that there is no conflict of interests.

INTRODUCTION

Prosthetic Joint Infection (PJI) [1]

Early postoperative (<30d)

Debridement, Antibiotics and Implant Retention (DAIR)

≥ 90% cure rate [2]

Late acute hematogenous (LAH)

¿ ?

Chronic PJI

One or two stage exchange

[1] **Zimmerli W, Trampuz A, Ochsner PE**. Prosthetic-joint infections. *N Engl J Med* 2004;351(16):1645–1654.

[2] **Zhang C-F, He L, Fang X-Y, Huang Z, Bai G-C, Li W-B, et al**. Debridement, Antibiotics, and Implant Retention for Acute Periprosthetic Joint Infection. Orthop Surg 2020;12(2):463–470.

OBJECTIVE

Report the cure rate of LAH PJI following TKA treated by means of DAIR at long-term follow up,

DAIR provides a high cure rate in LAH PJI with functional outcomes comparable to non-infected cases.

MATERIALS AND METHODS

Prospective study

Single center

TKA performed between 2005 and 2010

Exclusion Criteria

- History of infection in the knee
- History of allergy to ALBC
- Minimum follow up 12 months

TKA

⇩

Diagnosis of PJI [1]

⇩

Treatment

DIAGNOSIS OF PROSTHETIC JOINT INFECTION (PJI)

**Zimmerli criteria (Prosthetic-Joint Infections. NEJM. 2004)*

- **Sinus tract.**
- **Purulent discharge.**
- **Synovial Fluid: ≥1.700 PMN/mm^3 or > 65% PMN.**
- **≥2 positive cultures (x3 intraoperative tissue specimens).**
- **Histopathological studies ≥5 PMN/HPF**

[1] **Zimmerli W, Trampuz A, Ochsner PE**. Prosthetic-joint infections. *N Engl J Med* 2004;351(16):1645–1654.

MATERIALS AND METHODS

Prospective study

Single center

TKA performed between 2005 and 2010

TKA

⇩

Diagnosis of PJI [1]

⇩

Treatment

Failure rate

- Further surgical intervention for tt of infection
- Death before the end of ATB tt
- Life long ATB tt

Knee Society Score (KSS)

Antibiotic treatment

Source of infection (primary focus)

Microorganisms isolated

Surgeon who performed the surgery

[1] **Zimmerli W, Trampuz A, Ochsner PE**. Prosthetic-joint infections. *N Engl J Med* 2004;351(16):1645–1654.

RESULTS

8,5 years follow up

10 acute hematogenous PJI of 2498 TKA

Rate of LAH **0,4%**

⇩

DAIR performed in all them by knee or PJI surgeon

⇩

0% Failure rate

RESULTS

- 4,7 y (SD 3,6) elapsed time TKA to LAH
- 2,75 d DAIR from the onset of symptoms.
- 3 cases identified source of infection

Organism	Total (n=10)
Staphylococcus aureus	3
Escherichia colli	3
Coagulase negative staphylococcus (CNS)	2
Culture-negative PJI	2

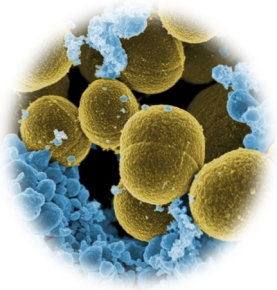

RESULTS

	Late acute hematogenous (LAH) (n=10)	Control group (n=20)	P value
Age (yr.)	72.60 ± 9.47	70.70 ± 9.76	0.44
Gender (M/F) (%)	2/8 (20/80)	4/16 (20/80)	1
KSS	84.1 ± 17.87	82.10 ± 10.7	0.29
Follow up (years)	8.5 ± 2.46	8.95± 2.96	0.74

DISCUSION

Prosthetic Joint Infection (PJI) [1]

Observational Study > J Infect. 2019 Jan;78(1):40-47. doi: 10.1016/
Epub 2018 Aug 7.

Clinical outcome and risk factors for failure in late acute prosthetic joint infections treated with debridement and implant retention

Marjan Wouthuyzen-Bakker [1], Marine Sebillotte [2], Jose Lomas [3], Adrian Taylor [3], Eva Benavent Palomares [4], Oscar Murillo [4], Javad Parvizi [5], Noam Shohat [6],

Late acute hematogenous (LAH)

DAIR
Low cure rate (≈ 70%)

Observational Study > Clin Orthop Relat Res. 2020 Jun;478(6):1348-1355.
doi: 10.1097/CORR.0000000000001171.

Lower Success Rate of Débridement and Implant Retention in Late Acute versus Early Acute Periprosthetic Joint Infection Caused by Staphylococcus spp. Results from a Matched Cohort Study

Marjan Wouthuyzen-Bakker [1], Marine Sebillotte [2], Kaisa Huotari [3], Rosa Escudero Sánchez [4], Eva Benavent [5], Javad Parvizi [6], Marta Fernandez-Sampedro [7], José Maria Barbero [8],

[1] **Zimmerli W, Trampuz A, Ochsner PE**. Pro
infections. *N Engl J Med* 2004;351(16):1645–1654.

DISCUSION

DAIR
High cure rate (100%)

Why this disparity?

DAIR
Low cure rate (≈ 70%)

- **Misdiagnose** LAH PJI
  - Unrecognized chronic PJI that deteriorated acutely
- DAIR performed by **knee and/or PJI surgeon**
- 50% staphylococcal species in our study.
  - High cure rate
- Non streptococcal microorganism in our study
  - Lower cure rate

CONCLUSION

DAIR provides a **high cure rate** in LAH PJI with **good functional outcomes** in long term follow up

REFERENCES

1. McNally M, Sousa R, Wouthuyzen-Bakker M, Chen AF, Soriano A, Vogely HC, et al. The EBJIS definition of periprosthetic joint infection. Bone Joint J 2021;103-B(1):18–25.
2. McNally M, Sousa R, Wouthuyzen-Bakker M, Chen AF, Soriano A, Vogely HC, et al. Infographic: The EBJIS definition of periprosthetic joint infection. Bone Joint J 2021;103-B(1):16–17
3. Zimmerli W, Trampuz A, Ochsner PE. Prosthetic-joint infections. N Engl J Med 2004;351(16):1645–1654.
4. Zimmerli W, Widmer AF, Blatter M, Frei R, Ochsner PE. Role of rifampin for treatment of orthopedic implant-related staphylococcal infections: a randomized controlled trial. Foreign-Body Infection (FBI) Study Group, 1998. Grammatopoulos G, Bolduc M-E, Atkins BL, Kendrick BJL, McLardy-Smith P, Murray DW, et al. Functional outcome of debridement, antibiotics and implant retention in periprosthetic joint infection involving the hip: a case-control study. Bone Joint J 2017;99-B(5):614–622.
5. Ghirardelli S, Fidanza A, Prati P, Iannotti F, Indelli PF. Debridement, antibiotic pearls, and retention of the implant in the treatment of infected total hip arthroplasty. Hip Int 2020;30(1_suppl):34–41.
6. Zhang C-F, He L, Fang X-Y, Huang Z, Bai G-C, Li W-B, et al. Debridement, Antibiotics, and Implant Retention for Acute Periprosthetic Joint Infection. Orthop Surg 2020;12(2):463–470.
7. Winkler T, Stuhlert MGW, Lieb E, Müller M, Roth P von, Preininger B, et al. Outcome of short versus long interval in two-stage exchange for periprosthetic joint infection: a prospective cohort study. Arch Orthop Trauma Surg 2019;139(3):295–303.
8. Ilchmann T, Zimmerli W, Ochsner PE, Kessler B, Zwicky L, Graber P, et al. One-stage revision of infected hip arthroplasty: outcome of 39 consecutive hips. Int Orthop 2016;40(5):913–918.
9. Koh IJ, Han S-B, In Y, Oh K-J, Lee D-H, Kim TK, et al. Open debridement and prosthesis retention is a viable treatment option for acute periprosthetic joint infection after total knee arthroplasty. Arch Orthop Trauma Surg 2015;135(6):847–855.
10. Izakovicova P, Borens O, Trampuz A. Periprosthetic joint infection: current concepts and outlook. EFORT Open Rev 2019;4(7):482–494.
11. Pérez-Prieto D, Hinarejos P, Alier A, Sorlí L, Martínez S, Puig L, et al. Adherence to a reliable PJI diagnostic protocol minimizes unsuspected positive cultures rate. BMC Musculoskelet Disord 2021;22(1):653.