ISAKOS CONGRESS 2023

Boston Massachusetts June 18–June 21

Clinical Outcomes Of Lateral Meniscus Posterior Root Repair In The Acl-Reconstructed Knees.

Lika Dzidzishvili

Irene Isabel López-Torres

David Sáez

Antonio Hernández Diez

Emilio Calvo

Hospital Universitario Fundación Jiménez Díaz Grupo quirónsalud

IIS FJD Instituto de Investigación Sanitaria Fundación Jiménez Díaz

UAM Universidad Autónoma de Madrid

ISAKOS CONGRESS 2023

Boston
Massachusetts
June 18–June 21

Author´s Disclosure

L.D, II.LT, DS, and AHD have nothing to disclose.

E.C. has received consulting fees from DePuy Synthes, Smith & Nephew, and Stryker.

Hospital Universitario Fundación Jiménez Díaz
Grupo quirónsalud

IIS FJD
INSTITUTO DE INVESTIGACIÓN SANITARIA
FUNDACIÓN JIMÉNEZ DÍAZ

UAM Universidad Autónoma de Madrid

Background and Objective

- Biomechanical studies have demonstrated the importance of lateral meniscus posterior root (LMPR) repair provides secondary stability to the anterior cruciate ligament (ACL) during pivot shift loading. On the other hand, meniscal tears (other than root tears) repaired at the time of ACL reconstruction have demonstrated improved outcomes when compared with those repaired in isolation. It has been theorized that the reason behind these improved outcomes relates to a favorable healing environment created by biological augmentation of the repair from the intra-articular release of the bone marrow when drilling the ACL tunnels.

- The main purpose of the study was to report clinical and radiological outcomes of LMPR repair in the ACL-reconstructed knee.

Methods

- 17 patients with LMPR and ACL injury.
- Clinical outcomes: KOOS and Lysholm Knee Questionnare.
- Radiological outcomes: Kellgren-Lawrence grade using a plain X-ray, MRI evaluation for cartilage damage and meniscal extrusion.
- Intraoperative arthroscopic assessments.

Summary of Results

Follow up (months)	29.4 ± 5.5
Age	32.1 ± 9.9
BMI	25.7 ± 3.5
Time from injury to surgery (months)	6.4 ± 6.1
Male	13 (76.5%)
Female	4 (23.5%)
Right	6 (35.3%)
Left	11 (64.7%)
La Prade Classification	
1	0 (0.0%)
2	2 (11.8%)
3	6 (35.3%)
4	0 (0.0%)
5	9 (52.9%)

Table 1. Summary of baseline demographic and clinical data of all included patients.

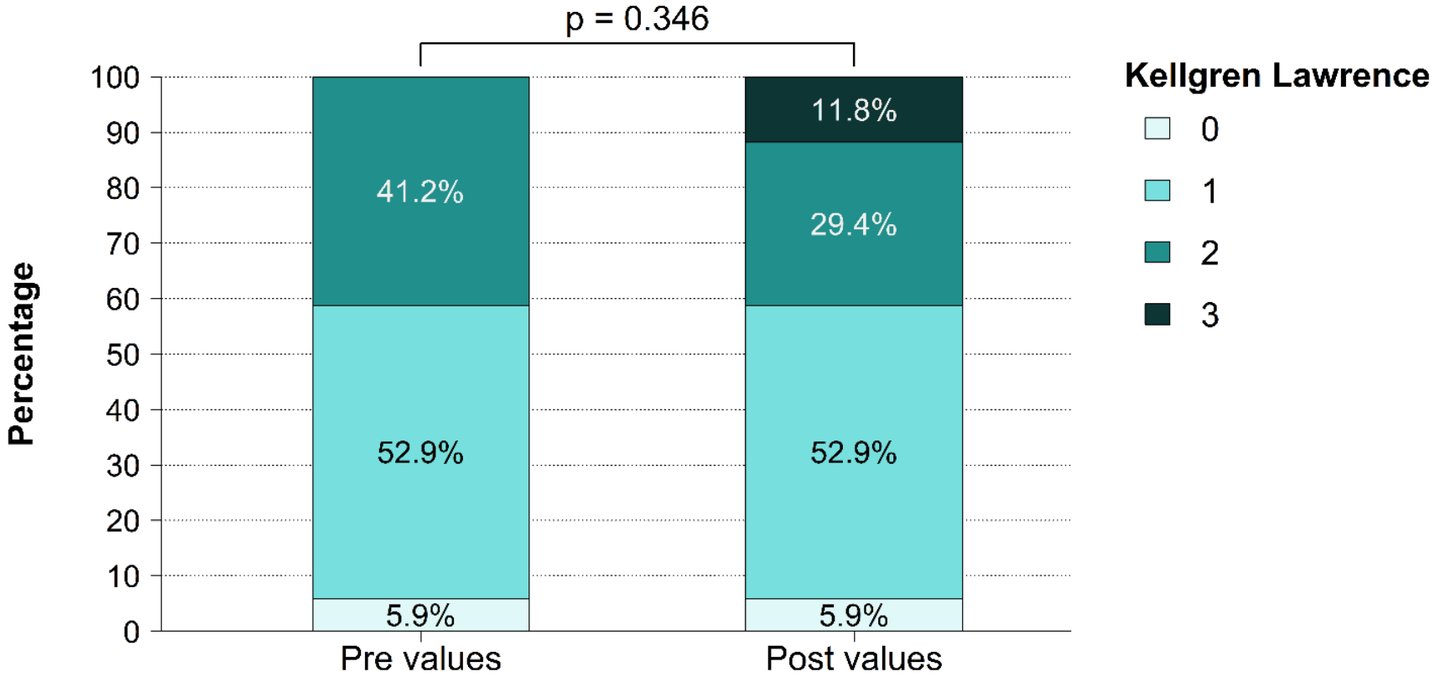

Figure 1. No significant radiological progression of arthritic changes was observed postoperatively using KL score (P=0.346).

ISAKOS CONGRESS 2023 | Boston Massachusetts June 18–June 21 | Hospital Universitario Fundación Jiménez Díaz Grupo quironsalud | IIS FJD | Instituto de Investigación Sanitaria Fundación Jiménez Díaz | UAM Universidad Autónoma de Madrid

Summary of Results

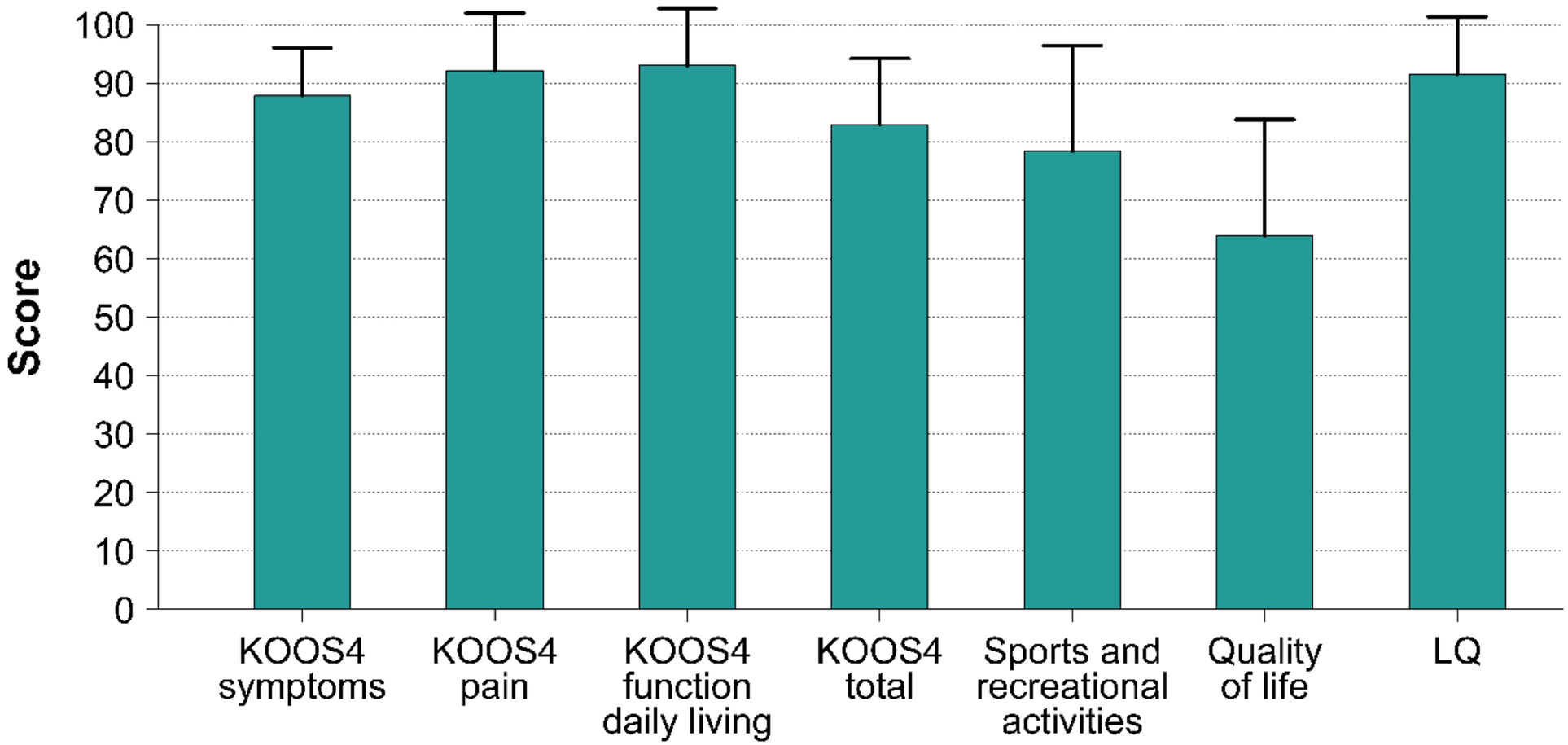

Figure 2. Significantly improved clinical outcomes were observed postoperatively and at the final follow-up.

Summary of Results

Postoperative meniscal extrusion	
Yes	2 (11.8%)
Osteochondral defect	
Yes	1 (5.9%)

Table 2. Regarding postoperative MRI findings, 2 patients presented meniscal extrusion and only 1 case of osteochondral defect was documented.

Conclusions

Satisfactory midterm clinical and radiological outcomes with no re-tears and progression to knee OA have been observed.

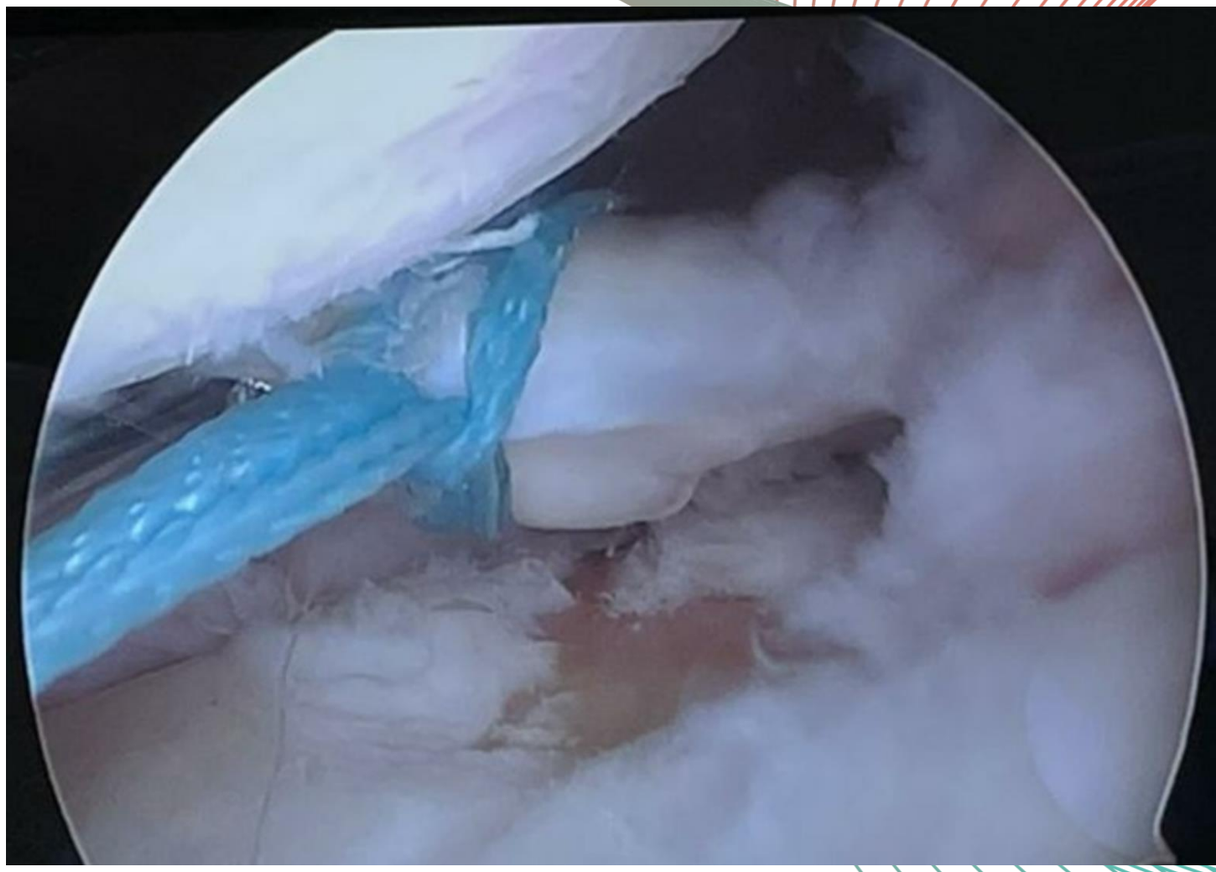

References

- Tang X, Marshall B, Wang JH, Zhu J, Li J, Smolinski P, Fu FH. Lateral Meniscal Posterior Root Repair With Anterior Cruciate Ligament Reconstruction Better Restores Knee Stability. Am J Sports Med. 2019 Jan;47(1):59-65. doi: 10.1177/0363546518808004.
- Forkel P, von Deimling C, Lacheta L, Imhoff FB, Foehr P, Willinger L, Dyrna F, Petersen W, Imhoff AB, Burgkart R. Repair of the lateral posterior meniscal root improves stability in an ACL-deficient knee. Knee Surg Sports Traumatol Arthrosc. 2018 Aug;26(8):2302-2309. doi: 10.1007/s00167-018-4949-8.
- Uffmann W, ElAttrache N, Nelson T, Eberlein SA, Wang J, Howard DR, Metzger MF. Posterior Lateral Meniscal Root Tears Increase Strain on the Reconstructed Anterior Cruciate Ligament: A Cadaveric Study. Arthrosc Sports Med Rehabil. 2021 Feb 3;3(2):e505-e513. doi: 10.1016/j.asmr.2020.11.005.
- Dean CS, Chahla J, Matheny LM, Mitchell JJ, LaPrade RF. Outcomes After Biologically Augmented Isolated Meniscal Repair With Marrow Venting Are Comparable With Those After Meniscal Repair With Concomitant Anterior Cruciate Ligament Reconstruction. Am J Sports Med. 2017 May;45(6):1341-1348. doi: 10.1177/0363546516686968.
- LaPrade CM, James EW, Cram TR, Feagin JA, Engebretsen L, LaPrade RF. Meniscal root tears: a classification system based on tear morphology. *Am J Sports Med*. 2015; 43(2):363–369. https://doi.org/10.1177/0363546514559684.
- Outerbridge RE. The etiology of chondromalacia patellae. *J Bone Joint Surg Br*. 1961; 43-B:752–757. https://doi.org/10.1302/0301-620X.43B4.752.
- Roos EM, Roos HP, Lohmander LS, Ekdahl C, Beynnon BD. Knee injury and osteoarthritis outcome score (KOOS)–development of a self-administered outcome measure. *J Orthop Sports Phys Ther*. 1998;28(2):88–96. https://doi.org/10.2519/ jospt.1998.28.2.88.
- Tegner Y, Lysholm J. Rating systems in the evaluation of knee ligament injuries. *Clin Orthop Relat Res*. 1985;198:43–49.