



ISAKOS
CONGRESS
2023



Boston
Massachusetts
June 18-June 21

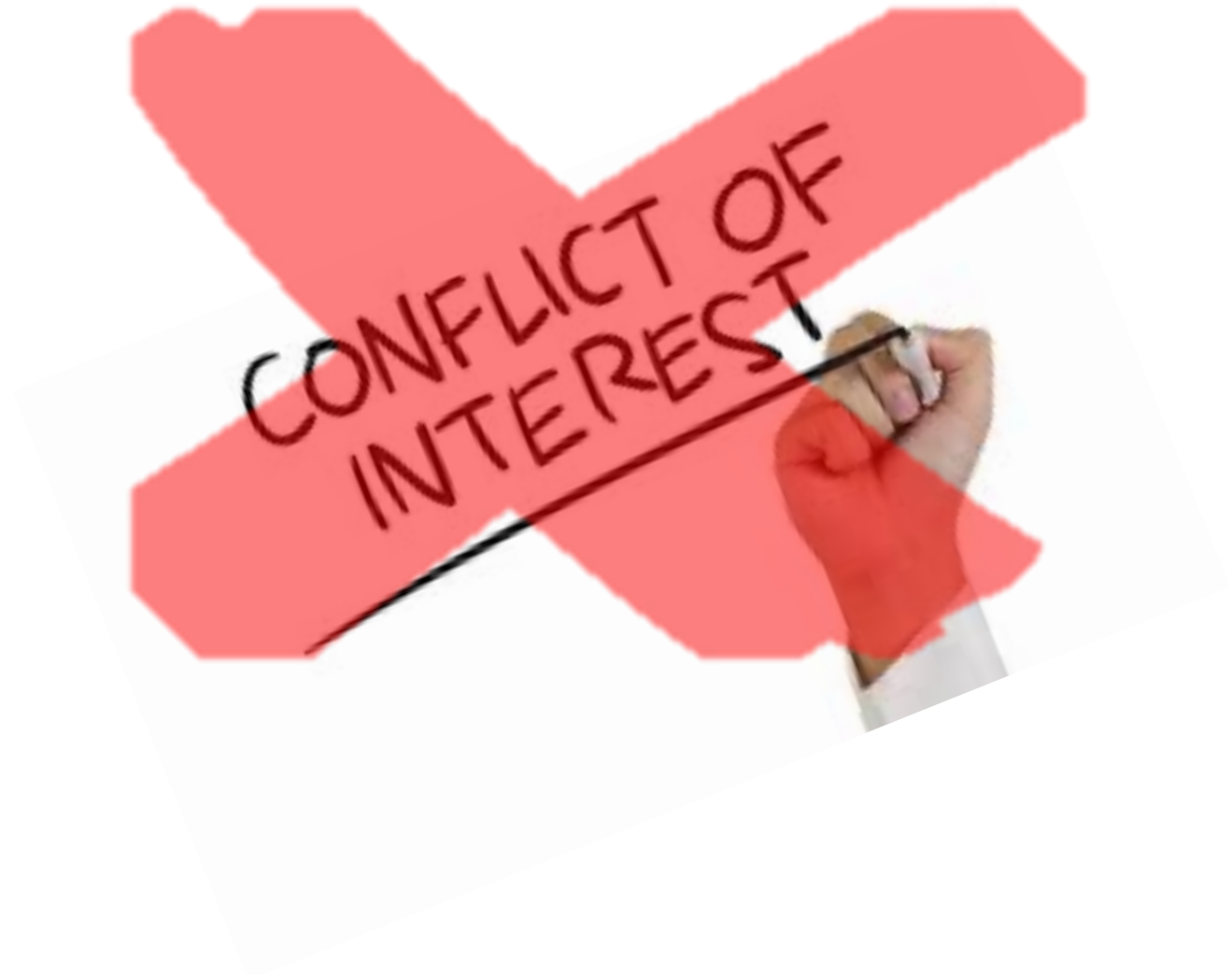

Polyurethane Meniscal Scaffold In Postmeniscectomy Syndrome Presented Good Clinical Results At Minimum 10-Years Of Follow-Up

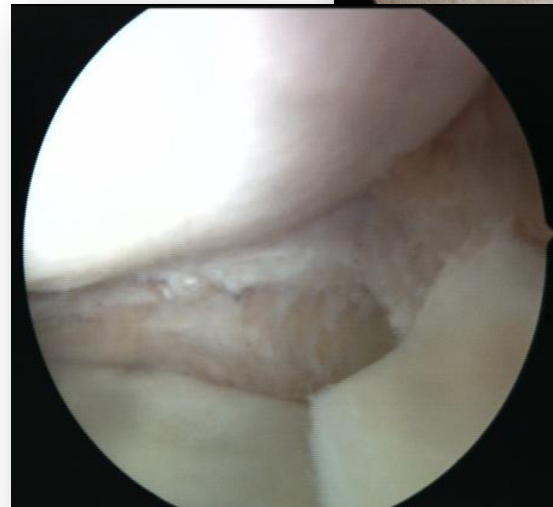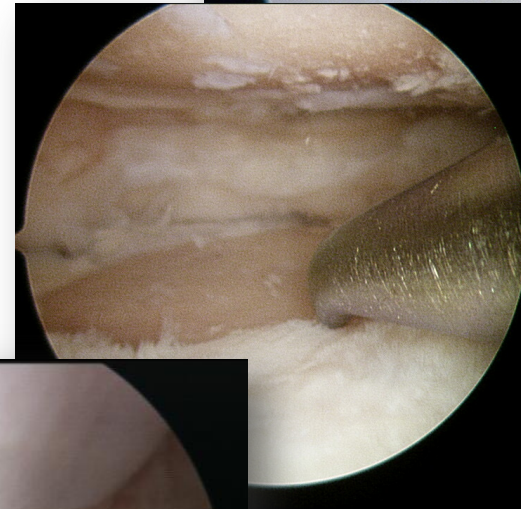
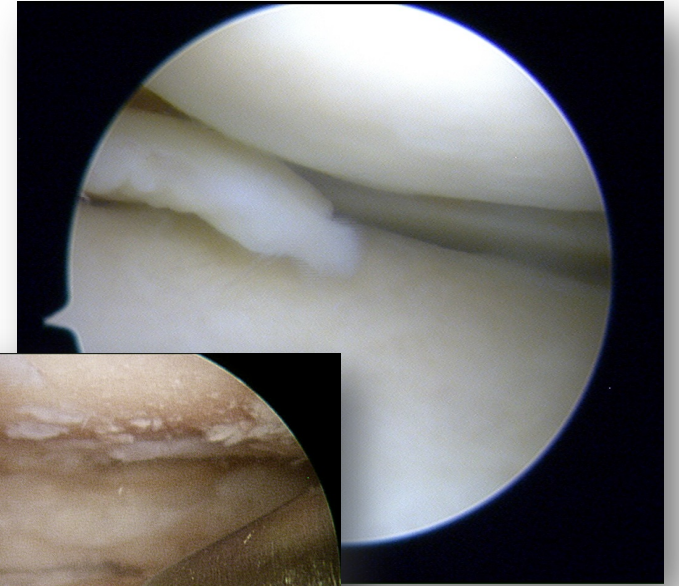
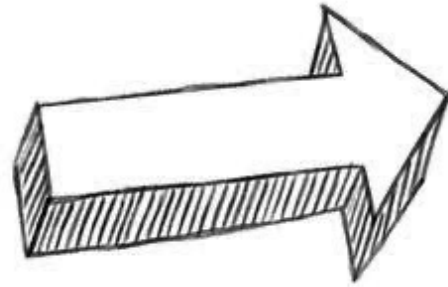
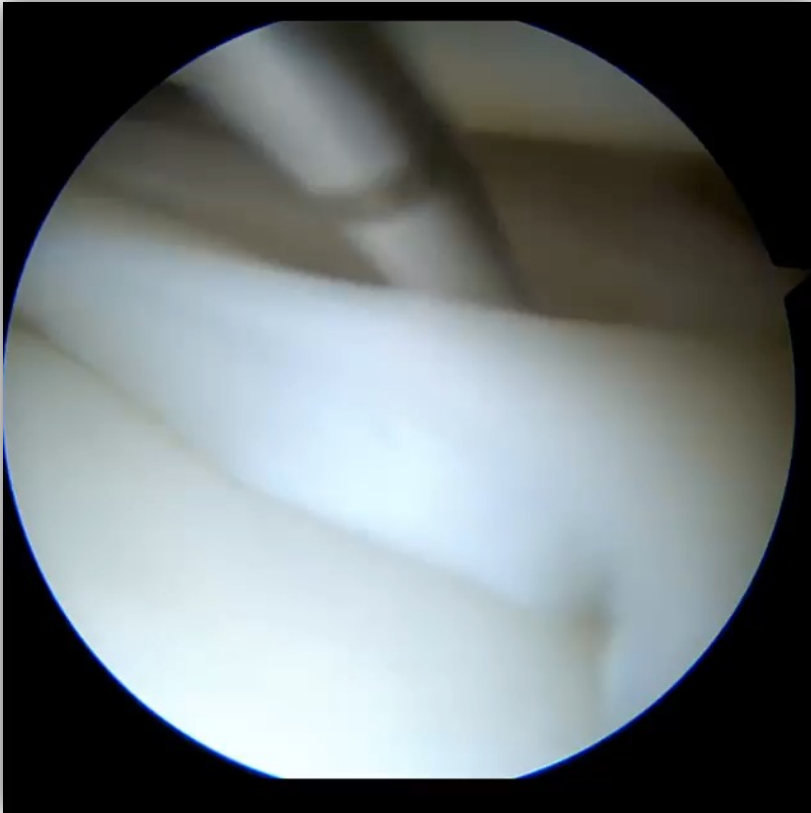
Ibañez Maximiliano, Torres Claramunt Raul, Perelli Simone, Masferrer Pino Angel, Perez Prieto Daniel, Gelber Ghertner Pablo Eduardo, Monllau Joan Carles

*ICATME - Hospital Universitario Quirón-Dexeus
Barcelona*

Hospital Universitari **Dexeus**
Grupo **quirónsalud**



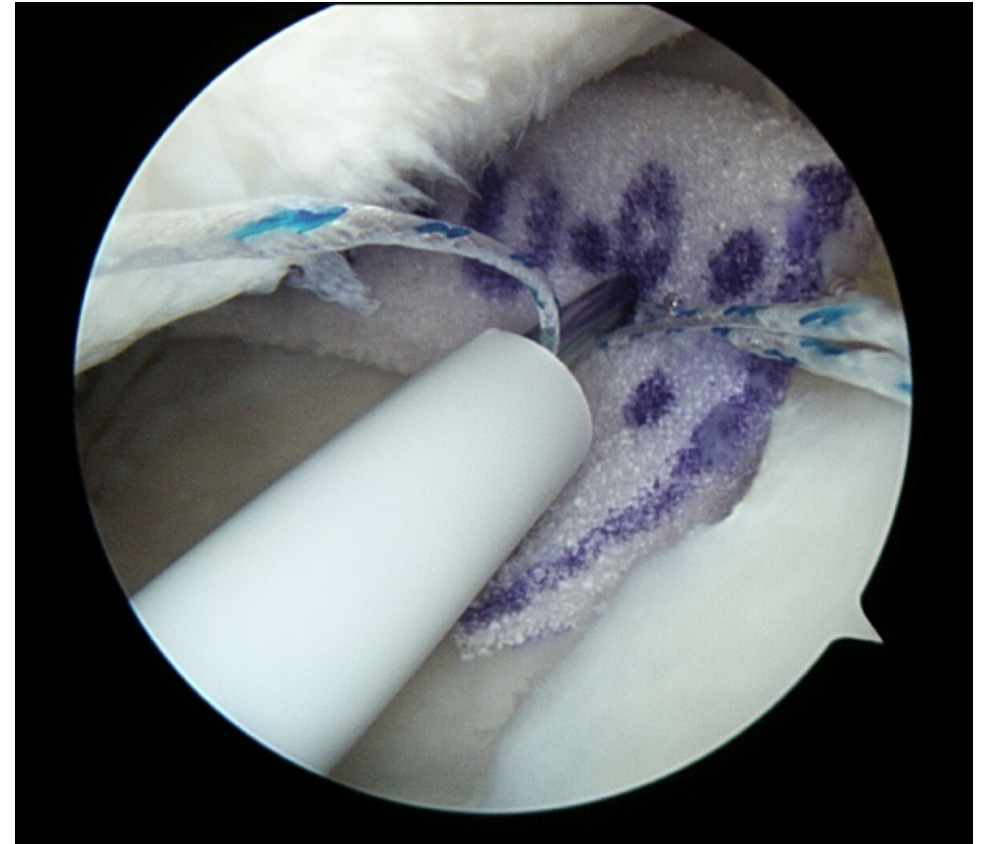
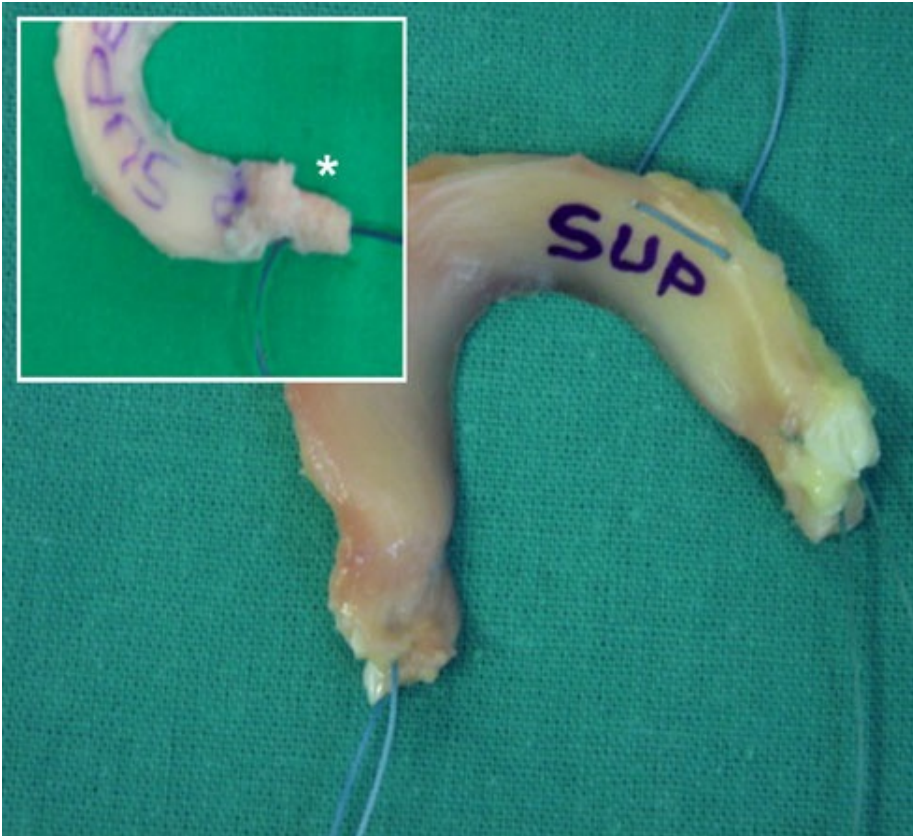Background



save the.
meniscus
some things are better left intact



Post-meniscectomy syndrome



Purpose

To evaluate the clinical outcomes at a minimum 10-year follow up in a series of patients with post-meniscectomy syndrome treated with a polyurethane meniscal scaffold.

Hypothesis

Both pain relief and improvement in knee functions, observed after a 5-year follow-up, would remain significant, despite the expected joint deterioration associated with the aging process

Methods

- Prospective study: 27 patients (2008 – 2011)
- KOOS, IKDC, Lysholm, Tegner
- X-Ray –MRI (5 – 10 years post op)
- *Student's t-test. 0,05.*

EXCLUSION

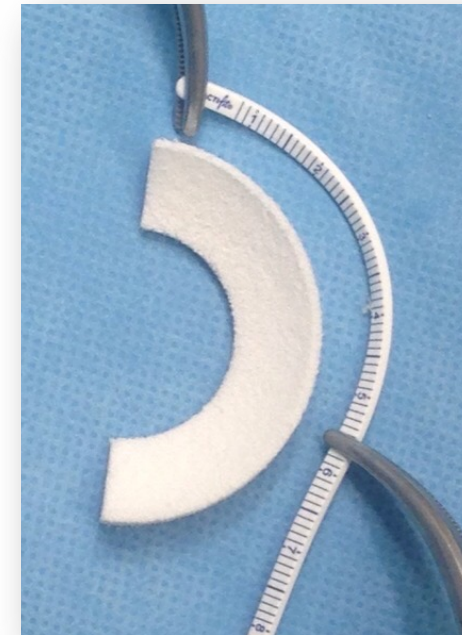- Complete absence of meniscus
- Grade III – IV chondral lesión
- Untreated knee instabilities
- Untreated malalignments $>5^\circ$
 - Inflammatory arthritis
 - Polyurethane allergy
- Autoimmune diseases and pregnancy

ARTHROSCOPIC TECHNIQUE

- ALL-IN Posterior horn
- OUT-IN Body and anterior horn

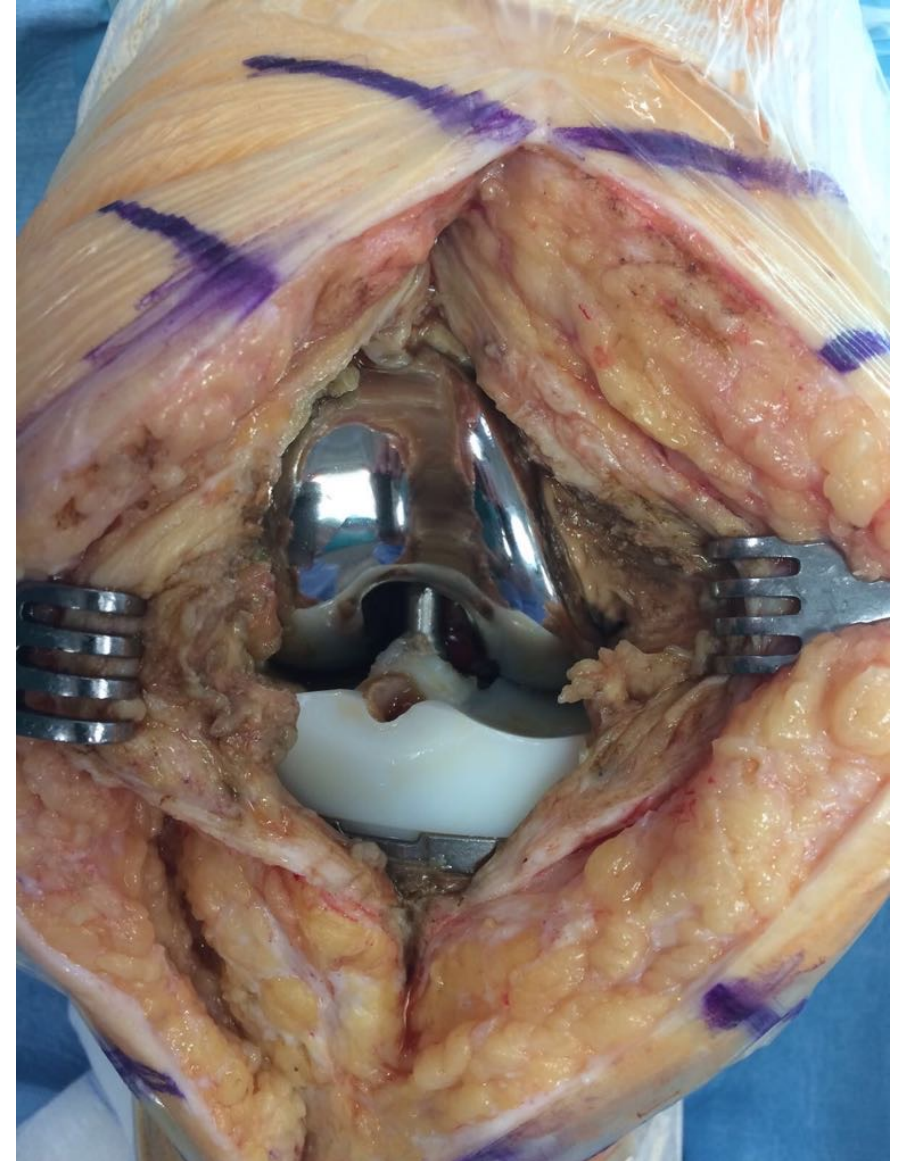
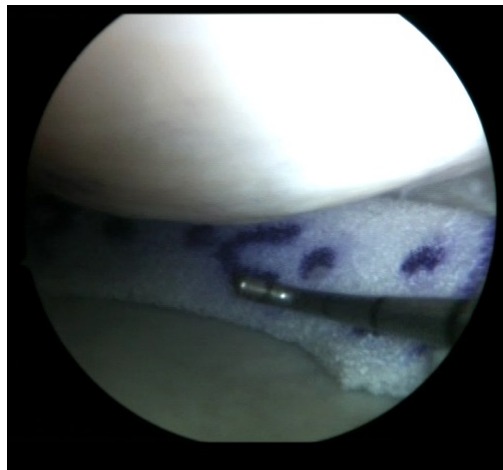

Surgical Technique	n
Isolated polyurethane scaffold implantation	6
Microfractures	2
HTO	5
HTO + microfractures	9
ACL-R	1
ACL-R + microfractures	2
ACL-R + HTO	1
PCL-R	1

HTO, high tibial osteotomy; ACL-R, anterior cruciate ligament reconstruction;
PCL-R, posterior cruciate ligament reconstruction.



Results

- **21 patients**
 - Male 17 Female 4
 - Right 10 Left 11
- *Follow-up 142.2 +/- 9.6 (123-153) months*
- *Age 56 +/- 9.8 años (36 - 68)*
- *No complications*
- **2 TKR 122 months**

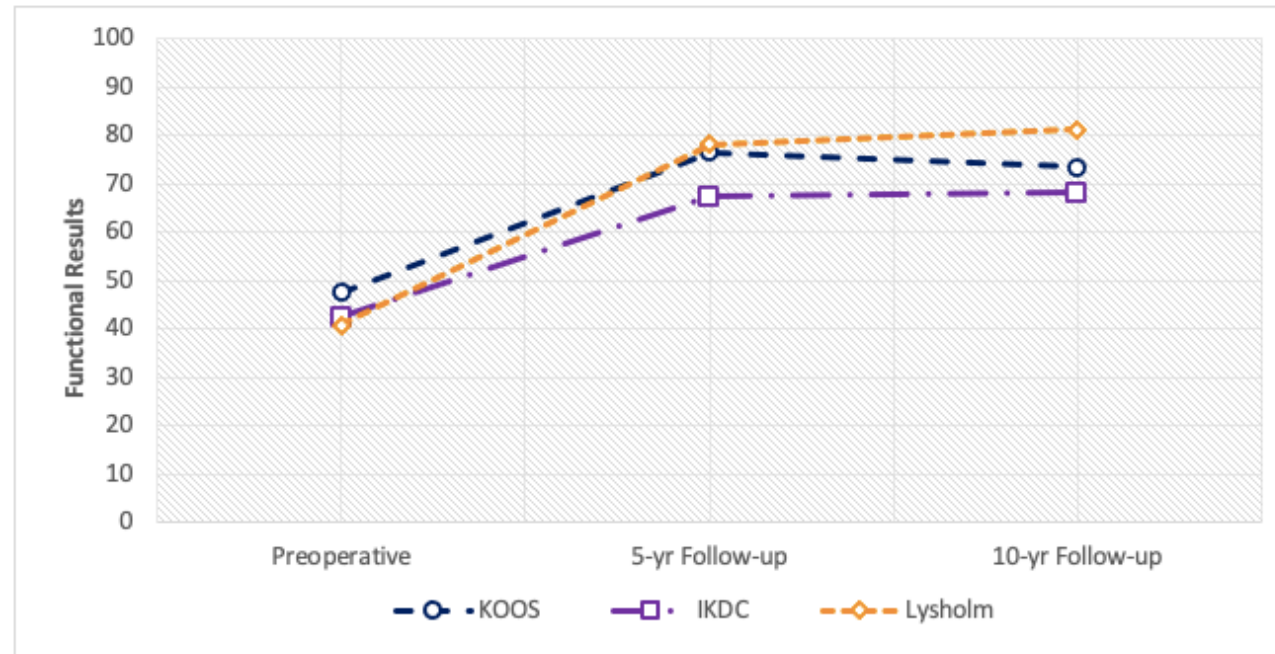


Results

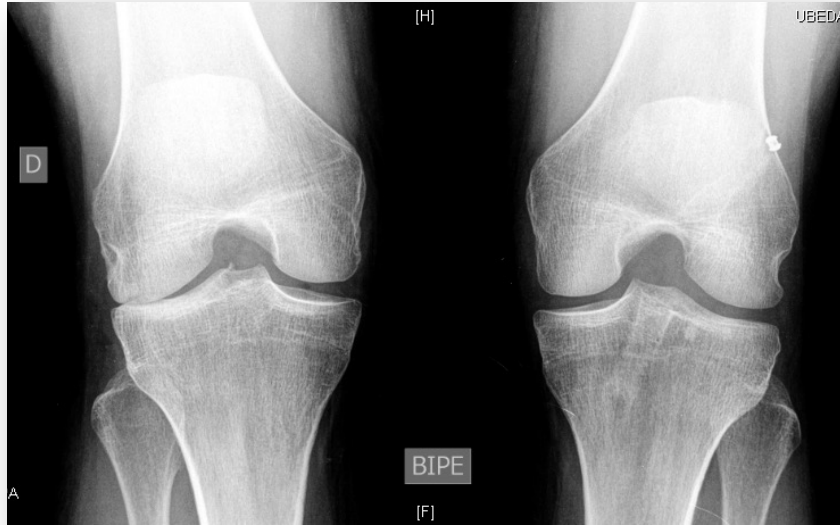	Preoperative	5-yr Follow-up	Final Follow-up
KOOS	47.4 ± 21.2 (15-88)	76.5 ± 11.7 (60-100); p<0.001	73.4 ± 20.6 (25-97.6); p<0.001
IKDC	42.3 ± 19.1 (13.2-82.8)	67.2 ± 15.5 (41.4-88.5); p<0.001	68.1 ± 20.6 (28,7-95.4); p=0.001
Lysholm	40.7 ± 18.4 (11-88)	77.0 ± 17.1 (60-100); p<0.001	81.2 ± 15.7 (49-100); p<0.001
Tegner	5 (0-9)	5 (2-8); n.s.	6 (1-8); n.s.

NOTE. All data are expressed as mean ± SD (range). Statistical significance (P value) was set at 0.05.

KOOS, Knee injury and Osteoarthritis Outcomes Score; IKDC, International Knee Documentation Committee.

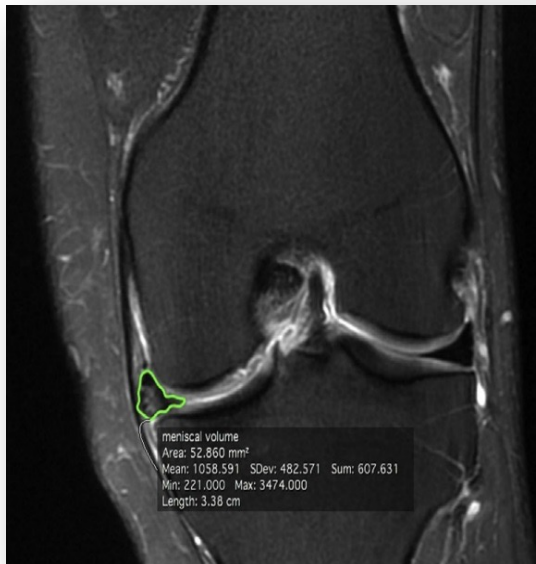


Results



Joint space narrowing in the Rosenberg projection

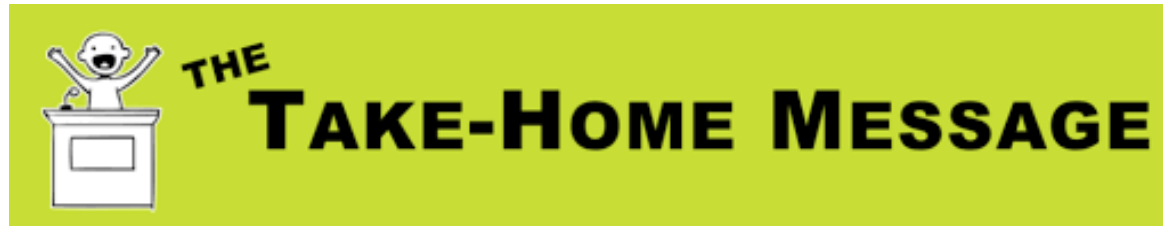5 years	10 years	
1.32 ± 1.57 mm (0-4)	0.5 ± 1.32 mm (0-3.5)	P>0.05



Complete resorption at 10-year follow-up in 4 MRI

Conclusion

The polyurethane implant in patients with postmeniscectomy syndrome provides significant and stable pain relief over time, with good functional results at 10 years. However, the images obtained do not demonstrate a chondroprotective effect.



- The implant improves symptoms even after 10 years, in a meniscectomized compartment, even though arthritic changes are evident
- A survival rate of 90.5% at 10 years is a fact to consider



ICATKNEE
Cirugía de Rodilla



drmaximilianoibanez



Maximiliano Ibañez

drmaximilianoibanez@gmail.com

References

1. Toanen C, Dhollander A, Bulgheroni P, Filardo G, Zaffagnini S, Spalding T, Monllau JC, Gelber P, Verdonk R, Beaufils P, Pujol N, Bulgheroni E, Asplin L, Verdonk P. Polyurethane Meniscal Scaffold for the Treatment of Partial Meniscal Deficiency: 5-Year Follow-up Outcomes: A European Multicentric Study. *Am J Sports Med.* 2020;48(6):1347-1355.
2. Figueroa D, Figueroa F, Calvo R, Gomez C, Vaisman A. Meniscal polyurethane scaffold plus cartilage repair in post meniscectomy syndrome patients without malalignment improves clinical outcomes at mid-term follow-up. *J Clin Orthop Trauma.* 2020;15:16-21.
3. Filardo G, Kon E, Perdisa F, Sessa A, Di Martino A, Busacca M, Zaffagnini S. Polyurethane-based cell-free scaffold for the treatment of painful partial meniscus loss. *Knee Surg Sports Traumatol Arthrosc.* 2017;25(2):459-467.
4. Monllau JC, Gelber PE, Abat F, Pelfort X, Abad R, Hinarejos P, Tey M. Outcome after partial medial meniscus substitution with the collagen meniscal implant at a minimum of 10 years' follow-up. *Arthroscopy.* 2011;27(7):933-943.
5. Monllau JC, Poggioli F, Erquicia J, Ramírez E, Pelfort X, Gelber P, Torres-Claramunt R. Magnetic Resonance Imaging and Functional Outcomes After a Polyurethane Meniscal Scaffold Implantation: Minimum 5-Year Follow-up. *Arthroscopy.* 2018;34(5):1621-1627.
6. Leroy A, Beaufils P, Faivre B, Steltzlen C, Boisrenoult P, Pujol N. Actifit® polyurethane meniscal scaffold: MRI and functional outcomes after a minimum follow-up of 5 years. *Orthop Traumatol Surg Res.* 2017;103(4):609-614.
7. Houck DA, Kraeutler MJ, Belk JW, McCarty EC, Bravman JT. Similar clinical outcomes following collagen or polyurethane meniscal scaffold implantation: a systematic review. *Knee Surg Sports Traumatol Arthrosc.* 2018;26(8):2259-2269.
8. Grassi A, Zaffagnini S, Marcheggiani Muccioli GM, Benzi A, Marcacci M. Clinical outcomes and complications of a collagen meniscus implant: a systematic review. *Int Orthop.* 2014;38(9):1945-1953.
9. Zaffagnini S, Marcheggiani Muccioli GM, Loporno N, Bruni D, Giordano G, Ravazzolo G, Molinari M, Marcacci M. Prospective long-term outcomes in the medial collagen meniscus implant versus partial medial meniscectomy: A minimum 10-year follow-up study. *Am J Sports Med* 2011;39:977-985.
10. Li W, Pan J, Li J, Guo J, Zeng C, Xie D. Clinical application of polyurethane meniscal scaffold: A meta-analysis. *J Orthop.* 2021;24:173-181.