

DOUBLE BUNDLE ACL RECONSTRUCTION Using Only the Semitendinosus



ALBERTO GOBBI, MD
*Orthopaedic Arthroscopic Surgery
International*
Via Amadeo G. A., 21–20133
Milano, Italy
Tel: +39027610310
Fax: +390270124931
E-mail: sportmd@tin.it

Due to recent studies suggesting the need for better rotational control than that provided by the conventional ACLR techniques currently used, renewed interest at the anatomic double bundle ACLR have prompted the orthopaedic community to take a second-look at the technique and its possible implications. Foremost among the concerns associated with the double bundle procedure is the technical expertise required to perform the technique properly. Moreover, surgeons have to contend or at least be wary of the reported incidence of hamstring weakness when using both the semitendinosus and gracilis tendons for this type of reconstruction. But basically, surgeons contemplating the use of a double bundle technique have to answer the same question: Is double bundle ACLR better than conventional reconstruction techniques available? At present, the answer may be more complicated than one would expect.

INTRODUCTION

Anatomical studies have demonstrated that the anterior cruciate ligament is composed of two functional bundles [anteromedial (AM) and posterolateral (PL)]^[1,2]. The nomenclature of these two bundles is related to their insertion in the tibial plateau. On the femoral side, these bundles have been demonstrated to lie on different coronal planes with the AM bundle originating more proximally than the PL bundle. Biomechanically during knee flexion, the AM bundle has been observed to tighten while the PL bundle slackens. On the contrary, during knee extension the PL bundle tightens while the AM bundle loosens^[3,15].

The majority of the reconstruction techniques basically reconstruct the anteromedial bundle of the cruciates as the femoral tunnel is placed between the 10 and 11 o'clock position for the right knee (or 1 and 2 o'clock position for the left knee). While good results have been generally demonstrated concurrent with its ability to restore the knee's AP stability, questions remain regarding its efficiency in restoring rotatory stability^[1]. Recently, the performance of an anatomic double bundle reconstruction technique has generated renewed interests as several in vitro analysis demonstrated better results in terms of restoring knee rotational stability^[4,5,6,2,7,8,9].

Performing an anatomic double bundle reconstruction usually entails the use of both the semitendinosus (ST) and Gracilis (G) autografts requiring the use of independent femoral and tibial fixations^[10,11,2]. With this technique therefore, the surgery becomes more costly with the additional fixation required.

Moreover, with the use of both the STG, hamstring strength deficits in deep flexion and internal rotation can be a possible complication as have been demonstrated by previous studies^[12,5,6].

In the following technical note, we illustrate a modification of the anatomic double bundle technique using a single semitendinosus autograft with independent femoral but single tibial fixation system. This double bundle single tendon (DBST) technique enables the surgeon to achieve an anatomic reconstruction without compromising the hamstring function while at the same time avoids the use of additional fixations limiting the cost of the surgery.

SURGICAL TECHNIQUE

Following the administration of anesthesia, the patient is positioned supine on the operating table. A tourniquet is placed at the proximal aspect of the thigh with sufficient distance from the expected exit point of the beath needle in the thigh's lateral aspect. A lateral post for thigh support and a foot bar are then placed to enable the knee to be positioned at 90° flexion on the table during surgery. This set-up also allows sufficient provision for full range of motion.

Once standard prepping and draping are completed, the tourniquet is inflated to 300 mmHg. A 3 cm vertical incision is then made centered approximately 5 cm below the medial joint line, midway between the tibial tubercle (Gerdy's tubercle) and the posteromedial aspect of the tibia. The sartorial fascia is incised and the semitendinosus tendon is dissected. The tendon is completely detached from its proximal attachment with an open tendon stripper. On its tibial end, the tendon's length is maximized preserving as much length as possible by detaching the ST close to the bone. Ideally, a length of > 28 cm. is desired.

At the back table, while the surgeon prepares the tunnels, the surgical assistant proceeds with the preparation of the double bundle graft. Once the graft is cleaned and devoid of excess tissues, measurement of the tendon follows. The minimum length needed is 28 cm. to allow the possibility of cutting the graft in half with sufficient length to fold each half of the graft to a length of 7 cm. In such way, we can have 2 cm. graft length for the femoral and tibial tunnels and 3 cm. intra-articularly. The ends of the grafts are then whipstitched using Ticron 5 sutures. The appropriate sizes of the EndoButton® CL (Smith & Nephew Endoscopy, Andover, Massachusetts) as determined by the AM and PL tunnel lengths are then attached

DOUBLE BUNDLE ACL RECONSTRUCTION

Using Only the Semitendinosus *(cont.)*

at the end of each graft. The diameter of each bundle is then measured using 0.5 mm increment sizers to match with the size of the femoral and tibial tunnels. Pretensioning and preconditioning of the grafts with cyclic flexion and extension of the knee under maximum manual tension follows [13,14].

Using standard anterolateral and anteromedial portals, the knee joint is visualized and prepared for tunnel placements. The anatomic footprints of the native ACL on both the femoral and tibial sides are identified. The PL femoral tunnel is initially prepared using an "outside-in" technique. To properly achieve this step, a customized Posterolateral (PL) tunnel guide is used (Shino K. Japan). This customized guide has a component arm designed to reach either the 9 o'clock or the 3 o'clock position. The arm of the PL guide is inserted in the antero-lateral portal and positioned at either 9 o'clock or 3 o'clock on the medial wall of the lateral condyle while the handle is maneuvered at the area of the junction of the distal femur and lateral condyle to fix the entry point for the tunnel. A guide wire is inserted from outside which is followed by a 4.5 mm cannulated drill to prepare the pilot hole. Once the length of this hole is measured, a 6 mm PL tunnel with its appropriate depth is drilled. Preparation of the 7 mm AM tunnel follows, using standard techniques with the tunnel placed at the either the 11 o'clock or 1 o'clock position. At the end of this step, we have two divergent tunnels positioned anatomically.




Figure 1a: The PL bundle demonstrated here with the attached endobutton CL is initially inserted

Figure 1b: The AM bundle is then inserted. Both bundles are checked if they are properly anchored against the cortical surface of the femur

The tibial tunnels are prepared at an angle of 45° with the entry point separated by a distance of 1 – 1.5 cms. These tunnels converge on the ACL's footprint intraarticularly.

With the tunnels ready, the PL bundle is positioned first followed by the AM bundle (Fig 1a & 1b). Once in place, the femoral fixation is double checked to determine if the endobuttons are securely anchored against the cortex.(Fig 2)

On the other hand, the tibial end of the graft is fixed using a single screw-post construct with the AM bundle secured at 40°- 60° of flexion and the PL bundle fixed at full extension.

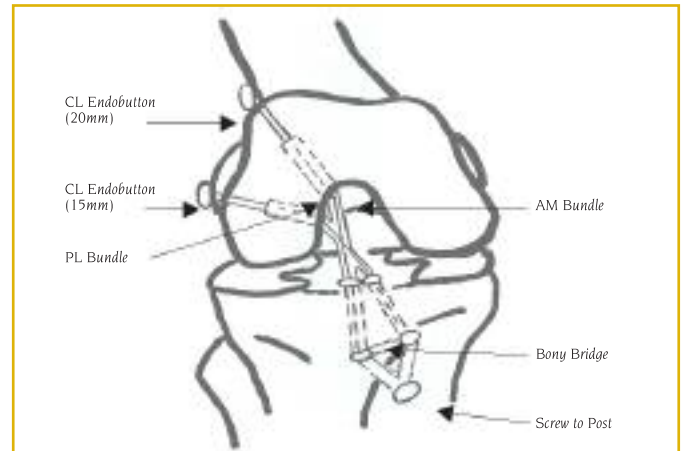


Figure 2a & 2b: AP and lateral post-operative radiographs are taken to check the position of the grafts

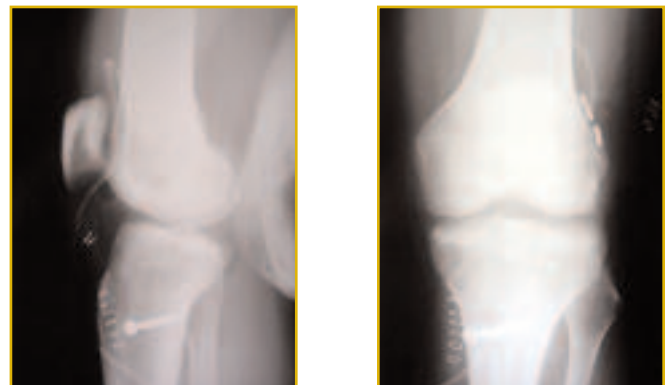


Figure 3a & 3b: Immediate post op. Xray showing the tunnels, femoral and tibial graft fixation

The graft is then checked for impingement and the knee examined for range of motion and stability with the lachman's test. The graft's position is confirmed with the post-op radiographs (Fig 3a & 3b). Postoperatively, a standard rehabilitation regimen is commenced.

DISCUSSION

The anterior cruciate ligament (ACL) plays a crucial role in maintaining the anteroposterior and rotational stability of the knee joint. Because of recent investigations indicating that conventional ACL reconstruction procedures only provide sufficient AP and inadequate rotational stability, renewed interest on the performance of an anatomic reconstruction technique has been generated. Biomechanical and in vitro investigations reveal that anatomical reconstruction can result to an anterior tibial translation that is significantly closer to that of an intact knee and produces better rotatory stability than

DOUBLE BUNDLE ACL RECONSTRUCTION

Using Only the Semitendinosus (cont.)

conventional single bundle ACL procedures [10,11,15,7,16]. These findings are consistent with the results of Tashman et al [2] which demonstrated that single bundle reconstruction sufficiently restores AP tibial translation but fails to provide rotational stability during dynamic loading.

The DBST (double bundle, single tendon) technique described here offers the possibility of reconstructing both the AM and PL bundles without sacrificing the functional integrity of the hamstring muscles by preserving the gracilis avoiding deep flexion and internal rotation strength deficit and preserving an active protection for further ACL injuries. Furthermore, the single fixation system at the tibial side achieves adequate fixation at the prescribed flexion angles for each bundle with less cost for the patient.

The authors recognize that the performance of an anatomic double bundle reconstruction is technically demanding and entails an additional cost for the surgery. Therefore, it is recommended that surgeons carefully select the patients for this procedure.

CONCLUSIONS

The DBST technique enables an anatomic reconstruction which preserves the gracilis minimizing the hamstring strength deficits. The single tibial fixation system offers a stable fixation achieved the prescribed angle demanded by each bundle. Further biomechanical and clinical investigations are necessary to validate the outcome for this technique.

ACKNOWLEDGEMENT

Ramces Francisco, MD – for the invaluable help in developing this technique.

REFERENCES

1. Radford WJ, Amis AA. Biomechanics of a Double Prosthetic Ligament in the Anterior Cruciate Ligament. *J Bone Joint Surg Br* 1990; 72: 1038-1043
2. Tashman S, Colon D, Anderson K, et al. Abnormal rotational knee motion during running after anterior cruciate ligament reconstruction. *Am J Sports Med* 2004 Jun;32(4):975-83
3. Mae T, Shino K, Matsumoto N, et al. Force sharing between two grafts in the anatomical two bundle anterior cruciate ligament reconstruction. *Knee Surg Sports Traumatol Arthroscop* 2006 Jan 6;:1-5
4. Adachi N, Ochi M, Uchico Y, et al. Reconstruction of the anterior cruciate ligament: single versus double multistranded hamstring tendons. *J Bone Joint Surg Br* 2004, 515-220
5. Gobbi A, Francisco R. Anatomic Double Bundle ACL Reconstruction with the Semitendinosus Tendon. *MME AAOS Annual Meeting* 2006, Chicago, USA
6. Makihara Y, Nishino A, Fukubayashi T, et al. Decrease of Knee flexion torque in patients with ACL reconstruction: combined analysis of the architecture and function of the knee flexor Muscles. *Knee Surg Sports Traumatol Arthrosc.* 2005 Oct (e pub)
7. Yagi M, Wong E, Kanamori A, et al. Biomechanical Analysis of an Anatomic Anterior Cruciate Ligament Reconstruction. *Am J Sports Med* 2000; 28:660-666
8. Yasuda K, Koga H, Morito T, et al. A Retrospective Study of the midterm outcome of Two Bundle Anterior Cruciate Ligament Reconstruction using Quadrupled semitendinosus tendon In comparison with One Bundle reconstruction. *Arthroscopy* 2006; 22(3):252-258
9. Yasuda K, Kondo E, Ichiyama H, et al. Clinical evaluation of anatomic double bundle anterior cruciate ligament reconstruction procedure using hamstring tendon grafts: Comparison among 3 different procedures. *Arthroscopy* 2006;22(3):240-251
10. Hamada M, Shino K, Horibe S, et al. Single versus Bi-socket anterior cruciate ligaments reconstruction using autogenous multiple-stranded hamstring tendons with endobutton femoral fixation: A prospective study. *Arthroscopy* 2001; 17:801-807
11. Muneta T, Sekiya I, Yagshita K, et al. Two Bundle Reconstruction of the Anterior Cruciate ligament Using Semitendinosus Tendon with Endobutton: Operative Technique and Preliminary Results. *Arthroscopy* 1999; 15: 618-624
12. Gobbi A, Domzalski K, Pascual J, et al. Hamstring anterior cruciate ligament reconstruction Is it Necessary to sacrifice the gracilis? *Arthroscopy.* 2005 Mar; 21(3): 275-80
13. Chen L, Cooley V, Rosenberg T. ACL Reconstruction with hamstring Tendon. *Orthop Clin Am* 2003 Jan;34(1):9-18
14. Gobbi A, Mahajan S, Tuy B, et al. Hamstring graft tibial fixation: biomechanical of different linkage systems. *Knee Surg sports Traumatol Arthroscop.* 2002 Nov; 10(6):330-4
15. Woo S. News in Biomechanics Research on ACL. 8th International Conf on Ortho
16. Biomechanics and Sports Rehabilitation. Nov 19-21, 2004. Assisi, Italy
17. Yamamoto Y, Hsu W H, Woo SL Y, et al. Knee Stability and Graft Function After Anterior Cruciate Ligament Reconstruction. *Am J Sports Med* 2004; 32:1825-1832