

ISAKOS

ISAKOS NEWSLETTER 2016 • VOLUME I

Current Concepts on Arthroscopy, Knee Surgery & Orthopaedic Sports Medicine



- INSIDE**
- 3** 2017 CONGRESS - SHANGHAI, CHINA
 - 8** PEARLS & PITFALLS: HIP PRESERVATION
 - 19** GENETICS AND PATHOGENESIS OF ROTATOR CUFF HEALING
 - 29** TEACHING CENTER SCHOLARSHIP REPORTS



in this issue

Editor's Message	1
President's Message	2
2017 Congress, Shanghai, China	3
Pearls & Pitfalls – Surgical Technique	8
Current Concepts	14
Teaching Center Scholarship Reports	29
Approved Course Reports	32
Fellowship Report	34
Upcoming Approved Courses	35

EDITOR

Robert Marx, MD, MSc, FRCSC UNITED STATES

EDITORIAL BOARD

Benno Ejnisman, MD BRAZIL
Iftach Hetsroni, MD ISRAEL
Christophe H. Hulet, MD, Prof. FRANCE
Bruce A. Levy, MD UNITED STATES
Stephen L. Lyman, PhD UNITED STATES
Tatsuo Mae, MD, PhD JAPAN
David Sadigursky, MD, MSc BRAZIL
Luis Alberto Vargas, MD, PhD UNITED STATES
Daniel Whelan, MD, MSc, FRCSC CANADA
Omer Mei-Dan, MD UNITED STATES, Past Editor



**International Society of
Arthroscopy, Knee Surgery and
Orthopaedic Sports Medicine**

2410 Camino Ramon, Suite 215
San Ramon, CA 94583 – 4318 USA
Telephone: +1 925 807 – 1197
Fax: +1 925 807 – 1199
Email: isakos@isakos.com

ISAKOS By the Numbers

The International Society of Arthroscopy, Knee Surgery and Orthopaedic Sports Medicine continues our 20th Anniversary Celebration! ISAKOS was formed in 1995 by the merger of the International Arthroscopy Association (IAA) and the International Society of the Knee (ISK) at the IAA & ISK Combined Congress in Hong Kong. ISAKOS will return to our roots in 2017 for the 11th Biennial ISAKOS Congress in Shanghai, China.

ISAKOS was established *to advance the worldwide exchange and dissemination of education, research and patient care in arthroscopy, knee surgery and orthopaedic sports medicine*. This continues to be evident in our diverse membership committed to education and patient care.

ISAKOS recently had the opportunity to survey our members about their thoughts about ISAKOS. ISAKOS membership ranges from those members under 30 to those over 70, with a majority (35%) averaging between 51 and 60 years of age. ISAKOS currently has 3,029 members from 93 different countries. When polled, members stated that their primary reasons for joining ISAKOS were expanding their expertise to become a better professional; gaining global scientific knowledge, learning from global educational offerings and because ISAKOS is a premier global group within the specialties of arthroscopy, knee surgery and sports medicine.

ISAKOS' global perspective is most evident at the ISAKOS Congress. Our 11th Biennial ISAKOS Congress will be held in the global city of Shanghai, China. More information on the ISAKOS Congress can be found on page 3 of this Newsletter, and also in the recently released ISAKOS Congress Preliminary Program + Call for Abstracts – www.isakos.com/2017. Our Congress faculty includes more than 250 surgeons from 40 different countries. A variety of educational opportunities will be available ranging from live surgical demonstrations, instructional courses, symposia, debates, lectures, and scientific papers.

If you are interested in participating in the Scientific Program, make sure to submit your abstract by September 1, 2016! Abstract submissions and award applications can be completed online at www.isakos.com/2017congress.



ISAKOS would like to recognize past-President Dr. John Bergfeld on his appointment as an Honorary Member of the Spanish Knee Society. We apologize for the omission in the ISAKOS Newsletter 2015: Volume II



ISAKOS is on the MOVE!

I recently had the pleasure to participate in the ISAKOS Committee meetings, held preceding the AAOS Annual Meeting in Orlando, Florida. These meetings represent one of the few in-person meetings held by the ISAKOS Committees during their two-year committee term. ISAKOS sincerely appreciates the effort of our committee members to attend these meetings and provide their expert input into upcoming ISAKOS Committee Activities.

As you can see from this issue of the ISAKOS Newsletter, our committees are our greatest resource! ISAKOS Committees include more than 240 unique ISAKOS Members from 43 different countries! Under the leadership of ISAKOS President, Dr. Philippe Neyret, the ISAKOS Committees have undergone a reorganization in the last year, including the division and creation of more specific clinical committees. These new committees include Elbow, Wrist & Hand, Hip, Groin & Thigh, Knee: Arthroplasty & Alternatives, Knee: Sports & Preservation, Leg, Ankle & Foot, Scientific, Shoulder and Sports Medicine Committees. These committees are hard at work on behalf of the ISAKOS membership, and have many exciting projects to announce over the coming months. For more on the committee work and their specialties, please see the Current Concepts section of this Newsletter on page 14.

Easily one of the most exciting things to come out of the AAOS Meeting was the successful launch of *Journal of ISAKOS*! *JISAKOS* is a new hallmark of our society, helmed by Prof. C. Niek van Dijk. *JISAKOS* is intended to advance the worldwide dissemination of knowledge and research in orthopaedic sports medicine and traumatology, arthroscopy, knee surgery, and degenerative joint disease, with the ultimate goal of improving the quality of life for our patients. Our goal is to provide an authentically global perspective to orthopaedic surgeons and related professionals; and reflect diverse patient populations, healthcare systems, and clinical preferences.

JISAKOS is a new and exciting member benefit, and will be published bimonthly in print and online. Each issue will include systematic reviews and state-of-the-art articles, dealing primarily with surgical and/or non-surgical interventions in the journal's key fields of interest, as well as papers called "The Classic" will provide a historical perspective of a major concept or technique. I encourage you to read the first "Classic" focusing on the early work of William Clancy.

With the work of AAOS behind us, ISAKOS and our members can turn our focus to the ISAKOS Congress! The Committees have already contributed greatly to the ISAKOS Congress—more than 125 suggestions were made for Symposia and Instructional Course Lectures for the 2017 ISAKOS Congress! Dr. Julian Feller and Dr. Stefano Zaffagnini have done a fantastic job developing an exciting scientific program from these suggestions. Have you seen the ISAKOS Congress Call for Abstracts & Preliminary Program yet? It's available online at www.isakos.com/2017Congress. Seven different abstract based awards are available, as well as three different fellowship opportunities. I encourage you to not delay and submit your ISAKOS Congress abstract before the September 1, 2016 deadline! More information on the 2017 ISAKOS Congress can be found on page 4.

ISAKOS is gearing up for an exciting 2016 and whirlwind 2017—we hope you enjoy the journey and we look forward to seeing you in Shanghai!

Robert G. Marx, MD, MSc, FRCSC UNITED STATES

ISAKOS Newsletter Editor 2015–2017



Dissemination of Education All Around the World

The last ISAKOS Congress in Lyon welcomed participants from all around the world – more than 4,000 participants from 95 different countries to be exact! This shows the importance of ISAKOS' mission to promote the *worldwide exchange and dissemination of education, research and patient care in arthroscopy, knee surgery and orthopaedic sports medicine*.

To achieve this goal outside of the ISAKOS Congress, ISAKOS has been pleased to collaborate with Regional and National societies who share similar goals. Such efforts already in 2016 have included the “Challenges in Football Injuries” meeting co-sponsored by ISAKOS, Aspetar and the FIFA Medical Committee, held February 11-12, 2016 in Doha, Qatar; the 13th Meeting of the Combined Orthopaedic Associations (COMOC) held April 11-15, 2016 in Cape Town, South Africa; and the Combined 3rd ISAKOS Knee Course & 6th Pune Knee Course, held April 22-23, 2016 in Pune, India. Future collaborations will include AMECRA, SLARD, and ESSKA – we encourage you to check the ISAKOS Homepage for collaborative courses to be held in your geographic area. ISAKOS continues to meet regularly with the leadership of various international, regional and national societies to develop collaborations.

ISAKOS also encourages member education through our online education! As a member of ISAKOS, do you know you have access to the following benefits:

- **Free access to the NEW *Journal of ISAKOS*, including a mailed subscription**
- Mailed subscription to *Arthroscopy: The Journal of Arthroscopic and Related Surgery*
- Access to Global Link: ISAKOS Online Education Portal – now featuring NEW surgical demonstration videos!
- Subscription to the ISAKOS Biannual Newsletter
- Optional subscription to *KSSTA*, the official Journal of ESSKA
- Online access to unique articles and reports provided by OrthoEvidence
- Access to myISAKOS including ISAKOS publications, ISAKOS Committee projects, Congress archives and more
- Opportunity to participate in ISAKOS approved teaching centers and approved courses

Following the recent ISAKOS Strategic Retreat, held prior to the American Academy of Orthopaedic Surgeons Annual Meeting, it is clear that Education will continue to be ISAKOS' focus looking forward. Our new, five-year Strategic Plan reflects this as ISAKOS pledges to:

- Enhance ISAKOS member expertise and experience
- Enhance ISAKOS presence in the profession
- Enhance ISAKOS efficiencies and productivity
- Support ISAKOS research
- Ensure the future leadership of the society

ISAKOS will be seeking to enhance the above listed educational benefits to improve the experience of our members. The ISAKOS Clinical Committees are a wonderful resource and will be carefully reviewing content such as the ISAKOS Global Link to maximize member experience and address learning gaps. More information on the ISAKOS Strategic Plan implementation will be sent in the coming months!

There are many possibilities for members to support and contribute to ISAKOS! We appreciate the unique contribution each member gives to ISAKOS, whether that is through submitting an Abstract for the ISAKOS Congress (available through September 1, 2016!), serving on an ISAKOS Committee, or making a financial donation as an ISAKOS Godfather. We view our members as family and thank you for your participation! You are each part of the DNA of ISAKOS, our mission and identity.

Philippe Neyret, MD, FRANCE

ISAKOS President 2015–2017



2017

11TH BIENNIAL

ISAKOS CONGRESS

JUNE 4-8, 2017 | SHANGHAI, CHINA





On behalf of the entire ISAKOS Program Committee and Board of Directors, I would like to cordially invite you to attend the 11th Biennial ISAKOS Congress. The 11th Biennial ISAKOS Congress will be held in Shanghai, China on June 4–8, 2017.

The 11th Biennial ISAKOS Congress will focus on discussions of new initiatives in medicine and technology as they relate to arthroscopy, knee surgery and orthopaedic sports medicine. Participants will be able to evaluate clinical cases and advance the practice of evidence-based, informed orthopaedic care. Our more than 300 international faculty will demonstrate the application of current techniques, procedures and research, as well as identify and analyze current research data pertaining to the management of ankle, foot, knee, hip, wrist, elbow and shoulder problems, and to sports medicine. ISAKOS will also present live cadaveric surgical demonstrations from international leading faculty.

Known for our broad perspective, the ISAKOS Congress is a unique opportunity to learn from a diverse faculty. Past Congresses have included faculty from nearly every continent, and the 2017 Congress will strive to strike a balance between Eastern and Western perspectives.

Unique opportunities will be available at the Congress in Shanghai, including six different pre-courses! These pre-courses will be held on Saturday, June 3rd and will range in topic from the use of Biologics in Sports Medicine, to Knee Arthroplasty. Registrants will have the ability to pay one registration fee and attend any of the six pre-course sessions offered. More information on the pre-courses can be found in this Newsletter on Page 7.

The ISAKOS Congress currently seeks abstract submissions. Abstract submissions are accepted for Scientific Paper or e-Poster presentation, and must be submitted online through the ISAKOS website by September 1, 2016. Also available are a variety of ISAKOS Awards and Traveling Fellowships – for more information, please visit www.isakos.com/awards.

The city of Shanghai is known as a showpiece of modern China. A popular tourist destination, Shanghai features such historical landmarks as The Bund, City God Temple and Yu Garden. Other cultural highlights include the Shanghai Museum and the China Art Museum. Shanghai is well recognized for its extensive Lujiazui skyline featuring many skyscrapers. A variety of social events will be offered including a Welcome Reception, a spouse and guest program and tour assistance.

You are a vital part of the 11th Biennial ISAKOS Congress! We hope you will plan to participate in the international experience that is the ISAKOS Congress.

Julian A. Feller, FRACS AUSTRALIA

ISAKOS Program Chair 2015–2017

SPORTS PHYSICIAN CONCURRENT COURSE: CURRENT SITUATION FOR TEAM PHYSICIANS*

SUNDAY, JUNE 4 –
MONDAY, JUNE 5, 2017

Course Chairs:

Liu Yu Jie, Prof. CHINA
Shiyi Chen, MD, PhD CHINA
Jiang Chun Yan, Prof. CHINA
Simon Yeung, Prof. CHINA

The Sports Physician Course will feature topics related to rehabilitation and sports medicine from a non-surgical procedure. Topics will include general information about sports injuries, topics relevant to the athletic trainer, bracing, taping, and rehabilitation. Participants will be able to understand the state of the art of concept and practice in Sports Medicine, especially the timing of evaluation and early stage intervention.

***Please note: This Course will be presented in Chinese only. Translation will not be available.**

JOIN US IN SHANGHAI



The enormous metropolis of Shanghai is a city of changes. Melding old with new, Shanghai is the most populous city in China, with more than 23 million residents. Shanghai is a wonderful host city for ISAKOS, as more than 9 million of the 23 million residents of the city are from outside of China!

A fascinating mix of East and West, the city of Shanghai has a wide diversity of architecture, ranging from the historic shikumen (石库门) houses that blend the styles of Chinese houses with European designs, to one of the richest collections of Art Deco buildings in the world. The city has a distinctly cosmopolitan feel with Parisian, Tudor and 1930s New York or Chicago style buildings.

Shanghai is one of China's primary industrial hubs, with a stated goal to become a financial and economic center of China and Asia. Shanghai is also home to one of the world's most prolific skylines, and will be home to the second tallest building in the world – the Shanghai Tower.



Shanghai is marked by a humid and subtropical climate. The month of June will bring Shanghai's wettest month, with estimated highs around 35°C (95°F), and monthly rainfall totals above 170mm or 6.5 inches.

Shanghai is a good city for walking, especially in the older parts of the city such as The Bund, but tourists are cautioned to be aware that "right of way" is proportional to the size of the individual. Vehicles trump motorbikes, which trump pedestrians! Motorbikes and bicycles rarely use headlights and can come from any direction.

Particular points of cultural interest include Yuyuan Gardens (豫园) (in Old City), which is full of classical Chinese architecture. For a taste of 1920s Shanghai, head for the stately old buildings of the The Bund or the French Concession – this area is becoming known for boutique shopping and fantastic restaurants! For art aficionados – the Shanghai Museum (上海博物馆) has an impressive Ancient Bronze exhibit, as well as other traditional art offerings. Zhujiajiao Water Town (朱家角镇) is known as the Venice of Asia. This more than 400-year-old classic, water village is home to a five-arch bridge spanning the Cao Gang River. The city is located about 40 minutes from downtown Shanghai, but is home to quaint shops and restaurants serving local favorites. Visitors can stroll the maze of paths and bridges, and take a boat ride to view the residences of this nicely-preserved water village.

Chinese shoppers account for more than 47% of the global luxury goods market around the world, so Shanghai is a wonderful city for shopping! Shanghai's premier shopping street is Nanjing Road (南京东路), or visitors can visit the Yuyuan Bazaar for Chinese crafts and jewelry, not far from The Bund. For those interested in boutique shopping, head to the French Concession Streets Xinle Lu (新乐路), Changle Lu (长乐路) and Anfu Lu (安福路), starting from east of Shaanxi Lu (陕西路). This section of the city features tree-lined streets with small boutiques of clothing and accessories, where young Shanghainese looking for the latest fashions shop.

Shanghai's cuisine, like its people and culture, is primarily a fusion of the forms of the surrounding Jiangnan region, with influences sprinkled in more recently from the rest of China and the international community. Shanghainese cuisine, and authentic Shanghai cuisine, primarily features fresh ingredients, bright colors, and original flavors. Boiled eel (锅烧河鳗), three yellow chicken (三黄鸡), fried shrimp (油爆河虾), and Shanghai drunk crab (上海醉蟹) are the common Shanghainese dishes. Another common dish are small steamed buns called xiǎo lóngbāo (小笼包), and are full of tasty (and boiling hot!) broth inside with a dab of meat.

We hope you will join ISAKOS in Shanghai to experience this wonderful and worldly city!

2017

11TH BIENNIAL

ISAKOS CONGRESS

JUNE 4-8, 2017 | SHANGHAI, CHINA

CALL FOR ABSTRACTS

ONLINE ABSTRACT SUBMISSION INSTRUCTIONS

- 1** Log-in using the Presenting Author's email and password for ISAKOS (if a record does not exist for the Presenting Author you will be directed to create a record).
- 2** Complete contact information for the Presenting and Corresponding authors, including the institution of research. It would also help to have the ISAKOS ID number for as many authors as possible. If needed, you may contact the ISAKOS Office at isakos@isakos.com to obtain an author's ISAKOS ID number—please do not make duplicate records.
- 3** Provide the abstract title in proper case for publishing.
- 4** Submit the plain abstract text into the provided text box within the online application. Please note, graphics and tables are not accepted.
- 5** Complete the Financial Disclosure Statement, American Food and Drug Administration (FDA) Statement, and Copyright License Agreement, on behalf of all authors.
- 6** Author Warranty: Authors must read and abide by the Abstract Submission Guidelines in order to be considered for presentation.

APPLY FOR AWARDS & FELLOWSHIPS!

- John Joyce Award
- Richard B. Caspari Award
- Scientific Research Award
- Albert Trillat Young Investigator's Award
- Achilles Orthopaedic Sports Medicine Research Award
- Patellofemoral Research Excellence Award
- Gary G. Poehling Award
- The Upper Extremity Traveling Fellowship
- The Patellofemoral Traveling Fellowship
- The Masaki Watanabe Arthroscopy Traveling Fellowship

isakos.com/awards



ABSTRACT SUBMISSION DEADLINE
SEPTEMBER 1, 2016

isakos.com/2017congress

Pre-Courses Saturday, June 3, 2017

MORNING COURSES

The Knee: Maximizing Surgical Procedures in the Active and Athletic Patient

Chairs: Elizabeth A. Arendt, MD UNITED STATES
Mark Clatworthy, FRACS NEW ZEALAND
Christopher J. Vertullo, MBBS, FRACS (Orth),
FAOrthA AUSTRALIA

This pre-course is targeted to the orthopaedic surgeon whose practice centers on the young and the aging sports knee. It will present the latest knowledge and surgical techniques relevant to the management of knee pathology, focusing on surgical knowledge and technique. The course will be suitable for the subspecialist knee surgeon as well as the general orthopaedic surgeon desiring an update on controversies and techniques within the athletic and the aging knee.

The morning will consist of a series of expert and evidence-based lectures combined with case examples querying the experts on difficult problems with diverse and at times controversial solutions. Key cadaveric surgical demonstrations are embedded within each topic. An interactive audience response system has enhanced audience participation and has augmented audience education. Following this course, the participant will be well-versed in the approach to the injured athletic knee, with improved knowledge in its management.

The IOC Prevention of Injuries and Illnesses in High Level Athletes

Chairs: Lars Engebretsen, MD, PhD. NORWAY
Gino M.M.J. Kerkhoffs, MD, PhD, Prof. NETHERLANDS

Upon completion of this pre-course, participants will be able to understand the principles of injury and illness prevention. Practical examples will translate the principles into practical programs on Olympic athletes.

Current Concepts in Shoulder Surgeries: New Insights INTO Instability, Rotator Cuff Repair and Minimally Invasive Humeral Fracture Fixation

Chairs: Andreas B. Imhoff, MD, Prof. GERMANY
Felix "Buddy" Savoie III, MD UNITED STATES

This course will present the latest techniques in shoulder stabilization like Latarjet – the French and US experience, and also new insights into rotator cuff repair (tendon to bone healing and superior capsule reconstruction) and minimally invasive humeral fracture fixation. Each presentation will be moderated separately as a cross-fire to involve the attending members.

AFTERNOON COURSES

Advanced Course on Knee Arthroplasty

Chairs: Sebastian Lustig, MD, PhD, Prof. FRANCE
Shuichi Matsuda, MD, PhD JAPAN
Willem Mare van der Merwe, MBChB, FCS, SA Ortho
SOUTH AFRICA

This pre-course will provide a comprehensive update and overview of the latest knowledge and techniques relevant to knee arthroplasty for the orthopaedic surgeon. The topics will include basic concepts and surgical technique of cruciate-retaining and cruciate-sacrificed total knee arthroplasty, as well as unicompartmental knee arthroplasty. Focusing on management for severe varus or valgus deformity, instability, contracture, bone defect, and intraoperative trouble shooting. We have assembled an international faculty, including experts from around the world, presenting on their areas of expertise.

This half-day course will consist of a series of expert and evidence-based lectures. In addition to the lectures there will be panel discussions, particularly on controversial topics such as kinematic alignment. This pre-course will present a variety of surgical techniques, involving video demonstrations, as well as pearls and pitfalls, and discussions for each topic. Following this course, participants will be able to understand how to treat more difficult cases such as severe varus or valgus deformity by total knee arthroplasty.

The Use of Biologics to Treat Sports Medicine Pathology

Chairs: Johnny Huard, PhD UNITED STATES
Robert F. LaPrade, MD, PhD UNITED STATES
Nicola Maffulli, MD, PhD, MS, FRCS(Orth)
UNITED KINGDOM

The course aims to provide a clinical-based overview on the scientific basis for the use of biologics to treat orthopaedic sports medicine pathology. The various treatment options available, including growth factors, platelet rich plasma, and stem cells will be presented, and the basic science rationale behind their use clarified. Their clinical use will be presented, the regulatory issues related to their use, and the evidence on their effectiveness and efficacy will be discussed.

Evaluating Athletes with Hip and Groin Problems: From Symptoms to Diagnosis and Treatment

Chairs: Per Holmich, Prof., DMSc DENMARK
Nick Mohtadi, MD, MSc, FRCSC CANADA
Alston J. Stubbs, MD UNITED STATES

At the completion of this course, participants will be able to understand the presenting complaints, symptoms and patient-reported outcome information. Participants will be able to confirm the common diagnoses in athletes presenting with a hip and groin problem. Participants will be able to understand the role of non-surgical and surgical treatment of common groin and hip conditions.

Hip Preservation



Omer Mei-Dan, MD
Associate Professor
Hip Preservation Center
University of Colorado
Denver/Boulder, CO UNITED STATES

The Concept

Labral tears are a significant cause of hip pain, and are currently the most common indication for hip arthroscopy. Compared to labral debridement, labral repair has significantly better outcomes in both daily activities, as well as athletic pursuits, in the setting of femoral acetabular impingement (FAI).

Previously described repair techniques all utilize anchor placement on the capsular aspect of the acetabular rim and labrum, a position that is not always ideal and has the potential for significant complications, especially anteriorly where the rim is very thin. A shallow dysplastic hip, drilling trajectory, narrow width of the acetabular rim or some specific anatomic variations may generate difficulty during this commonly utilized anchor placement. Anchor breakage, anchor slippage into the surrounding (capsular side, IP bursa) soft tissue or penetration of the cartilage surface are among the most common complications. Furthermore, anatomical anomalies do exist in the acetabular labrum, where the native labrum does not create an adequate suction seal with the femoral head, reducing even distribution of cushioning synovial fluid, and increasing the forces within the joint. In anatomical cases such as these, the superior deviation of the labrum would only be worsened by the direction of pull from sutures coming out of an anchor placed behind the labrum, displacing the labrum from the correct anatomical position that much further.

We describe an intra-articular anchor placement technique, which provides a means to repair a torn labrum when more standard approaches are less ideal. This technique can also assist in labral advancement (pulling the labrum towards the femoral head to create a more functional seal), when the native labrum fails to create a proper seal due to its location away from the femoral head.

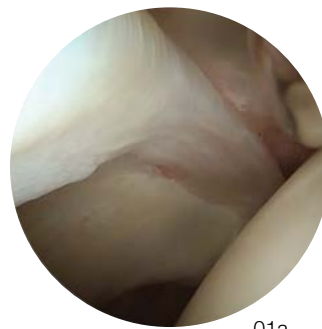Surgical Technique

If the patient is known to have dysplasia or does not have a pincer lesion which requires rim resection, they are good candidates for the 'inside-out' technique.

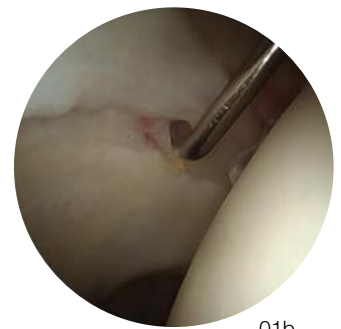Following debridement of the labral base tear the labrum is lifted slightly off the rim at the site the anchor will be placed, and manual gentle rasping is performed to facilitate revascularization for healing.

Drill guide is placed under the labrum (at the chondro-labral junction) ensuring ample bone in which the anchor can take hold. Either straight or angled guides can be used according to portal trajectory and repair's hour of the clock. Once the anchor (Nanotack, Stryker) has been secured, a labral base repair, or a repair with stitch around the labrum, can be performed. In order to complete a labral base repair, both suture limbs are retrieved through the labrum, in a vertical or horizontal mattress fashion, to the capsular side of the labrum using the arthroscopic suture passer (Nanopass, Stryker). Arthroscopic knot tying techniques are used to secure the labral repair.

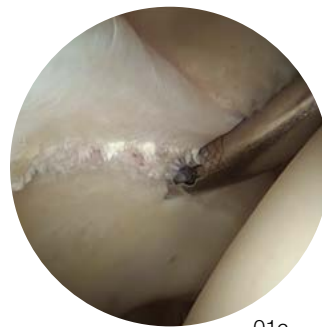In order to perform a labral advancement, the anchor is placed in the same fashion, but after the labrum is freed from its native attachment away from the chondrolabral junction. Once the labrum can be mobilized freely with a probe, it will be brought closer to the chondrolabral junction using the anchor suture limbs.



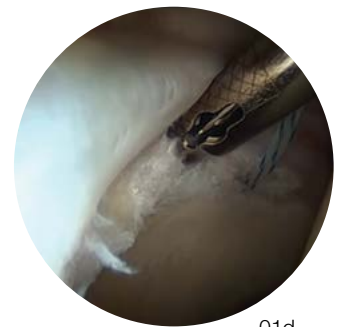01a



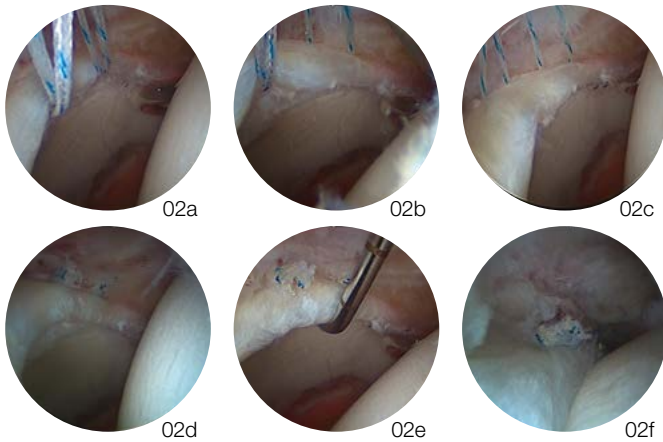
01b



01c



01d



Discussion

Current methodologies used to treat labral tears may be limited in their efficacy in some patients with hip dysplasia and would result in unnecessary capsule-labral detachment and rim exposure/roughening in patients whose acetabulum doesn't require acetabular rim trimming. The intra-articular placement of the 'inside-out' technique allows the surgeon to place the anchor in bone with ample substance while the anchor position allows the forces to pull the labrum inferiorly, instead of superiorly, helping to ensure a more natural anatomical function. Also, when performing a labral repair from the articular surface, the need to separate the capsule from the labrum, as well as to trim the rim, is eliminated. Philippon established that labral adhesions were the major factor necessitating revision hip arthroscopy. By implementing this method of repair, the risk of developing adhesions is minimized, thereby decreasing the need for potential revisions in the future.

In addition, in cases of anatomic variations, where the labrum does not create an adequate suction seal due to superior deviation of the labrum, the direction of pull from conventional anchor placement sutures would be unfavorable. Conventional repair could worsen the labrum anatomy, pulling it further from the correct anatomical position, thereby worsening the pathoanatomy. The 'inside-out' technique can restore the physiological suction seal while maintaining the native labrum.

The intra-articular anchor placement described here provides an alternative method for anchor placement, utilizing standard approaches and operative techniques, allowing for easier and faster repair. Lastly, further biomechanical and clinical studies need to be performed to validate this technique and to demonstrate safety.

- 01 The 'inside-out' technique is demonstrated on these arthroscopic pictures on a right hip in the supine position with the camera in the midtrochanteric portal and instrument in the anterior portal.
- 01 a/b. A probe is used to demonstrate the labral tear
- 01 c. The guide is placed and medial anchor is drilled
- 01 d. Lateral anchor is drilled
- 02 02 a. Both suture limbs are seen under the labrum
- 02 b. The first anchor suture limbs are passed through the base of the labrum
- 02 c. Both anchor suture limbs are seen through the base of the labrum
- 02 d-f. Stable labral repair is complete and show anatomical labral seal

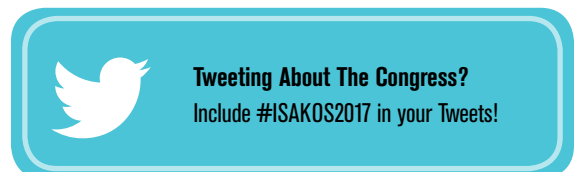
Join the ISAKOS Global Conversation!

Facebook.com/myISAKOS

@ISAKOS



Join the ISAKOS Group on LinkedIn



Combined Medial Patellofemoral Ligament and Medial Patellotibial Ligament Reconstruction in Children



David Sadigursky, MD
Orthopedic and
Traumatologic Clinic
COT Hospital Manoel
Victorino-Salvador, Bahia,
BRAZIL

Anatomical and biomechanical studies have shown that the Medial Patellofemoral Ligament (MPFL) is the main restrictor to the lateral translation of the patella. Numerous surgical techniques have been described in the literature for the reconstruction of the MPFL with favorable clinical outcomes. In addition to the MPFL, ligaments that contribute to the medial restriction of the patella are the Medial Patellotibial Ligament and the Medial Patellomeniscal one. The latter contribute to the restriction of the patella at angles above 30° of knee flexion. Philipot et al showed that the MPTL contribution increases in extension from 26% to 46% at 90° flexion. Besides contributing to patellar stability, the MPFL influences the tilt and the rotation of the patella. Hence, the reconstruction of the MPFL combined with the MPTL is important to maintain the normal kinematics of the patellofemoral joint throughout the range-of-motion. As found by the group of knee surgery of the University of São Paulo (IOT HC USP), the combined reconstruction with a secondary stabilizer (MPTL or MPML) could reduce stress on the rebuilt MPFL and thus increase the functional results and may be an attractive technique when the osteotomy of the Anterior Tibial Tuberosity (ATT) is not possible.

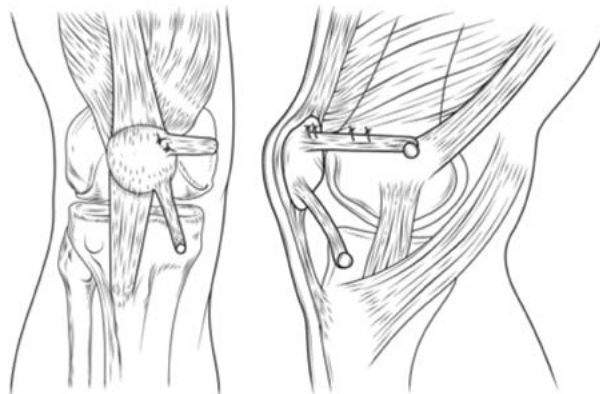
Various grafts have been demonstrated to be effective for the combined MPFL and MPTL reconstruction. Different ways of fixing these grafts have been described with favorable clinical outcomes, despite maintaining a rate of complications around 26.1% with both objective and subjective instability rates of 12%, according to the systematic review published by Shah et al in 2012.

In 1922, Galeazzi described a MPTL reconstruction technique in patients with open physis, in order to control the height of the patella in relation to the femoral condyle and transmit the contraction force from the quadriceps to the tibia. Giordano et al, in 2012, demonstrated the MPFL/MPTL combined reconstruction using the semitendinosus and gracilis tendons with a longitudinal bone tunnel on the patella and fixation on the femur with a metal anchor. The technique was indicated for skeletally immature patients with a high patella, trochlear dysplasia, increased TT-TG and ligamentous laxity.

Hinckel et al published the MPFL/MPTL combined reconstruction technique using the quadriceps tendon for MPFL and the patellar tendon for the reconstruction of MPTL, both from their medial portion and transferred to the anatomical points of both tibial and femoral insertions, with the aid of fluoroscopy (Fig. 1).

The authors developed the variation of the technique previously published by Giordano et al, using the semitendinosus tendon. The graft is fixed to the tibia, patella and femur with the use of metal anchors previously positioned in their respective anatomical landmarks, with the aid of fluoroscopy.

The combined reconstruction is indicated in the presence of patellar instability in skeletally immature patients with patella alta, increased TT-TG, trochlear dysplasia and ligamentous laxity, when techniques such as ATT osteotomy and trochleoplasty cannot be used. However, this procedure may not be needed after skeletal maturity when additional procedures such as ATT osteotomy, osteotomy for the correction of angular deviations of the lower limbs or trochleoplasty are indicated.



01

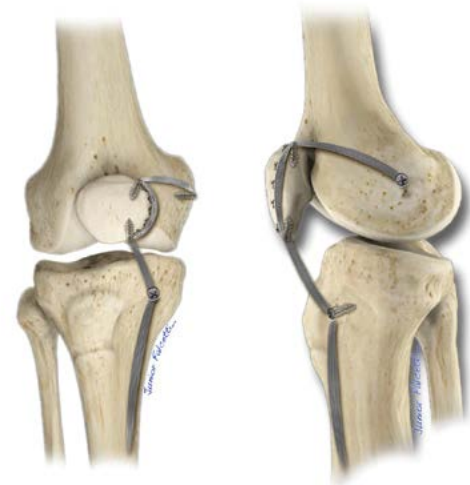
Surgical Technique

Firstly, the arthroscopic procedure is carried out and the articular cartilage, the menisci and ligaments are inspected. The surgical procedure is performed with three small incisions. The first incision is made at the proximal medial tibia in order to identify the insertion of pes anserinus tendons. The semitendinosus tendon is divided from the muscle-tendon junction, preserving the distal insertion site. The tendon must be at least 12-13 cm in length. The semitendinosus tendon was chosen for greater length and sufficient strength for the reconstruction. A second incision is performed at the medial border of the patella, including the landmark for the fixation of the graft. The last incision is made in the area between the adductor tubercle and the medial epicondyle with the aid of fluoroscopy for the identification of anatomical points of graft insertion.

After preparing the graft with sutures at its free end, a metal anchor is placed in the tibia with a small incision in the region of the medial patellofemoral ligament insertion, proximal to the physis, between the medial border of the patellar tendon and the superficial medial collateral ligament, forming an angle of approximately 20° with the patellar tendon, proximal to the physeal line. The graft is fixed at this point and then transferred percutaneously to the distal incision from the medial border of the patella, which is fixed with a metal anchor at 90° of knee flexion with tension similar to the one perceived in the patellar tendon, according to Hinckel et al. A third anchor is positioned on the patella, at the point between the middle and proximal thirds of the patella in its medial border. Then the graft is passed to the femur through the second layer of the medial retinaculum of the patella, and the fourth anchor is placed in the distal region to the physis, by means of fluoroscopy, according to the study by Schöttle et al, in the region between the medial epicondyle and the adductor tubercle, between 5mm and 6.4mm distal to the physis. Prior to the insertion of the anchor, the positioning must be checked in both planes, AP and true lateral. The graft is then secured with the knee between 45° and 60° flexion without excessive tension, reconstructing the medial patellofemoral ligament. The patella is tested during flexion-extension by observing its medium-lateral course, which should allow mobility between 25% and 50% of the patella without lateral displacement.

After confirming the stabilization of the patella and full range of motion with complete flexion-extension, the graft is enhanced with the suture at the periosteum of the patella between the suture anchors to increase the area of patellar insertion, according to its anatomical characteristics (Fig. 2 and 3).

After surgery, the patient remains with a removable immobilizer for three weeks. Physical therapy is started on the second day after surgery with isometric exercises for the quadriceps. The exercises for range-of-motion and quadriceps strengthening are encouraged progressively and as tolerated after the 30th day after surgery. The load without crutches is allowed when the patient is able to walk without a limp. One month after surgery, knee flexion of more than 90° should be achieved. Sports activities are restricted for 4–6 months.



02

- 01 Insertion and reconstruction of medial patellofemoral ligament with quadriceps tendon and of medial patellofemoral ligament with patellar tendon.
- 02 Reconstruction of the Medial Patellofemoral Ligament (MPFL) and the Medial Patellofemoral Ligament (MPTL) with the semitendinosus tendon.

Combined Medial Patellofemoral Ligament and Medial Patellotibial Ligament Reconstruction in Children

Discussion

The main advantage of the technique presented is the possibility of carrying out the ligament reconstruction in skeletally immature patients and with the presence of predisposing factors. With the combined reconstruction, it is possible to stabilize the patella without performing other procedures such as ATT osteotomy and trochleoplasty.

In skeletally immature patients, procedures for preserving the physis are recommended.

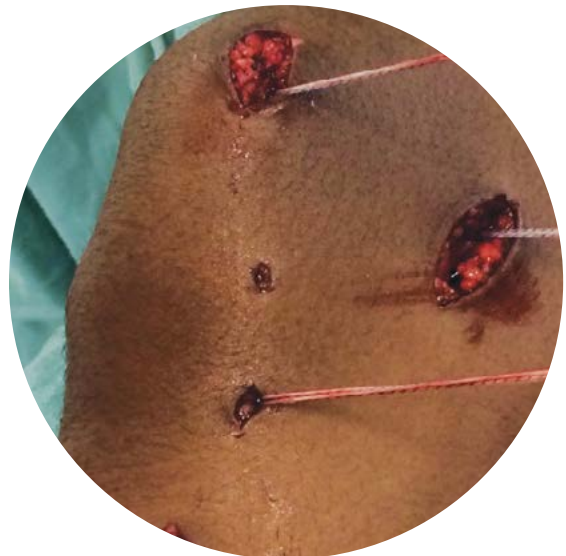For the fixation of the graft in the patella, tibia and femur, metal anchors were used due to their capacity to maintain the stability of the graft and eliminate the need for bone tunnels in the patella avoiding complications such as patella fracture and cartilage damage. The advantage of using anchors in the femur and tibia is the avoidance of drilling and bone tunnels near the physeal line, preventing injury. Kang et al demonstrated the effectiveness of using metal anchors for the reconstruction of the two bands of MPFL, with no evidence of failures or recurrence in the reconstruction. This technique allows for small and cosmetic incisions. After achieving skeletal maturity, patients should return for physical examination, as well as x-rays.

The fixation of the graft relative to the femoral distal physis remains controversial because of the publication of Shea et al in 2010, which demonstrated that the fixation point on the femur should be proximal to the physis. However, we fix the graft distal to the physis, inclined distally, slightly obliquely, to prevent the risk of perforation of the physis. We believe that the distal fixation to the physis is more reproducible with the use of fluoroscopy, as described by Kepler (2011), Ladd et al (2010) and Parikh et al (2013). When the fixation is positioned significantly distal to the physis, there is the possibility to overtension the patellofemoral joint in extension, which can be corrected by moving the point to an anterior position in the same proportion that it is placed distally.

In the tibia, the fixation of the graft at the proximal epiphysis instead of the tibial proximal metaphysis, avoids the risk of distal migration of the graft insertion with growth, which could cause a change in tension and function.

The reconstruction of MPFL combined with medial MPTL using flexor tendons as graft has shown satisfactory results. Summarizing the main Tips and Pitfalls in the combined reconstruction of MPFL and MPTL:

- It should be recommended to skeletally immature patients with anatomical risk factors such as generalized ligamentous laxity, knee hyperextension, instability in flexion and subluxation of the patella in extension with the contraction of the quadriceps.
- The single semitendinosus tendon may be used as a graft with preservation of its tibial insertion.
- The use of anchors avoids bone tunnels in the patella and near the physis of the femur and tibia.
- The identification of anatomic points with the aid of fluoroscopy.
- Appropriate tensioning of MPTL at 90° of flexion with similar tension to the patellar tendon identified by touch.
- And, lastly, avoiding the overtensioning of MPFL, which could cause the medial subluxation of the patella, patella baja and medial overpressure of the patellofemoral joint.



Journal of ISAKOS

Joint Disorders & Orthopaedic Sports Medicine



Authoritative. High quality. Evidence based.

Clinical developments in orthopaedic sports medicine have accelerated in recent years. *Journal of ISAKOS (JISAKOS)* helps orthopaedic surgeons, and relevant specialists, stay current on the latest research and evidence-based guidelines, including understanding the different approaches to diagnosis and intervention around the world.

State of the Art and systematic review articles provide the best evidence for diagnosis and treatment, the pros and cons of various alternatives and future perspectives of the field. *JISAKOS* not only covers how patients respond to treatments, but how findings translate into practical application.

***JISAKOS* synthesizes current research in orthopaedic sports medicine to provide an expert guide to treating and managing patients.**

Features include:

- **Expert reviews:** Authors are invited and papers are peer-reviewed
- **Timely updates:** The latest content publishes continuously online
- **Global representation:** International editorial board members, authors and peer reviewers reflect diverse patient populations, healthcare systems and clinical preferences
- **Historical perspective:** Invited papers called "The Classic" provide a historical approach to major concepts or ideas, with abundant references to literature
- **Outcome measures:** Validated outcome measures (including PROMs) and classifications, presented in easy-to-read tables
- **Practical application:** Clinically-relevant reviews assist readers in their daily clinical practice

Visit the journal website today!
jisakos.bmj.com



BMJ

Anatomic Deltoid Ligament Repair



Gian Luigi Canata, MD
Casale Centre of Sport Traumatology
Koelliker Hospital
Torino, ITALY

Valentina Casale
Centre of Sport Traumatology
Koelliker Hospital
Torino, ITALY

Introduction

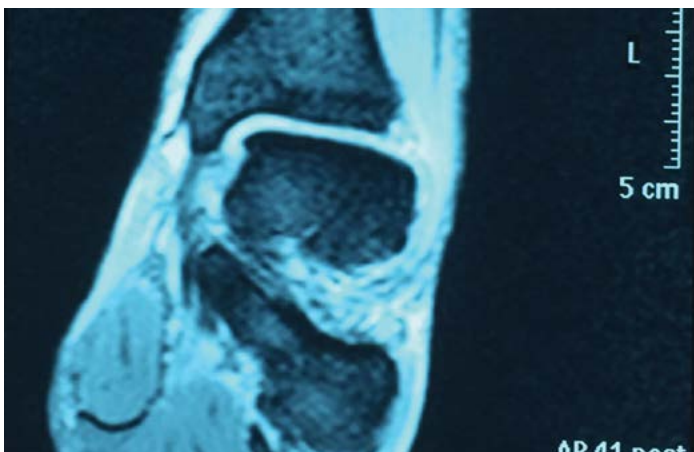
The deltoid ligament, also known as the medial collateral ligament of the ankle, connects the medial malleolus to several tarsal bones.

Its superficial components include the tibiocalcaneal ligament, the tibionavicular ligament, the posterior superficial tibiotalar ligament and the tibiospring ligament.

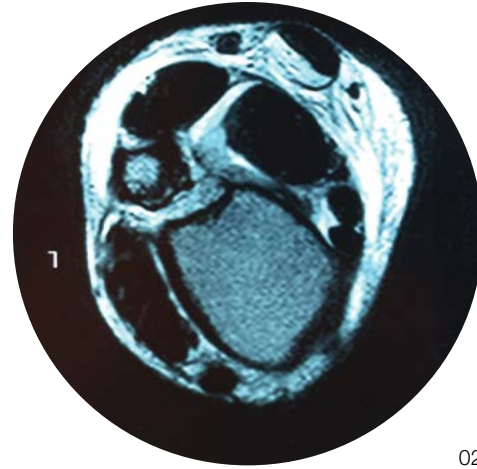
Its deep layer is intraarticular, covered by synovium, and includes the anterior tibiotalar ligament (ATTL) and the posterior deep tibiotalar ligament (PDTL).

Both the superficial and the deep deltoid components work closely to stabilize the ankle against valgus and pronation forces. These components can be damaged after a rotational ankle fracture, ankle eversion injuries, or in the presence of chronic ankle instability, as well as in late stages of adult acquired flatfoot deformity. The most distinctive mechanisms of injury are pronation – abduction, pronation – external rotation and supination – external rotation of the foot.

Among the several classification systems developed over the years to stage the deltoid ligament injury, the Myerson's classification is the most frequently used.



01



02

Clinical Presentation and Diagnosis

Deltoid ligament injuries usually cause pain, tenderness and swelling on the medial side of the ankle. In the acute injury setting, it is important to thoroughly evaluate the syndesmosis for sprain or diastasis, and assess for fibula fractures. Injuries to the syndesmosis, which commonly affect the athletic population, are identified using a combination of palpation and stress tests. In the presence of an obvious syndesmosis injury (i.e., related to a fibular fracture), stress tests are not indicated and the patient typically ambulates with decreased power at push-off. Tenderness will be evident with palpation over the anterior-inferior tibiofibular ligament (AITFL) and pain will be perceived during external rotation and dorsiflexion of the ankle against the articular facet of the fibula.

If a fibular fracture is present, the medial side of the ankle must be assessed for the presence of a bimalleolar equivalent injury.

Pressure on the proximal portion of the fibula assesses the presence of a Maisonneuve fracture and hence the likelihood of syndesmotic and deltoid ligament disruption.

In the setting of chronic deltoid instability, the external rotation stress test also helps to evaluate the integrity of the deltoid ligament.

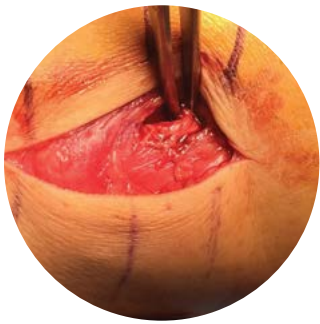
As the superficial component of the deltoid ligament crosses and stabilizes the subtalar joint, clinical evaluation of subtalar stability against valgus heel stress is also helpful. Be aware of global instability as well when examining the lateral ligaments. In severe chronic cases, valgus alignment and osteoarthritis can develop.

Radiographic Evaluation

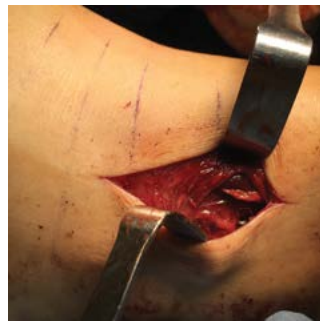Radiographic evaluation with standard plain radiographs may be useful for diagnosing a deltoid ligament injury due to a syndesmosis lesion, using the anteroposterior (AP), mortise and lateral views of the ankle. Weight bearing should be used if possible, though this can be difficult in the presence of fracture.

The radiographic parameters of a syndesmotic injury are:

- Increased tibiofibular clear space: The distance between the medial border of the fibula and the lateral border of the posterior tibia as it extends into the incisura fibularis (normal value <6mm in AP and mortise views)
- Decreased tibiofibular overlap (normal values >6mm or >42% of the width of the fibula on the AP view; >1mm on the mortise view)
- Increased medial clear space: The distance between the lateral border of the medial malleolus and the medial border of the talus



03



04

Porter et al. (2014) stated that a syndesmosis injury may be present if there is more than 1 mm lateral subluxation or more than 5 mm supination between the distal fibula and tibia on the mortise view.

It is important to note that isolated deltoid rupture does not necessarily involve a widening of the medial clear space. If the syndesmosis remains intact, the lateral malleolus holds the talus in position. This type of injury can be difficult to assess with static radiographs, thus eversion-stress radiographs help to detect isolated deltoid injury, and latent syndesmotic injuries.

Finally, when a proximal fibula fracture is suspected (i.e., Maisonneuve injury), anteroposterior and lateral views radiographs of the entire fibula should be completed.

Computed tomography (CT) is more sensitive to detect minimal (2-3 mm) syndesmotic diastasis, not visible on plain radiographs.

Magnetic resonance imaging (MRI) is highly sensitive and specific for the diagnosis of syndesmotic injuries. It has been demonstrated that the widening of the medial tibiotalar clear space on the mortise view may not be closely associated with deep deltoid ligament injuries. For these reasons, MRI may be helpful for early and accurate diagnosis, mitigating the risk of chronic medial instability, osteoarthritis and medial ankle impingement syndrome.

Indications for Surgery

The key to appropriate healing of the deltoid is stabilization of the syndesmosis.

When a syndesmotic injury occurs, treatment options depend on the severity of the lesion:

- Type 1: There is clinical evidence of a syndesmotic injury, without radiological signs. In this case, conservative treatment can be successful with weight-bearing allowed as tolerated.
- Type 2: There is radiological evidence of syndesmotic affection. A non-weight bearing cast is positioned for the first 30 days, then weight-bearing is gradually permitted.
- Type 3: An ankle syndesmotic diastasis occurs. In this case, surgical treatment is recommended to reduce and stabilize the syndesmosis.

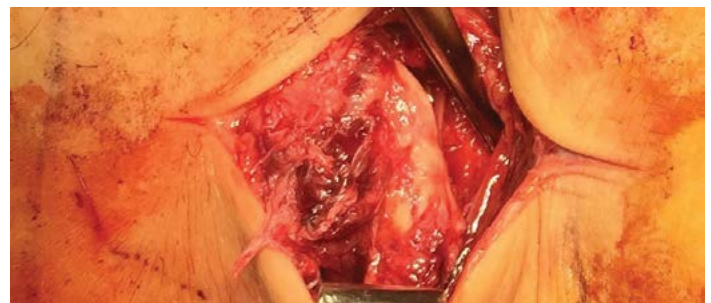Eversion ankle sprain and subsequent instability may cause partial or complete deltoid ligament tear, although surgery is rarely needed if the ankle mortise remains stable.

Syndesmotic injuries, even without fractures, involve the distal talofibular joint and can lead to ankle mortise instability. Complete deltoid ligament ruptures usually develop in combination with ankle fractures.

The possible associated fractures include supination-external rotation ankle fractures (Weber type B), pronation-external rotation ankle fractures (Weber type C) and fractures of the proximal fibula (Maisonneuve type). Since these injuries are typically associated with lateral ligamentous injuries, surgery is often recommended in case of fractures.

A deltoid ligament lesion or a combination of osseous and ligamentous lesions may develop in case of medial instability associated with a lateral malleolar fracture, caused by a medial malleolar fracture.

An entrapment of the deltoid within the medial gutter of the ankle may result from unstable bimalleolar ankle fractures, especially when the mortise remains wide medially after anatomic reduction and fixation of the lateral side of the ankle.



05

- 01 MRI: Deltoid ligament dislocated under the medial malleolus
- 02 MRI showing the fibula lying outside the syndesmotic lesion
- 03 Lateral incision for syndesmotic repair
- 04 Lateral side after reduction with screws
- 05 Medial side incision below the medial malleolus

Anatomic Deltoid Ligament Repair

Surgical Technique

The patient lies in the supine position, the tourniquet is placed on the calf and inflated 100 mmHg above the systolic arterial pressure. In the absence of acute fractures, the stability of the syndesmosis is tested with external rotation and abduction stress under fluoroscopy. If a fibula fracture is present, this should be stabilized and repaired before stress testing of the syndesmosis and medial ankle.

The surgical approaches for the stabilization of the syndesmosis may be both medial and lateral.

The lateral approach is made to repair the fibula fracture and reduce and repair the syndesmosis, while the medial approach is used to repair a ruptured deltoid ligament. When the lateral approach is performed, use caution to avoid damage to the sural and superficial peroneal nerves. Carefully reduce any distal fibula fracture, reduce the diastasis and correct any malrotation. After the fibula reduction, the syndesmosis may be stabilized with two screws across four cortices. Then, it is possible to repair the AITFL, if completely torn.

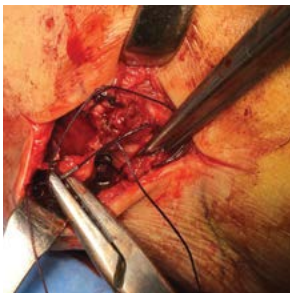
When the medial approach is performed, a curvilinear skin incision distally and parallel to the medial malleolus is made. After the exposure and the incision of the most superficial layers, including the flexor retinaculum, the deltoid ligament is evaluated. If the deep ligament is compromised due to a syndesmotic injury, a primary repair of the ligament can be performed.

During this procedure, it is important to ensure that the posterior tibial tendon (PTT) and the spring ligament are intact and protected, otherwise the ankle joint stability will not be guaranteed.

The PTT sheath is incised and the tendon is retracted, in order to obtain a good inspection of the articular surfaces. Any possible cartilage damage must be debrided and drilled if necessary.

Using no. 1 Vicryl sutures, the deep fibers of the deltoid ligament are sutured and tied; then the superficial stitches are secured only after the osteosynthesis is completed and a definitive reduction and fixation on the lateral side is obtained, in order to avoid any possible future suture avulsion.

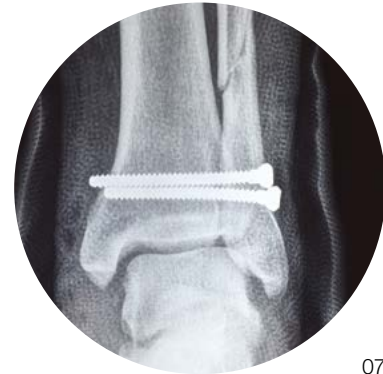The final result, including joint reduction and new alignment, may be evaluated with fluoroscopy, before layered skin closure.



06

Postoperative Regimen

Joint immobilization is advised immediately after surgery. It is recommended even from the third to the sixth week postoperatively, using a non-weight bearing boot. Radiographic assessment is performed after four weeks to check the correct anatomic alignment. After two months, the patient may begin weight bearing in a hinged ankle brace. After nine weeks, running is permitted but always wearing an ankle tape. Finally, after twelve weeks, the patient can stop using joint protections.



07

Conclusions

The superficial deltoid ligament has been shown to resist talar abduction, while the deep deltoid has been demonstrated to be more closely related to rotational stability of the talus within the mortise.

The goal of surgery must be the anatomical restoration of both deep and superficial deltoid ligaments and the syndesmosis stabilization. This technique is less invasive than others, thereby it ensure optimal outcomes.

MYERSON'S CLASSIFICATION	
STAGE	DESCRIPTION
Stage 1	Avulsion of the superficial component of the deltoid ligament
Stage 2	Rupture of the superficial deltoid ligament and avulsion of the deep component
Stage 3	Rupture of both superficial and deep deltoid ligaments
Stage 4	Rupture of deltoid ligament associated with rupture of the posterior tibial tendon (PTT)

08

06 Deltoid ligament detached from the medial malleolus. Medial repair with absorbable sutures.

07 Anatomic alignment after surgery

08 Myerson's classification for deltoid ligament injuries

Patellar Resurfacing: Where Are We Now?



Michelle L.
Cameron-Donaldson, MD
*Northern Montana Hospital
Havre, MT, UNITED STATES*

The appropriate management of the patella during primary total knee arthroplasty remains elusive. The earliest knee replacements focused entirely on the tibio-femoral joint. The patello-femoral joint was not addressed in the first generation of knee arthroplasty. With the success of the first generation of knee arthroplasty and recognition of significant complications with the patello-femoral joint, advances were made in joint design, including more attention to the patella. The addition of a trochlear flange to the femoral component to accommodate the native patella improved outcomes. The next major design advancement occurred in the 1980's with the introduction of resurfacing. However, as patellar resurfacing was accepted as a crucial portion of total knee arthroplasty, a unique set of complications was identified. The metal backed patella was introduced during this time, and resulted in catastrophic failures. Historically, the patella accounted for up to 50% of total knee replacement failures in the 1980's and 90's. This led to significant rethinking of the necessity of patellar resurfacing. The debate over how to address the patella has continued for three decades.

International Perspective

The controversy in patella resurfacing is demonstrated by the wide divide in international approaches to the patella during total knee arthroplasty. In North America, greater than 90% of surgeons routinely resurface the patella. Vielgut et al published an interesting review of eight European joint registries in *International Orthopaedics* in 2013 and noted wide differences in patellar resurfacing. In Scandinavian countries there are dramatic differences in the approach to the patella. The Danish joint registry shows that 76% of patellae are resurfaced, whereas in Norway and Sweden, only 2% are resurfaced. Australian surgeons resurface approximately 50% of patellae. The English and Welsh registry showed a 30% rate of patellar resurfacing.

The Portuguese registry showed a 65% resurfacing rate. In New Zealand 30% are resurfaced and in Canada almost 60% are resurfaced. Reviewing the revision rates of these same registries, there appears to be no correlation with patellar resurfacing.

Current Approaches to Patellar Management in Total Knee Arthroplasty

As of 2016, there are three camps in the approach to patellar resurfacing; routine resurfacing, no resurfacing and selective resurfacing.

Routine Resurfacing

Proponents of routine resurfacing cite reduced post-operative anterior knee pain, higher patient satisfaction, better overall function and low complication rates. Revision rates for resurfaced patellae have decreased from 50% in the 1980s and early 90's to approximately 10% in the current literature. Complications associated with resurfacing include patella fracture, maltracking, soft tissue impingement, patellar ligament rupture, polyethylene fracture, polyethylene wear, component loosening and component dissociation. In total, the risk of all of these complications is low with most studies citing individual complication risks in the 1% range.

No Resurfacing

Clinicians who favor retaining the native patella argue that clinical results between patients with and without resurfacing are similar to resurfacing. The reported rate of secondary resurfacing due to recalcitrant anterior knee pain is 10-12% based on multiple studies. The non-resurfacing camp claims preservation of patellar bone, more normal patello-femoral kinematics, and ease of resurfacing if recalcitrant anterior knee pain develops. Furthermore, they emphasize the avoidance of post-operative complications attributable to resurfacing.

Selective Resurfacing

Proponents of selective resurfacing attempt to identify patients at risk for recalcitrant anterior knee pain or poor clinical function. Broad guidelines for patellar resurfacing are pre-operative anterior knee pain, inflammatory arthritis, crystalline disease, and evidence of Outerbridge grade IV changes, patellar maltracking, subluxation or dislocation.

Patellar Resurfacing: Where Are We Now?

Current Literature

Since the patellar resurfacing discussion has been ongoing for over 30 years, there are literally hundreds of articles on the topic. The studies, reviews and meta-analysis published in the last five years continue to be inconclusive. In 2011, Breeman et al published a randomized controlled trial of 1,715 patients randomized to resurfacing vs. non-resurfacing with five year follow-up and found no difference in functional outcomes, reoperation rate or total health care costs. Two percent of the patients that were in the non-resurfaced group required secondary resurfacing within five years, and one percent of the patients undergoing resurfacing sustained a patellar related complication that required revision surgery. Pavlou et al performed a meta-analysis also published in 2011 which showed that patellar resurfacing did not significantly affect anterior knee pain or functional outcomes; however, there was a slightly higher reoperation rate in the non-resurfaced group. Another meta-analysis also published in 2011 by Li et al, reported that the risk of reoperation due to patello-femoral pain was reduced by patellar resurfacing; however, there was no difference in pain and knee function between the two groups. In 2012, Beaupre et al reported the results of another randomized controlled trial with 5–10 year follow-up and showed no difference between the resurface and non-resurfaced groups. A meta-analysis in 2012 published by Pilling et al found that patellar resurfacing decreased the risk of reoperation due to patello-femoral pain, but otherwise no difference in patient satisfaction, pain or function was noted between the two groups. However, it is important to note that in the resurfaced group anterior knee pain was 11% less than in the non-resurfaced group. Chen et al published another meta-analysis in 2013 that found that the absolute risk of reoperation was reduced by 4% in the patellar resurfacing arm; meaning that one would have to resurface 25 patellae to prevent one reoperation. There was no difference in groups in regard to anterior knee pain, knee pain score and knee function score.

Controversy/Consensus

The biggest problem in the resurfacing vs. non-resurfacing debate is not understanding why some patients have post-operative anterior knee pain and others do not. This is the driving force behind the selective resurfacing argument. In 2001 Barrack et al found that 28% of patients with resurfaced patellae suffered from anterior knee pain post-operatively. These patients had not reported pre-operative anterior knee pain. 9% of patients that reported pre-operative anterior knee pain had continued pain post-operatively despite resurfacing. In the non-resurfaced group, 23% reported anterior knee pain pre-operatively and continued to report similar pain post-operatively; 14% of the non-resurfaced group developed new anterior knee pain post-operatively.

Despite the variation in outcomes with and without resurfacing, there is some consensus regarding patients that should undergo resurfacing at the time of primary total knee arthroplasty, these include patients with inflammatory arthritis, severe patellar deformity or eburnation, and the presence of crystalline disease.

Conclusions

Despite 30 years of research into patellar resurfacing, answers remain elusive. North American surgeons continue to be the most aggressive in patellar resurfacing, with Europeans in general being less likely to resurface, with wide variations from country to country. Most data point to similar outcomes with resurfaced and non-resurfaced patellae; however, the risk of reoperation for anterior knee pain persists and is more common in non-resurfaced patellae.

Ultimately, the answer will most likely reside in selective resurfacing; however, the criteria for selective resurfacing still requires more research to determine which patients are at highest risk for post-operative anterior knee pain and would benefit from primary resurfacing. Several confounding factors may be at play in making these selection criteria elusive including vast differences in implant “patellar-friendly” design; sensitivity of the knee scoring systems to determine real differences in patient outcomes, the so called “ceiling effect”, the vast heterogeneity in data in the large meta-analysis with different implants and surgeon treatments of the patella. It appears as if the debate will continue for years to come, until further research and analysis can bring clarity to the appropriate patient for resurfacing vs. non-resurfacing.

Genetics and Pathogenesis of Rotator Cuff Healing: The Race is Long!



Carina Cohen, MD
Federal University of São Paulo, BRAZIL

Degenerative rotator cuff tears are a frequent cause of shoulder pain that may lead to severe impairment of function, therefore rotator cuff repair is a very commonly performed orthopedic procedure. However, re-tear rates after the tendon repair is high, reported to be around 20% and even greater than 90% in massive tears. Not all repaired tendons heal completely but residual defects or retears after repair can be asymptomatic.

There are multiple factors that affect the outcome of cuff tearing and healing process. We will review the pathogenesis and genetic factors involved in rotator cuff tears to look for solutions that address the biological aspects of the disease.

The normal bone-to-tendon interface involves the interdigitation of layers of intact, oriented Type I collagenous fibers to a continuous insertion on the humerus. Longitudinally, there are four distinct zones of tissue: tendon, nonmineralized fibrocartilage, mineralized fibrocartilage, and bone. When the tendons within the rotator cuff begin to degenerate, the collagenous fibers undergo hyaline and myxoid degeneration, and the bone undergoes chondroid metaplasia. Inflammation, calcification, vascular proliferation, and fatty infiltration are also present. These degenerative changes are often macroscopically visible at the site of rupture during surgical repair and are also present throughout the damaged tendon suggesting the degenerative process happens not only locally.

In normal bone-to-tendon healing and also after surgical repair there are three stages (inflammatory, repair stage, and remodeling), however the four fibrocartilagenous zones are not recreated since the bone and tendon are joined by a layer of fibrovascular scar tissue predominated by Type III collagen. This tissue is weaker than the original insertion site which makes repairs prone to failure. Tissue healing in adults with a competent immune system is characterized by fibrosis rather than regeneration of normal tissue structure and composition due to a number of inflammatory mediators (such as cytokines) and pathways that affect the process.

Growth factors are a group of cytokines that have been implicated in the repair stage of natural bone-to-tendon healing, such as the cytokines basic fibroblast growth factor (bFGF), insulin-like growth factor 1 (IGF-1), platelet-derived growth factor β (PDGF- β) and transforming growth factor beta (TGF- β). In general, these growth factors induce mitosis, extracellular matrix production, neovascularization, cell maturation, and differentiation. Research has focused on their ability to augment rotator cuff repairs showing that several growth factors are capable of increasing the strength of repairs in animal models. However, the strengthening is accomplished through the production of more scar tissue, as opposed to regeneration of native tissue so is not clear whether it really improves quality.

Although many growth factors and cellular processes have been identified in the normal bone-to-tendon healing process, each growth factor has a multitude of functions and interactions, and it is unlikely a great change will be observed through application of individual growth factors. Therefore, there is a great amount of interest in the creation of “platelet-rich plasma” (PRP) by centrifuging autologous blood to purify a dense, suturable plasma matrix. PRP includes high platelet concentration that provides a release of many growth factors and bioactive molecules identified previously as crucial in normal bone-to-tendon healing: TGF- β , bFGF, PDGF, vascular endothelial growth factor, connective tissue growth factor, and epidermal growth factor.

The safety of PRP augmentation to rotator cuff repair has been investigated but PRP has yet to prove itself as a useful augment to rotator cuff repair. There are 16 controlled studies about PRP, but is very hard to compare them as they have different study designs, tear sizes, surgical technique of cuff repair (double row, single row, transosseous repair), biologic characteristics of PRP (presence or absence of white cells and whether it is used activated by trombin or in the inactivated form), devices used (since different devices produce different concentrations), and method used for application—either by direct injection or by incorporation of platelet rich fibrin matrix into the repair.

The latest Cochrane systematic review and meta-analysis found no benefit attributable to PRP for short-, medium-, or long-term function. It showed improvement in Constant Score at one year follow-up but not statistically significant. Short-term improvements in pain were identified but the effect sizes were small, and unlikely to be clinically important. Based on this review, PRP use is currently unsupported. These results are similar to other previous systematic reviews and meta-analyses on this subject. Growth factor therapy for rotator cuff repairs remains a promising therapy for the future; however, much work needs to be done to optimize its effectiveness. The optimal timing and vehicle for growth factor delivery have remained elusive.

Genetics and Pathogenesis of Rotator Cuff Healing: The Race is Long!

The modulation of the tissue microenvironment through cell or gene therapy, as well as with the use of tissue scaffolds, may also provide promising options for the future. A recent study used ultrasound-guided human umbilical cord blood (UCB)-derived mesenchymal stem cell (MSC) injection to regenerate a full-thickness subscapularis tendon tear in a rabbit model without surgical repair or bioscaffold. The histology analysis revealed that UCB-derived MSCs was able to induce regeneration of rotator cuff tendon tear and that the regenerated tissue was predominantly composed of type I collagen. It is important to highlight that it is still necessary to optimize these methods prior clinical use.

Genetic factors have been suggested as intrinsic risk factors for rotator cuff tendon injury. Harvie et al described that siblings present an increased risk for full-thickness tears and of experiencing symptoms than spouses, who were not biologically related. Moreover, Gwilym *et al* reported that full-thickness rotator cuff tears in siblings are more likely to progress over a period of five years than in a control population. Thus, these studies showed that genetic factors may have an important role in the susceptibility and the progression of rotator cuff tears.

It is believed that the etiology of the rotator cuff tear is determined by both genetic and environmental factors (for example, smoking habit and type of work). Degenerative rotator cuff tear is seen as a multifactorial trait, in which the interaction of several genetic and environmental factors is necessary for the disease development.

It is of interest to elucidate the genetic variants (also called as DNA polymorphisms) that may be responsible for interindividual susceptibility to rotator cuff tears. The first study in this field investigated whether some polymorphisms within specific genes involved in intrinsic tendon-muscle degeneration were associated with the risk of rotator cuff disease, including tendinosis, partial-thickness cuff tear, and full-thickness cuff tear. The study performed by Motta et al. showed association of this disease and some genetic variants of *DEFB1*, *ESRRB*, *FGF3*, *FGF10* and *FGFR1* genes in the Brazilian population. Terrlink *et al* performed an independent study aiming to confirm the association between these multiple candidate genes and rotator cuff disease in a U.S. patient's cohort. The authors demonstrated that two variants in *ESRRB* gene were associated with the risk of rotator cuff disease. More recently, this research group performed the first genome-wide study trying to screen genetic factors influencing rotator cuff tearing. Two polymorphisms were significantly associated, residing in *SAP30BP* on chromosome 17 and *SASH1* on chromosome 6. Both genes are associated with the cellular process of apoptosis.

Our group has also been studying this topic (unpublished data). We firstly detected that several genes involved in the synthesis and repair of the extracellular matrix presented altered expression in human injured supraspinatus tendon samples, such as, Type V collagen (*COL5A1*, a collagen involved in the fibrinogenesis process). We are trying to determine whether polymorphisms of these genes may be associated with risk of rotator cuff injury. Among the preliminary findings, a polymorphism in *COL5A1* was associated with risk of rotator cuff injury.

Few genetic variants that are involved in susceptibility for rotator cuff tears have been identified. Understanding of these genetic factors, as well as their interactions with environmental factors, is necessary to better understand the disease etiology and to allow for personalized medicine. The development of an accurate prediction model based on these factors may help in the identification of individuals at risk for the development of rotator cuff tear and in the selection of treatment and prevention strategies.

In summary, the process of healing is still an issue to be studied since re-tear rates are very high. Surgeons may potentially improve outcomes after rotator cuff repair by controlling and optimizing the mechanical and biological environment after rotator cuff repair. However, the scientific literature regarding the best choice for augmentation remains unclear. Current evidence is not sufficient to conclude that PRP provides clear clinical benefit and augmentation of soft tissue healing. Although PRP seems to present great potential, there is a lack of standardization and the ideal platelet concentrations, dose-response curves, saturation effects and ideal timing of intervention remain unknown. The potential of exogenous cells sources to improve healing combined with PRP may be of interest in the future. Also we are making an effort to advance the knowledge regarding the contributions of genetics in this area.

Elbow Injuries in the Throwing Athlete: Location, Location, Location!



Michael T. Freehill, MD
*Department of Orthopaedic Surgery,
 Wake Forest School of Medicine
 Winston-Salem, NC, UNITED STATES*



Austin V. Stone, MD, PhD
*Department of Orthopaedic Surgery,
 Wake Forest School of Medicine
 Winston-Salem, NC, UNITED STATES*

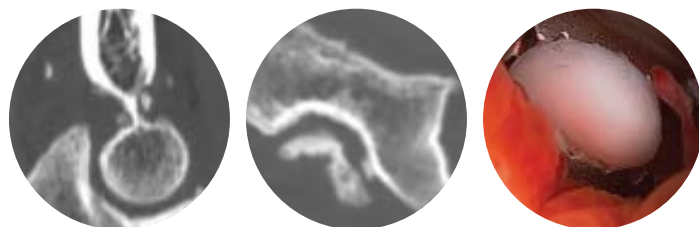
Elbow injuries in the throwing athlete can have a substantial impact on the player's performance and may be highly detrimental to the player's career. Unlike elbow injuries resulting from acute trauma, injuries in the thrower's elbow tend to be chronic as a result of repetitive stress. The unique stress of throwing predispose the elbow to a subset of pathology reviewed in this article. In the throwing athlete, considerations for elbow pain include: ulnar collateral ligament injury, valgus extension overload, olecranon osteophytes, ulnar neuritis, olecranon stress fractures, flexor pronator injury, medial epicondyle avulsion fracture, capitellar osteochondritis dissecans, and loose bodies. These injuries are usually the cumulative result from repetitive stress during maximum internal rotation torque through the completion of the throwing motion with rapid elbow extension. This pattern was described by King and colleagues (1964) as the progression from medial tension and lateral compression overload to extension overload. The varying tensile, shear, and compressive forces can ultimately result in overuse injuries. Since many pathologies can be found in the throwing elbow, a thorough history of the timing and the location of the reported symptoms can help establish a differential diagnosis.

History and Physical Examination

The history should begin with an understanding of the throwing athletes sport, position, and level of activity or competition. The athlete's pain should then be characterized based on its location, chronicity, associated neurologic or mechanical symptoms, and in the context of the athlete's sport. The primary symptom may be decreased throwing speed, accuracy, or mechanical symptoms rather than pain. The timing and duration of the pain or symptoms should be characterized and potentially correlated with training regimen alterations, increased pitch counts or innings played, and any suspected traumatic event.

Physical examination in the throwing athlete should include an analysis of the general posture, resting position and muscle mass of the throwing and non-throwing arms. Elbow pain may be a manifestation of shoulder or scapular pathology, so both upper extremities should be examined in their entirety. The elbow carrying angle should also be evaluated. A normal carrying angle is 11° in men and 13° in women; although the carrying angle may be increased up to 15° in throwers. Asymmetric elbow range of motion in the throwing arm may be indicative of effusions, osteophytic change, or loose bodies.

The elbow should be palpated both before and during range of motion to assess for static and/or dynamic injury. The stability of the elbow can be assessed in varying degrees of flexion and extension and in pronation and supination. Since many of the injuries are related to chronic overload, a dynamic evaluation will best elucidate the pathology. Ulnar neuritis may be identified with a positive Tinel's sign at the cubital tunnel. Integrity of the UCL can be tested with a modified milking maneuver and the moving valgus stress. The modified milking maneuver is performed with the shoulder in adduction and maximum external rotation. The examiner uses one hand to hold the elbow in 70° of flexion with the thumb on the medial joint line— 70° of flexion was described in a cadaveric study to be the position of greatest valgus laxity in a sectioned UCL. The other hand is used to pull the thumb of the patient creating a valgus stress. Palpation of the joint line can determine joint space opening and presence of an end point. The moving valgus stress test described by O'Driscoll is performed with the shoulder at 90° of abduction and external rotation. The physician applies and maintains a constant valgus torque moving from a fully flexed elbow quickly into extension. A positive test results from apprehension, pain, or instability within the arc from 70 to 120 degrees. The elbow may also be evaluated with supination and rapid extension for assessment of posterior medial olecranon impingement.



01

01 Loose body demonstrated on computed tomography scans and at the time of arthroscopic removal.

Elbow Injuries in the Throwing Athlete: Location, Location, Location!

Imaging Studies

Standard radiographs of the elbow including anteroposterior, lateral and oblique views should be obtained. These radiographs can demonstrate stress fractures or avulsion injuries, osteophytes or presence of loose bodies. Stress fractures may not be apparent on routine radiographs and can be evaluated with CT or bone scans; however, MRI is the most commonly used advanced imaging modality because of its ability to detect stress injury in both bone and soft tissues. Ultrasound imaging is also gaining popularity for UCL evaluation due to its accessibility and affordability.

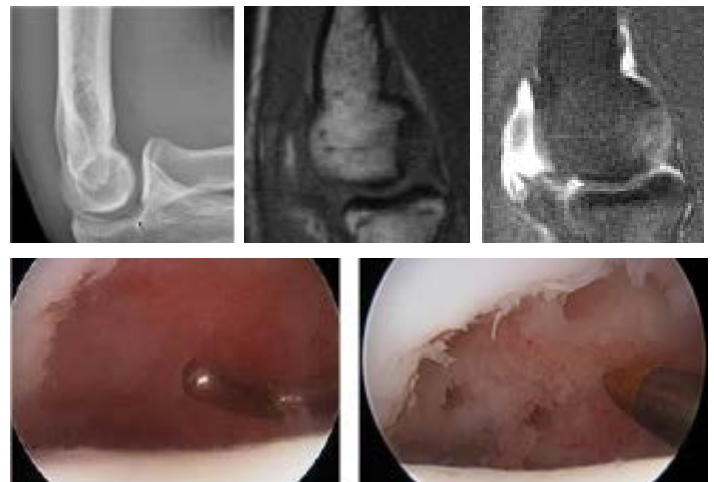
Table 1. Differential diagnosis based on symptom location.

Location	Tender to Palpation	Potential Pathology
Medial	Medial Epicondyle	Epicondylitis Ulnar collateral ligament injury Flexor-pronator mass injury
	Cubital Tunnel	Ulnar Neuritis
Lateral	Radial Head	Valgus extension overload Capitellar OCD
	Posterolateral	Capitellar OCD Radiocapitellar plica
Posterior	Lateral olecranon	Stress fracture Osteophytes
	Medial olecranon	Triceps avulsion Injury Stress fracture Apophysitis Osteophytes
	Posteromedial	Valgus extension overload Osteophytes

Treatment Strategies: Medial Elbow Ulnar Collateral Ligament Injuries

Treatment of UCL injuries depends on whether they are partial tears or complete ruptures. Partial tears are typically treated non-operatively with a period of rest for approximately three months with gradual return to play after therapy and a throwing program. Nonsteroidal inflammatory drugs are routinely used and some authors advocate for the injection of platelet rich plasma.

Operative indications for reconstruction of the UCL include complete ruptures of the ligament or in partial tears which remain symptomatic after nonoperative management. Primary repair of the ligament in adults was historically unsuccessful, however there may be a role in certain cases with early intervention. The original reconstructive technique described by Jobe et al utilized a free tendon graft through figure of eight bone tunnels in the medial epicondyle, detachment of the flexor pronator mass and ulnar nerve transposition. A later modification preserved the flexor-pronator mass and does not mandate transposition of the ulnar nerve.



02

An alternative method for UCL reconstruction includes the docking technique which splits the flexor carpi ulnaris and creates a single humeral tunnel. The graft is passed through the ulnar tunnels as in the Jobe technique and is then “docked” into the single humeral tunnel. The graft is tensioned with sutures tied over the humeral cortex. The docking technique was found to be biomechanically superior in the laboratory, but clinical outcomes have not identified superiority of either procedure. The largest UCL reconstruction cohort in the literature described 83% return to same level of competition.

Ulnar Neuritis

Another common elbow pathology in the throwing athlete is ulnar neuritis. The ulnar nerve arises from the medial cord of the brachial plexus and travels through several sites of potential compression. These sites include the arcade of Struthers, the medial intermuscular septum, the cubital tunnel, the two heads of the flexor carpi ulnaris, and in Guyon's canal. In the throwing athlete, more common compression sites are the hypertrophied intermuscular septum, the medial head of the triceps, posteromedial osteophytes, and Osborne's ligament.

For non-elite throwers, initial management of ulnar neuritis focuses on activity modification and rest. Nonoperative treatment is frequently unsuccessful in the elite throwing athlete due to the stresses across the elbow and nerve. Operative treatment for ulnar neuritis includes in situ decompression or anterior transposition. Throwing athletes are particularly predisposed to subluxation if the cubital tunnel is released without transposition. All sites of ulnar nerve compression should be released prior to transposition. Subcutaneous or submuscular transposition is then performed. Regardless of the transposition technique, the medial antebrachial cutaneous nerve, the ulnar vascular supply and the first motor bridge to the flexor carpi ulnaris must be preserved.

Flexor-Pronator Injury

The origins of the flexor-pronator mass are subject to overuse tendonitis since the flexor digitorum superficialis and flexor carpi ulnaris are prominent stabilizers during throwing. Flexor-pronator injury is generally treated conservatively with rest and non-steroidal anti-inflammatory drugs until symptoms resolve. The thrower is then rehabilitated with an emphasis on strengthening the flexor-pronator mass and graduating to an interval throwing program.

Medial Epicondyle Avulsion or Apophysitis

Medial epicondyle avulsion or apophysitis is more common in adolescent throwers and is low on the differential in the adult. Treatment is also conservative for medial epicondyle apophysitis, but if the medial epicondyle is completely avulsed, then open reduction and internal fixation is recommended. Athletes are permitted to heal through rest followed by a gradual return to throwing.

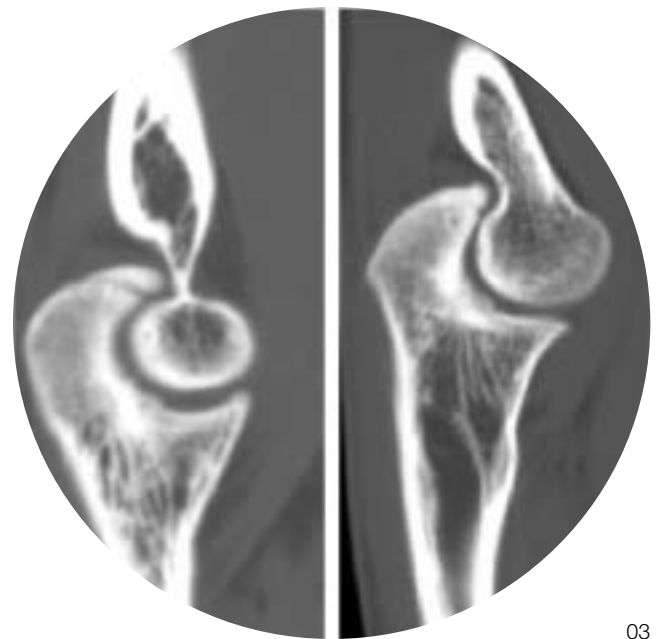Treatment Strategies: Lateral Elbow Pain

Osteochondritis Dissecans of the Capitellum

Osteochondritis dissecans of the capitellum (OCD) remains an enigma. The spectrum of pathology can include injury to the subchondral bone and the development of frank loose bodies. Capitellar OCD is usually manifested with lateral elbow pain with both palpation and valgus stress.

Treatment for capitellar OCD is based on the severity of the lesion. Nonoperative treatment is usually commenced with an extended period of rest with no throwing. Nonoperative treatment is more likely to be successful in those with open physes rather than in mature individuals. Following resolution of pain, a strengthening and rehabilitative program is used to return the athlete to throwing.

Operative treatment of capitellar OCD is indicated in those who do not respond to nonoperative management and those with loose bodies. Debridement and removal of loose bodies can be performed with arthroscopy. Unstable lesions may be repaired; however, results are variable. In the event of an irreparable lesion, some authors have tried debridement with micro-fracture or osteochondral graft transplantation. The initiation of elbow strengthening and return to throwing is based on the procedures performed and the respective time to healing.



03

- 02 Radiograph, T1 and T2 MRIs, and arthroscopic evaluation of osteochondritis dissecans of the capitellum.
- 03 An incomplete olecranon stress fracture on presentation and at 3 months after nonoperative treatment.

Elbow Injuries in the Throwing Athlete: Location, Location, Location!

Treatment Strategies: Posterior Elbow Pain

Valgus Extension Overload Syndrome

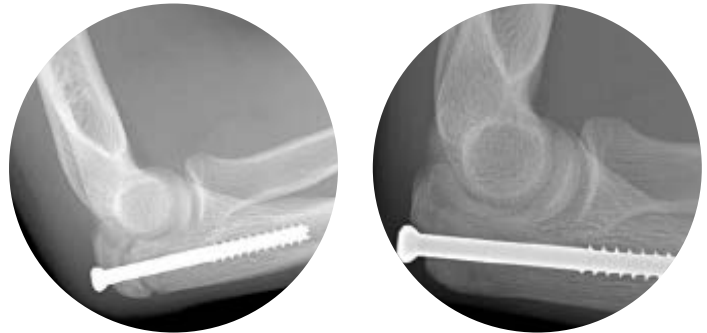
Valgus extension overload syndrome (VEOS) is a common malady in throwing athletes. VEOS is thought to be secondary to posteromedial impingement secondary to repetitive valgus microtrauma and the subsequent formation of posteromedial osteophytes. Osteophyte formation results in posterior pain with repetitive locking and catching in extension and is frequently symptomatic in the late acceleration and follow-through throwing phases. VEOS may be associated with UCL injury or capitellar OCD.

Nonoperative treatment follows a standard approach of rest, ice and nonsteroidal anti-inflammatory drugs. Range of motion and strengthening exercises are subsequently resumed following symptom improvement. Operative treatment is indicated after unsuccessful nonoperative management or in throwing athletes with symptomatic osteophytes. Arthroscopic debridement and osteophyte excision is primarily used. Athletes should be aware of the risk of recurrence and intraoperative risk of ulnar nerve injury. Concomitant pathology should also be addressed at the time of surgery. Rest and rehabilitation is dependent on the extent of the operation.

Olecranon Stress Fracture

Olecranon stress fractures may develop from repetitive microtrauma, osteophyte impingement, or from tensile failure from the triceps insertion. Pain is localized to the posterolateral or posteromedial olecranon. As with most pathology in the throwing elbow, the pain is usually insidious in onset and progresses over time.

Nonoperative management with rest and no throwing is initially attempted. Brief immobilization and initial limited extension may relieve symptoms and allow for healing. Operative intervention is recommended for complete fractures. Two mainstays of operative management include compressive cannulated screw fixation and plate osteosynthesis. Range of motion exercises are generally commenced early to prevent elbow stiffness; however in nonoperative treatment extension may be initially limited. Gradual return to throwing is initiated at approximately 6-8 weeks for either non-operative or operative treatment.



04

Summary

The diagnosis of elbow pain in the throwing athlete is principally determined by the location and timing of the pain during throwing. A thorough history of the pain when throwing can help elucidate chronic overuse injuries. The differential is then quickly reduced based on where the elbow is tender and the location of pain with range of motion. A limited and specific imaging modality can then confirm the diagnosis. Following treatment it is important to be cautious in the rehabilitation process to prevent the recurrence of overuse injuries. When examining the elbow in the throwing athlete, remember: Location, Location, Location!

- 04 A complete olecranon stress fracture treated operatively with cannulated screw fixation. Lateral radiographs taken immediately and at two months post-operative.

Soft Tissue Balancing in Total Knee Arthroplasty



Tomoyuki Matsumoto, MD, PhD
Hirotsugu Muratsu, MD, PhD
Kobe University Graduate School
of Medicine, Kobe, JAPAN

Ryosuke Kuroda, MD, PhD
Masahiro Kurosaka MD, PhD
Steel Memorial Hirohata Hospital, Himeji, JAPAN

Introduction

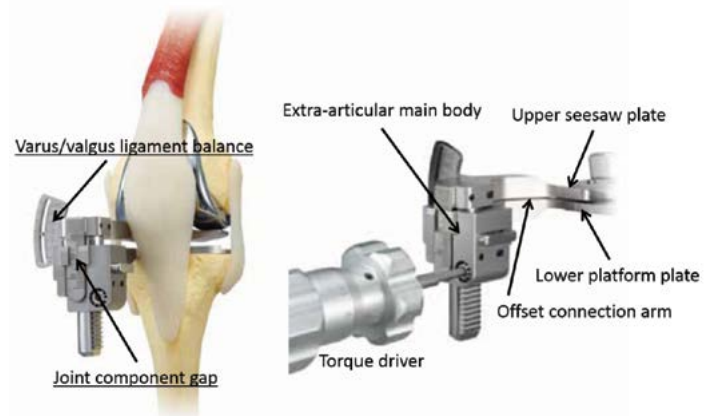
Total knee arthroplasty (TKA) is a well-established procedure, which generally results in pain relief, improved physical function, and a high level of patient satisfaction. However, knee instability following primary TKA is considered an important factor for early TKA failure, as shown in the registry data. Fehring et al studied 279 revision surgeries within 5 years of their index arthroplasty, and reported 74 revision cases (27%) caused by instability. In a retrospective study of revision surgery, Sharkey et al reported instability in 21.2% of their early revision knee arthroplasty failures. They concluded that the instability might be due to inadequate correction of soft tissue imbalances in both the sagittal and coronal planes. As a result, soft tissue balancing has been recognized as an essential surgical intervention for improving the outcomes of TKA.

Intraoperative assessment of soft tissue balance remains difficult, and management is left much to the surgeon's subjective feel and experience. Whereas several quantitative measurement methods using tensors or balancers were traditionally reported, measurement was performed under unphysiological conditions after TKA; including an assessment of bone cut surfaces with patello-femoral (PF) joint eversion.

In this article, an offset-type tensor device in which soft tissue balance can be assessed throughout the range of motion with a repaired PF joint and a femoral component in place, is discussed and the clinical value of using the system is also highlighted.

Offset-type Tensor

In order to permit soft tissue balancing under physiological conditions, in a surgeon-friendly manner, a new tensor was developed to obtain soft tissue balancing throughout the range of motion with a reduced PF joint and an aligned tibiofemoral (TF) joint. The offset type tensor consists of three parts: an upper seesaw plate, a lower platform plate with a spike, and an extra-articular main body (Fig. 01). Both plates are placed at the center of the knee, and we apply one of the two tensioning devices that fit either a cruciate-retaining (CR) or a posterior-stabilized (PS) TKA. The PS TKA tensor consists of a seesaw plate with a proximal post along the center that fits the inter-condylar space, as well as a cam for the femoral trial prosthesis. This post and cam mechanism controls the tibiofemoral position in both the coronal and sagittal planes. The CR TKA tensor consists of a seesaw plate with a proximal convex shaped centralizer that fits the inter-condylar space and controls the coronal joint alignment. These mechanisms permit us to reproduce the joint constraint and alignment after implanting the prostheses. This device is ultimately designed to permit surgeons to measure the varus/valgus ligament balance and joint center/joint component gap, while applying a constant joint distraction force.



01

Joint distraction forces ranging from 30 lb (13.6 kg) to 80 lb (36.3 kg) can be exerted between the seesaw and platform plates through a specially made torque driver, which can change the applied torque value. After sterilization, this torque driver is placed on a rack that contains a pinion mechanism along the extra-articular main body, and the appropriate torque is applied to generate the designated distraction force.

Disclosures:

Tomoyuki Matsumoto - No Conflict of Interest
Hirotsugu Muratsu - Consulting and Royalty Zimmer Biomet
Ryosuke Kuroda - No Conflict of Interest
Masahiro Kurosaka - No Conflict of Interest

01 Offset-type tensor

The tensor consists of three parts: upper seesaw plate, lower platform plate, and extra-articular main body. Two plates are connected to the extra-articular main body by the offset connection arm.

Soft Tissue Balancing in Total Knee Arthroplasty

Once appropriately distracted, attention is focused on two scales that correspond to the tensor: the angle ($^{\circ}$, positive value in varus ligament balance) between the seesaw and platform plates, and the distance (mm) between the center midpoints of upper surface of the seesaw plate and the proximal tibial cut (mm, joint center/joint component gap). By measuring these angular deviations and distances under a constant joint distraction force, the ligament balance and joint center/joint component gaps can be measured, respectively.

Soft Tissue Balance with Reduced PF Joint and Femoral Component Placement

In a series of intraoperative soft tissue balance assessments, the importance of maintaining a reduced and anatomically oriented PF joint was emphasized, in order to obtain accurate and more physiologically relevant soft tissue balancing. First, the joint component gap kinematics in PS TKA showed a different pattern with the PF joint everted and reduced; the component gap increased throughout knee flexion with the PF joint eversion, while the component gap with the PF joint reduction increased with knee flexion but decreased after 60° of flexion. Second, intra-operative assessment of the joint component gap with reduced PF joint has been reported to predict post-operative flexion. Both an increased value during the extension to flexion gap and a decreased value during the flexion to deep flexion gap with the PF joint reduced, not everted, showed an inverse correlation with the post-operative knee flexion angle, not pre-operative flexion angle. Third, the correlations between the soft tissue balance assessed by the tensor and the navigation system were higher with the reduced PF joint than everted PF joint, suggesting that surgeons should assess soft tissue balance during PS TKA with the PF joint reduced when using a navigation system. In addition to these reports, some recent studies have emphasized the importance of the physiological post-operative knee condition in assessing soft tissue balance with the PF joint reduction.

The main concepts of measurement using the new tensor are different from the conventional tensioning device, with the femoral trial component in place as well as a reduced PF joint. As the next step, accordingly, the difference in soft tissue balancing between the femoral trial component in place and the conventional osteotomized condition was explored. In the intraoperative assessment of soft tissue balance, the joint gap showed significant decrease at extension, not flexion, after the femoral trial prosthesis placement, and varus ligament balances were significantly reduced at extension and increased at flexion after the femoral trial placement.

These changes at extension might have been caused by the tensed posterior structures of the knee with the posterior condyle of the externally rotated aligned femoral trial. At knee flexion, a medial tension in the extensor mechanisms might be increased after the femoral trial placement with the PF joint repaired, and increased ligament balance in varus. We measured the “joint component gap”, which is remarkably different from conventional gap measurement.

The joint component gap is measured with the femoral component in place, whereas the conventional gap measurement is done between the cut surfaces of the femur and tibia. By keeping the femoral component in place, the knee is afforded a greater degree of extension due to its curving arc. In this arrangement, the posterior condyles of the component tighten the posterior capsule, resulting in a smaller joint gap at full extension. In addition, due to the 7-degree posterior slope of the tibia and a slight femoral anterior bowing, we can consider the “conventional extension gap” to be at about 10 degrees of the knee flexion angle. Mitsuyama et al similarly reported on 80 varus type osteoarthritic knees with the offset-type tensor, that selecting larger size of femoral component as well as the femoral component placement reduced the extension gap. They reported that the placement of femoral component reduced the medial and lateral extension gaps by a mean of 1.0 mm and 0.9 mm, respectively, and medial and lateral gaps further decreased by a mean of 2.1 mm and 2.8 mm, respectively, when a specially made femoral component with a posterior condyle enlarged by 4 mm was tested. Mihalko et al stated that the release of more posterior structures had a greater effect on the extension gap than on the flexion gap in explaining the importance of the relationship between posterior structures and the extension gap in a cadaver study. Sugama et al reported in their operative study that a bone cut from the posterior femoral condyles could change the tension of the posterior soft tissue structures and thus alter the width and shape of the extension gap. These previous reports support the above mechanism.

Clinical Relevance of Intraoperative Soft Tissue Balance Assessment

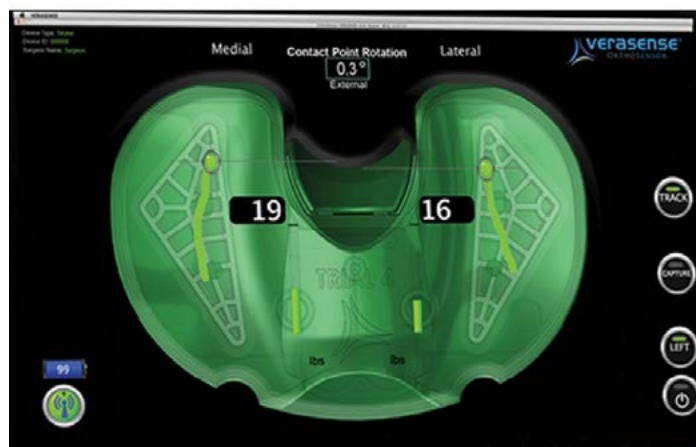
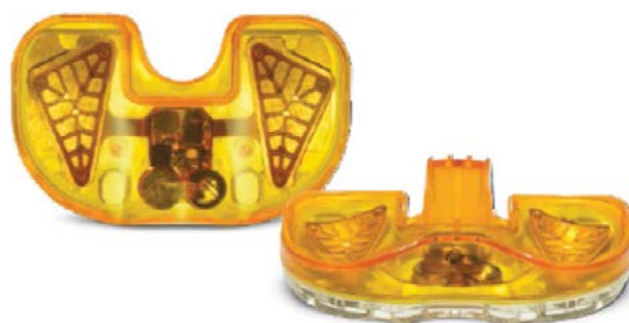Considering clinical significance of intraoperative assessment, we should confirm that intraoperative values assessed with the tensor, reflects the postoperative soft tissue balance. Hence, we investigated the correlation between the intraoperative values assessed with the tensor and the 5-year postoperative values assessed with stress radiographs at extension and flexion. In CR TKA, postoperatively both the joint component gap and ligament balance at extension and flexion showed positive correlations with the intraoperative values of 10 degrees of flexion and 90 degrees of flexion. However, in PS TKA, whereas postoperatively both the joint component gap and ligament balance at extension showed positive correlation with intraoperative values of 10 degrees of flexion, postoperatively neither joint component gap nor ligament balance at flexion showed correlation with that at 90 degrees of flexion.

These results indicate that the intraoperative measurements of soft tissue balance by the tensor reflect postoperative values assessed by the stress radiographs even at the 5-year follow-up.

However, despite existing correlations in extension, there were no correlations in flexion in both the joint component gap and ligament balance between intra and postoperative values in PS TKA. This discrepancy in PS TKA may be caused by flexion instability due to a larger flexion gap compared to extension gap.

Acquisition of high flexion angle after TKA is one of the factors leading to patient satisfaction. Therefore, we focused on the postoperative flexion angle in relation to intraoperative soft tissue balance. In the series of studies in PS TKA, joint gap change value (90-0°) with PF joint reduced, not everted, showed inverse correlation with the postoperative knee flexion angle and posterior condylar offset. However, in another series of studies on CR TKA, the postoperative flexion angle was positively correlated with the joint gap change value (90-0°). In either case, multivariate regression analysis among various values including joint gap change values, ligament balance, and pre-operative knee flexion angle, demonstrated that the preoperative knee flexion angle and the joint gap change value (90-0°) had a significant independent effect on the postoperative knee flexion angle. One of the reasons for this discrepancy may be the different patterns of soft tissue balance between PS and CR TKA. In that report, CR TKA in comparison to PS TKA, showed significantly smaller gaps when the arc of movement ranged from mid-to deep flexion. The posterior cruciate ligament (PCL) in the osteoarthritic knee is considered relatively rigid and shortened, despite being relatively macroscopically intact. When we consider the flexion gap tightness, Ritter et al reported that 30% of CR TKA required ligament balancing to obtain a smooth flexion arc.

If the PCL was too tight, excessive femoral rollback resulted in anterior lift-off of the tibial tray in flexion, leading to limitation of flexion. To improve postoperative flexion, balancing the flexion gap can result in a satisfactory range of motion. In our series of studies on CR TKA, it was identified that 16% more flexion gap tightness (smaller flexion gap than extension gap) resulted in a smaller flexion angle. Similarly, using a commercially available knee balancer with the measurement under 80 N distraction force, Higuchi et al reported that flexion medial/lateral gap tightness led to restriction of the flexion angle. Therefore, in these cases, surgeons are advised to avoid flexion gap tightness by soft tissue release such as PCL.

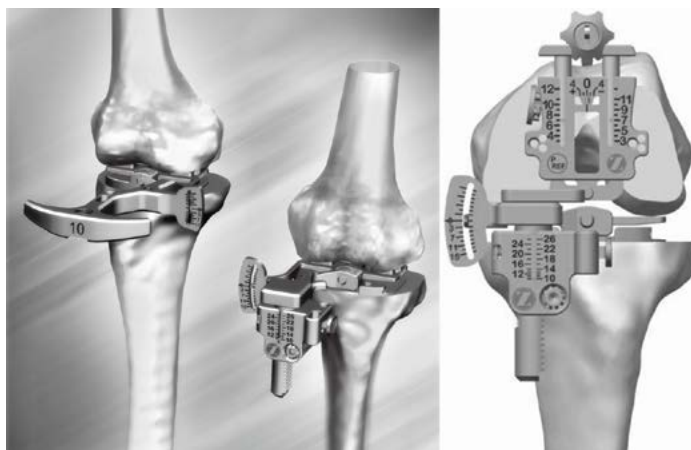


02

- 02 Verasense Knee System (OrthoSensor Inc., Dania Beach, Florida) Verasense Knee System provides two essential profiles; dynamic Femoral Contact Points enabling the surgeon to visualize femoral component rollback and tibial tray rotation to improve tibial-femoral articulation; and Kinetic Tracking™ feature displaying femoral component motion paths in the medial and lateral compartments to enable a full kinetic (force and motion) assessment of knee function.

Soft Tissue Balancing in Total Knee Arthroplasty

Finally, postoperative kinematics such as tibial internal rotation and tibial anterior translation are important to achieve better clinical outcomes including high knee flexion angle. With regard to achieving high flexion after TKA, some studies have emphasized that an increase in postoperative tibial internal rotation is observed during knee flexion. Therefore, we investigated the correlation between intraoperative soft tissue balance assessed by the tensor and postoperative knee kinematics assessed by navigation system following all prostheses implanted. The results confirmed a positive correlation between varus ligament balance and tibial internal rotation, which may indicate that looseness of the lateral compartment in relation to the medial side at 60° and 90° flexion permits rotational mobility and results in increased tibial internal rotation.



03

In fact, the positive correlation between the lateral compartment gap and tibial internal rotation from mid-to-deep knee flexion was a more sensitive factor than the joint component gap, and the fact that there was no relationship between the medial compartment gap and tibial internal rotation supported this result. Moreover, in another study on assessing correlation between intra and postoperative knee flexion angle and knee kinematics, postoperative knee flexion angle as well as preoperative knee flexion angle were significantly correlated to the postoperative tibial internal rotation. In addition, we reported positive correlation between intraoperative lateral laxity at flexion and postoperative flexion angle in CR TKA, indicating that medial stability with appropriate lateral laxity was important for achievement of high flexion angle. Similarly, Kobayashi reported on postoperative stress radiograph, that lateral laxity at flexion (flexion-valgus, 3.4°: flexion-varus, 6.2°) showed positive correlation with postoperative knee flexion angle [30]. These studies are supported by other studies indicating that the flexion gap in healthy knees is not rectangular and that the lateral joint gap is significantly lax. In summary, to reproduce medial pivot motion after TKA, medial stability with moderate lateral laxity during flexion might lead to appropriate tibial internal rotation and result in a high flexion angle.

Perspective

Recent advances in sensor technology have provided surgeons with an easy tool for assessment of intraoperative pressure distribution and femoral contact points on tibial trial insert. OrthoSensor® enables surgeons to assess Kinetic Tracking™ feature (force and motion), displaying femoral component motion paths in the medial and lateral compartments (Fig. 02). Recently, Gustke et al introduced a new assessing system and reported better patient satisfaction rate with balanced knee (94.1%) compared to that with unbalanced knee (82.1%), by using the assessment system; Verasense Knee System (OrthoSensor Inc., Dania Beach, Florida). This assessment tool highlights the measurement condition same as offset-type tensor; PF joint reduction throughout the range of motion. However, whereas the measurement with the sensor is focused on natural knee condition with load distribution on tibial insert, offset-type tensor aims to measure the characteristics of soft tissue envelope with distraction force. Both these two measurement methods are important and might be combined in the future.

The most important aspect in soft tissue balancing is the close interaction between the surgical technique and the assessment, in which surgeons should adjust the surgical technique to attain final soft tissue balance. With the measured resection technique for CR TKA, we recently reported the importance of minimal medial release (osteophyte removal and release of deep layer of medial collateral ligament) for varus-type osteoarthritis to maintain appropriate tibial internal rotation and gain high flexion angle. Recently, offset type tensor has been developed to be used for gap technique as well as measured resection technique during TKA. With this new system FuZion™ (Zimmer, Inc.) (Fig. 03), surgeons can assess and correct soft tissue balance after femoral distal and tibial proximal cut, then adjust femoral rotation based on the tensor measurement, and confirm the final balance throughout the range of motion with the femoral component placement. The information available by the use of the tensor during surgery is useful in a real-time manner and essential for the insight of true postoperative kinematics. It allows the surgeon to adjust the soft tissue balance more accurately and thereby expect a better postoperative outcome.

Considering successful clinical outcomes, accurate osteotomy/implantation and soft tissue balancing are essential in TKA. Appropriate bone cut and prosthetic implantation have improved due to advances in surgical instrumentations such as the computer-assisted navigation system, preoperative image-matching technique, or patient-specific instrumentation. Similarly, appropriate soft tissue balancing has become more important than before. With the recent advances in this field described here, improvement of patient satisfaction after TKA is expected in the near future.

- 03 FuZion™ Instrument (Zimmer, Inc.)
The FuZion Instruments are based on two platforms: the FuZion Spacer Block and FuZion Tensor, and were specifically designed to provide crossover utility, harmonizing measured resection and gap balancing philosophies.

Teaching Center Fellowship Report

Vitor Barion Padua, MD BRAZIL

I am an orthopedic surgeon, specialist in knee surgery and sports trauma, in Marilia-SP Brazil, and was selected to participate in the ISAKOS Teaching Center fellowship. I chose to visit the service of Prof. Romain Seil in Luxembourg, and Prof. Andreas Imhof in Munich. In Luxembourg I followed the service for a week, having participated in several surgeries such as unicompartmental knee prosthesis, rotated cuff revision and knee arthroscopy with trans-septal via.

Prof. Romain, was very attentive, explaining to me details of the procedures and always open for discussion.

I also followed the rehabilitation service, focused on muscle gain and proprioception, with periodic evaluations, and specific methods of instability evaluation such as Genourob, performed by a well-trained staff, not allowing patients to return to full sporting activities before fully recovered.

Something very interesting was the LCA pathway, where there is a framework for collecting all data of patients with ACL injury, treated surgically or not, and the operative data of each patient undergoing reconstruction. And how they manage the largest number of patient at follow-up.



At the end of the week I had the chance to participate in the third Osteotomy Congress of Luxembourg, which were present various world references in this topic, which was really very nice.

In Munich I accompanied Prof. Imhof in a surgical day, and saw some osteotomies, where we could discuss from the indications, surgical techniques and the newest materials. He was always very attentive, making sure I could follow every detail of the procedures.

I would like to thank ISAKOS for the opportunity to participate in the ISAKOS Teaching Center fellowship, where I had the opportunity to meet two services with two reference Teachers in Europe and in the world. These surely did greatly enrich my knowledge what will help me a lot in my daily practice.

My ISAKOS Center Fellowship to Hospital for Special Surgery, USA

Hatem Galal Z. Said, MD, FRCS EGYPT

I was very pleased to revive the news of my awarding the ISAKOS visiting Centre fellowship. I specialize in Hip arthroscopy, and had planned to visit Dr. Bryan Kelly in the Hospital for Special Surgery in New York. Dr. Kelly is well known in the field of Hip arthroscopy with many publications, while HSS is among the top Orthopaedic Hospitals in the US. I had contacted Lisa who had kindly arranged the technical paperwork and the dates on short notice.

I attended four days, in which I got the chance to attend two OR days with Dr. Kelly. He utilizes two staggered ORs which allows a rapid turnover between surgeries. I enjoyed watching Dr. Kelly perform Hip Arthroscopy through Central access first.

One important point was reproducibility in the setup, traction, portals and surgical steps – this reduced the surgical time, and facilitated the team work flow. I also attended a day of clinic, in which I had very thoughtful discussions with the Physiotherapist Todd, who had confirmed the importance of the team approach and assessment of the patients with hip pathologies.



01

The focus on analyzing individual hip muscle dysfunctions and directed strengthening or stretching is of utmost importance. At the same day, I visited a small Cadaver dissection session with the fellows who were training on Peri-acetabular osteotomy.

I appreciate very much the opportunity which allowed me to get exposure this great hospital and surgery. I have learned new tips which I will apply in my Arthroscopic Hip Surgery, and hope to benefit my patients further.

01 Photo Hatem Said with Dr. Bryan Kelly in HSS, NY

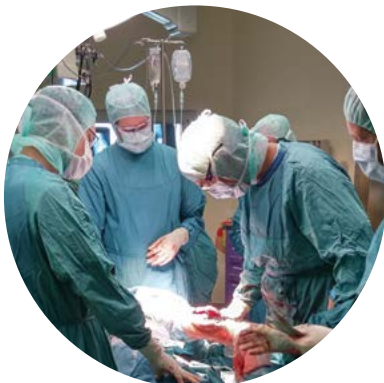Haris S. Vasiliadis, MD, PhD SWITZERLAND

Quite a long time ago I had applied for the ISAKOS Teaching Center Scholarship. Since then, I had the luck and pleasure to go through several changes both in my professional but also in my private life. Just at this time, quite unexpectedly, I received this email from the Director of Education of the ISAKOS, Mrs. Anderson announcing the great news to me, that I won the fellowship. This was an additional success adding to my happiness, as it came just a few days after the birth of my daughter.

The only bad thing... I was too busy at this time to plan anything soon. I had to choose between the 50 ISAKOS approved training centers worldwide and to arrange the visit within this year. Vienna was from the first time in my mind, along with another couple of centers. At this time-point it seemed to be the most suitable for me. This is always difficult to decide, when you have the option to choose by yourself. There are so many good centers, with good friends in some of them, but unfortunately you must choose just one.

So, the first contact with Dr. Müllner from Evangelisches Krankenhaus in Wien came, after the very kind introduction of Mrs. Anderson. This was actually a quite short notice to Dr. Müllner, just a few weeks before the visit, but I feel very lucky and very grateful that he responded positively. Obviously there was not so much time left for him to perfectly organize a special training surgical schedule, which he clarified from the first moment. But as I found out later, there was no need for that. The usual daily surgical schedule was already perfect enough to provide a spherical training and education to a visitor.

After a short email exchange, everything was fixed and perfectly planned, and my visit to Wien on 7 September was completely arranged.



I arrived in the lovely city one day earlier, with a perfect sunny weather and looking forward to the upcoming few days. I have been there several times in the past, for congresses or just tourism, but Wien is never boring. This is always a great pleasure, and this time even more, as the cause of this journey is to visit a well-known medical center of the city. The plan is to spend some time in the Orthopaedic department and mainly to attend Dr. Müllner, to experience the every day surgical schedule and to learn by participating in a variety of surgeries of the knee and not only. And the beginning of this experience would take place early next morning.

I slept early night reading once again the email with the directions I had recently received from the "Sekretariat Kollegiale Führung" of the hospital, Mrs. Caldwell.

So, the first official day of the fellowship started the next day, Monday early morning, by meeting the lovely and always very kind and helpful Mrs. Caldwell at the reception of the Evangelisches Krankenhaus. I had to pass through all the necessary bureaucratic procedures first (like providing the MRSA negative result, filling paperwork, taking the medical clothes for my stay and also the keys for my locker). Then I was ready to be transferred to the clinic and be introduced to the orthopedic team.

We found the whole group in the doctors' room just in time to start the morning rounds. My impression was very positive even from the first moment. Everybody was kind, smiley and happy to discuss with me and answer to all my possible questions either regarding the Hospital and its function or of orthopaedic interest. Dr. Pongracz was the first to receive me from Mrs. Caldwell and he introduced me to the rest of the group. I had the pleasure also to meet Dr. Nikolakis and the rest of the staff. I followed the rounds with them and then received an introductory guide to the hospital premises by Dr. Pongracz, which was absolutely kind and helpful.

After a short tour, we moved to the OR, where the surgeries were about to start. My surgical experience in Wien started with a TKA performed with navigation system. In the schedule was also a THA, with AL approach, which to my pleasure I also attended. A bit later in the morning I met Dr. Müllner, the head of the Department and my main host in this fellowship visit. We had a very warm discussion and we made a brief schedule for the next days. At the end of the daily schedule, my day continued with the evening surgeries of external coworkers of the hospital, which was also very interesting to follow.

The next days my main host Dr. Müllner had also surgeries, and most of my surgical time was spend with him. In total I had the chance to participate in a wide range of cases of the lower limb. This included also a number of hip replacements performed with A and AL approaches although knee surgeries were of course my first priority. So knee replacements, primary but also revisions and of course arthroscopic knee surgeries. The latter included of course ACL reconstructions, primary but also revision cases.

It was a very useful experience to attend all these surgeries and to observe how the group of Dr. Müllner and his colleagues work. What it was also very helpful was the discussions during, between and after the surgeries, with many questions being answered and many ideas being discussed.

Although my stay was limited to only one week, I was lucky enough that a knee symposium was taking place at the last day of my visit in Wien. It was focusing on knee replacements in total, with talks and discussions covering the whole range, from the choice of the right implant to revisions and to potential complications like infections. This contributed a lot to the knowledge I claimed from this fellowship, as a number of knee experts of the surrounding areas and countries were participating, sharing their experience and been exposed to discussions and questions from the audience. This was a very interactive meeting in a very nice area of the city.



A visitor to Wien should of course try to find some free time to live a part of the Viennese atmosphere. Some evening walks in the wonderful city center and meeting a couple of old good friends was unfortunately the only thing I managed to do during my stay. What I definitely missed was to visit some of the wonderful museums of Wien, which I plan to do on my next (hopefully soon) visit. Of course having dinner in some of the numerous local restaurants with good Viennese food was also one of the things I enjoyed a lot.

To my disappointment, the time to leave Wien was almost over, despite that I was sure that I would have many more things to learn. Thankfully I have already received the confirmation from Dr. Müllner that I will be always welcome at any time in the future.


I am really very grateful to ISAKOS and especially to Dr. Joao Espregueira-Mendes, the ISAKOS Education Committee Chair for the chance he provided me. I am also grateful to Dr. Müllner and his colleagues for the very nice experience I had during my visit in Wien.

ISAKOS PUBLICATIONS



Full Access in myISAKOS

ISAKOS Members can access all official ISAKOS Publications through myPublications in myISAKOS—including *Journal of ISAKOS*!



www.isakos.com/myISAKOS

International Elbow Course

3–5 December, 2015

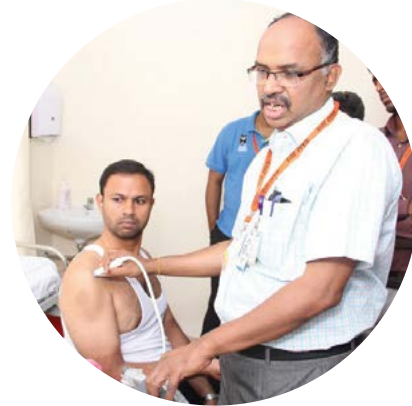Arezzo, Italy

Under the patronage of ESSKA, SICSeG, ISAKOS an International Elbow Course was held at the ICLO Teaching and Research Center – St. Francis de Sales, housed within the Nicola's Foundation in Arezzo (via A. Einstein, 12). The faculty was composed by Italian and European surgeons, members of the Elbow and Wrist Committee of the ESSKA, chaired by L. A. Pederzini. The Italian ones were Renzo Angeloni (Florence), Paolo Angelo Arrigoni (Milan), Davide Blonna (Turin), Andrea Celli (Modena),

Alessandra Colozza (Faenza), Felice Di Palma (Sassuolo), Maurizio Fontana (Faenza), Giuseppe Giannicola (Rome), Enrico Guerra (Bologna), Alessandro Marinelli (Bologna), Luigi Adriano Pederzini (Sassuolo), Giuseppe Porcellini (Cattolica), Roberto Rotini (Bologna), Pierluigi Tos (Turin). The international faculty included Mehmet Demirtas (Turkey), Emilio Lopez Vidriero (Spain), Nuno Sevivas (Portugal), Roger Van Riet (Belgium), Alexander Van Tongel (Belgium).

On December 3, the faculty was involved in a close meeting, working all day in a section on three elbow specimens. On one of them they studied how elbow instability developed after progressively cutting primary elbow stabilizers from lateral to medial. On the second elbow, cutting primary elbow stabilizers from medial to lateral. On the third limb different patterns of instability development were studied.

In the evening the faculty met participants for dinner at a local restaurant in the center of Arezzo. The participants came from different Countries as Giordania, Russia, Egypt and South America.



The following day, the faculty members gave their presentations covering important elbow topics from arthroscopic procedures, instability and prosthesis.

After each section there was a cadaver lab where the participants could practice what they learned. Every two participants had their own workstation where they could learn arthroscopic and open procedures with one of the faculty member as tutor.

In the evening everybody met again for dinner where students had the opportunity to get to know faculty members and to clarify any doubts about the cadaver lab.

On the last day, the course began with other presentations followed by a cadaver lab.

These three days of intense research and discussions were very interesting and informative for everybody who attended. Strong friendships were built and all the participants were happy to learn important things to apply to their job in order to progress. It was an important professional, cultural and social moment.

We are deeply thankful to the sponsor of the scientific segments of this course, to ESSKA, SICSeG and ISAKOS, our unbelievable hosts and all the people who made this meeting possible.



IEAAF 2015 Course

3–5 July, 2015

Chennai, India

The Indo-European Arthroscopy & Arthroplasty Foundation conducted its 7th Annual Conference at Sri Ramachandra University, Chennai in July 2015. The theme of the conference was “Advance Knee Arthroscopy, Wrist & Elbow Arthroscopy & Sports Sciences.” It was a well-attended event with around 249 delegates and notable faculty from around the world.

The conference included:

- Live Arthroscopic surgical demonstration with interactive session
- Didactic lectures on Arthroscopy and Sports Sciences
- Advance hands on cadaver knee Arthroscopy workshop
- Prof. S.S.K. Marthandam gold medal, scientific paper session
- Included rehabilitation symposium, advance sports sciences and USG workshops

International Faculty of the program included Prof. Alex Fievez (Netherlands), Dr. Jonathan Herald (Australia), Prof. Demeritus (Turkey), Prof. Tim Noakes (South Africa). National Faculty of the program included Prof. S. Arumugam, Dr. Sachin Tapasvi, Dr. K.N. Subramanian, Dr. S.R. Sundararajan, Dr. Raju Eswaran, Dr. Kiran Acharya, Dr. I.P.S. Oberoi, Dr. Roshan Wade, Dr. Vijay Shetty, and Dr. B. Bhupesh Karthik

The conference ended on high note with much appreciation and positive feedback from the delegates and faculty.

ISAKOS Members Now Receive Full Access to OrthoEvidence

ISAKOS/OrthoEvidence Portal

OrthoEvidence's database has more than 3,400 evidence-based summaries from more than 360 journals of the highest-quality research in orthopaedics.

1

Log in to myISAKOS at www.isakos.com/myISAKOS

myISAKOS

2

Click on myPublications in the myISAKOS Dashboard



3

Click “Access” the ISAKOS / OrthoEvidence Portal

Access

OE ORTHOEVIDENCE⁺

in partnership with



International Sports Medicine Fellows Conference

Karolina Stępień, MD POLAND

In January 2016, I had a great opportunity to attend the International Sports Medicine Fellowship Conference held in Carlsbad, California. I felt especially awarded because I was the youngest fellow sent to this event by ISAKOS!

I had a long fifteen-hour flight from Poland, but it was worth it. Being a part of this event provided me with a lot of theoretical and practical information about orthopaedic surgery. The Conference was focused on two main subjects: articular cartilage repair and hip arthroscopy. Articular cartilage repair is one of most important in orthopaedic surgery – every day I meet patients with this kind of problem. Lectures and surgical skill labs were very useful and helpful for my practice. In turn, issues with hip arthroscopy were so interesting because the number of doctors who do this kind of procedure and patients that undergo these operations are still growing in my country. It is not so common like knee arthroscopy but it still develops.

Organization of the Conference was at a high level – the lectures and labs were prepared perfectly. The faculty were very helpful and gave us a chance to discuss and ask questions.

One of the most interesting things was a possibility to compare our way of work with people from other countries. We have different groups of patients, different tools and, of course, different experiences. It gave me a new, fresh look on orthopaedic surgery.

ISAKOS gives amazing possibilities for young fellows – you really should take advantage of this!



2015 ISAKOS Congress Content and Videos

Available on Global Link

Videos and papers from the **2015 ISAKOS Congress** in Lyon, France are **LIVE** on ISAKOS Global Link

2015 Congress Surgical Demo Video Courses – Coming Soon!

ISAKOS global link

isakos.com/GlobalLink

Nice Shoulder Course
Hyatt Regency Nice Palais de la Méditerranée
Nice, FRANCE

May 2–4, 2016

Chair(s): Pascal Boileau, MD

For further information, please contact:

FREGEAC
Tel: +33 4 92 03 64 97
Fax: +33 4 92 06 61 31
fregeac.a@chu-nice.fr

4th Biennial Congress of Iranian Society of Knee Surgery, Arthroscopy & Sport Traumatology
International Convention Center, Milad Tower
Tehran, IRAN

May 17–20, 2016

Chair(s): Dr. Javad Parvizi

For further information, please contact:

Keivan Ahadi
Tel: 009 82188777176, 009 82188782322
Fax: 009 82188777176
www.ISKAST2016.com

2016 AMECRA Annual Meeting
Centro de Convenciones Siglo XXI
Merida, MEXICO

May 25–28, 2016

Chair(s): Michell Ruiz-Suarez MD, PhD

For further information, please contact:

Michell Ruiz-Suarez
Tel: +521 55 54311206
Fax: +525 555646000
www.amecra.org.mx

VII SLARD Congress–Argentina 2016
Buenos Aires Hilton Hotel
Buenos Aires, ARGENTINA

June 1–4, 2016

Chair(s): Claudio Mingo, MD, Guillermo Allende MD, Guillermo Arce MD

For further information, please contact:

Guillermo Arce
Tel: +54911 5 4058200
Fax: +5411 4 9656500 interno 5047
www.slard.org

2016 Congress of APKASS & The 13th International Forum of Orthopaedic Sports Medicine and Arthroscopic Surgery
Jockey Club School of Public Health, Prince of Wales Hospital
Hong Kong

June 9–12, 2016

Chair(s): Dr. Patrick Shu-Hang Yung

For further information, please contact:

Shiyi Chen
Tel: +852 2144 5016
Fax: +852 2646 3020
www.apkass.org/2016congress/index.php

2016 APKASS Congress & the 13th IFOSMA
Prince of Wales Hospital
Hong Kong

June 10–12, 2016

Chair(s): Shiyi Chen

For further information, please contact:

Gina Wong
Tel: +852 2144 5016
Fax: +852 2646 3020
www.apkass.org/2016congress/abstractguide.php

International Extreme Sports Medicine Congress

St. Julien Hotel & Spa
Boulder, CO USA

June 10–11, 2016

Chair(s): Dr. Omer Mei-Dan

For further information, please contact:

Omer Mei-Dan
Tel: +1 720-400-3833
Fax: 303 724 1593
www.ucdenver.edu/academics/colleges/medicine/sportsmed/cusm_events/2014-Extreme-Sports-Medicine-Congress/Pages/default.as

IMUKA 2016 Transatlantic Current Concepts in Outpatient Arthroplasty

van der Valk Congress Center Maastricht
Maastricht, NETHERLANDS

June 16–17, 2016

Chair(s): N.P. Kort, MD, PhD

For further information, please contact:

Mascha van der Meijden
Tel: 31-6-14867358
Fax: 31-46-4490146
www.imuka.eu

16th Amsterdam Foot and Ankle Course
Amsterdam Medical Center
Amsterdam, NETHERLANDS

June 22–23, 2016

Chair(s): Prof. Dr. C.N. van Dijk

For further information, please contact:

G. Vuurberg
Tel: +31(0)20 566 2474
Fax: 00 31 20 566 9117
www.ankleplatform.com

2nd Advanced Foot and Ankle Course
Academic Medical Centre
Amsterdam, NETHERLANDS

June 23–24, 2016

Chair(s): Prof. Dr. C.N. van Dijk

For further information, please contact:

G. Vuurberg
Tel: +31 (0)20 566 2474
Fax: 00 31 20 566 9117
www.ankleplatform.com

8th International Meeting of Arthroscopic Surgery

Los Delfines Hotel
Lima, PERU

June 29–July 1, 2016

Chair(s): José Luis Guzmán, MD

For further information, please contact:

Alfonso Barnechea
Tel: (+51)997635502
http://www.spotrauma.org/?q=node/303

Advanced Instructional Courses on Arthroscopy and Arthroplasty
University Medical Centre
Utrecht, NETHERLANDS

July 4–8, 2016

Chair(s): W.J. Willems, MD

For further information, please contact:

F. Hanselaar
Tel: + 31 30 276 9174
Fax: + 31 30 276 9251
www.shoulder-elbow-knee.nl

Joelho Degenerativo no Jovem–The Young Arthritic Knee
Royal Palm Plaza
Campinas, BRAZIL

August 25–27, 2016

Chair(s): Wilson Mello

For further information, please contact:

Vitor Padua
Tel: 55 14 991239932
Fax: 55 14 34549326
www.drvtitorpadua.com

17èmes Journées Lyonnaises de Chirurgie du Genou–The ACL
Convention Centre
Lyon, FRANCE

September 22–24, 2016

Chair(s): Professor Elvire Servien

For further information, please contact:

Audrey Martin
Tel: 33 (0) 495 09 38 00
Fax: 33 (0) 495 093 801
www.lyon-knee-surgery.com

13th ICRS World Congress
Hilton Sorrento Palace
Sorrento, ITALY

September 24–27, 2016

Chair(s): William Bugbee, Henning Madry

For further information, please contact:

International Cartilage Repair Society
Tel: 0041 44 503 73 70
Fax: 00 41 44 503 73 72
cartilage.org/13th-icrs-world-congress/contact/

6th National Congress SIGASCOT 2016
Congress Venue Palazzo dei Congressi
Florence, ITALY

September 28–30, 2016

Chair(s): Pietro Randelli, Luigi Pederzini

For further information, please contact:

Nives Sagramola
Tel: 0039 055 2399112
Cell: 0039 338 3837991
Fax: 0039 055 4641490
www.sigascot.com

Knee & Ankle Current Concept
Hotel Park Inn by Radisson
Krakow, POLAND

October 7–8, 2016

Chair(s): Boguslaw Sadlik MD, PhD

For further information, please contact:

Ewa Maza
Tel: +485 00096778
Fax: +483 38273634
www.ortopedia2016.pl

3rd Birmingham Patellofemoral Masterclass
The Queen Elizabeth University Hospital
Birmingham, UNITED KINGDOM

October 28–29, 2016

Chair(s): Tanweer Ashraf

For further information, please contact:

David Penford
Tel: +44(0)1476860759
Fax: +44(0)1476860843
www.birminghampatfem.org

UPCOMING ISAKOS APPROVED COURSES

ISKSAA Global Summit 2016
Leela Ambience Hotel
Delhi, INDIA

November 20–23, 2016

Chair(s): Dr. Pushpinder Bajaj

For further information, please contact:

Dr. Pushpinder Bajaj
Tel: 00919811056525
Fax: 00911141057558
isksaa.com/isksaa2016/index.php

XIII Turkish Sports Traumatology, Arthroscopy
and Knee Surgery Congress
Wyndham Grand Istanbul Levent
Istanbul, TURKEY

November 22–26, 2016

Chair(s): Prof. Mehmet Asik MD

For further information, please contact:

Banu Ucar
Tel: 009 05335905525
Fax: 009 02122586078
tusyadistanbul2016.org/en/

4st Theoretical and Practical course of
SIGASCOT on Patellofemoral Surgery
Combined Meeting SIGASCOT IPSPG
Salone D'Onore Palazzo Del Coni
Rome, ITALY

December 2–3, 2016

Chair(s): Alfredo Schiavone Panni,
Giuseppe Milano

For further information, please contact:

Nives Sagramola
Tel: 0039 338 3837991
Fax: FAX: +39 055 4641490
www.sigascot.com

2017 International Sports Medicine Fellows
Conference
Sheraton Carlsbad Resort & Spa
Carlsbad, CA USA

January 20–22, 2017

Chair(s): Bert Mandelbaum, MD

For further information, please contact:

ISMF Course Office
Tel: 925-807-1190
Fax: 925-807-1199
www.ismf-conference.com

Is your Course an...

ISAKOS
Approved-Course

www.isakos.com/meetings

Become an ISAKOS Godfather!

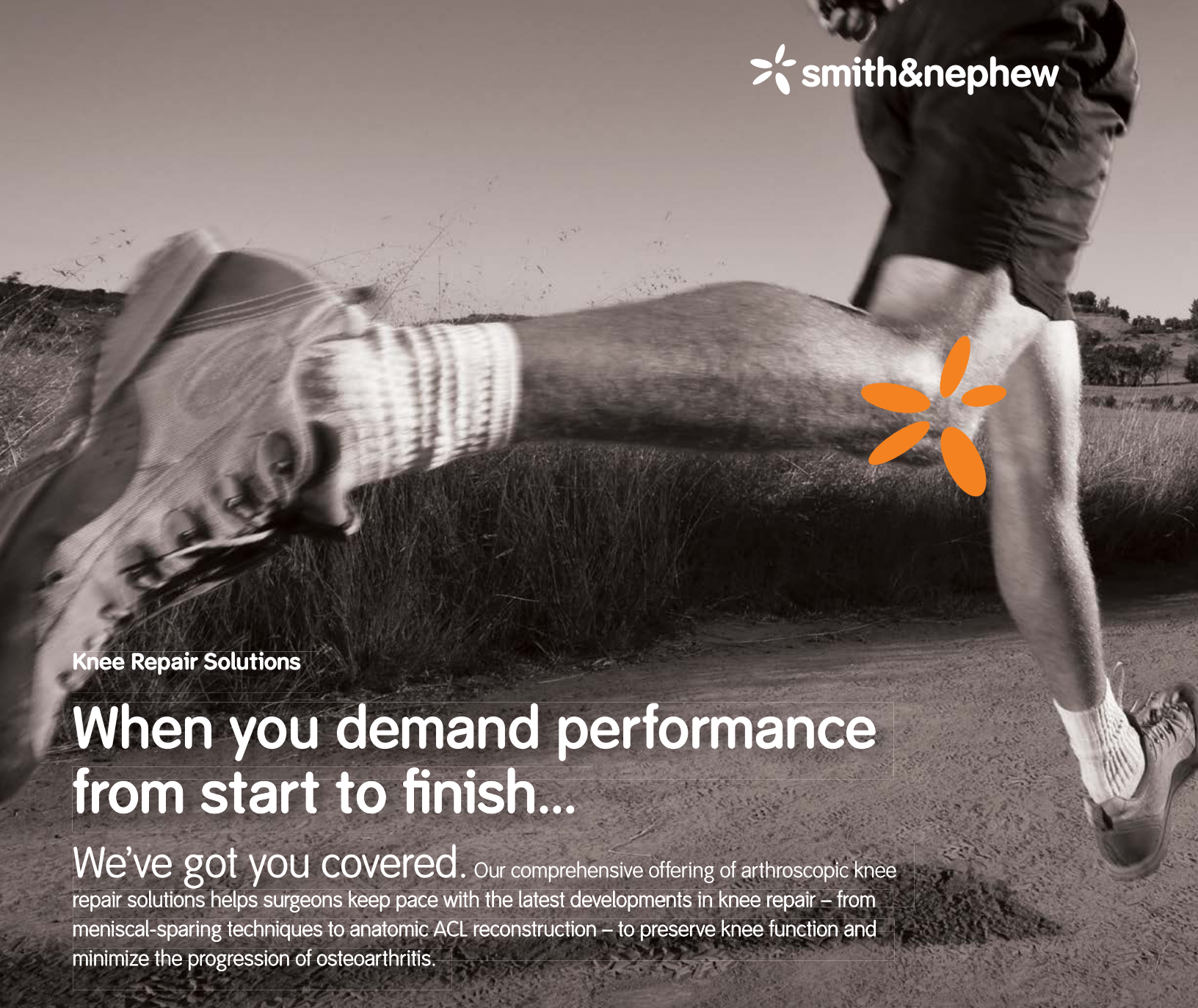The ISAKOS Godfather Initiative was created to provide high quality, educational programs and resources to deserving individuals worldwide.

A portion of your pledge would be allocated toward 5-year ISAKOS membership for a deserving individual from a developing region.

MAKE A DONATION

Today at www.isakos.com/campaign





Knee Repair Solutions

When you demand performance from start to finish...

We've got you covered. Our comprehensive offering of arthroscopic knee repair solutions helps surgeons keep pace with the latest developments in knee repair – from meniscal-sparing techniques to anatomic ACL reconstruction – to preserve knee function and minimize the progression of osteoarthritis.

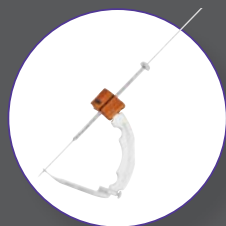
To learn more about our complete knee solutions, go to www.smith-nephew.com, contact your Smith & Nephew sales representative or call +1 800 343 5717.

Comprehensive product offerings for your next knee repair.

TRUKOR®
Depth Gauge



ACUFEX® PINPOINT
Anatomic ACL Guide System



CLANCY™ ANATOMIC CRUCIATE GUIDE
Flexible Drill System



ENDOBUTTON® CL ULTRA
Fixation Device




FAST-FIX® 360
Meniscal Repair System





International Society of Arthroscopy,
Knee Surgery and Orthopaedic Sports Medicine
2410 Camino Ramon, Suite 215
San Ramon, CA 94583-4318 USA

Telephone: +1 925 807-1197
Fax: +1 925 807-1199
isakos@isakos.com
www.isakos.com



11TH BIENNIAL

ISAKOS CONGRESS

JUNE 4-8, 2017 | SHANGHAI, CHINA

CALL FOR ABSTRACTS

ABSTRACT SUBMISSION DEADLINE

SEPTEMBER 1, 2016

isakos.com/2017congress

