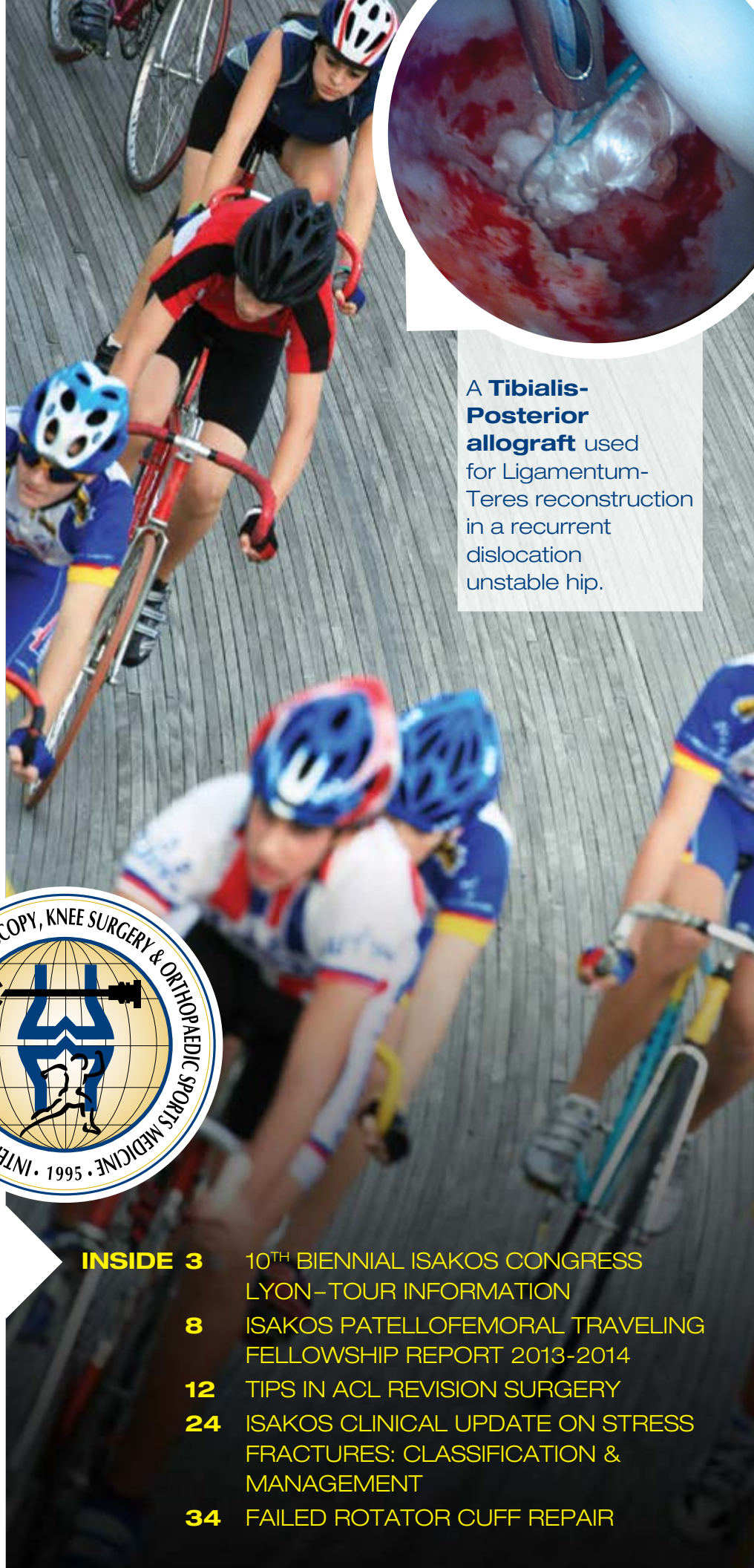


# ISAKOS

## ISAKOS NEWSLETTER 2015 • VOLUME I

Current Concepts on Arthroscopy, Knee Surgery & Orthopaedic Sports Medicine



A **Tibialis-Posterior allograft** used for Ligamentum-Teres reconstruction in a recurrent dislocation unstable hip.

- INSIDE 3** 10<sup>TH</sup> BIENNIAL ISAKOS CONGRESS LYON-TOUR INFORMATION
- 8** ISAKOS PATELLOFEMORAL TRAVELING FELLOWSHIP REPORT 2013-2014
- 12** TIPS IN ACL REVISION SURGERY
- 24** ISAKOS CLINICAL UPDATE ON STRESS FRACTURES: CLASSIFICATION & MANAGEMENT
- 34** FAILED ROTATOR CUFF REPAIR

# in this issue

Editor's Message . . . . .	1
President's Message . . . . .	2
2015 Congress: Explore Lyon . . . . .	3
Lifestyle: Traveling Fellowship Report . . . . .	8
Pearls & Pitfalls – Surgical Technique . . . . .	10
ISAKOS Asks . . . . .	17
Research Report: Pivot Study Group . . . . .	21
Current Concepts . . . . .	22
In a Nutshell . . . . .	40
Approved Course Reports . . . . .	42
ISAKOS Asks, You Answered . . . . .	42
Upcoming Approved Courses . . . . .	50
Nominating Procedure: 2 <sup>nd</sup> Vice President . . . . .	52
Sports Medicine Injection Survey Info. . . . .	52

## EDITOR

Omer Mei-Dan, MD, USA

## EDITORIAL BOARD

Nadim Aslam, FRCS Orth, UNITED KINGDOM  
Mandeep S. Dhillon, Prof., MS, FAMS, INDIA  
Lucio S. R. Ernlund, MD, MSc, BRAZIL  
Norimasa Nakamura, MD, PhD, JAPAN  
David Sadigursky, MD, BRAZIL  
Gonzalo Samitier, MD, PhD, USA  
Daniel A. Slullitel, MD, Prof., ARGENTINA  
Luis Alberto Vargas, MD, USA  
James H. Lubowitz, MD, USA, Past Editor



**International Society of  
Arthroscopy, Knee Surgery and  
Orthopaedic Sports Medicine**

2410 Camino Ramon, Suite 215  
San Ramon, CA 94583-4318 USA

Telephone: +1 925 807-1197  
Fax: +1 925 807-1199  
Email: [isakos@isakos.com](mailto:isakos@isakos.com)

## The Countdown is On!

Less than four months remain before the ISAKOS Biennial Congress in Lyon! Preparations continue for the ISAKOS Congress, and the celebration of ISAKOS 20th Anniversary. More than 500 faculty and presenter invitations have been sent for the more than 1,000 different presentations that will be held over the six days of the ISAKOS Congress.


ISAKOS would like to take a moment to congratulate the authors of the 200 scientific papers and more than 700 electronic posters that were accepted for presentation. More than 2,300 abstracts were received – special thanks are owed to our hardworking committee members for their tireless review of Congress abstracts! ISAKOS Awards review is currently ongoing and an announcement of the winners will be made in late March – stay tuned!

Have you seen the Pre-Course agendas? Three concurrent pre-courses will be offered on Saturday, June 6th, including two surgical skills pre-courses, and a partnership event with FIFA. In our second official collaboration with FIFA, ISAKOS is thrilled to announce the *ISAKOS & FIFA Pre-Course: Challenges in Safety and Health in Football 2015*. This pre-course includes the top team physicians involved in the treatment of soccer/football players, and will have a special focus on the treatment of players during the World Cup. Our two surgical skills pre-courses will focus on the Knee and Shoulder – *Advances in the Management of Knee Pathology: ACL, Meniscus, Patellofemoral, Osteotomy, and Chondral Pathology* and *International Update on Surgical Controversies of the Shoulder*. Both these pre-courses will include a half day of surgical skills demonstration and a half day of didactic sessions and surgical videos. These pre-course offerings are a great way to start your ISAKOS Congress experience, and provide a more intimate educational experience – we hope you will join us!

The ISAKOS Congress will be held over five days, and will involve a variety of topics ranging from treatment of ACL injuries, to the rotator cuff, biologics and cutting edge technology, to the treatment of the athlete, to injuries of the foot, ankle, hip, wrist, elbow. Instructional courses, symposia, debates, featured lectures, and live surgical demonstrations will provide a variety of educational options for our attendees. To plan your Congress experience, we encourage you to visit the ISAKOS Congress Interactive Agenda, featuring up to the moment information, handouts and more.

Registration is open now, as well as hotel and tour reservations! For more information, please refer to the Congress portion of the ISAKOS Website.

We hope to see you in Lyon!



Two years have passed at the speed of light, since our last ISAKOS meeting in Toronto, and we are only a few months away from our upcoming 10<sup>th</sup> Biennial meeting in Lyon, France. Twenty years... two decades of enormous and constant growth.

The time of the year, the great weather, the outstanding history and neighboring cities and countries, with all they have to offer, turn this meeting into a great all-family destination and trip opportunity. Whether you are a fan of amazing food, an urban history enthusiast, or a nature geek, Lyon has something to offer you, from hundreds of years of well curved and designed alleys to the French Alps' sheer peaks. Check out the Tourism Profile on Lyon on page 4 to get some ideas as you prepare for your trip.

In the previous issue of the Newsletter we asked our members what is the best retirement age for an orthopaedic surgeon, assuming most of us would see themselves operating for their entire life. It was not surprising then, that more than 50% of respondents felt that the ideal retirement age was between 66 and 75 years old. 8% of respondents don't plan to ever retire, with less than 6% planning to retire before age 55. We, forever, will feel young, and keep on learning, even the basics that we sometimes forget. Tune in to "In a Nutshell" to refresh your memory with some plain and simple aspects of our work, things that we usually don't pay attention to.

Also interesting from our Summer Newsletter Poll was our members' opinions on the best way to stay current on information related to arthroscopy, orthopaedics and sports medicine. 40% felt that reading papers on a monthly basis was the best, while 43% felt they learned most by attending and teaching cadaver labs and hands-on workshops; and 32% like to attend annual meetings. Thankfully, ISAKOS has something to offer for all the ways our members like to learn! Stay tuned for more information on upcoming hands-on courses near you.


Being an internationally diverse and dynamic association enables us to gather data, learn and share experiences across countries and continents. This data can facilitate improvement and help us treat our patients better. Different people, different cultures, different training regimens, tend to generate different perspectives, and ways to do things to solve problems. Sharing these differences and working in synergy yields optimal results! One of ISAKOS' current collaborative efforts, led by the Orthopaedic Sports Medicine Committee, tries to understand better our daily utilization of injections—one of the most common procedures we perform routinely without giving it much thought. Please see page 52.

We hope this Newsletter delivers a combination of new perspectives on technical tips, current concepts and some basic science to flavor it all up. We tried wrapping it all up as visually as possible, so you can sip us up with your morning coffee.

I look forward to seeing you in Lyon!

**Omer Mei-Dan**

ISAKOS Newsletter Editor







### A Sincere Thank You

As my time as ISAKOS President draws to a close, I would like to take this moment to thank the membership of ISAKOS for their support. More specifically, thanks are owed to the ISAKOS Executive Committee for their diligence and dedication to making ISAKOS the worldwide powerhouse we have become. These men and women are not only fantastic surgeons who are pioneers in their fields, but great friends and I have greatly enjoyed working closely with them for my presidential term.

Over the last few weeks, I have taken more than a few moments to reflect on my time as part of the ISAKOS Presidential Line. Following my appointment as Second Vice President at the 7th Biennial ISAKOS Congress in Osaka, Japan in 2009, ISAKOS has made fantastic strides. The introduction of the ISAKOS Global Link, our online learning platform, has been a particular source of pride. ISAKOS has helped to forward research in our field with the three recipients of the ISAKOS & OREF Global Research Grants, with each grant involving more than two centers on two continents, and continuing to strengthen the bonds of friendship cultivated by our wonderful fraternity of surgeons around the world. ISAKOS has gone into the field to hold courses in India, China, Brazil, and Indonesia, as well as strengthening our Approved Course process and Teaching Centers. We have experienced two incredibly successful ISAKOS Congresses in Rio de Janeiro, Brazil in 2011, and Toronto, Canada in 2013. We have published multiple booklets and even some textbooks for the reference and continuing education of our membership. These are all accomplishments that could not have been completed without our strong committee leaders, and the support of the ISAKOS Office.

My predecessors have said that we stand on the shoulders of giants, and that is especially true of the office of ISAKOS President. Dr. John Bergfeld, Dr. Freddie Fu and Dr. Moises Cohen have been fantastic mentors to me as I took on this momentous job. Trying to satisfy the educational needs of our diverse population is a constant challenge, but it is my belief that this group thrives on providing not only quality science, but information ranging from basic topics to advanced techniques. We are strong because we are diverse!

I leave you in the very capable and caring hands of our incoming Presidents—Dr. Philippe Neyret, ISAKOS President 2015–2017, and Dr. Marc Safran, ISAKOS President 2017–2019. It is my firm belief that they will continue to guide and improve on the strong history and traditions of this great organization, while also driving forward to employ the newest cutting edge technology to best serve our community.

I thank you for your support and look forward to the next 20 years of ISAKOS!

#### Masahiro Kurosaka, MD, Japan

ISAKOS President 2013–2015



01 ISAKOS Presidential Line  
G. Poehling, R. Jakob, B. Tietjens,  
P. Renstrom, J. Bergfeld, F. Fu,  
M. Cohen, M. Kurosaka

01



10TH Biennial

# ISAKOS 2015

JUNE 7-11, 2015  LYON, FRANCE







## *Explore Beautiful Lyon, France!*

ISAKOS has arranged for Congress attendees and their guests to have the opportunity to register for tours in Lyon and the surrounding areas during Congress! Please visit the Hotels & Tours page on the 2015 Congress website at [www.isakos.com/2015Congress](http://www.isakos.com/2015Congress) to browse and book excursions. Tours are filling quickly—book now!

**Available Tours:****“Classical” Lyon****€ 75.00**

Sunday, June 7, 2015	9:30am–1:00pm
Monday, June 8, 2015	2:00pm–5:00pm
Wednesday, June 10, 2015	2:00pm–5:00pm

Lyon boasts 2,000 years of history! Visit by coach and travel around the city, including the most illustrious districts (Bellecour, the quays of the Rhône and the Saône, the Terreaux, Fourvière) and their iconic monuments (the Bartholdi fountain, the Opéra Nouvel, the Hôtel de Ville, the Palais St Pierre, the view from the esplanade, the basilica, etc.). Visit the Vieux Lyon on foot and discover one of the most extensive Renaissance neighbourhoods in Europe after Venice, spread out over one kilometer along the Saint Georges, Saint Jean and Saint Paul districts.

**Run of the River****€ 95.00**

Sunday, June 7, 2015	10:45am–2:30pm
Tuesday, June 9, 2015	10:45am–2:30pm
Thursday, June 11, 2015	10:45am–2:30pm

Set sail on a commentated cruise on the Rhône and Saône to the Vieux Lyon (Old Lyon). Discover the hidden treasures of Lyon’s heritage as seen from the river, highlighted by your guide who will share the city’s secrets throughout your journey. From the quays of Rhône to the classic and bourgeois buildings of the 17th and 18th centuries, followed by the innovative urban planning of the new, environmentally-friendly Confluence area, and finally onto the Saône for the Vieux Lyon Renaissance and its mullion facades of the 14th, 15th and 16th centuries, St Georges, St Jean and the Old Palace of Justice. Disembark opposite Vieux Lyon and have lunch at a traditional restaurant.

**The Original Road of Croix-Rousse****€ 75.00**

Sunday, June 7, 2015	2:00pm–5:00pm
Wednesday, June 10, 2015	9:00am–12:00pm

Lyon – the Capital of Silk! Lyon has been a hub for silk production since the Renaissance. Come and discover the history of the Lyon silk manufacturers and the “Canuts” by visiting their traditional neighbourhood as well as two iconic workshops where you will see demonstrations of authentic looms and printing on silk. In La Croix-Rousse, on a hill in Lyon, you can visit the “Maison des Canuts” and discover Jacquard’s famous mechanical loom. Then go to the Terreaux district where you can watch a demonstration of silk printing and discover more about the universal method that made it internationally famous. After this, L’Atelier de Soierie will welcome visitors and present one of Lyon’s traditional crafts: silk printing, which is also known as frame printing or silk screening.





### Discovering the Beaujolais Wines

€ 155.00

Monday, June 8, 2015 9:00am–6:00pm

You will follow the Beaujolais Route des Crus, an itinerary full of wine merchants! Visit the Hameau en Beaujolais (wine museum), which was created by Georges Duboeuf, the first Beaujolais wine merchant. Then, further south in Salles-Arbussonnas, you will visit the cloister, the Beguine convent and the oldest Romanesque church in the Beaujolais region. Lunch will be served at an excellent restaurant in Chénas. Near Mont Brouilly, in the wine region. You will have the opportunity to taste a great “Cotes de Brouilly” in the vaulted cellar of the famous Chateau de La Chaize. In the afternoon, visit the Romanesque Cloister in Salles-en-Beaujolais (12th–14th century), with its great Beguine convent of the Canon-Countesses.



### Go Up to the Roofs of Fourvière

€ 95.00

Monday, June 8, 2015 10:00am–2:30pm

Thursday, June 11, 2015 10:00am–2:30pm

Take a unique visit to the Fourvière basilica, the most emblematic monument in all of Lyon! You will discover the hidden sections of the basilica, such as the Grande Tribune (triforium level), the architects’ cabinet, the Galerie des Anges (Angels Gallery), and the attics with the “modelos” (plaster models). Then move on to the bells of the basilica (23 electronic Monet and Paccard bells). Following this, you will cross the terrace at St Michel and head to the roof for a magnificent panoramic view over the entire historic town of Lyon. Next, visit the Gallo-roman theatre and the Odeon, a remarkable site that was built shortly after the town was founded in 43 BC. Lunch will be served at a restaurant in Old Lyon, drinks included.

### In the Kitchen of the Pastry Chef

€ 220.00

Monday, June 8, 2015 11:45am–3:00pm

Tuesday, June 9, 2015 11:45am–3:00pm

With the desire to teach and share his knowledge and passion for patisserie, Sébastien Bouillet wanted to create a school where both beginners and experienced amateurs could create recipes worthy of a great chef. Today, chef Bouillet is world-renowned. An unforgettable experience for you to learn how to cook like a real pro! At the end of the course, lunch will be served – where you will enjoy your own creations.

### Paul Bocuse Halles

€ 130.00

Monday, June 8, 2015 10:45am–2:30pm

Visit the “Paul Bocuse” Halles of Lyon, named after the Chef of Chefs who made them famous throughout the world. An indoor market and a true temple of French gastronomy, this is where the region’s best chefs and gastronomes come to refuel. Regional products (cured meats, pork scratchings, snails, quenelles, Saint Marcellin cheese, Coteaux du Lyonnais wine, etc.) are displayed with pride! You will also find the most beautiful culinary delights from around the world at Les Halles de Lyon. Two tasting sessions are included (cured meat and seafood).



### Pérouges & Dombes “A Very Famous, Typical Medieval Village”

€ 115.00

Tuesday, June 9, 2015 11:00am–6:00pm

Visit the magnificent historic village of Pérouges and Dombes. At the top of a hill, protected by ramparts, this true gem of medieval architecture is found over its winding streets lined with houses dating back to 1470. The setting is so authentic that filmmakers come to use it for historical films such as “The Three Musketeers”. Have lunch at a traditional inn in the center of the village. Return through the streets of Dombes, a shrine to gastronomy, passing the many ponds, red-brick castles and picturesque villages.

### Fashion & Design

€ 70.00

Tuesday, June 9, 2015 9:00am–12:00pm

Wednesday, June 10, 2015 2:00pm–5:00pm

Discover the talented Lyon fashion designers! The Village des Créateurs (Designers Village), founded in 2001, is an economic development establishment for fashion, decoration and design companies based in Rhône-Alpes. 70 designers are currently being supported by the Village des Créateurs. Located in the Passage Thiaffait, once a traboule (a typically Lyonnais passage), now an architectural landmark and residential area, which today brings together brands and designers located in the region. You will be given a general introduction to the Village and a tour of the traboule before meeting several designers in their shops.



10<sup>TH</sup> Biennial

ISAKOS  
CONGRESS 2015

JUNE 7–11, 2015  LYON, FRANCE



### Chef for the Day

€ 250.00

Wednesday, June 10, 2015 11:45am–3:00pm

Lyon is well known as the capital of gastronomy! Take a cooking class in a relaxed atmosphere and lend a hand to prepare your own meals under the supervision of a great chef! Specialists in the art of making delicious and beautiful dishes, these chefs have chosen to share their passion for food with you. After being welcomed over an aperitif, you will begin with mini-workshops: going from stand to stand, salty then sweet, at your own pace. You will create recipes that take 5 to 10 minutes to prepare which you will be able to eat afterwards as your lunch.

### On the Road to the Châteaux in Vintage Cars

€ 290.00

Wednesday, June 10, 2015 9:00 am–6:30pm

Discover Beaujolais in the mythical 2CV (Old Fashion French car)! Located just outside Lyon, the south of Beaujolais is a vibrant, bright place, remarkable for its yellow ochre villages that reflect the sunlight. Our itinerary will take you on a journey to discover the best of this magnificent region through visits to famous churches, cloisters and châteaux. Participants will be divided into groups of 4 per car, and each person will drive part of the journey. Each participant holding a valid driving license will be able to drive a 2CV. Lunch will be served with views over the vineyards and the Saône valley.



## ISAKOS PF Traveling Fellowship, 2014 Summary Report

### Fellows

Laurie A. Hiemstra, MD

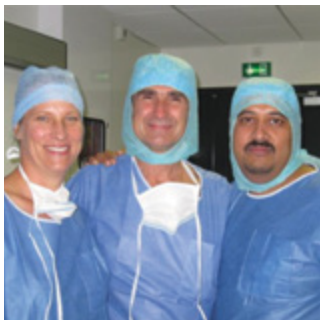*Banff Sports Medicine, Banff, BC, CANADA*

Shital N. Parikh, MD

*Cincinnati Children's Hospital, Cincinnati, OH, USA*

### Lyon, France (October 6–8, 2014)

Our traveling fellowship started in Lyon, France's second-largest city which is immersed in rich historical and cultural tradition. On the morning of October 6, Dr. David Dejour picked us up from the hotel and we headed straight to the operating room. The day was packed with 8 surgeries, back and forth between 2 operating rooms and 2 very efficient surgical teams. The surgical cases included patellofemoral arthroplasty, salvage trochleoplasty, MPFL reconstruction and tibial tubercle distalization. The sad part was that there was no time for lunch. The evening dinner was hosted by Dr. Dejour at Brasserie Leon de Lyon with Professor Elvire Servien, Dr. Guillaume Demey and a visiting fellow. On October 7, we visited the Albert Trillat Center at University Hospital, where we were greeted by Professor Philippe Neyret and Professor Servien. It was wonderful for Professor Servien to present the 'History of French Orthopaedics' with brief introduction of the pioneers of patellofemoral surgery. The morning session ended with case discussions. That afternoon gave us some free time to hike up the 'Fourviere' and the 'Roman ruins'. The morning of October 8 was again spent with Dr. Dejour in the operating room where we had chance to discuss some cases, interact with him and get more surgical perspective on the patellofemoral joint.



01



02

### Tampere, Southern Finland (October 9–11, 2014)

Tampere has been dubbed as the 'Manchester of Finland' for its industrial past. Dr. Petri Sillanpaa, picked us up from the hotel on the morning of October 9 and we headed to 'Kirurgian Koulutuskeskus', the newly launched surgical training center. A pre-course seminar on lower extremity osteotomies was organized which was attended by Finnish orthopaedic surgeons. The presentations were impressive and it was a delight to hear the experience of senior surgeons, who later confessed how nervous they were as they had to repeatedly rehearse their presentations in English—just for us. That afternoon, we scrubbed with Dr. Sillanpaa on 2 surgical cases, an ACL reconstruction in a skeletally immature patient and MPFL reconstruction for patellar instability. The evening was relaxing with the unique experience of Finnish tradition at Sauna Hangaslahti, followed by dinner prepared by local chefs. On October 10, there was an academic conference on patellofemoral joint at the Tampere University Hospital. We both gave two presentations related to patellofemoral instability and there were thoughtful exchanges of ideas during the conference. The afternoon surgical cases included a trochleoplasty with MPFL reconstruction and an MPFL reconstruction using adductor longus autograft in a skeletally immature patient. The evening dinner was at Finlayson Palatsi restaurant in the heart of Tampere.



03

### London, United Kingdom (October 13, 2014)

We met Professor Andrew Amis at the Imperial College in London on Monday, October 13; it was raining, as expected. Founded in 1907, Imperial College London is one of the world's best science-based institutions. Professor Amis gave us a guided tour of his biomechanical lab, including the history, development and basis for several workstations in the lab. He introduced us to a robot in his lab that has been used to study joint biomechanics. The display of heavy-duty automatic guns on his shelf could give an insight towards his love for machines. We met Joanna Stephen, MSc in the lab who gave us an in-depth review of all the patellofemoral cadaveric experiments that she had been involved with. At noon, we presented our perspective on patellofemoral joint at the weekly research meeting and enjoyed interacting with postdoctoral and PhD research fellows and students. This was followed by lunch in the cafeteria of Victoria and Albert museum, the world's largest museum of decorative arts and design. We had nice discussions about potential biomechanical research related to PF joint. That evening we headed to Norwich.






04

### Norwich, United Kingdom (October 14–15, 2014)

Just two hours north of London, Norwich has a wealth of historical architecture and medieval churches. Professor Simon Donell welcomed us in his countryside house and introduced us to his family members which included four cats, three Alpacas, a few chickens and a horse. The fabulous meals at his house were prepared using home-grown eggs, vegetables and fruit. The morning of October 14 was spent at Norfolk and Norwich Hospital where Professor Donell showed us a video presentation of his modified trochleoplasty and a sample of complex cases that were treated by him in past. The afternoon was spent in the new patient clinic, where we had a chance to examine several referred patients with complex patellofemoral disorders, including patients with failed previous patellar stabilization procedures and a subluxed patellofemoral joint with arthrosis. The dinner was hosted by Professor Donell at 'The Wildebeest' – an African themed restaurant with great food. The morning of October 15 was spent in the operating room for a complex case of habitual/obligatory dislocation of patella in flexion. The surgery comprised of distal femur de-rotational osteotomy, Albee trochleoplasty, MPFL reconstruction and quadricepsplasty. After surgery and rounding on inpatients, we headed to the airport on our way to Munich.




05a



05b

### Ulm and Oberstdorf, Germany (October 16–17, 2014)

On October 16, we arrived in Ulm which was an hour long train-ride from Munich. Ulm is a city in southern Germany and is the birthplace of Albert Einstein. We were greeted by Dr. Sabine Lippacher, who accompanied us to the Institute of Orthopaedic Research and Biomechanics at University of Ulm. She introduced us to the head of the Joint Biomechanics Group, Professor Dr. Lutz Durselen, who gave us the tour of the lab; the lab was unique and immaculate. It was an all-in-one research center including capabilities for studies related to biomechanical engineering, cell biology, histopathology, microCT and computer modeling. Dr. Lippacher explained to us her experiments that were conducted in the lab to detect PF contact forces after MPFL reconstruction.



06



07

That evening, we reached Oberstdorf, a hiking and skiing town in southwest Germany, located in the Bavarian Alps. Dr. Manfred Nelitz received us at the train station. At dinner, he talked about his training in pediatric orthopaedics and how it has helped him to understand the developmental issues related to patellofemoral joint. On the morning of October 17, he picked us up from the hotel and we headed to the operating room. We assisted him in an MPFL reconstruction using a sleek technique of quadriceps tendon graft harvest. We continued case based discussions related to trochleoplasty, arthroscopic assessment of trochlear dysplasia, patellofemoral instability in skeletally immature patients and role of de-rotational osteotomy in management of patellofemoral disorders.

**October 18, 2014:** After two weeks of learning, sharing and fun, we said au revoir, nähdään, see you later and Auf Wiedersehen to each other

- 01 with Dr. David Dejour
- 02 with Professor Elvire Servien
- 03 with Dr. Petri Sillanpaa
- 04 with Professor Andrew Amis
- 05ab with Professor Simon Donell (center)
- 06 with Dr. Sabine Lippacher and Dr. Lutz Durselen
- 07 with Dr. Manfred Nelitz

## Description of a Novel, Effective and Reproducible Portal for Arthroscopic Distal Clavicle Excision: Technique and Cadaveric Validation



Justin J. Mitchell, MD  
 Department of Orthopaedic Surgery  
 University of Colorado School of  
 Medicine  
 Aurora, CO, USA

Additional Author:  
 Jonathan T. Bravman, MD

### Purpose

The purpose of this research is to provide an anatomic description for creating an anterior portal that preserves local anatomy, and is both safe and effective for glenohumeral and acromioclavicular joint access using reproducible anatomic landmarks. This technique has recently been published, and has been clinically reliable for our practice. The described portal is both safe and effective, allowing the surgeon direct access to the AC joint while also allowing access to the glenohumeral joint. This description can be important for surgical planning, as distal clavicle excision often occurs at the end of the arthroscopic shoulder procedure, and anterior portals are infrequently planned to accommodate this.

### Methods

Five cadaveric shoulder specimens were examined in a laboratory setting. Using reproducible subcutaneous anatomic landmarks of Neviasser's point, the clavicle, the acromion and the coracoid, cutaneous markings are made (Fig. 1). A line perpendicular to the clavicle that connects Neviasser's point to the most lateral aspect of the coracoid is then drawn (Fig. 2). Along this line, a ruler is used to mark a distance 1.5cm distal to the anterior edge of the clavicle, which typically localizes the entry point to position just superior and lateral to the tip of the coracoid. This point also places a planned anterior portal directly in line with the AC joint, but also allows for access to the glenohumeral joint for examination and treatment.

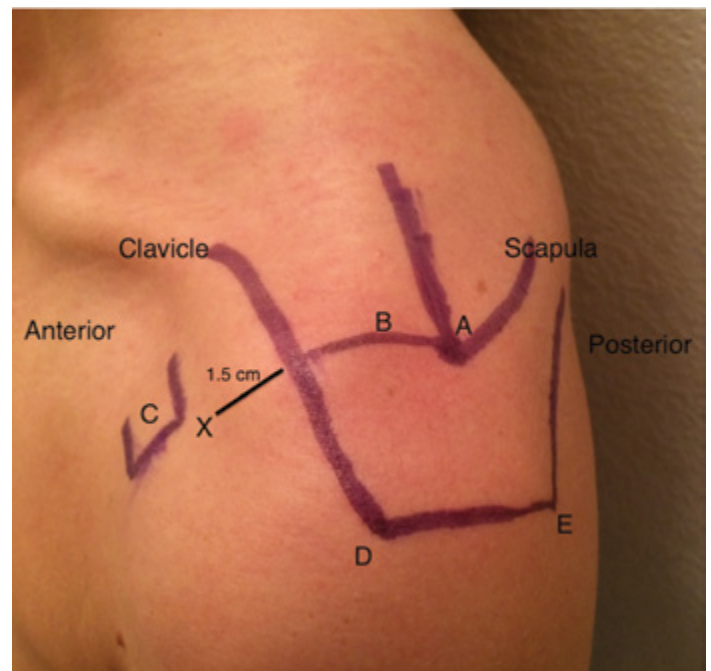
An anterior portal is established at this location, and using a sharp pin to mimic an arthroscopic device, the subacromial space was entered. The portal with the intact pin was then carefully dissected both anteriorly and superiorly to examine the coracoacromial ligament and AC joint (Fig. 3). Further, the distance and angle of the pin from the AC joint axis in both the anterior and posterior aspects of the joint was measured to validate the placement of the instrument.

### Results

The average angle from the central portion of the AC joint to the pin anteriorly was 6 degrees. Average distance (offset) from the same point anteriorly averaged 3.2mm. Posterior offset averaged 2.8mm, and the posterior average angle from the central portion of the AC joint to the pin was 3.6 degrees. Dissection of all portals revealed pin placement above the CA ligament in all five specimens, and that there was no iatrogenic damage to this structure.

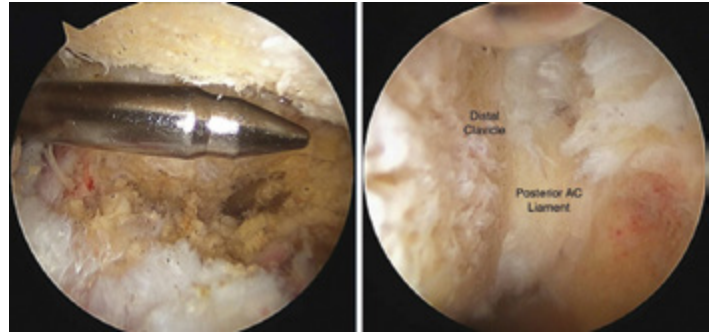
### Conclusions

This study demonstrates a safe, effective, and reproducible way to establish the anterior portal for arthroscopic distal clavicle excision. On cadaveric dissection, the average distance to the center of the AC joint is less than the width of a standard arthroscopic burr, allowing for safe and adequate resection of the distal clavicle. This is especially important, in that the most difficult portion to resect, the posterosuperior aspect of the distal clavicle, can be easily and reproducibly accessed using this technique.



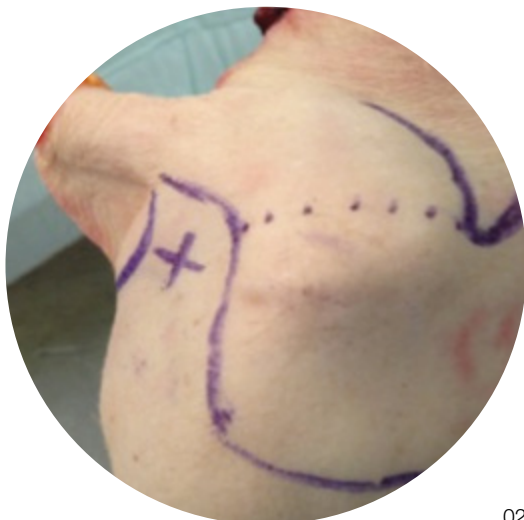01

Of note, in a true intra-operative setting, we commonly will draw out the anatomic landmarks and planned anterior portal placement (as described above) and still create our portal under direct arthroscopic visualization into the glenohumeral joint using a spinal needle, as there is no need to create it blindly. However, we have not yet found the need to deviate the skin incision of the portal location from our pre-operative marking. Ultimately, the trajectory of the needle is such that it still enters the joint within the described safe intraarticular triangle of the rotator interval. The description and location of the portal is optimal for arthroscopic distal clavicle excision in the patient undergoing concomitant subacromial or intraarticular procedures, and is versatile in that it can be used as an isolated portal for access to both the glenohumeral and AC joints or as an anterosuperior accessory portal when an more inferior portal is needed to access the glenohumeral joint. Importantly, this portal also provides access to the posterosuperior aspect of the distal clavicle so that adequate resection can be undertaken, and places the arthroscopic instruments parallel (or nearly parallel) to the AC joint allowing for ease of resection.

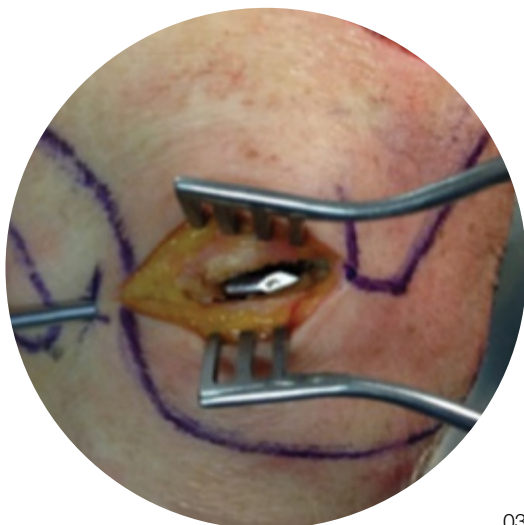

**Clinical Relevance:**

This method of establishing the anterior portal for distal clavicle excision provides the surgeon with a safe corridor for placement of instruments in a reliable manner that does not disrupt the important stabilizers of the glenohumeral or AC joint.



02



03

- 01 Fig 1 Superior view of a left shoulder identifying the surface landmarks of the shoulder. (A) Nevaizer's Point, (B) AC Joint, (C) Coracoid, (D) Anterior border of Acromion, (E) Posterior border of Acromion. The proposed anterior portal (X) is marked a distance of 1.5 cm from the anterior border of the clavicle and just superior and lateral to the tip of the coracoid process.
- 02 Fig 2 Superior view of a disarticulated left shoulder with a point for portal entry (X) located 1.5cm inferior to the anterior edge of the clavicle along the line created between Nevaizer's Point and the lateral margin of the coracoid.
- 03 Fig 3 Superior view of a cadaveric shoulder specimen with dissection of the anterior portal. This portal placement reveals no iatrogenic damage to the CA ligament and is in line with the AC joint.



## Tips in ACL Revision Surgery



Gonzalo Samitier, MD, PhD,  
FEBOT<sup>1</sup>

Eduard Alentorn-Geli, MD, MSc, PhD, FEBOT<sup>2</sup>  
Ramon Cugat, MD, PhD<sup>3</sup>  
Kevin W. Farmer, MD<sup>4</sup>  
Alejandro I. Marcato, MD<sup>4</sup>  
Michael W. Moser, MD<sup>4</sup>

<sup>1</sup> Sports Medicine and Shoulder Division. Hospital General de Villalba (Comunidad de Madrid – SPAIN). Grupo Idcsalud

<sup>2</sup> Sports Medicine Division, Duke University Medical Center, Durham, NC, USA

<sup>3</sup> Orthopaedic Surgery Department, Hospital Quirón Barcelona. García-Cugat Foundation, Barcelona, SPAIN

<sup>4</sup> Sports Medicine Division, Department of Orthopaedics and Rehabilitation, University of Florida, Gainesville, FL, USA

### INTRODUCTION

Anterior Cruciate Ligament (ACL) rupture is one of the most common orthopaedic surgical conditions in active population; ACL reconstruction has satisfactory outcomes in 75% to 97% of patients, however, with the number of primary procedures increasing each year, the absolute number of graft failures after ACL repair is also rising and so revision surgeries. In a very recent study using two large US databases, the incidence rate of ACL rupture rose from 32.9 per 100,000 person-years in 1994 to 43.5 per 100,000 person-years in 2006, particularly in females as well as those younger than 20 years and those 40 years or older.

No universally accepted definition for failure of an ACL reconstruction exists; objectively Hofbauer et al. recently redefined it as a deficit of 10° of knee extension or 10° of knee flexion compared with the contralateral, uninjured side and/or demonstration of knee instability as assessed by the Lachman test ( $\geq 2$ ), pivot-shift test ( $\geq 2$ ), or arthrometer ( $>3$  mm side-to-side difference).

In this article we would like to review the multifactorial causes of ACL surgery failure, focusing on preventing and solving such situations, particularly those due to primary graft insufficiency or rupture and recurrent instability.

### 1. KNOWING WHAT FAILED

#### Patient Evaluation

A meticulous evaluation of the patient will help us to better understand the cause of primary failure as well as to plan ahead the revision surgery if needed. Most of the factors that should be considered during the initial approach to a patient with ACL graft failure are shown in Table 1. Laboratory tests are not included in our table but may be also helpful in some cases to detect infectious or inflammatory processes.

**Table 1. Relevant History Data for Preoperative Planning.**

<b>Primary Procedure</b>
Injury: date, mechanism of injury, symptoms
Surgery: date, surgical technique, graft choice, fixation methods, associated injuries, other surgical procedures
Postoperative: complications, rehabilitation, return to sports
Recurrence: date, mechanism of injury, signs and symptoms (instability/pain/stiffness/knee effusion)
<b>Physical Exam</b>
Inspection: scars, swelling, muscle atrophy, lower limb alignment, gait
Palpation: temperature, knee effusion, trigger points, catching, locking, crepitation
Function: range of motion, knee strength
Special tests: anteroposterior stability (Lachman test, anterior-posterior drawer), rotational stability (pivot shift sign test, dial test), and mediolateral stability (valgus-varus test), meniscal tests
<b>Imaging Studies</b>
Plain radiographs (standing anteroposterior view, lateral view at 30° of knee flexion, axial view at 45° of knee flexion [Merchant's view], standing posteroanterior view at 45° of knee flexion [Fick's view], with Long leg weightbearing, functional radiographs): assess lower limb alignment, position of tunnels, tunnel widening, fixation methods, degree of knee osteoarthritis and associated instabilities
MRI: assess knee effusion, graft preservation, tunnel preservation, cartilage damage, and meniscal injuries
Bone scintigraphy Tc <sup>99m</sup> : degree of knee arthropathy, complex regional pain syndrome, infection CT and 3-D CT scan: bone abnormalities, previous tunnels size and exact assessment of the previous tunnel location.
<b>Technical Considerations</b>
Graft choice: autograft vs allograft, soft tissue vs bone-tendon grafts, ipsilateral versus contralateral graft
Surgical technique: non-anatomic transtibial vs anatomic, single-bundle vs double-bundle, all-in side vs outside-in,
Removal of hardware: fluoroscopy, universal set of instruments
Other procedures: high tibial osteotomy, treatment of cartilage, meniscectomy vs meniscal repair, meniscal transplant, associated ligament injuries reconstruction

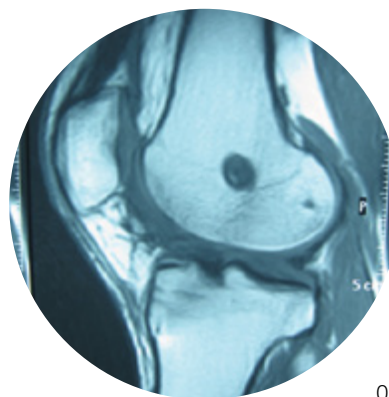
**Etiologic Classification**

There are three clinical signs and symptoms that lead us to consider an ACL reconstruction as a failure: **instability**, **stiffness**, and **pain**. Trying to identify what failed in first place is important; we have summarized most of the causes that can make the knee to progress into one or several of the previously mentioned conditions.

<b>Table 2. Etiologic Classification of Failure of ACL Reconstruction</b>	
<b>1. Instability</b>	
Abnormal mechanical loads	Acute traumatic event Chronic repetitive movement Inappropriate accelerated rehab postop
Non-anatomical tunnel placement	Anterior femoral tunnel Posterior femoral tunnel Anterior or posterior tibial tunnel Vertical femoral tunnel Medial or lateral tibial tunnel
Misdiagnosed associated injuries	Medial collateral ligament Posterolateral corner Posterior cruciate ligament
Failure of graft fixation	Failure of fixation method Failure of graft tension Failure of graft isometry
Failure of graft selection	
Failure of graft incorporation	
Failure of graft due to infection	
Lower extremity malalignment	
<b>2. Stiffness</b>	
Primary	
Secondary	Inappropriate rehabilitation postop Technical error Surgery at acute phase of injury Infection CRPS Synovitis and hematoma
<b>3. Pain</b>	
Patello-femoral pain	
Donor site pain	
Femoro-tibial osteoarthritis	
Residual meniscal tears	
Synovial disease	
Neuroma	
CRPS	

Classically literature has shown that ACL graft failures are primarily caused by technical mistakes (estimated at around 70%), chronic or acute traumatism, and biologic causes. A recent Multicenter ACL Revision Study (MARS) Group developed a multi-surgeon, multicenter prospective longitudinal study to allow multivariable analysis and determine predictors of clinical outcome in revision ACL. The MARS cohort (460 patients) showed that mode of failure, as deemed by the revising surgeon, was traumatic (32%), technical (24%), biologic (7%), infection (<1%) and more often a combination of some of the previous (37%). Also from the MARS cohort, femoral tunnel malposition was reported to be the most common technical failure finding (80%), followed by tibial tunnel malposition (37%). Table 3 summarize the most common technical failures regarding non-anatomical tunnel placement.

<b>Table 3. Common Mistakes in Femoral and Tibial Tunnel Placement</b>		
Tunnel	Position	Consequences on the graft
Femoral	Anterior	Excessive tension in flexion or stiffness in extension
	Posterior	Excessive tension in extension or laxity in flexion
	Central/Vertical	Rotational instability
Tibial	Anterior	Excessive tension in flexion or impingement against intercondylar notch in extension
	Posterior	Excessive tension in extension or impingement against the posterior cruciate ligament
	Medial	Impingement against the medial femoral condyle or against the posterior cruciate ligament
	Lateral	Impingement against the lateral femoral condyle



01

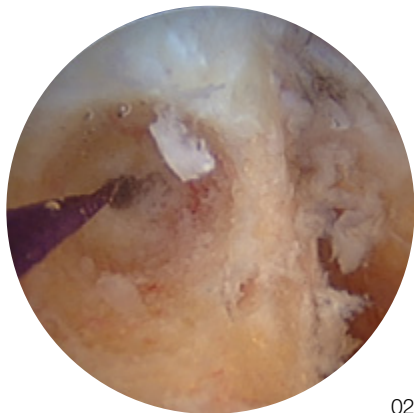
Tips in ACL Revision Surgery

2. HAVE A PLAN

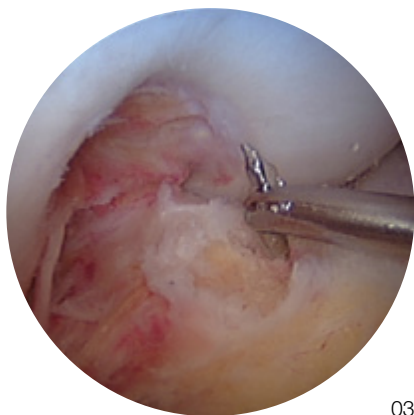
Surgical Technique to Use

For years, the transtibial technique has been the gold standard for ACL reconstruction. However, transtibial endoscopic ACL reconstruction often result in vertical graft orientation because of the inherent limitations in reaming an anatomic femoral and tibial tunnel. Non-anatomically positioned tunnels is one of the most common causes of clinical failure after ACL reconstruction with 15% to 31% of athletes complaining of pain, persistent instability, or an inability to return to the previous level of competition. For this reason, independent drilling of the tibial and femoral tunnels over the native ligament footprints is recommended.

For revision ACL reconstruction we normally favor single bundle anatomic technique but some surgeons advocate for a double-bundle reconstruction of the ACL. In a recent article Hofbauer, Fu F et al. showed a flowchart for surgical decision-making strategies according to previous femoral tunnel locations in revision surgery after failed primary double-bundle ACL reconstruction. Minimal mandatory requirements for secure double bundle technique remain; Tibial or Femoral ACL insertion site of more than 14 mm in diameter and notch width/height at least of 12 mm.



02



03

Type of Graft

Recent, systematic reviews on randomized prospective studies that compare hamstrings with BTB grafts have suggested that the type of graft is not the main determining factor for success in ACL reconstructions. Since most of the failures are a result of technical errors and not of graft choice, what counts is the surgeon’s experience with the technique used and the selection of the patient. The graft distribution in ACL reconstruction varies in different parts of the world but definitely Semitendinous-Gracillis (ST-G) graft has gained popularity within the last years. A US-based study reported 25% patellar tendon autografts, 31% hamstring autografts, 42% allografts, and 2% other grafts. Autografts were used for primary ACL reconstruction in 90% of the patients and allografts in 5% in a study from Ontario, Canada.

Results from a present large prospective study from Scandinavia using the Norwegian National Knee Ligament Registry (NKLK), based on 45.998 primary ACL showed that patients receiving patellar tendon autografts had a statistically significantly lower risk of revision compared with patients receiving hamstring autografts specially for those patients with higher demands. Interestingly, patellar tendon and hamstring autografts were used in 14.6% and 84.1% of the patients, respectively. The remaining patients received allografts, direct sutures, or other graft types (1.3%).

Table 4 Summarize the pros and cons in between ST-G and BTB autograft.

Table 4. Classical Differences Associated to the Use of BTB or ST-G Autografts.		
	Pros	Cons
BTB	<ul style="list-style-type: none"> <li>• Fixation with osseous plug</li> <li>• Greater revascularization capacity</li> <li>• Less risk of failure</li> <li>• Greater tensional strength</li> <li>• Better flexion</li> <li>• Faster and more vigorous return to sports</li> <li>• Better Tegner Score</li> </ul>	<ul style="list-style-type: none"> <li>• Anterior knee pain</li> <li>• Late arthritis, specially patellofemoral</li> <li>• Kneeling difficulty</li> <li>• Knee flexion and extension difficulty</li> <li>• Less strength at extension (first 6 months)</li> <li>• Patellar tendon shortening</li> <li>• Paresthesia in medial region</li> <li>• Technically demanding</li> <li>• Skeletal immature patients</li> </ul>
ST-G	<ul style="list-style-type: none"> <li>• Ease Extension</li> <li>• Less anterior knee pain</li> <li>• Less kneeling pain</li> </ul>	<ul style="list-style-type: none"> <li>• Reduction in flexion strength (first 6 months)</li> <li>• Reduced stability</li> <li>• Posterior knee pain</li> <li>• LCA agonist muscles weakening</li> <li>• Bone-soft tissue fixation</li> <li>• Tunnels widening</li> <li>• Internal saphenous neuromas</li> <li>• Hematomas</li> <li>• Higher revision rate than BTB</li> </ul>

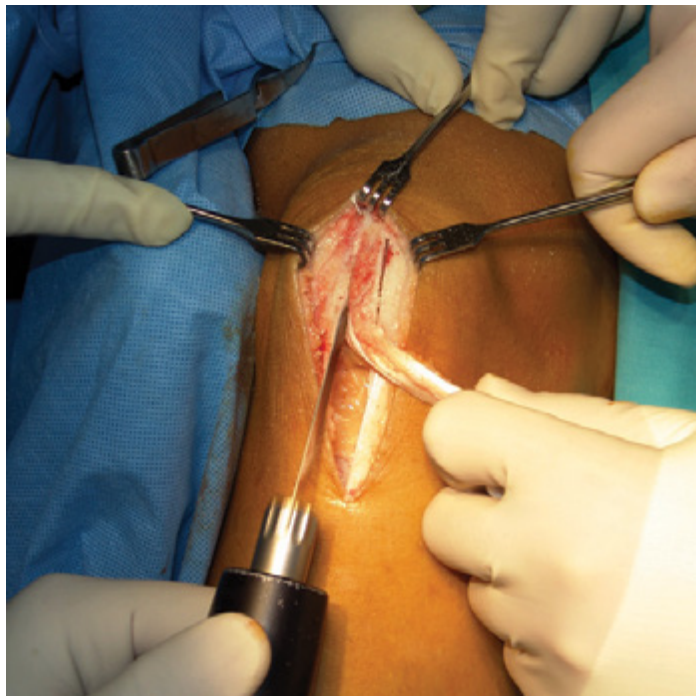

Other possibilities, though used less often, are the quadriceps tendon and iliotibial band. The quadriceps tendon autograft for ACL reconstruction is getting supported by current orthopaedic literature as a safe, reproducible, and versatile graft that should be considered in future studies of ACL reconstruction.

When it comes to decide in between auto or allografts Among the advantages of the autograft are faster integration to bone and no risks of disease transmission or immune reactions. Nonetheless, the morbidity at the site of extraction as well as the potential limitations of the size of the graft are worth discussing. Additionally, the use of autografts imposes a limitation in the advent that revision surgery is required. In these cases, ipsilateral BTB grafts are often the choice if it has not been previously used in the primary surgery; if it has, the contralateral BTB can be used. The repeated use of the BTB or of the quadruple ST-G have also succeeded, although there are doubts about the mechanical properties of the re-extracted autograft. For this reason, reuse is not advised in general.

Allografts are being used increasingly, in revision surgeries as well as primary surgeries. They offer advantages such as less morbidity, avoiding complications at the graft extraction site, a shorter surgery time and more options for choosing the right size and shape of the graft. Among the worries are the biologic integration, the risk of transmitting diseases, the availability and cost. Allografts tend to incorporate more slowly than autografts, which can prolong the rehabilitation process. Several studies have failed to identify significant differences between autografts and allografts at a one-year follow-up although, the recent literature has suggested that allografts may have a greater rate of failure in young athletic and active patients, with failure rates as high as 15 times more likely in the allograft group compared with the autograft cohort.

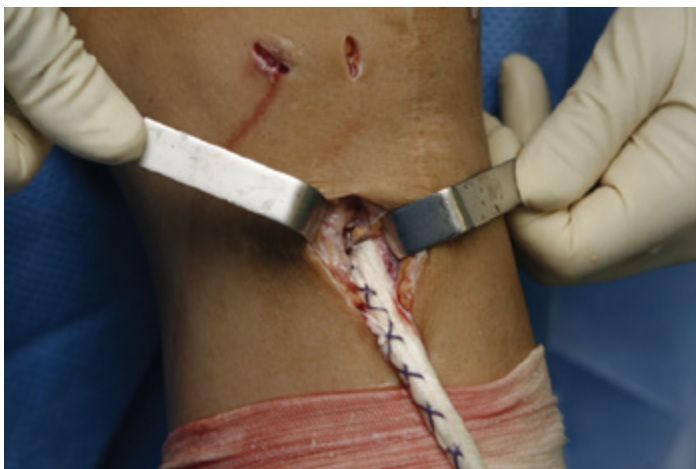Of note, the recent literature has suggested that allografts may have a greater rate of failure in young athletic and active patients, with failure rates as high as 15 times more likely in the allograft group compared with the autograft cohort.



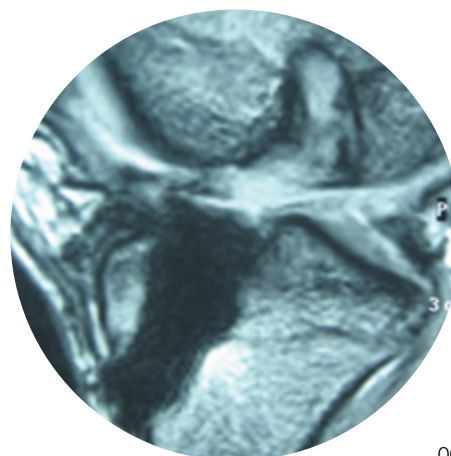
05

#### When to Stage the Procedure

We favor a non-staged revision ACL procedure whenever proper tunnel placement and stable graft fixation can be achieved. Two-stage revision surgery is often necessary in cases of tunnel widening, synovial fluid fistules through the tunnel or artificial grafts with severe synovitis. In such cases, a first surgery may be performed to remove remnants of the previously reconstructed ACL and place bone graft into the old tunnel. Tunnel widening occurs more commonly when using soft tissue or synthetic graft. This situation usually arises when the graft does not exactly match the tunnel width; it may have been diminished by using press-fit techniques or interferential screws that locked the graft as close as possible to its entrance into the joint in both femur and tibia; this prevents a windshield-wiper effect and the synovial fluid to ingress into the tunnel, enhancing graft incorporation.



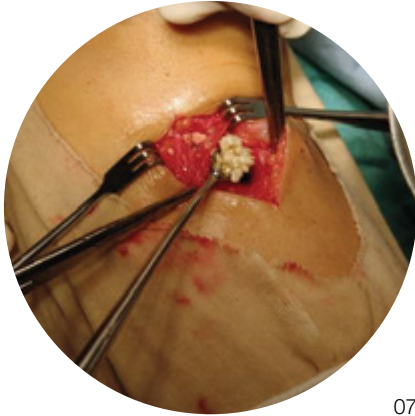04



06

## Tips in ACL Revision Surgery

Two stages revision surgery may be also needed when ROM deficit more than 5° in extension or 20° in flexion, as well as in case of active infection. Two-stage revision usually requires a 4 to 6-months gap between procedures. Surgeon and patient have to be aware that his prolonged period of instability can produce secondary chondral and/or meniscal injuries but also that every single additional surgery carries the risk for potential inherent complications (e.g., anesthesia-related, infection, deep venous thrombosis).



07

### 3. EXECUTE YOUR PLAN

#### Intraoperative Tips to Correct Tunnel Malpositioning

When ACL reconstruction has failed due to non-anatomical tunnel placement, one of the most important aspects of the revision surgery is to *ensure adequate visualization of the previous tunnels* and the integrity of the postero-medial wall of the lateral femoral condyle. Occasionally, trochleoplasty can be needed, specially when narrowing or osteophytes in the intercondylar notch. Once these previous steps have been conducted, drilling of the new tunnels may be performed as close as possible to their anatomical location. The femoral insertion site of the ACL encompasses approximately the lower 30% to 35% of the intercondylar notch wall, and revision tunnels should thus be placed accordingly; If possible, *both tunnels should be placed far enough and divergent enough* from previous tunnels to prevent tunnel overlapping.

In order to avoid previous non-anatomical femoral tunnel, in a single bundle reconstruction an anteromedial (AM) parapatellar portal can be created just in front of the medial femoral condyle and as low as possible; special care has to be taken to avoid damaging the medial femoral condyle and the anterior horn of the medial meniscus respectively. The drilling of the femoral tunnel should be performed at least with 110° of knee flexion in order to get adequate tunnel length and decrease the risk of damaging the lateral neurovascular structures.

Depending on surgeon's preference several surgical options can also be performed to create a new anatomic femoral socket or If the medial-posterior wall of the lateral femoral condyle is insufficient:

- a) extra-cortical fixation with suspensory devices;
- b) over-the-top fixation through a lateral post;
- c) changing the orientation of the femoral tunnel through the use of accessory AM portal;
- d) using the classical open outside-in drilling technique;
- e) using flexible reamers through the AM portal allowing a more modest knee flexion
- f) new options as arthroscopic retro-drilling outside-in technique.

*Hardware removal* is another factor to consider and *should be planned* in advance as it may involve intraoperative difficulties, longer surgery and may entail a bone stock loss, thus hardware should only be removed when it is in the way of the new tunnels. Sometimes previous hardware can be useful in avoiding old tunnels when the new ones are drilled. New screws should be placed with caution, taking care that they do not enter into the old tunnels. If both communicate, the graft should be positioned in contact with the "healthy" wall instead of the old tunnel; this can be checked intraoperative just visualizing with the scope through the tunnel. When previous interference screws removal is necessary, it is imperative to have the adequate screwdriver and reproduce portal and knee flexion degree used during insertion. If previous screws are not removable, it is possible to drill over them if reabsorbable. If staples were used, it is strongly recommended to have the appropriate extractors and consider the potential bone loss after removal, which could affect tibial fixation.

Tibial tunnel can be also challenging as even with previous transtibial technique was performed; we have to be specially careful in trying to diverge from the previous tunnel in the coronal and sagittal planes and exit as far as possible in the joint from the previous tunnel; in many occasions partial or complete convergence of the tunnels occur creating a double barrel effect; in order to avoid that the new graft "falls" into the old tunnel, we can with fill in the old tunnel with impacted bone graft or even with a press-fit cannulated interference screw to create some support; again, the graft should be positioned against the "healthy" wall instead of the old tunnel.

#### Fixation Mode

Kurosaka et al. established that the weakest point of a fixation is the weakest link during the immediate postoperative period. For this reason, a solid fixation is essential to prevent changes in the position of the graft inside the tunnel, keeping in mind that autologous and bone-bone integration happens faster than soft tissue-bone or allografts integration.

For the BTB fixation, the interference screws have proven to be more effective than staples, posts or other devices. Yet, screws can pose problems at the time of fixation, such as being driven into the tunnel, divergence caused by the screw, rupture of the bone plug or screw, damage of tendinous fibers, among others.



Usually, extra-cortical suspensory systems are employed for the fixation of the quadruple reconstruction of hamstrings, although interference screws and staples or combination could also be used.

Repeated flexing-extending cycles of the knee is recommended in order to preinstall the graft before the fixation. Adequate tension of the graft in between 0 and 30° is tested with the probe under arthroscopic control and the surgeon's perception must be that the tension is the same or very close to the one felt with a normal ACL.

### REHABILITATION TIPS

Rehabilitation after ACL revision surgery often are more conservative than the aggressive protocols used for primary surgery. Patients must remember that results are less predictable and they should not exceed the limits indicated for them. A delayed return to intense activities is also expected. Each rehabilitation protocol must be individualized and based on the type of reconstruction performed, the strength of the fixation and the type of graft used and patient.

**Table 5. Key Factors for Functional Recovery After Acl Reconstruction Surgery.**

- Active extension produces an important stress on the ACL graft. Must be performed with assistance during the first weeks limited from 30° to 0°.
- Open chain exercises produce maximal shearing forces.
- Close chain exercises do not produce stress on the ACL graft.

**Table 6. Criteria for safe return to unrestricted activities**

1. Complete range of motion.
2. Quadriceps strength over 85% of contralateral side.
3. Hamstrings strength of 100% of contralateral side.
4. Good ischio/quad muscle balance over 70%.
5. One-legged jump of 85% of length of contralateral side.
6. KT-1000 measured difference of less than 3mm between knees.

### CONCLUSIONS

Revision ACL surgery is a challenging procedure with many factors to consider; correct identification of the cause of failure, anatomic positioning of tunnels and careful, individualized rehabilitation protocol are the keys for success in a patient with realistic expectations.

- 01 Fig 1 Excessive anterior femoral tunnel location (MRI sagittal view)
- 02 Fig 2a Suitable femoral tunnel positioning leaving 2 mm of posterior wall (arthroscopic intraoperative view).
- 03 Fig 2b Intraarticular guide pin exiting at the anteromedial aspect of the ACL tibial footprint (arthroscopic intraoperative view from AL portal)
- 04 Fig 3a Intraoperative view during excision of bone-tendon-bone patellar tendon autograft.
- 05 Fig 3b Achilles tendon allograft exiting through the tibial tunnel during ACL reconstruction. Tibial fixation was achieved using two 8-mm metal staples.
- 06 Fig 4a Widened tibial and femoral tunnel (MRI sagittal view).
- 07 Fig 4b Tibial tunnel filling with allograft bone cancellous chips



## ISAKOS ASKS

**Tell us about yourself, and we will tell you where you sit in the crowd.**

The ISAKOS Newsletter Poll questions are available on the ISAKOS homepage – [www.isakos.com](http://www.isakos.com). Results and additional comments will be published in the next ISAKOS Newsletter.

### 1. Do you add Adrenaline to your Arthroscopy fluid?

1. Yes, always
2. Yes, only in the first couple of bags
3. Never

### 2. Do you read MR/CT imaging of your patients alone or rely on the written report sent?

1. Always read myself, every single one
2. Read myself only unique/complicated cases
3. Prefer to read these with my radiologists
4. I rely on the written report I get

### 3. Will you bring your family to ISAKOS in Lyon?

1. No
2. Only my spouse
3. I will bring my spouse and my kids along!

### 4. How many hours a day (average) do you think an orthopaedic surgeon should work?

1. 9
2. 11
3. 13
4. 15
5. 24

### 5. How would you rate your typing and computer skills?

1. 5 – Great, use it all the time, very proficient
2. 4
3. 3 – Fairly proficient, use occasionally
4. 2
5. 1 – Barely proficient, only use it when I have to

Visit Page 42 for the results of the ISAKOS Newsletter 2014: Volume II Poll

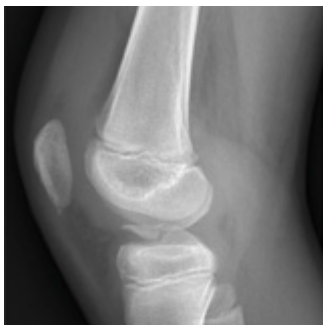## Arthroscopic All-Epiphyseal Suture-Anchor Fixation of Tibial Eminence Fractures



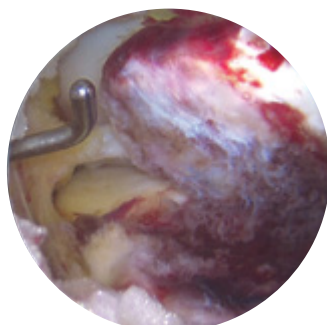Tigran Garabekyan, MD  
Huntington, WV, USA

### Background and Classification

Tibial eminence fractures are typically seen in children and young adolescents who sustain a low-energy, non-contact knee injury. The deforming force characteristically causes attenuation of the anterior cruciate ligament (ACL) prior to disrupting the incompletely ossified tibial eminence. If suspected, an MRI should be obtained to rule out concomitant injuries to the menisci, articular cartilage, and collateral ligaments.



01



02

The most commonly used classification system is that proposed by Meyers and McKeever who originally grouped the injuries into three types. Type I fractures are non-displaced and typically treated non-operatively in a cylinder cast. Type II fractures have anterior cortical displacement with an intact posterior hinge. If near anatomic reduction can be achieved with gentle knee extension, a Type II fracture may be treated non-operatively. Otherwise, with inadequate reduction (often due to interposed structures) or in the presence of concomitant injuries, operative treatment should be sought. Type III fractures are completely displaced and typically treated surgically (Fig. 1).

Zaricznyj later added a Type IV category to describe comminuted fractures, which was more relevant at the time due to implications for screw fixation.

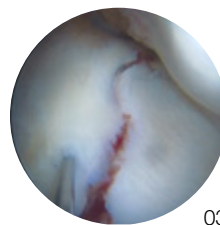
### Surgical Technique

Candidates for operative management are treated within 2–3 weeks of the injury to facilitate anatomic reduction. Early surgery also reduces the period of pre-operative immobilization as patients typically guard against motion due to pain and presence of lipohemarthrosis. The surgeon is prepared to address all concomitant injuries including articular cartilage lesions and meniscal tears, with efforts directed to preserve and repair native structures.

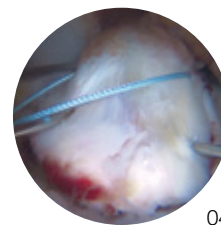
The operating room is equipped with 0.062" C-wires, a wire driver, standard knee arthroscopy instruments, and various suture anchors. Given the small size of the typical patient, a regular OR table, with the patient positioned centrally, is adequate for fluoroscopic visualization should it be desired. In the majority of cases, a fluoroscope is not utilized as direct visualization allows for excellent assessment. A bump is placed under the ipsilateral hip.

Standard diagnostic arthroscopy is performed utilizing anteromedial (AM) and anterolateral (AL) working portals, and a superomedial outflow portal. An accessory medial (AccM) portal is made to facilitate suture passage. The fracture fragment is assessed for size and extension into the medial and lateral compartments. With the knee at 90 degrees of flexion, the fracture bed is lightly debrided utilizing an oscillating shaver, removing interposed hematoma and fibrous tissue that would otherwise impede anatomic reduction. Care is taken to avoid aggressive debridement to preserve bone stock and native growth factors present in the fracture hematoma (Fig. 2).

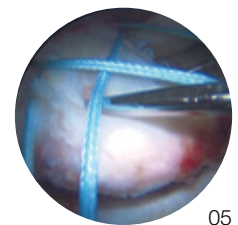
The next step involves reduction and provisional stabilization of the fragment to facilitate suture passage. While viewing with a 70-degree arthroscope through the AL portal, a 0.062" C-wire is inserted percutaneously at the medial border of the patella and advanced freehand to gently manipulate and depress the fragment into anatomic alignment. A probe is inserted through the AM portal and used to retract the intermeniscal ligament anteriorly while the fragment is manipulated with the C-wire. Following reduction, the intermeniscal ligament is released and rests on top of the fragment, stabilizing it from re-displacing. As the C-wire is advanced across the medial aspect of the fracture, the medial joint reduction is visualized and confirmed to be anatomic (Fig. 3).



03

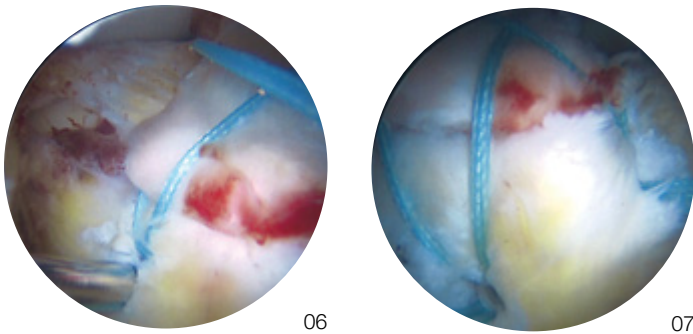


04

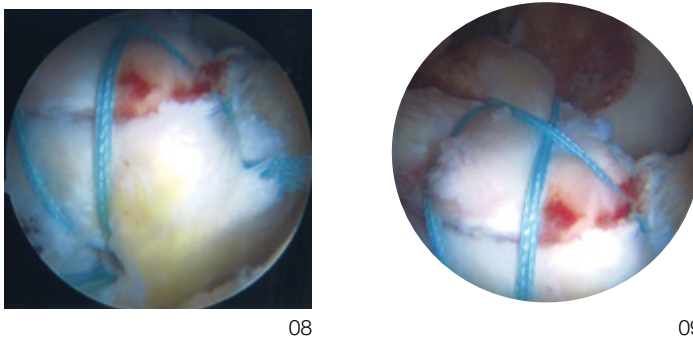


05



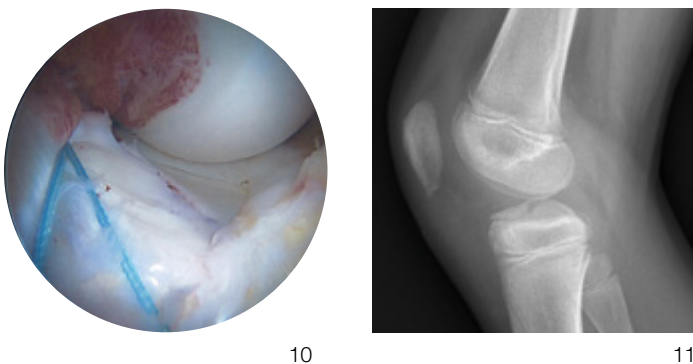


A second percutaneous 0.062" C-wire is inserted at the lateral border of the patella and advanced across the lateral aspect of the fracture. A fluoroscopic lateral may be obtained at this point to confirm reduction, however is often unnecessary due to excellent visualization. Number-2 braided high-strength non-absorbable sutures are preferred for repair. A 90-degree straight suture lasso is ideal when utilized through the AccM portal, with the nitinol wire retrieved through the AL portal for suture shuttling. The first suture is passed through the posterior substance of the ACL staying as distal as possible, close to the fragment. Proximal passage of suture will result in kinking and non-anatomic alignment of the ACL (Fig. 4).



The second suture is shuttled in identical fashion through the mid-substance of the ACL, again staying as distal as possible (Fig. 5).

The pre-tibial space is debrided to visualize the anterior cortex for suture-anchor placement. Care is taken to avoid injury to the perichondrial ring of LaCroix as dissection is kept proximal to the physis. Two knotless 2.9 mm biocomposite suture anchors (Arthrex Push-Lock) are utilized for fixation and C-wires are removed prior to tensioning (Fig. 6–9).



## Discussion

The technique presented in this article is novel and has many advantages. The all-epiphyseal technique avoids potential complications with tethered growth as may occur with screw fixation and suture fixation through bone tunnels. Additionally, biomechanical studies have demonstrated the efficacy of suture fixation across the base of the ACL with respect to stiffness and pull-out strength when compared with screw fixation. The novel use of suture anchors on the anterior face of the tibia reliably reduces the anterior cortical displacement and provides excellent compression at the fracture site. Alternative methods of suture anchor fixation have been described involving placement of anchors in the bony bed and performing single- and double-row repairs. It is the author's opinion that placement of suture anchors in the posterior fracture bed is rarely required for adequate compression, even in Type III fractures. This two-anchor technique is less expensive and less time consuming than alternative methods of suture anchor fixation. Additionally, with thoughtful application, the current technique allows for varying degrees of anterior translation of the fragment during reduction and tensioning. This feature may allow for a restoration of the normal functional tension of the attenuated ACL, thereby addressing the anterior-posterior laxity that typically results from this injury. It should be noted, however, that this laxity seldom results in functional instability following successful healing.

The key to an excellent functional outcome in treating tibial eminence fractures is to achieve stable, anatomic fixation allowing for early post-operative rehabilitation. The most common complication associated with surgical treatment of this injury is development of a flexion contracture and loss of quadriceps strength. Early return to weight bearing and knee range of motion is vital for an excellent functional outcome. The author recommends protected weight-bearing as tolerated in an unlocked hinged-knee brace and early quadriceps strengthening exercises focusing on achieving terminal knee extension.

- 01 Fig 1 A Type III fracture.
- 02 Fig 2 Elevated fracture fragment following light debridement of interposed hematoma to facilitate anatomic reduction.
- 03 Fig 3 Anatomic reduction of medial compartment with percutaneous 0.062" C-wire.
- 04 Fig 4 First suture shuttled through posterior ACL staying close to the fragment.
- 05 Fig 5 Second suture shuttled through mid-substance of ACL, again staying close to the fragment.
- 06 Fig 6 A 2.9 mm knotless suture-anchor (Arthrex Push-Lock) placed through the AL portal, proximal to the physis.
- 07 Fig 7 Epiphyseal placement of both knotless suture anchors.
- 08 Fig 8 Anatomic reduction and compression of fracture.
- 09 Fig 9 Anatomic reduction of fracture extension into medial compartment.  
Post-reduction (Fig. 10) and follow-up (Fig. 11) x-rays confirm anatomic reduction and bony union, respectively.
- 10 Fig 10 Immediate post-operative x-ray confirming anatomic reduction.
- 11 Fig 11 1-year follow-up x-rays showing complete union.

## The Pre Osteoarthritic Joint in Hip FAI: Is There a Role for Biomarkers?

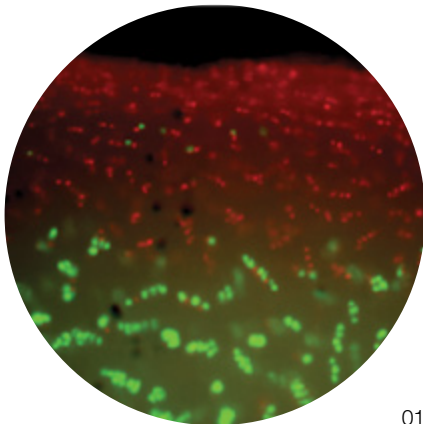


Cecilia Pascual-Garrido, MD  
Hip Preservation Center,  
Division of Sport Medicine  
University of Colorado  
Boulder, CO, USA

Additional Author:  
Omer Mei-Dan, MD  
Hip Preservation Center, Sport Medicine  
University of Colorado  
Boulder, CO, USA

Treatment of the pre-osteoarthritic joint disease is a new concept, which emphasizes the need of preventive strategies that will modify the course of a disease. Femoroacetabular impingement (FAI) is one of the most common mechanisms that lead to the development of early cartilage and labral damage in the non-dysplastic hip. Currently, surgical treatment of FAI is an effective, reliable, and safe method to relieve pain and improve function at short- to mid-term follow-up in patients without significant OA (osteoarthritis). However, when the procedure is done many of the joints have already entered the pre-osteoarthritic phase.

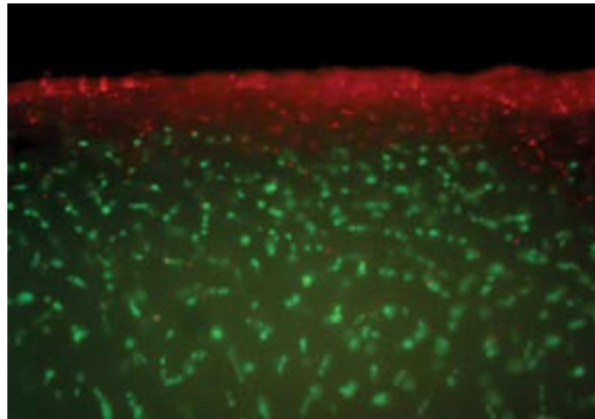
Early-stage or pre osteoarthritic disease is clinically silent in that structural changes typically precede clinical signs and symptoms of pain, deformity, functional limitations and disability. Metabolic changes in articular cartilage, synovium and subchondral bone may represent the earliest measurable changes in pre-OA conditions.



01

As such, identification and validation of biomarkers for pre-OA states at risk joints may have wide application in clinical trials of new intervention strategies. The ability to observe early and reversible cartilage damage supports the development of disease-modifying osteoarthritis drugs (DMOADs) such as P-188 or anticaspases (Fig. 1).

Many biomarkers of inflammation and cartilage turnover have been used to study the progression of OA. Particularly in Hip FAI, biomarkers have been shown to be elevated, suggesting that the cartilage from these patients is already being affected by this condition.



02

In the near future, we will stratify patients with regards to clinical, biomechanical, genetic and epigenetic profiles. For example, patients with symptomatic FAI could be stratified using biomarkers of cartilage disease and high-resolution MRI sequences combined with quantitative MR techniques that will provide accurate assessment of the cartilage tissue biochemistry. These patients, if shown to have already developed a “pre-osteoarthritic condition”, could then be offered a surgical treatment, coupled with DMOADs (disease-modifying osteoarthritis drugs) that could potentially reverse their cartilage to a healthy state.

That, in turn, will increase the chances of both post surgical symptomatic improvement and the prevention of future OA, compared with untreated patients with a pre-osteoarthritic condition.

Anti-apoptotic drugs applied immediately following acute injury reduce the development of post-traumatic cartilage degeneration and promote cell survival after a single impact to human ankle cartilage

- 01 Fig 1a Cartilage explant 7 days post injury. Note the great amount of dead cells (red cells), evident in all superficial, medial and deep layer.
- 02 Fig 1b When cartilage was pre-treated with P-188 before trauma, the dead cells are only evident in the superficial layer, suggesting the potential for prevention of cartilage degeneration after cartilage trauma.

## Pivot Study Group Project Update

### Pivot Study Group

Yuichi Hoshino, MD, PhD, Japan<sup>1</sup>

Additional Authors:

Volker Musahl, MD, USA<sup>2</sup>

Ryosuke Kuroda, MD, Japan<sup>1</sup>

Stefano Zaffagnini, MD, Italy<sup>3</sup>

Kristian Samuelsson, MD, PhD, MSc, Sweden<sup>4</sup>

Nicola Lopomo, PhD, MSc Eng, Italy<sup>3</sup>

James J. Irrgang, PT, PhD, ATC, FAPTA, USA<sup>2</sup>

Chad J. Griffith, MD, USA<sup>2</sup>

Jon Karlsson, MD, PhD, Sweden<sup>4</sup>

Freddie H. Fu, MD, USA<sup>2</sup>

<sup>1</sup> Kobe University, Kobe, JAPAN

<sup>2</sup> University of Pittsburgh, Pittsburgh, PA, USA

<sup>3</sup> Bologna University, Bologna, ITALY

<sup>4</sup> University of Gothenburg, Gothenburg, SWEDEN

ISAKOS is world renowned as an international society of expert orthopaedic surgeons, which provides and enhances the standard of medical care in sports medicine. The wide diversity of languages spoken during ISAKOS meetings is analogous to the worldwide lack of standardization in the pivot shift test. Due to its global influence, no group outside of ISAKOS could establish a globally accepted standardized language for evaluation of knee rotational laxity.

During the 8th ISAKOS congress in Rio de Janeiro, Brazil, the very first conversations were held regarding the lack of standardization in clinical evaluation for rotational laxity in the ACL injured knee. A study group was formed to establish a standard and clinically relevant objective measure of the pivot shift test.

There were numerous issues in the evaluation of rotational laxity. Several quantitative measurement tools had been developed to assess the pivot shift test, but they had not been validated. In addition, the execution of the testing maneuver was quite varied from place to place. To date, there are no measurement systems for the pivot shift test which accurately evaluate knee function and joint pathology, as well as guide surgical decision-making and predict outcomes.

The PIVOT group determined that a clinically relevant, objective, and comparable measurement should be established for the evaluation of the knee rotational laxity. As a first step, a preliminary in-vitro study was conducted in 2011 during the Panther Summit meeting in Pittsburgh, USA, to provide scientific base of the quantitative pivot shift measurement systems. As a result, some measurement tools were validated by comparing the direct bony measurement and the benefit of the standardized testing maneuver was demonstrated to reduce the measurement variability. Based on that basic study, an international multicenter clinical study was designed with funding applied for through the ISAKOS/OREF Research Grant.

In short, over 100 ACL injured patients have had their knees tested by the standardized pivot shift test (Fig. 1). The knee movement is quantitatively measured by two systems, an image based iPad system and inertial sensors in the same manner (Fig. 1).

Pre- and post-operative evaluations are collected and compared to several clinical measures, such as subjective knee function, clinical pathology, and outcome after the ACL reconstruction.

Our intermittent results of this multicenter study have been presented in previous meetings (Fig. 2). Principal preliminary results were:

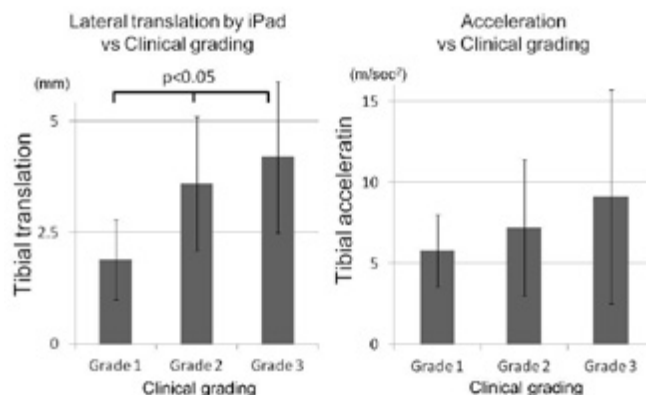
- 1) possible relationship between quantitative measurement and clinical grading of the pivot shift test (Fig. 2),
- 2) successfully reduced rotational laxity by the ACL reconstruction, and
- 3) mutual validation between iPad and inertial sensor systems.

The ultimate goal of this study group is to establish a universal, reproducible, and clinically relevant objective measurement of the pivot shift test. The common language for addressing rotational instability will be available in near future through ISAKOS. We are always welcome to your questions and suggestions.

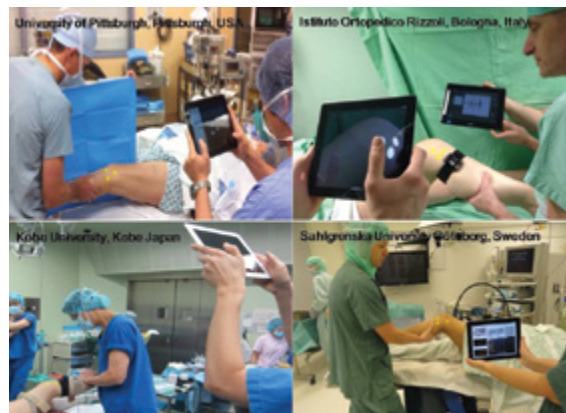Please feel free to contact us

Volker Musahl: [musahlv@upmc.edu](mailto:musahlv@upmc.edu)

Yuichi Hoshino: [you.1.hoshino@gmail.com](mailto:you.1.hoshino@gmail.com)



01



02

- 01 Fig. 1 Simultaneous measurement of the pivot shift test using iPad and accelerometer in four institutions.
- 02 Fig. 2 Intermittent result of pivot shift measurements in 33 ACL deficient knees. Tibial translation measured by iPad demonstrated stepwise increase along with clinical grading (Left). Tibial acceleration measured by the accelerometer had a similar tendency without a statistical significance.



## Double Bundle Medial Patellofemoral Ligament Reconstruction



David Sadigursky, MD, MSc  
*Manoel Victorino Hospital/Faculty  
 of the COT Hospital  
 Salvador, Bahia, BRAZIL*

The medial patellofemoral ligament (MPFL) is the major restraint that prevents lateral translocation of the patella. In most patients, the MPFL is torn during acute patellar dislocation. Because of this, several surgical techniques have been described for the treatment of patellar instability. Surgical treatment is accepted as necessary for the restoration of the stability of the MPFL.

Despite the biomechanical importance of MPFL reconstruction, its value was appreciated only relatively recently, particularly over the last two decades. Although a wide range of techniques have been described for MPFL reconstruction, with different graft sources and fixation methods, accumulating evidence shows good clinical results of this surgery, with a very low recurrence rate of instability.

A major concern is the consequence of a graft positioning error in MPFL reconstruction. Small errors of 5 mm in the ideal position or graft tension  $> 2\text{N}$  are known to lead to increased joint forces on the medial facet of the patella, increasing the risk of pain and degeneration of the patellar cartilage. This leads to the need for techniques that can distribute the graft tension on the patella, reproducing the anatomy more closely.

However, Sandmeier et al. and Parker et al. showed that isolated MPFL reconstruction was unable to restore normal patellar tracking through medium and maximum flexion. Failure to restore proper anatomy or isometry of the MPFL may be responsible for this issue, thus limiting the long-term success of such reconstruction.

In 2010, Kang et al. introduced the concept of MPFL bands. The ligament has a thin layer that connects the femoral condyle to the supramedial border of the patella. From the femoral origin, MPFL fibers become larger, forming two bands, named by the authors as the inferior straight bundle (ISB) and superior oblique bundle (SOB). However, the two bands do not separate completely, forming a single structure. The lower fibers act as the static restraint, and the upper fibers act in the dynamic stabilization of the patella owing to their close association with the vastus medialis obliquus tendon.

MPFL reconstruction has become the technique of choice for most authors since the 1990s, even in cases where trochlear dysplasia and patella alta are identified. Isolated MPFL reconstruction has been shown to be a suitable and effective technique for the correction of patellar instability, except in cases where the tibial tuberosity-trochlear groove (TTTG) distance is longer than 20 mm.

In 2010, Kang et al. described the anatomy and function of the MPFL and their two bands. The superior oblique bundle together with the vastus medialis obliquus exerts traction on the patella, medially promoting a dynamic restraint. Meanwhile, the lower inferior straight bundle acts as a static restraint to balance the resulting lateral forces that act on the patella, caused by the Q angle. Thus, reconstruction of the two bands could increase the stability during the first flexion angles around  $30^\circ$ . The function of the MPFL at greater angles requires more elucidative studies.

Despite the MPFL being the primary stabilizer against patellar dislocation between  $30^\circ$ – $40^\circ$  of flexion, Philippot et al. described the role of the medial patellotibial (MPTL) and the medial patellomeniscal (MPML) ligaments acting on the rotation, tilt, and dislocation at angles greater than  $45^\circ$ . The reconstruction of the MPTL is gaining popularity both in patients with open physes and in adults. During the arc of motion from total extension to flexion of  $90^\circ$ , the MPTL and MPML contribute 28%–48% against the lateralization of the patella, 23%–71% against tilt, and 32%–92% against rotation. This finding cannot be disregarded in the planning of the correction of patellar instability. Despite the growing interest in the reconstruction of MPTL, with the aim of reducing dislocation of the patella at larger angles, possibly eliminating the inverted J sign, no data so far show the superiority of clinical outcomes in the combined reconstruction of the MPFL and MPTL with the double- or single-bundle technique.

Applying the MPFL reconstruction technique with the use of metal anchors has shown that the resistance is appropriate for achieving restraint against dislocation of the patella, especially in the early knee flexion angles. The MPFL tensile strength is relatively low, around 208 N, making the implant useful in fixing the graft. Mountney et al. showed no significant difference in tensile strength between the passage of the graft through bone tunnels and anchor fixation. Comparing the bone tunnels and anchor fixation, Hapa et al. did not find differences, although anchor fixation showed less stiffness. Bone tunnels were also demonstrated to enable better integration of the graft. As stated by Song et al., tendon-to-bone healing also occurs in the anchor fixation technique, as a bone bed in the medial border of the patella is made to accommodate the graft, which is then covered by the layer of periosteum and medial retinaculum.

Patellar fracture and cartilage perforation were described as among the possible complications of the patellar bone tunnel fixation technique. These complications were not found in studies that used anchor fixation. This fact is due to the non-perforation of the patella with drills, which require greater technical precautions in order to avoid these complications, particularly in patients with smaller patellae, such as Asians or people of short stature.

An advantage of using the anchor fixation technique is the possibility of using a graft of shorter length, as in the case of the gracilis tendon. Furthermore, the procedure allows for smaller incisions with better aesthetic results. This is because less exposure is required, as looping the graft through the lateral facet of the patella or to expose the bone tunnels is not necessary. Corroborating the opinion of Song et al., another advantage is that it is a relatively simple technique, which results in shorter surgical time and decreased exposure to radiation.

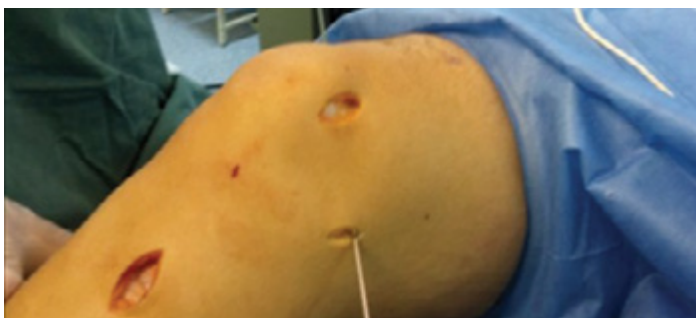Straight lateral radioscopy was used to identify the femoral insertion site of the graft in all cases, following the parameters described by Schöttle et al. According to studies by Schöttle et al., the use of radioscopy is considered of great importance in determining the ideal anatomical point for graft fixation in the femur. Several authors have shown that non-anatomical positioning of the femoral tunnel interferes with the patellofemoral kinematics. Elias and Cosgarea found that the tunnel positioning error, more proximal in the femur, can overload the medial compartment of the patella, which can lead to degeneration of the medial facet and graft rupture or failure. Similarly, Thauinat and Erasmus suggested that non-proximal anatomical positioning of the graft would lead to hypertensioning of the graft and consequently to knee rigidity. A more distal positioning is not able to tension the graft enough to restrict dislocation of the patella. Amis et al. found that the positioning error in the frontal plane is better tolerated.

Kang et al. suggested that the fixation of the MPFL bands should be performed at different angles, with the ISB at 0° and the SOB at 30°. In this way, the patellar stability can be maintained at higher flexion angles such as at greater than 60°.

### Surgical Technique

The patient was placed in the supine position under spinal anesthesia. First arthroscopy was performed to identify associated lesions or to remove intra-articular loose bodies. Lateral retinacular release was not performed in any of the cases.

The gracilis tendon was removed through an incision of about 2 to 3 cm above the pes anserine tendons. The "goose foot" bursa was removed, and the semitendinosus tendon was exposed and resected. The gracilis tendon was considered sufficient due to its resistance, which is compatible with what is expected for MPFL, which is 208 N. However, the semitendinosus tendon was used, as it was long enough to permit the preparation of the two bundles, with the passage of the graft through the bone tunnel in the femur.



Then, an incision was made under the medial border of the patella at a distance of 4 to 5 cm between the medial border of the patella and the medial epicondyle of the femur. With the aid of a curette, a sulcus was made on the medial border of the patella, above the transition with the posterior chondral facet, deep enough to accommodate the graft. Two 5-mm metal anchors were inserted into the proximal two-thirds of the patella, 10 to 15 mm from the joint.

The anatomical site on the femur was confirmed with the aid of straight lateral radioscopy, following the parameters described by Schöttle et al. A Kirschner wire was inserted at this point, directed anteriorly and proximally, thus avoiding penetration into the posterior region of the femoral condyle. The femur was drilled to create the bone tunnel, and the central part of the graft was first fixed at this point by using the bioabsorbable interference screw. Next, the two bundles of the graft were passed through the patella by the second layer of the medial retinaculum, with the aid of curved forceps. The two ends of the graft were sutured separately by the anchors. The first bundle, considered as the inferior straight bundle, was set at 30° of flexion; and subsequently, the superior oblique bundle was set at 60° of flexion (Kang et al., 2010, Han et al. 2011 Sadigursky et al. 2012). The required tension was checked by the mobility of the patella, which can reach glide approximately 2 quadrants.

After fixation, the position of the patella was checked by using arthroscopic imaging. Local irrigation was performed with 0.9% physiological saline, the subcutaneous tissue was sutured with Vicryl 2.0, and the skin was sutured with separate stitches of Nylon 3.0.

### Postoperative Period

The knee was immobilized in extension with a long brace for 2 weeks. Physical therapy was initiated in the first week with a progressive increase in the arc of motion and should reach 120° of flexion during the sixth week. During the first 3 weeks, partial load with the aid of crutches was allowed. After the third week, the patient was allowed to bear full load without crutches. Isometric exercises to strengthen the quadriceps and elevation of the leg in extension were permitted in the immediate postoperative period. After 6 weeks, the patient should be able to return to normal activity. Contact sports and rotation were allowed at 6 months after surgery.

### Conclusion

The double bundle MPFL reconstruction at different angles of flexion, or at the same angle fixing on the patella first, aims to gain stability at higher flexion angles, specially above 45 degrees of knee flexion. Nevertheless more clinical trials should be conducted in the future, especially with the combined medial patellotibial ligament reconstruction, which seems to have similar goals in adult patients. In addition, more precise stratification of the patients should be considered for the elective patients that should undergo the technique.

## ISAKOS Clinical Update on Stress Fractures: Classification and Management



Timothy L. Miller, MD  
Granville, OH, USA



Christopher C. Kaeding,  
MD  
Director of Sports Medicine  
The Ohio State University  
Columbus, OH, USA

Stress fractures are not a single consistent injury. They occur along a spectrum of severity that impacts treatment and prognosis. Not only does the extent of the fracture vary, but the clinical behavior varies by location and causative activity. An understanding of common sport-specific stress injuries can help the clinician in the diagnosis, prevention, and treatment of these sports-related stress injuries. The most frequently reported anatomic sites of stress fractures in the literature involve the tibia, metatarsals, and fibula.

When treating these injuries, it should be borne in mind that no two stress fractures behave exactly alike. Treatment protocols should be individualized to the patient, the causative activity, the anatomical site, and the extent of the fracture. As athletes become more competitive and focus solely on one sport, the incidence of stress fractures continues to increase. A holistic approach to the treatment of these injuries should be taken.

### Pathophysiology

Stress fractures are a fatigue failure of bone. These stress injuries result from an overuse mechanism. Repeated episodes of bone strain can result in the accumulation of enough microdamage to become a clinically symptomatic stress fracture. Any stress or load causes some strain of or deformation to bone, and any strain of bone results in some microdamage. Healthy bone is in homeostasis between microcrack creation and repair.

Fatigue failure of bone has three stages: crack initiation, crack propagation and complete fracture.

Crack initiation typically occurs at sites of stress concentration during bone loading. Crack propagation occurs if loading continues at a frequency or intensity above the level at which new bone can be laid down and microcracks repaired. Continued loading and crack propagation allows for the coalescence of multiple cracks to the point of becoming a clinically symptomatic stress fracture. If the loading episodes are not modified or the reparative response is not increased, crack propagation can continue until structural failure or complete fracture occurs.

Through the adaptive process of remodeling, bone is able to respond to crack initiation and propagation such that the loaded bone is strengthened in preparation for future loading. This positive adaptive response is known as Wolff's law and is an essential part of bone health.

### Risk Factors for Stress Fractures

A variety of biological and mechanical factors are thought to influence the body's ability to remodel bone and therefore impact an individual's risk for developing a stress fracture. These include, but are not limited to sex, age, race, hormonal status, nutrition, neuromuscular function, and genetic factors. Other predisposing factors to consider include abnormal bony alignment, improper technique/biomechanics, poor running form, poor blood supply to specific bones, improper or worn-out footwear, and hard training surfaces. It is important to remember that the cause of stress fractures is multi-factorial, and individual athletes will vary in their susceptibility to stress injuries.

The key modifiable risk factors in the development of overuse injuries of bone relate to the pre-participation condition of the bone and the frequency, duration and intensity of the causative activity. Without pre-conditioning and acclimation to a particular activity, athletes are at significantly increased risk for the development of overuse and fatigue-related injuries of bone. Multiple intrinsic and extrinsic factors can influence the balance between the creation/propagation of microcracks and the body's ability to repair them.

### Classification/Grading

Stress fractures are classified in multiple ways but most commonly by the size of the fracture line seen on imaging, the severity of pain or disability, the biologic healing potential of the particular injury or location, the natural history of the particular fracture, or some combination of these parameters. The classification of stress fractures as either "high-risk" or "low-risk," has been suggested by multiple authors. High risk stress fractures have at least one of the following characteristics: risk of delayed or non-union, risk of refracture, and significant long term consequences if they progress to complete fracture.



Table 1 shows a list of anatomic locations considered high-risk for stress fractures. This distinction allows clinicians to quickly determine if they can be aggressive or conservative with the decision to return an athlete to training or competition.

<b>Table 1: Anatomic Sites for High-Risk Stress Fractures</b>
Femoral neck (Tension side)
Patella (Tension side)
Anterior Tibial Cortex
Medial Malleolus
Talar neck
Dorsal tarsal Navicular Cortex
5th Metatarsal Proximal Metaphysis
Sesamoids of the Great Toe

01

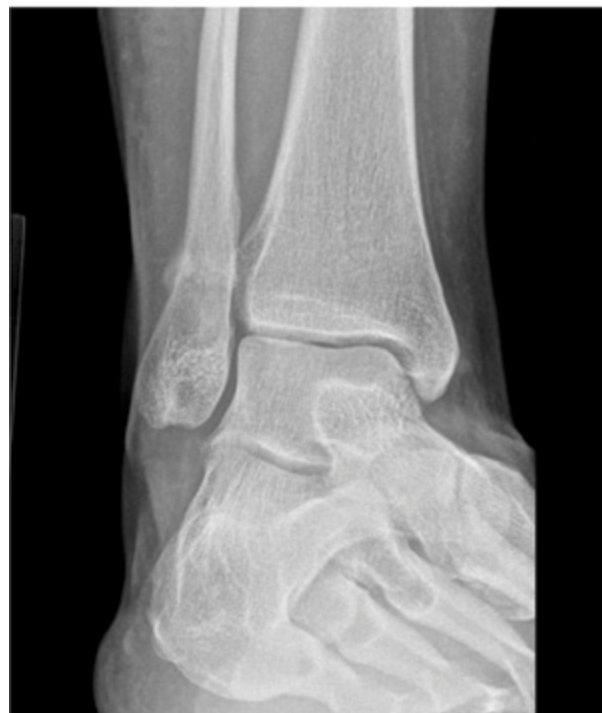In addition to knowing the classification of whether a stress fracture is high risk or low risk as determined by its anatomic site, the extent of the structural failure or “grade” of the stress fracture is also needed to completely describe the injury and make appropriate treatment plans. As described above, stress injuries to bone occur on a continuum from simple bone marrow edema (stress reaction) to a small microcrack with minor cortical disruption to a complete fracture with or without nonunion. The management of bony stress injuries should be based on the location and grade of the injury.

<b>Grade</b>	<b>Pain</b>	<b>Imaging Findings</b> (X-ray, Bone Scan, CT, MRI)
I	(-)	Evidence of Stress Injury
II	(+)	no fx line
III	(+)	fracture line
IV	(+)	displaced
V	(+)	non-union

02

Recently Kaeding and Miller proposed a comprehensive descriptive system for stress fractures. This includes a grading scale for classifying the extent of structural failure from Grade 1 to Grade 5. Grade 1 injuries are asymptomatic, usually incidental findings on imaging studies. Grade 2 injuries have imaging evidence of fatigue failure of bone, but no fracture line (Fig. 3). Grade 3 injuries have a fracture line with no displacement (Fig. 1 and 4). Grade 4 fractures are displaced (Fig. 5), and Grade 5 non-union of stress fracture (Fig. 3). This system is summarized in Table 2.

Two key features of the Kaeding-Miller system are that it is generalizable and has been validated with intra- and inter-observer reliability. This classification system has been shown to have high inter- and intra-observer reliability. Coupling this fracture grade with the location of the fracture provides a more comprehensive description of the injury that takes into account both the extent of structural failure and healing potential of the injury. When reporting the stress fracture grade in this system, the imaging modality used should be reported. Almost perfect intra-observer agreement was found among fifteen evaluators of the classification system which included orthopaedists, primary care sports medicine specialists, and physician assistants. Substantial to almost perfect inter-observer reliability was observed for the classification grades among the same evaluators.



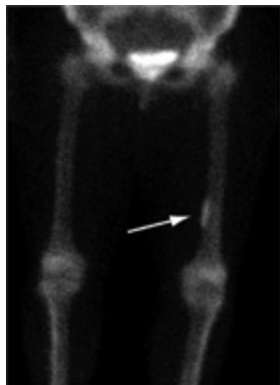03

### High Risk Stress Fractures versus Low Risk Stress Fractures

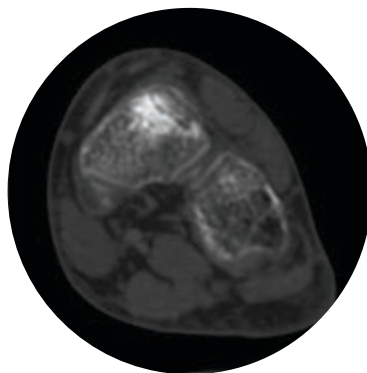
Low-risk stress fractures include the femoral shaft, medial tibia, ribs, ulnar shaft, and 1st through 4th metatarsals, all of which have a favorable natural history. These sites tend to be on the compressive side of the bone, and respond well to activity modification. Low-risk stress fractures are less likely to reoccur, develop nonunion, or have a significant complication should it progress to complete fracture.

**ISAKOS Clinical Update on Stress Fractures: Classification and Management**

Not only do fractures at high risk anatomical sites have a predilection to progress to complete fracture, delayed union, or nonunion, have a re-fracture, or have significant long term consequences should they progress to a complete fracture, but they also often have worsening prognosis if they have a delay in diagnosis. A delay in treatment may prolong the patient’s period of complete rest of the fracture site and potentially alter the treatment strategy to include surgical fixation with or without bone grafting. Due to their location on the tension side of the respective bones, these fractures possess common biomechanical properties regarding propagation of the fracture line. In comparison to low-risk stress fractures, high-risk stress fractures do not have an overall favorable natural history. With delay in diagnosis or with less aggressive treatment, high-risk stress fractures tend to progress to nonunion or complete fracture, require operative management, and recur in the same location.



04



05

**Rib and Upper Extremity Stress Fractures**

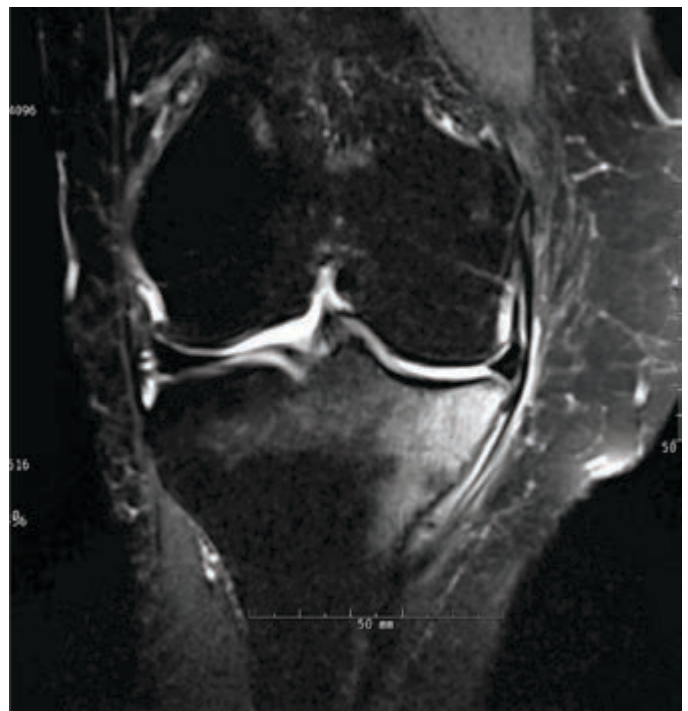Though over 90% of stress fractures occur in the lower extremities as a result of impact loading, athletes who perform repetitive tasks with the shoulder and upper extremity may also develop stress injuries of bone. Rib and shoulder girdle stress fractures are most commonly reported in rowers and throwing athletes along with those requiring repetitive rotation of the torso. The most common mechanisms for these injuries involve repetitive bony torsion, weight bearing, and muscle contraction overload. Any athlete complaining of the non-traumatic onset of pain in the ribs or upper extremity that occurs during or shortly after the repetitive activity should raise concern for a possible stress fracture.

In recent years, there has been increased attention focused on upper extremity stress fractures, and case reports of these injuries have increased in athletes such as baseball players who train continuously for one sport. Incidence has also paralleled the increase in popularity of cross-fit sports. In 2012 Miller et al. reviewed 70 cases of stress fractures of the ribs and upper extremity, the largest series in the literature. The authors noted that individuals performing weight-bearing activities of the upper extremity (e.g. gymnastics, cheerleading) developed nearly all of their stress fractures at or distal to the elbow, indicating that with such activities significant bony overload occurs in the distal upper extremity as opposed to the proximal portion.

The great majority of rib and upper extremity stress injuries are considered low-risk and usually require only activity modification to heal. One of the few exceptions to this that may require surgical intervention is the olecranon stress fracture in a competitive thrower (Fig. 5). Though this injury has the potential to heal with conservative management, when a fracture line (Grade 3 injury) is discovered in a throwing athlete’s olecranon process, internal fixation is the ideal treatment.

**General Treatment Principles**

Treatment principles for stress fractures include re-establishing the normal balance between the creation and repair of microcracks in bone. In order to decrease the creation of microcracks one must evaluate the patient’s training regimen, biomechanics, and equipment. In order to maximize the patient’s biologic capacity to repair microcracks, one must evaluate the general health of the patient, including nutritional status, hormonal status and medication use. The clinician should be aware of the female athletic triad and its potential detrimental effect on healing potential.



06

## Management of High-Risk Stress Fractures

Treatment decision-making for high-risk stress fractures should be based on radiographic findings with less consideration given to symptom severity. The immediate goal of treatment of a high-risk stress fracture is to avoid progression and get the fracture to heal. Typically this requires either complete elimination of loading of the site or surgical stabilization. Ideally while the fracture is healing, one works to avoid deconditioning of the athlete while minimizing the risk of a significant complication of fracture healing. While over-treatment of a low-risk stress fracture may result in unnecessary deconditioning and loss of playing time, under-treatment of a high-risk injury puts the athlete at risk of significant complications. In this case relative rest may be achieved with alternative training options such as aquatic training which may include an aquatic treadmill or suspended treadmill training.

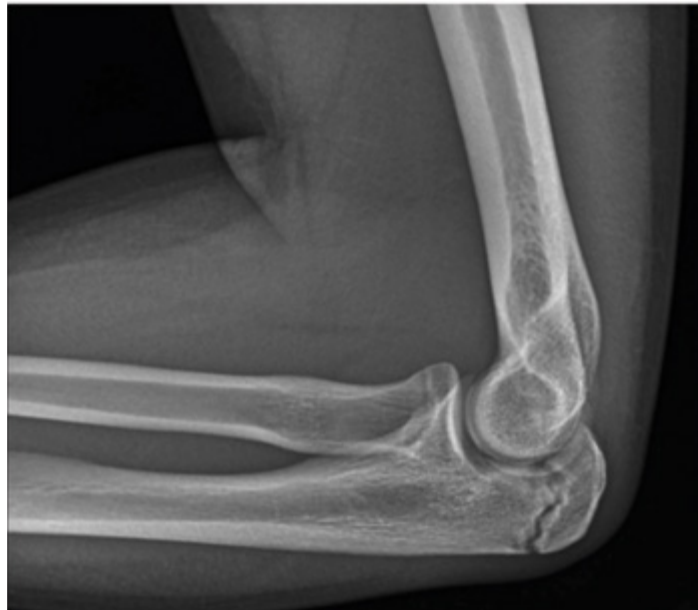The presence of a visible fracture line on a plain radiograph in a high-risk stress fracture should prompt serious consideration of operative management. If an incomplete fracture is present on plain films with evidence of fracture on MRI or CT in a high-risk location, immobilization and strict non-weight bearing is indicated. Worsening symptoms or radiographic evidence of fracture progression despite non-operative treatment is an indication for surgical fixation.

All complete fractures at high-risk sites should receive serious consideration for surgical treatment. In summary, surgical fixation should be considered for high risk stress fractures for several reasons. These include expediting healing of the fracture to allow earlier return to full activity as well as to minimize the risk of non-union, delayed union and re-fracture. Finally, surgical intervention may be necessary to prevent catastrophic fracture progression such as in the case of a tension-sided femoral neck fracture.

## Return to Sports Participation

Generally in athletes, return to play should only be recommended after proper treatment and complete healing of the injury. Because of the significant complications associated with progression to complete fracture, it is not recommended that an individual be allowed to continue to participate in their activity with evidence of a high-risk stress fracture. Return to play decision-making for a low grade injury at a high-risk location should be predicated on the patient's compliance level, healing potential, and risk of worsening of the injury. A key difference between a low-grade stress fracture at a high-risk location versus a low-risk location is that with the low-risk site the athlete or patient can be allowed to continue to train, whereas the high-risk site needs to heal prior to full return to activity.

Regardless of the grade and location, the risk of continued participation should be discussed with each athlete, and the management of each fracture should be individualized. Cross-training while resting from the inciting activity allows maintenance of cardiovascular fitness while decreasing stresses at the healing fracture site.



07

Return to participation should be a joint decision between the physician, athletic trainer, coach, and athlete. If a stress fracture is diagnosed in the non-competitive season, most athletes seek to achieve complete healing prior to return to training or competition. If the injury occurs at mid-season or in the championship season, elite athletes may limit the volume and intensity of their training while continuing to compete. Complete healing of the fracture is then sought once the season is over.

## Summary

Stress fractures are common injuries in highly active individuals. An understanding of the pathophysiology coupled with a clinically relevant classification system aids the clinician in their treatment decision-making. The authors' suggest using the grade of the fracture and its location (high vs low risk) as the classification system for stress fractures. Stress fracture management and return to play considerations should employ a holistic approach and be individualized to the patient taking into consideration injury site (low vs. high risk), grade (extent of structural failure), the individual's activity level, competitive situation, and risk tolerance.

- 01 Table 1 Anatomic Sites for High-Risk Stress Fractures
- 02 Table 2 Kaeding-Miller Stress Fracture Classification System
- 03 Fig 1 Oblique radiograph of a healing nondisplaced Grade 3 distal fibular stress fracture in a 19 year old female military recruit. Callus formation is evident after 6 weeks of activity modification.
- 04 Fig 2 Nuclear bone scintigraphy image of a 22 year old male distance runner with ongoing distal thigh pain. A grade 2 stress fracture is present of the left distal femur.
- 05 Fig 3 Coronal CT scan of a Grade 5 tarsal navicular stress fracture in an 18 year old high school football player. Evidence of a nonunion is present.
- 06 Fig 4 Coronal T2 MRI of a 36 year old professional golfer with medial knee pain. A grade 3 stress fracture is present at the medial proximal tibia.
- 07 Fig 5 Lateral radiograph of the elbow of a 24 year-old semi-professional baseball pitcher with a displaced (Grade 4) olecranon stress fracture.



## Blood Control in Total Knee Arthroplasty



David Sadigursky, MD,  
MSc  
*Orthopedic and Traumatologic  
Clinic–COT  
Hospital Manoel  
Victorino–Attending Surgeon;  
Faculty of the Orthopedic  
and Traumatology Fellowship  
Program  
Salvado, BA, BRAZIL*

The total knee arthroplasty (TKA), as any surgical procedure, is liable to a series of post-operative complications, such as, particularly in this procedure, excessive blood loss associated, prolonged hospitalization, with an increase in hospital expenses and a decrease in patient satisfaction.

Aiming to minimize intra- and postoperative bleeding as well as their complications, some alternatives are constantly studied. Among them, we find in the literature the use of hypotensive anesthesia, tourniquet use, intraoperative blood salvage, re-infusion drains, radiofrequency bipolar, or manipulation of the coagulation cascade, adrenaline, fibrin glue sprays, FloSeal®, auto-transfusion, as the most common procedures. The use of the plasminogen-activator inhibitor tranexamic acid (TA) has arisen interest as an inexpensive agent to be held in surgical procedures worldwide. Thus, the analysis of the clinical efficacy of the use of TA in reducing blood loss in TKA is of paramount importance as the current literature lacks clarity regarding the best dosage and the most effective timing of administration.

Different dosages and method of TA application can be found in the literature and can be shown in Table 1, according to the RCTs analysed.

Author and publishing year	Type of Intervention
Aguilera X et al., 2013	Use of fibrin glue, fibrinogen and troponin, and intravenous tranexamic acid
Pachauri et al., 2013	02 doses of tranexamic acid, injection, first dose one hour preoperatively and six hours postoperatively
Kim TK et al., 2013	01 dose before incision and a dose (10mg.kg-1) of tranexamic acid before tourniquet deflation
Roy SP et al., 2012	Use of tranexamic acid, 5ml, administered intra-articularly after the procedure
Wong J et al., 2010	Use of tranexamic acid 1.5 to 3.0 g applied for five minutes in the joint at the end of surgery
Kankar PN et al., 2009	Use of tranexamic acid 10mg.kg-1 just before inflation of the tourniquet followed by 1mg.kg-1 until the end of the procedure
Camaras et al., 2006	Use of tranexamic acid 10mg.kg-1 just before inflation of the tourniquet followed by 1mg.kg-1 until the end of the procedure

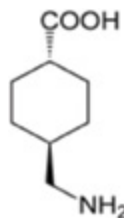01

At our institution, we performed a systematic review selecting papers analysing the effectiveness of TA in TKA over the last 10 years. In the first search, 59 articles were found of which seven randomized control trials (RCT) met the inclusion criteria and were selected with a total sample of 948 patients. After the analysis of and the comparison between the studies included in this work we can conclude that the use of TA in TKA, whether unilateral or bilateral, reduces blood loss in peri- and postoperative procedures significantly when compared to other antifibrinolytic agent. With the reduction of total blood loss, decrease in hemoglobin and haematocrit rate, and the reduction in the need for blood transfusions, the use of tranexamic acid has being demonstrated to be safe with no increase in side effects, such as venous thromboembolism. The use of TA as a hemostasis mechanism can reduce costs and shorten hospital stays, also avoiding the use of autologous blood transfusion.

The TA, synthetic antifibrinolytic agent, presents in its formula the trans isomer of the 4-amino-methyl-cyclohexane carboxylic acid (Transamin<sup>®</sup>), a synthetic derivative of the lysine amino acid, which acts through competition inhibiting the activation of both the plasminogen and the plasmin. This formula is strongly attracted to the lysine binding both in the plasminogen and the plasmin, thus competitively inhibiting plasmin activation and activity. Its action is fundamentally based on the slowing of the process of fibrinolysis (potent inhibitor of plasmin fibrinolytic action), a later stage to clot formation, causing the time of fibrin network dissolution to extend (Dunn & Goa, 1999).

This way, clotting is preserved, despite not resulting in activation of the coagulation cascade. These properties increase the haemostatic efficiency of the substance, reducing the intensity and the risk of bleeding in surgical procedures, as well as traumatism and diseases with bleeding tendencies. The acid in question has rapid absorption; about 90% of an intravenous dose is excreted through urine in 24 hours, with a plasma half-life of approximately 2 hours, while maintaining therapeutic levels for 6–8 hours. (Kim, 2014)

Based on the meta-analysis by Tan et al., in 2013, in our institution, the TA is administered at a dose of 10mg/kg before inflating the tourniquet, repeating the dose right before its released. A new dose may be applied six hours after the end of surgery, which has been demonstrated as effective when it comes to after surgery hemostasis improvement. (Maniar et al., 2012)



02

When comparing the use of intravenous tranexamic acid with fibrin glue and hemostasis using Tissucol (fibrinogen and thrombin). The results of this study revealed less blood loss in the group, which used tranexamic acid as hemostasis when compared with the use of Tissucol.

Nonetheless, in this study, the use of TA added to the topical application of fibrin glue around osseous tissues presented no benefits on this combined procedure. No complications were reported in any group. In this study we observed a small number of patients in each group, which may have influenced the results collected. (Aguilera et al., 2013) The TA has also the advantage of being significantly less expensive than fibrin spray. (Molloy et al., 2007)

The topical application of TA, which is also used in different methods of application, is gaining popularity due to existing concerns about the safety of intravenously applied TA. As long as the topical application works directly on the source of bleeding, it may be considered a safe and effective method, which reduces the systemic effects. In a meta-analysis, Panteli et al. (2013) confirmed the efficacy and safety of topical TA, using a dosage of 50mg to 3g of TA associated with saline solution from 5ml to 100ml. Topical application methods vary among authors, the most common ones being the application for 5 min before removing the tourniquet and 3–5 min after the operation. The dosage above 2g of topic TA has proven more effective in reducing blood transfusion after TKA. (Dang and Schwarzkopf, 2013)

Despite the use of TA, both intravenously and topically, TKA postoperative bleeding remains an issued to be solved. New agents must be produced with greater effectiveness in transfusion rate reduction.

To date the amount of published studies, with a large number of RCTs and systematic reviews, give us the necessary support for their use, which should be used more widely. More studies should be carried out in order to standardize the optimal method of application, in regards to the the frequency, time of administration and dosage. A cost-benefit analysis should be undertaken to quantify its salutary effects in decreasing perioperative blood transfusions, minimizing transfusion related complications, and reducing overall health care costs. (Georgiadis et al., 2013)

01 Table 1 Methods of application cited in articles.

02 Fig 1 Chemical structure of tranexamic acid. (Dang and Schwarzkopf, 2013)

## Treating Patellofemoral Cartilage Lesions



Aaron J. Krych, MD  
Associate Professor, Mayo Clinic  
Rochester, MN, USA

Additional Authors:

Bruce A. Levy, MD

Professor, Mayo Clinic, Rochester, MN, USA

Norimasa Nakamura, MD, PhD, FRCS

Professor, Institute for Medical Science in Sports, Osaka, JAPAN

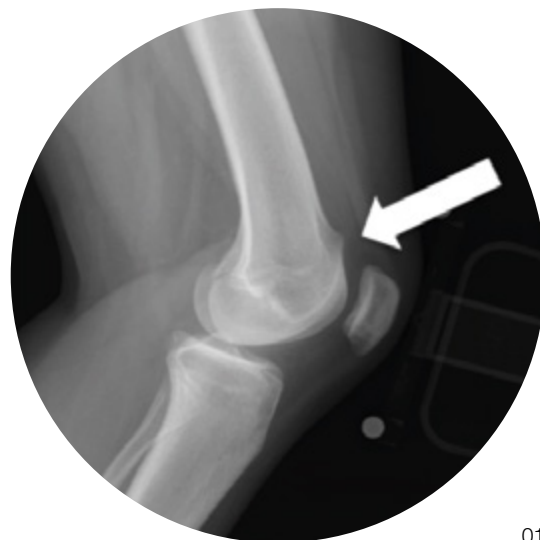Patellofemoral articular cartilage lesions are common in the young, active patient, and can be a challenging problem. Fortunately, recent advances have helped our understanding and ability to treat these patellofemoral lesions by addressing concomitant background factors associated with cartilage lesions. As well, new cartilage restoration techniques are now available with encouraging short term results.

In our opinion, the most fundamental aspect of approaching the patient with patellofemoral cartilage lesions is in recognition and understanding of the pathology leading to or associated with the defect. Is this simply an acute lateral patellar dislocation causing a medial patellar facet lesion, or is this a chronic lesion from trochlear dysplasia and abnormal contact pressures? As we have learned, patellofemoral instability may represent a complex spectrum of pathology and include genu valgus, increased femoral anteversion, increased tibial tubercle–trochlear groove (TT-TG) distance, patella alta, trochlear dysplasia, and medial patellofemoral ligament (MPFL) tear /insufficiency. The most commonly associated factors encountered with cartilage lesions include MPFL insufficiency addressed with MPFL reconstruction, trochlear dysplasia with trochleoplasty, distal malalignment with TTO, and tight lateral retinaculum with lateral retinacular lengthening. It's therefore essential to recognize that any successful cartilage restoration procedure requires concomitant pathology correction.

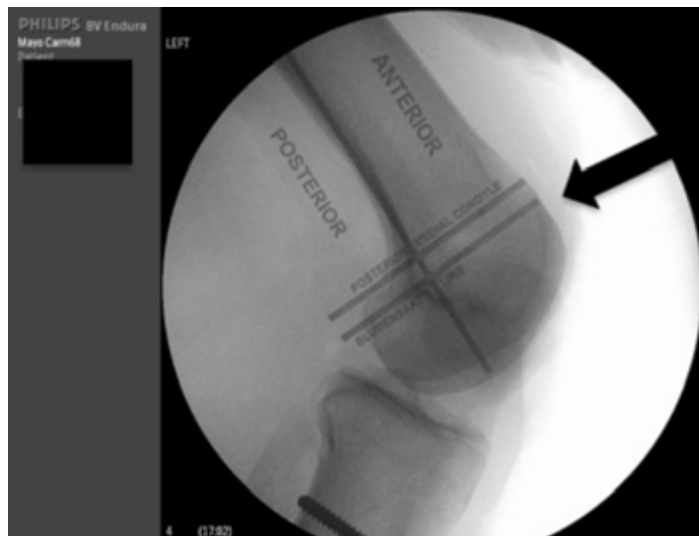
MPFL insufficiency can be suspected on clinical history from a history of lateral subluxation or dislocation or a sensation of instability and confirmed on examination with a positive lateral patellar apprehension test. The MRI is very helpful in determining the location of tear (femoral, patellar, or both) in the acute setting, and evaluating the quality of the remaining ligament in the chronic setting. However, as with the cruciate and collateral ligaments in the knee, we feel the exam is the most important for determining the function of the ligament. There are many techniques to reconstruct the MPFL as anatomically as possible.

In the setting of cartilage restoration surgery, it is vital to ensure the graft is not overtensioned to create increased medial patellofemoral contact pressure leading to pain and possible cartilage wear.

Trochlear dysplasia is best characterized by the Dejour classification. We find it helpful to evaluate both radiographs and the MRI for trochlear morphology. The lateral radiograph is helpful to look for a cross-over sign on the anterior cortex, but the Merchant view can be helpful as well. The MRI includes not only the bone structure on the axial images, but also includes the articular cartilage. Typically in dysplasia there is a convexity of the trochlea that causes both abnormal tracking of the patella and also increased contact pressure with a convex on convex articulation, rather than the normal convex on concave articulation to evenly disperse contact forces over the patellofemoral joint. There are many emerging techniques for trochleoplasty. We find the grooveplasty described by Lars Peterson to be an efficient and straightforward method of eliminating the convex trochlea and creating a good proximal entry point for guiding the alignment of the patellar with knee flexion.



01

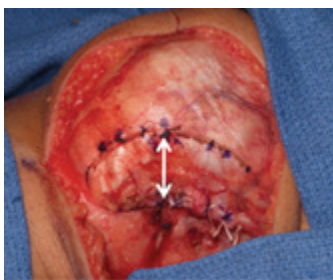




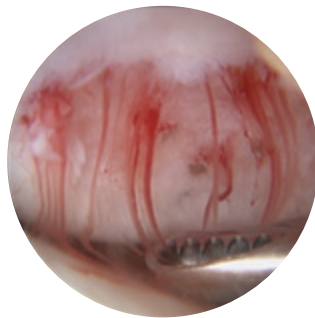
A lateralized tibial tubercle can lead to a lateral vector contributing to both lateral instability and cartilage wear. While examination of the tubercle alignment with the knee in full extension and flexion is critical, objective measurements with CT and MRI have been developed to aid the surgeon in both the decision to perform tibial tubercle osteotomy and in preoperative planning for the type of osteotomy to be performed. Typically, a TT-TG distance greater than 20 mm on CT is pathologic, but this threshold may be lower on MRI depending on technique. Our work by Camp et al. has helped define a simple method of calculating TT-TG distance on MRI, but certainly controversy continues in this area. With a dysplastic trochlear, measurement of this distance can be problematic, and alternative options, including TT-PCL distance are emerging, but likely require more refinement before widespread adoption.

Tibial tubercle osteotomy (TTO) options range from pure anteriorization to anteromedialization (AMZ). In the setting of cartilage surgery, it is important to remember that an AMZ will offload the distal and lateral patellar cartilage, but will overload the proximal and medial patellofemoral cartilage. A recent study by Gomoll et al. showed no significant difference between knees treated with autologous chondrocyte implantation (ACI) alone versus ACI and TTO, so it is important to assess each patient carefully and not perform more surgery than is necessary.

Traditionally, a lateral release was performed for a tight lateral retinaculum. A “tight” lateral retinaculum is defined as the patellar not able to be everted to neutral on physical examination, or significant lateral patellar tilt on a merchant view. However, recent interest has favored a lateral retinacular lengthening over lateral release. The advantages of the lengthening procedure have been preservation of the vastus lateralis attachment, less risk of medial iatrogenic instability, and in the setting of cartilage surgery, providing a closed layer between the joint and the subcutaneous tissues.



03



04

## Cartilage Treatment Options

### Microfracture

Marrow stimulation techniques serve an important role in the treatment of cartilage lesions. It has shown to be a cost-effective, minimally invasive technique for the treatment of cartilage lesions. In the short-term (< 5 years), microfracture has demonstrated excellent results in regards to pain relief and function, especially in younger patients. Unfortunately, the fibrocartilage produced by microfracture has proven to have unfavorable long-term durability and clinical results. In addition, there is also evidence to suggest possible detriment to the results of future cartilaginous procedures in the face of a failed microfracture due to the creation of intralesional osteophytes. Microfracture has also been proven to have suboptimal results with lesions greater than two to four centimeters, adding to its limitations as a treatment. We feel that microfracture can have a role for indicated lesions. However, even when performing a simple arthroscopic marrow stimulation technique, it is critical to follow the principles of cartilage surgery and identify and correct background factors in this setting.

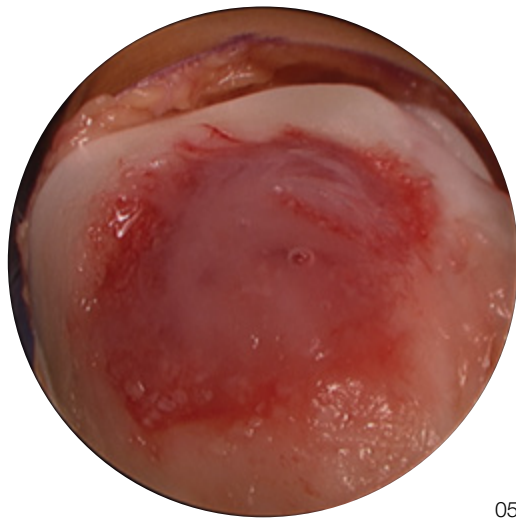
Currently, there are options to augment microfracture, in order to encourage more articular-like cartilage formation over fibrocartilage. One option is micronized cartilage matrix (BioCartilage, Arthrex, Naples, FL, USA), but clearly more research and clinical results are needed in this area. Other augmentation options include collagen and polymer membranes, chitosan and fibrin gels, hyaluronan injections, as well as numerous growth factors. Autologous matrix-induced chondrogenesis (AMIC) has demonstrated some promising early results. A microfracture-enhanced model may be the most cost effective technique, but more clinical results are needed.

### Autologous Chondrocyte Implantation (ACI)

Gradually ACI has demonstrated its role as a reliable treatment option for patellofemoral cartilage lesions. Short and long-term follow-up have demonstrated excellent results with modern ACI techniques. Recently, Gillogly et al. demonstrated good to excellent results in 83% of cases with ACI of the patella after a mean follow-up of 7.6 years. One technical advantage for ACI in the patellofemoral joint is that the geometry of the patch is unconstrained. ACI requires an index arthroscopy with a cartilage biopsy of 200 to 300 micrograms or approximately five to ten millimeters of cartilage, which is typically taken from the lateral margin of the intercondylar notch. A two-stage surgery is generally perceived as a disadvantage of the technique. However, a first stage surgery to define the extent and location of the cartilage lesions can give the surgeon helpful information for selecting the best treatment option.

### Treating Patellofemoral Cartilage Lesions

Despite generally good and excellent clinical results, it is important to note that ACI is not FDA-approved currently in the US for treatment of patellar lesions, or for treatment of bipolar patellofemoral lesions, despite its excellent clinical results in a recent multi-center trial. Use of a synthetic type I/III collagen patch has nearly eliminated hypertrophy compared with periosteum without detrimental effects on the maturation of the neo-cartilage. However, it is important to emphasize that the long-term 20-year results published by Lars Peterson and Tom Minas include the first generation technique of using periosteum. In addition, the collagen membrane is also an off-label, surgeon directed use in the United States and must be discussed with the patient during the informed consent process.



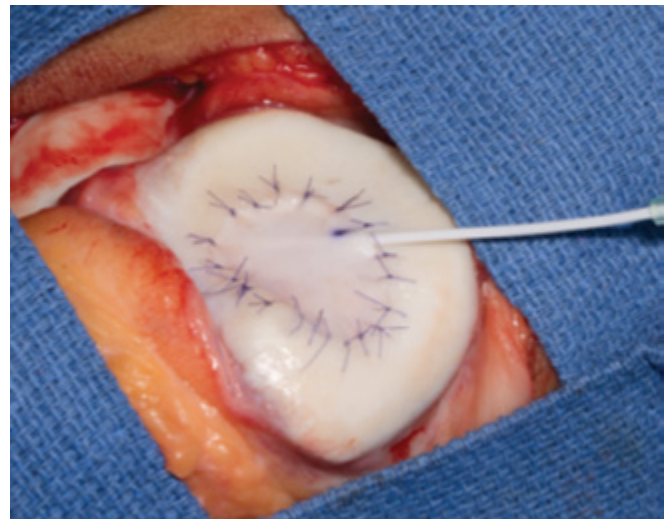
05

### Particulated Juvenile Articular Cartilage (PJAC)

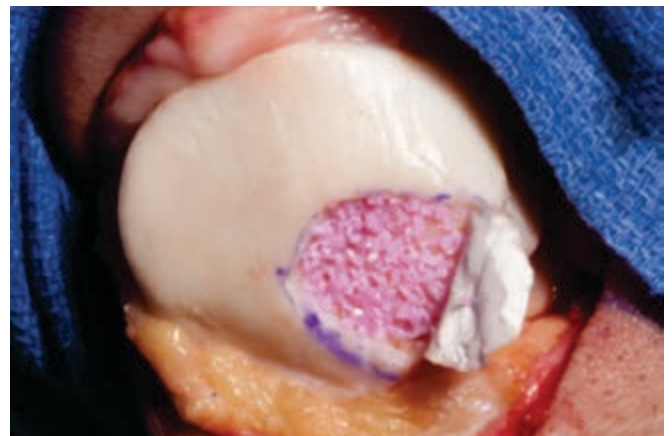
The use of PJAC for articular cartilage defects is an exciting and evolving treatment option. The most commonly used product currently is (DeNovo NT Natural Tissue Graft, Zimmer Inc, Warsaw, Indiana, USA) and it consists of allograft articular cartilage from donors less than 13 years old. PJAC implantation for the treatment of cartilage lesions is performed in a manner very similar to ACI. Lesion preparation is completed in the identical fashion to ACI and a single step implantation is possible, typically with fibrin glue used to secure the cartilage cells into the defect. A large advantage to this technique is that it is a one-stage surgery. One major limitation to the use of PJAC is the lack of high quality published outcome data. The few studies that do exist regarding its use have demonstrated promising results. In a recent case series published by Farr et al., the authors reported similar results in regards to clinical outcomes and defect repair in comparison to analogous matrix-associated ACI studies.

### Osteochondral Allograft (OCA)

Fresh or fresh-stored osteochondral allografts are limited to areas that have established tissue banks that can provide this tissue. They provide excellent options for osteochondral lesions in the patellofemoral joint, such as a post-traumatic defect, or an osteochondritis dissecans lesion. Generally the clinical results of osteochondral allografts have not been as good as in the femoral condyles. For these reasons osteochondral allografting of the patellofemoral joint is generally reserved as a salvage procedure in the young active patient.



06

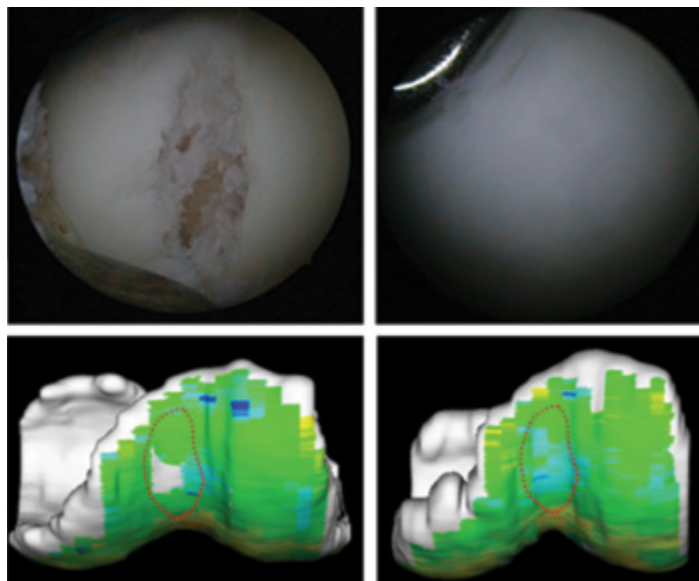


07

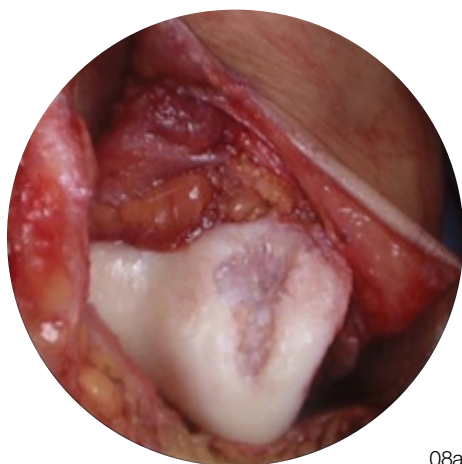### Stem Cell-based Cartilage Repair

Chondrocyte-based therapies have been extensively studied since the successful report of autologous chondrocyte implantation by Brittberg and Peterson. However, this procedure may have limitations, including the sacrifice of undamaged cartilage within the same joint and dedifferentiation associated with the ex vivo expansion of the cells. Furthermore, due to the degenerative changes in cartilage accompanying aging, the viability biologic potential of the cells may be limited in elderly individuals. To overcome such potential problems, stem cell therapies have become a focus to facilitate regenerative tissue repair. Mesenchymal stem cells (MSCs) have the capability to differentiate into a variety of connective tissue cells including bone, cartilage, tendon, muscle, and adipose tissue and can be isolated from various tissues. There have been several reports of clinical trials of stem cell-based cartilage repair. As a potential method, a scaffold-free three-dimensional tissue engineered construct (TEC) derived from synovial MSCs has been generated. Followed by the preclinical study, "First-in-men" clinical trial was started at the Osaka University Hospital which has a GMP-grade cell processing center in 2013. Preliminary results suggest the TEC could efficiently promote cartilage repair assessed by arthroscopy and magnetic resonance imaging (MRI) (conventional and quantitative such as T2 mapping) at 12 months (Fig. 8). This clinical study will be completed by March 2015.

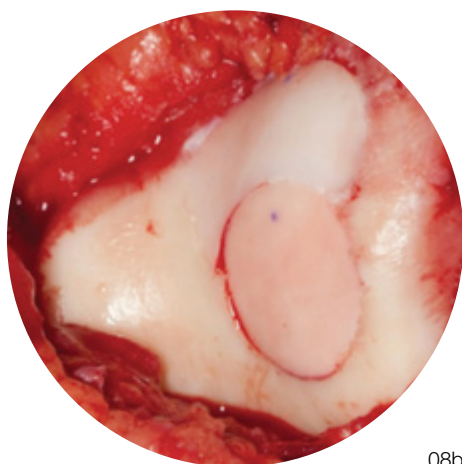
In summary, treatment of patellofemoral articular cartilage lesions remains a challenging clinical entity. Regardless of the procedure chosen to treat these lesions, identifying and correcting all contributing factors such as patellar trochlear mal-alignment and reducing contact stresses are essential for a successful outcome. Future research into biologically optimizing the environment for hyaline cartilage growth may serve to improve the results of our currently used methods.



09



08a



08b

- 01 Fig 1a Preoperative x-ray demonstrating trochlear dysplasia.
- 02 Fig 1b Intraoperative x-ray demonstrating correction of dysplastic trochlear spur (TTO and MPFL guide also visualized).
- 03 Fig 2 Intraoperative photograph demonstrating 2 cm lateral retinacular lengthening.
- 04 Fig 3 Intraoperative arthroscopy demonstrating microfracture of a patellar cartilage lesion with flow of marrow elements from subchondral bone.
- 05 Fig 4 Intraoperative photograph of microfracture with micronized cartilage allograft and fibrin glue.
- 06 Fig 5 Intraoperative photograph of autologous chondrocytes being injected under collagen I/III membrane.
- 07 Fig 6 Intraoperative photograph showing juvenile particulated chondral allograft implanted under a collagen membrane in a patella cartilage defect
- 08ab Fig 7 Intraoperative photograph of a lateral trochlear OCD lesion treated with 2 fresh stored osteochondral transplanted dowels (snowman technique).
- 09 Fig.8 Arthroscopic views of the pre-operation defect (Left) and 1 year after implantation of a TEC (Right) with corresponding T2 mapping of the lesion



## Failed Rotator Cuff Repair



Mandeep S. Virk<sup>1</sup>

**Additional Authors:**

Petar Golijanin<sup>2</sup>

Matthew T. Provencher, MD<sup>2</sup>

**Corresponding Author:**

Augustus D. Mazzocca, MS, MD<sup>1</sup>

*1 Department of Orthopaedic Surgery, New England Musculoskeletal Institute, University of Connecticut School of Medicine, Farmington, CT, USA*

*2 Department of Orthopaedic Surgery, MGH Sports Medicine Surgery, Harvard Medical School, Boston, MA, USA*

**Conflict of interest**

Mandeep S. Virk—No conflict of interest

Augustus D. Mazzocca—Consulting and research support from Arthrex

Matthew T. Provencher—Consulting Arthrex and JRF/Royalties Arthrex

Petar Golijanin—No conflict of interest

**Introduction**

Rotator cuff repair (RCR) results in a predictable pain relief and variable return of function (motion and strength) in the majority of patients. The symptomatic failed rotator cuff repair continues to be a challenge. However, not all rotator cuff structural failures have clinical deficiencies, and many patients who don't fully heal their rotator cuff may continue to enjoy a high level of function and pain relief. The term "failure" needs to be well defined-in that RCR may fail for pain, stiffness, or weakness, or a combination of some or all three of these factors.

For any revision surgery and in failed RCR there are three very important questions that the orthopaedic surgeon should ask oneself before proceeding with the revision surgery:

- a. Why did the first surgery fail?
- b. How does one go around fixing the problem this time (preoperative planning)?
- c. Are there any preoperative risk factors that are predictive of the high rate of failure of revision RCR and in that case what are the alternative treatment options?

Provided that the index surgery was appropriately indicated and performed for a correct diagnosis and other concomitant diagnoses or sources of pain were addressed in prior surgeries, there are multiple factors that can lead to failure of RCR (Table 1). A systematic approach should be utilized to investigate other causes (besides rotator cuff failure) that can result in shoulder pain and loss of function after rotator cuff repair (Table 2). These could be related to the cervical spine, biceps tendon, acromioclavicular (AC) joint, adhesive capsulitis and infection (Table 1).

Loss of motion and stiffness is less common with arthroscopic rotator cuff repair compared to the open repair. Numerous predisposing risk factors have been proposed for development of adhesive capsulitis and include prolonged immobilization, presence of preoperative stiffness or concomitant labral pathology, smaller tear size and articular sided tears, and systemic illness (diabetes, hypothyroidism).

Clinical studies measuring isokinetic strength testing of shoulder after rotator cuff repair have demonstrated that it takes up to a year to achieve peak recovery of shoulder strength. The recovery of strength in the shoulder is slower and inconsistent in large and massive tears compared to small and medium tears. Suprascapular nerve injury is an uncommon cause of postoperative worsening of rotator cuff strength and function.

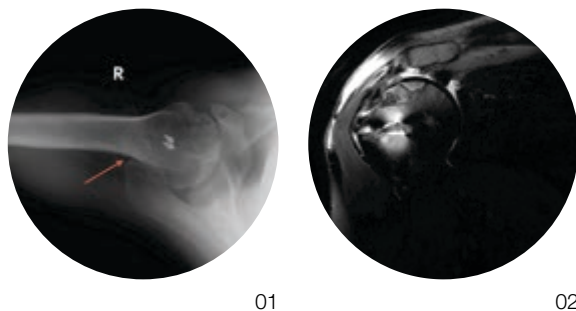
**Table 1. Associated with Failed Rotator Cuff**

<b>A. Biologic failure (inability of the cuff to heal at the bone tendon interface)</b>
1. Poor quality tissue for healing-poor blood supply, tendon atrophy, fatty infiltration, chronic tear with degenerative changes
2. Infection
3. Smoking
4. Physiologic older age
5. Diabetes
6. NSAIDS use
<b>B. Mechanical failure: (structural failure of rotator cuff fixation to the bone)</b>
1. Failure of fixation at the tendon suture interface (poor structural integrity of the cuff, repair under significant tension, tendon gap despite tendon tissue after mobilization)
2. Failure of fixation at the bone-anchor interface (greater tuberosity fracture, poor pull out strength in osteoporotic bone at the greater tuberosity)
3. Early aggressive rehabilitation
4. Infection
5. Non compliance with post-operative rehabilitation plan

## History Taking

Patients with rotator cuff failure can present with shoulder pain or significant weakness or stiffness or a combination of some or all of these presentations. From a diagnostic standpoint, it is reasonable to think that most of the patients presenting with pain after RCR fall into two broad categories: pain similar to preoperative pain and at the same site on the shoulder or pain at a different site (over the AC joint, subpectoral site of biceps tenodesis) in the same shoulder. A patient presenting with shoulder pain, which was similar in location and character to the preoperative pain can present as one of the three patterns and each of these has implications with respect to the diagnosis:

1. The pain never improved after surgery (wrong diagnosis with alternate etiology [Table 2], peri-operative RC failure, postoperative adhesive capsulitis)
2. Interval improvement in the symptoms but acute onset of pain in the index shoulder following a traumatic event (acute retear)
3. Interval improvement in the symptoms followed by insidious recurrence of similar pain in the index shoulder (chronic recurrent tear)

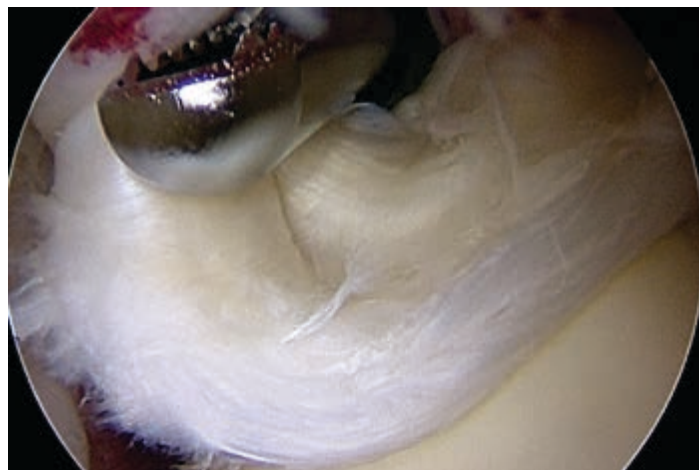

Patients may also present with loss of strength and functional capabilities independent of shoulder pain. Loss of motion or stiffness can present early or late after RCR. Stiffness can manifest as loss of forward flexion or external rotation or internal rotation behind the back or a combination of these depending on the anatomic region of the capsule involved.

History of any wound complications including drainage from the wound, use of antibiotics postoperatively should be asked to determine the history of post op infection. The patient should also be asked relevant questions about the postoperative rehabilitation protocol (timing of active range of motion and strengthening exercises) and compliance with physical therapy.

**Table 2. Causes of Persistent Shoulder Pain in Patients Following a RC Repair**

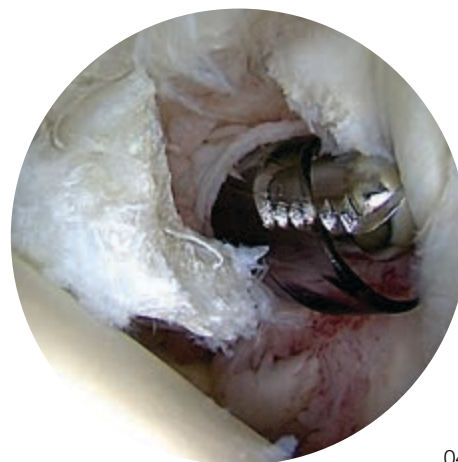1. Cervical spine pathology-radiculopathy
2. Suprascapular neuropathy
3. Intra-articular conditions (glenohumeral arthritis, adhesive capsulitis, instability, labral pathology and biceps tendinopathy)
4. Extra-articular conditions (persistent subacromial impingement, acromio-clavicular arthritis, deltoid muscle insufficiency).
5. Failed rotator cuff repair
6. Referred pain (intraabdominal causes)



03

## Physical Examination

A shoulder examination starts with a cervical spine examination to rule out cervical radiculopathy. Important physical examination findings on inspection include atrophy of the rotator cuff (RC) muscles in supraspinatus fossa and infraspinatus fossa, partial or complete deltoid atrophy (especially prior open or mini-open cuff repair), anterosuperior prominence of the humeral head, and scapular dyskinesia. The patient should be asked to point to the site of maximum pain before proceeding with palpation. Location of the pain and site of maximum tenderness is valuable in anatomic localization of the pain generating structure. Range of motion (active and passive) is usually tested next and includes evaluation of glenohumeral as well as scapulothoracic motion. Pseudoparalysis and anterosuperior escape should be specifically looked for, as these findings are important determinants for treatment decision-making. Strength testing of RC muscles will identify weakness of rotator cuff muscles (subscapularis, supraspinatus, infraspinatus and teres minor). Special tests for impingement (Hawkins and Neer sign), RC tear (bear hug, belly press, external rotation lag sign, horn blower sign, Jobes test), AC joint pathology (cross arm adduction, point tenderness, O'Brien's test) and biceps pathology (speeds, Yergason, O'Brien's test, subpectoral biceps test) should be performed.



04

## Failed Rotator Cuff Repair

### Imaging Studies

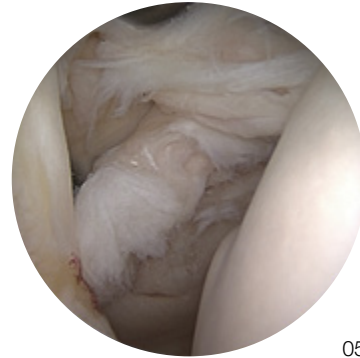
The imaging studies are generally helpful in identifying a RC defect post repair, however there are limitations to the imaging modalities as they may potentially either under call or overcall the level of healing of the tendon. Imaging is also important in assessing the status of the residual RC (atrophy, retraction, and fatty infiltration), and also helps to identify alternate pathology (glenohumeral arthritis, os acromiale, AC joint arthrosis, and calcific tendinitis) (Figs. 1 and 2). Plain radiographs of the glenohumeral joint including the anteroposterior, axillary, and suprascapular outlet views should be obtained to review degenerative changes, associated pathology and cysts or other postoperative issues. Advanced imaging studies are helpful in demonstrating a rotator cuff defect but whether this defect actually correlates with pain and loss of function requires clinical correlation. MRI arthrogram, CT arthrogram, and Ultrasonography are helpful and have their respective indications. MR arthrography is considered the imaging of choice for rotator cuff assessment in revision surgery. USG is cost beneficial but is highly user dependent. CT arthrogram is a valid option in patients who have a contraindication to an MRI. Presence of a rotator cuff defect on imaging studies after rotator cuff repair does not necessarily translate into clinical failure as many patients can have a painless functional shoulder despite having a rotator cuff defect.

<b>Table 3. Treatment Options in Failed Rotator Cuff Repair</b>
<b>1. Non-operative</b>
a. Physical Therapy-range of motion, scapular strengthening
b. Intraarticular steroid injections
c. Pain medications
d. Activity modifications
<b>2. Operative intervention: provided there is no infection following operative options exist</b>
a. Revision rotator cuff repair-arthroscopic or mini open
b. Arthroscopic debridement, subacromial decompression and biceps tenotomy/tenodesis
c. Tendon transfers
d. Prosthetic replacement

### Treatment

Failed RCR continues to be a technically challenging scenario. The key problem, symptomatic retear or presence of significant weakness or stiffness, or alternate diagnosis should be identified during preoperative work up. If symptomatic retear of the rotator cuff is the predominant problem and the potential causative factors have been identified, the next question is whether the RC is repairable or not. Active infection, chronic massive cuff tears, severe cuff tear arthropathy, multiple tendon tears (>2 tendons) and advanced fatty infiltration of RC (Goutallier stage >2) are scenarios that are less likely to have a successful repair and alternative treatment options should be considered.

Treatment options include both operative and non-operative strategies (Table 3). The patient should be informed about various treatment options, modifiable risk factors for poor healing of rotator cuff (smoking), the requirement for an extended postoperative rehabilitation and having realistic expectations from the revision surgery.

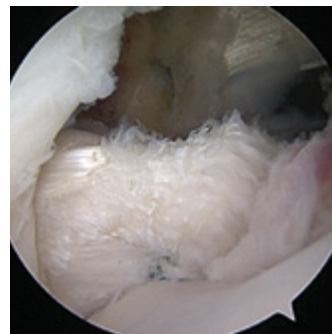


05

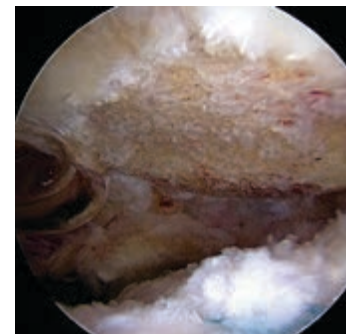
### Operative Principles of Revision Rotator Cuff Repair Surgery

The goal of revision rotator cuff repair is to perform a tension free rotator cuff repair. The integrity of the deltoid, presence of an external impingement, status of the biceps and AC joint, the quality of the residual RC tendons (atrophy, fatty infiltration, degree of cuff retraction, number of tendon involved), functional level of the patient, and hand dominance are important factors to be identified in preoperative planning. Prior operative notes, if available, can provide useful information regarding the type of rotator cuff repair performed during previous surgery (single row versus double row), the number and type of suture anchors used previously (absorbable versus metallic), status of the biceps tendon and quality of the residual rotator cuff.

Revision RCR can be performed via open or arthroscopic techniques based on the surgeon preference. We prefer arthroscopic revision RCR with provision to mini open if necessary. A beach chair position is used for arthroscopic revision RCR but a lateral approach can also be used based on the surgeon's preference. Exam under anesthesia (EUA) provides valuable preoperative information regarding instability, restriction of range of motion, and also provides an opportunity for gentle manipulation of the shoulder.



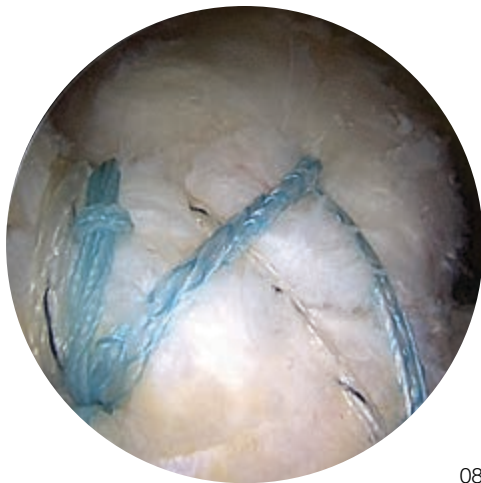06



07

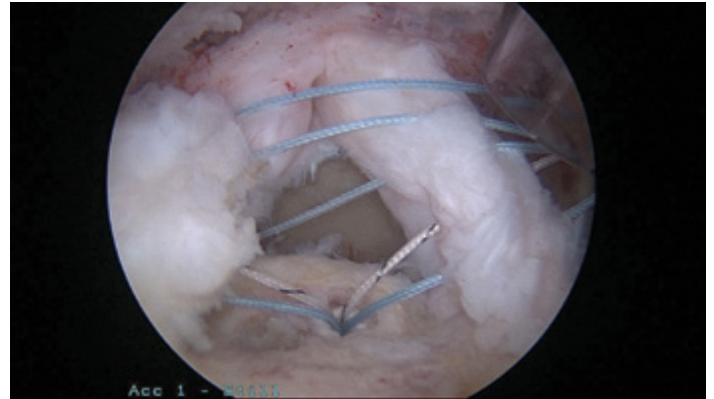


A diagnostic arthroscopy is performed using standard anterior and posterior portals next. Old portal sites can be used for arthroscopy if they are in the right location. Close attention should be paid to the long head of the biceps (LHB) insertion and the intraarticular and intertubercular portion of the biceps tendon (Fig. 3). We have a low threshold to perform tenotomy during revision surgery if there are any signs suggestive of tendonitis or significant tear (as a primary procedure or for later tenodesis; Fig. 4). Subscapularis tendon tears are less common compared to the posterosuperior cuff tears but they are often missed or misdiagnosed as just fraying of the upper rolled edge. The medial and lateral part of the subscapularis footprint should be meticulously examined (Fig. 5). If there is a subscapularis tear that requires repair, it is performed next. An anterolateral portal is required as an accessory working portal for arthroscopic subscapularis repair (Fig. 6). Extensive tears of subscapularis are addressed by open technique. We also prefer to perform intra articular release between the undersurface of the cuff and capsule over the glenoid and debride the rotator cuff footprint on the greater tuberosity via the intra articular portals. Chondral wear or damage on the humeral head or glenoid should be documented. Loose suture material or implants are removed. If there is any sign suggestive of infection, multiple synovial and rotator cuff biopsy specimens should be obtained and send for culture and sensitivities.



08

After performing a diagnostic arthroscopy and intra articular work, we proceed to the subacromial space and establish a lateral portal, which is utilized to perform a subacromial bursectomy and revision acromioplasty if necessary (Fig. 7). Fibrous bursal tissue or adhesions tethering the RC to the acromion and deltoid are carefully debrided without causing damage to the deltoid and the rotator cuff. The basic principles of arthroscopic rotator cuff repair should be followed during revision posterosuperior rotator cuff repair and includes tendon mobilization, tear pattern recognition, foot print preparation and performing a tension free repair. The morphology of the tendon tear, the size and the mobility of the torn rotator cuff are analyzed.



09

At this stage one of few options exists. First, if the tendon tissue quality is good and there is a sufficient RC tendon excursion to its native footprint, we prefer a transosseous equivalent double row repair with a suture bridge construct to increase the contact area of the tendon at the footprint for healing (Fig. 8). Second, if tension free repair is not possible due to limited RC excursion, soft tissue releases are performed. This includes the intra articular release of the undersurface of the cuff over the glenoid and the anterior and posterior interval slides, which are performed from the subacromial portals. Once enough mobilization of the RC tendons has been achieved we proceed with the transosseous equivalent double row repair. Third, if the tendon excursion is limited and tendon cannot be brought to the lateral footprint despite adequate soft tissue releases, we perform a single row repair with medialization of the tendon on the footprint.

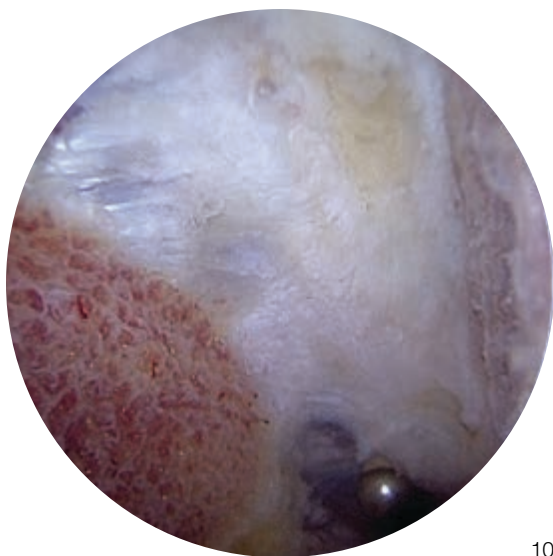Friable RC tissue that is not able to hold sutures, presence of severe RC tendon tissue loss (musculotendinous tendon tears), massive rotator cuff tears and tendons with poor excursion despite adequate soft tissue releases are intra operative indicators that a revision RCR will fail. This situation represents a decision dilemma for the surgeon. A partial repair of the torn tendon can be performed and includes the use of margin convergence (side to side repair) and repair of the reducible component of the cuff to the footprint (Fig. 9). Some patients surprisingly do well for a significant period of time with this treatment, a fact that many orthopaedic surgeons have experienced in their practice but the exact understanding of this phenomenon is not available. It is suggested that the restoration of the anteroposterior force couple with these limited or partial repair provides stability and relieves pain. Arthroscopic distal clavicle, if necessary, is performed after the rotator cuff repair has been accomplished (Fig. 10).

## Failed Rotator Cuff Repair

Options for managing rotator cuff defects include reinforcement by local autograft (long head of the biceps), and use of allograft tissue and synthetic scaffolds. Allograft patch (synthetic or biologic) augmentation is used for reinforcement of the tendon defects. The allograft can be biologically augmented with autologous platelet rich plasma (harvested from peripheral blood) and autologous bone marrow aspirate (harvested from the proximal humerus) (Fig. 11). Mini open arthroscopic assisted revision rotator cuff repair is an attractive option especially when dealing with a large rotator cuff tear and rotator cuff defect. Unlike the open technique the deltoid attachment on the acromion is maintained but still provides the ease of using Mason-Allen type grasping stitches through the tendon and extensive soft tissue releases. The use of suture anchors or transosseous repair seems more convenient with the mini open technique. Furthermore, this technique is especially helpful when using the allograft tissue or synthetic scaffolds to bridge or augment the rotator cuff defects.

Tendon transfers and arthroplasty are alternative treatment options for an irreparable revision rotator cuff. Pectoralis major transfer is indicated for an irreparable, painful subscapularis tendon tear. Latissimus dorsi transfer is principally a pain relieving operation, which is performed for an irreparable posterosuperior rotator cuff in a highly functional patient (usually younger patient) who does not have pseudoparalysis or advanced glenohumeral arthritis (preferably intact subscapularis). The gain in external rotation with a Latissimus dorsi transfer is variable. The reverse shoulder prosthesis is preferred in the older patients with chronic pseudoparalysis or severe rotator cuff tear arthropathy.

Post-operative rehabilitation is a critical part of the RCR management. We prefer a protective rehabilitation protocol allowing sufficient time to maximize healing and utilize delay muscle strengthening protocols.

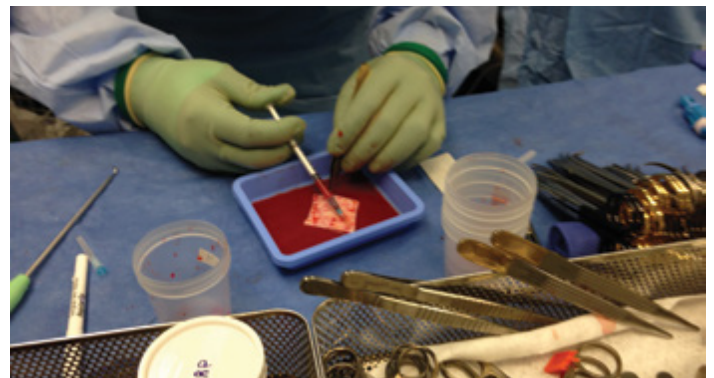


10

## Postoperative Shoulder Stiffness

Literature metaanalysis demonstrates that the shoulder stiffness after arthroscopic RCR is less common than open RCR. The majority of mild and moderate stiffness responds to non-operative treatment (structured rehabilitative protocol). Persistent significant shoulder stiffness is an indication for arthroscopic surgical capsular release (Fig.10). EUA provides useful information regarding the true pattern of stiffness. After performing diagnostic arthroscopy, we proceed with the rotator interval release and superior glenohumeral ligament release. Anterior or inferior or posterior capsular releases are performed depending on the predominant pattern of capsular stiffness. Subacromial adhesiolysis is performed after the intracapsular releases have been completed. The response to capsular releases and restoration of range of motion is checked intra-operatively to verify adequacy of capsular release.

In conclusion, failed rotator cuff repair is a challenging clinical situation. Symptomatic retear, stiffness and presence of significant weakness can result in dissatisfaction after rotator cuff repair. Identification of factors that led to failure of the index procedure, and systematic approach to the management of failed rotator cuff repair is essential for a successful outcome.




11

- 01 Fig 1 Axillary view of right shoulder following rotator cuff repair with continued pain in the acromion demonstrating os acromiale
- 02 Fig 2 Axial view of a magnetic resonance image demonstrates artifact from previous hardware, which can interfere with assessment of rotator cuff healing.
- 03 Fig 3 Arthroscopic view from the posterior portal demonstrating fraying, delamination and partial tear of long head of the biceps tendon
- 04 Fig 4 Arthroscopic view from the posterior portal showing LHB tenotomy
- 05 Fig 5 Arthroscopic view from the posterior portal showing a subscapularis tear
- 06 Fig 6 Arthroscopic view from posterior portal showing subscapularis repair
- 07 Fig 7 Arthroscopic view from the posterolateral portal showing revision acromioplasty
- 08 Fig 8 Arthroscopic view from the lateral portal showing transosseous equivalent double row rotator cuff (speed bridge technique)
- 09 Fig 9 Arthroscopic view from lateral portal showing suture passage for margin convergence and single row rotator cuff repair
- 10 Fig 10 Arthroscopic view from posterior portal showing distal clavicle excision
- 11 Fig 11 Injection of allograft dermal matrix with autologous PRP and bone marrow concentrate on back table (a) prior to implantation via miniopen incision to augment rotator cuff defect (b)

# The Journal of Rheumatology

First Release Articles  
Current Issue  
Archives  
Authors/Reviewers



## What you get

- Current
- Clinical
- Definitive

## Where you get it **THE JOURNAL**

To subscribe: visit [jrheum.org](http://jrheum.org) online or send in your completed coupon below

### Rates for 2014 calendar year USA/INTERNATIONAL

	Print + Online	Online Only
<b>INDIVIDUALS:</b>	<b>\$340 US</b>	<b>\$275 US</b>
<b>INSTITUTIONAL:</b>		
- Multisite <sup>#</sup>	On request	On request
- Multiuser (IP ranges)	\$1000 US	\$950 US
- Basic (up to 4 users)	\$525 US	\$475 US
<b>TRAINEES<sup>+</sup></b>	<b>\$205 US</b>	<b>\$140 US<sup>+</sup></b>
<b>Airmail (ADD)</b>	<b>\$100 US</b>	

For terms of access visit [jrheum.org](http://jrheum.org)

<sup>#</sup>Supervisor certification required below.

NAME OF SUPERVISOR: \_\_\_\_\_

SUPERVISOR SIGNATURE: \_\_\_\_\_

SUPERVISOR TELEPHONE: \_\_\_\_\_

### Please enter my 2014 subscription to **The Journal of Rheumatology**

Name (please print) \_\_\_\_\_

Address \_\_\_\_\_

City \_\_\_\_\_ State/Province \_\_\_\_\_

Country \_\_\_\_\_ Zip/Postal Code \_\_\_\_\_

Contact E-mail \_\_\_\_\_

Amount Enclosed \$ \_\_\_\_\_ Bill Me \_\_\_\_\_

Telephone Number \_\_\_\_\_ Fax Number \_\_\_\_\_

VISA/MasterCard Number \_\_\_\_\_ Expiration Date \_\_\_\_\_

Signature \_\_\_\_\_ CW \_\_\_\_\_

Mail completed form to: **The Journal of Rheumatology**  
365 Bloor Street East, Suite 901 | Phone: (416) 967-5155  
Toronto, Ontario Canada M4W 3L4 | Fax: (416) 967-7556  
E-mail: [subscriptions@jrheum.com](mailto:subscriptions@jrheum.com)

All subscriptions are for the calendar year. Renewals for print subscriptions received after May 31, 2014 will be charged an additional \$5 per back issue. Back issues: 3 years including current year are available if in stock. Single copies are available at \$30 each. Claims: US 2 months, elsewhere 4 months from issue date, e.g., March 1 and May 1, respectively, for the January Issue. **PRIVACY POLICY:** For details of our privacy policy, visit our website at [www.jrheum.org](http://www.jrheum.org).





Brett Moreira, MD  
Melbourne, AUSTRALIA

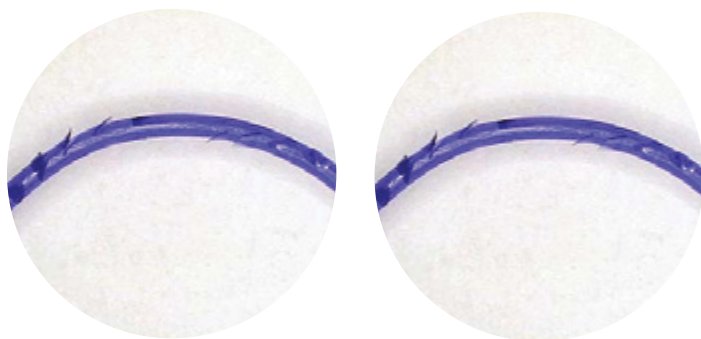
### Suturing Material–Knot vs Knotless for Wound Closure

In wound closure, suture materials come as braided or monofilament, absorbable or non-absorbable. Absorbable sutures, such as monofilament have shown less infections in contaminated wounds than braided sutures with several studies showing bacteria adhering more tightly to the braided suture. Monofilament sutures cause less reaction than do braided sutures, but require more ties to ensure an adequate knot compared to braided suture. Braided suture usually incites a larger inflammatory response but requires fewer ties to maintain the knot integrity.

Another option is a barbed bidirectional monofilament suture, which has permits knotless wound closure. The barbs allow the suture to distribute tension across the length of the wound without the need for knots. The bidirectionality allows for two surgeons to work simultaneously to close a wound.

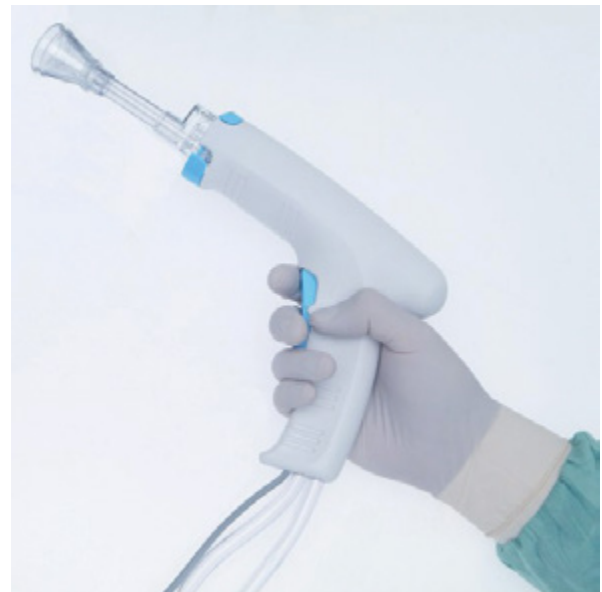Barbed monofilament suture is being used more frequently as a result of this efficiency and cost savings. Studies using barbed monofilament suture have shown decreased operative time and decreased costs to theatre with wound strength and tissue reaction scores comparable to those of monofilament suture tied with knots.

It is believed that knotting the suture can exaggerate the physical characteristics of the monofilament or braided suture causing inflammatory reactions. Therefore, a barbed suture that does not require knots may be less likely to provoke an inflammatory cascade.



Barbed sutures possess a theoretical advantage over traditional running monofilament sutures in the event of a suture rupture or failure. The barbs should theoretically resist a catastrophic failure of the entire length of the suture by holding the suture in place, even if one site breaks.

Overall, the presence of barbs is yet to be shown in the literature to prevent wound dehiscence over monofilament sutures. Currently, the bacterial properties of barbed monofilament suture, such as bacterial adherence and correlation with postoperative wound infection, have not been defined in comparison to standard monofilament and braided sutures.



### What is Pulsatile Lavage?

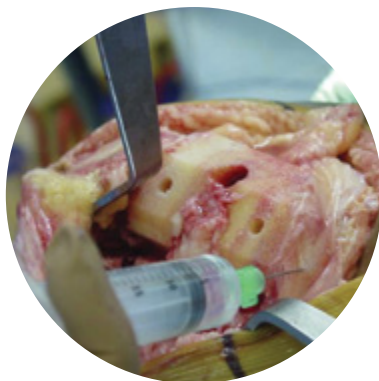Is the old orthopaedic phrase correct, that 'the solution to pollution is dilution'. We recognize the theoretical basis for irrigation to dilute contamination and non-viable tissue and that a greater volume of irrigation would be expected to achieve greater dilution. A decrease in wound infection is proportional to the amount of irrigation used. At least 5 liters of pulsatile lavage is required to ensure removal of more than 95% of the debris.

Irrigation has evolved from the use of a continuous stream of fluid to the use of discrete pulses of fluid, produced at a frequency of approximately 1,200 pulses/min (20 Hz), delivered to the required site. Pulsed or pulsatile lavage is a mechanical form of hydrotherapy and was originally used by oral surgeons at Walter Reed Medical Centre during the Vietnam War. It was used to rapidly irrigate grossly contaminated wounds to reduce wound related sepsis and delayed wound healing.

Today, its use has progressed part of standard of care for irrigating open fractures and contaminated wounds. In total joint arthroplasty, the role of pulse lavage is to help clean and improve the bone surface preparation, leaving a coralline structure that allows for better compression of the cement in the bone.

There are 3 adhesive forces preventing dislodgement of debris or bacteria: capillary, molecular and electrostatic. Thus 3 types of forces to remove material are mechanical contact (eg. Brushing or scrubbing), inertial forces, and fluid dynamic pressure which is utilized by pulsatile lavage. Initial compression phase of the tissues under the impact of the pulse, followed by an interpulse decompression phase during the zero-pulse periods may loosen foreign material. Ejection of the material by the elastic recovery of the tissue during the zero-pulse period may assist in debridement.

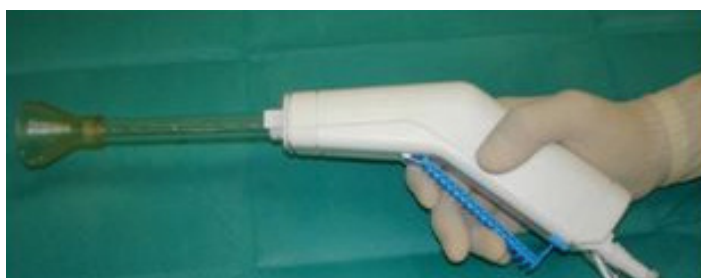Overall, pulsatile lavage has been shown to improve cement penetration in cancellous bone and increase mechanical strength at the cement–bone interface during in vitro studies. High-pressure pulsatile lavage should perhaps be reserved for severely contaminated wounds or for open injuries for which treatment will be delayed. Low-pressure irrigation might be useful if contamination is minimal or treatment is immediate. High-quality evidence is lacking regarding optimum lavage pressure in primary or revision TJA.



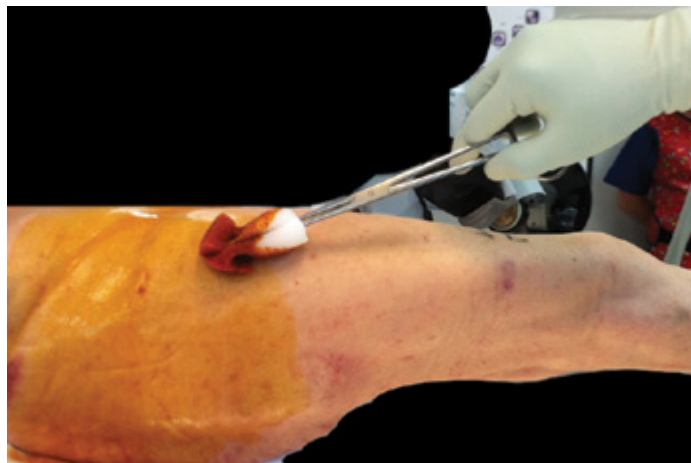
### High-Volume Local Infiltration Analgesia

HVLIA has a reputation among surgeons as a simple, safe and convenient method that provides good analgesia without motor block of the lower limb.

There are potential benefits of infiltrating high volumes of local anaesthetics around the soft tissues of replaced hip and knee joints. The risk of systemic toxicity is minimized with diluted local anaesthetic solution, which also allows a high volume to be used. Some principal advantages include intra-operative administration of analgesic agents by the surgeon, thereby minimizing the need for additional invasive procedures. Analgesia may be prolonged up to 48 hours with long-acting local anaesthetics and the administration of supplemental doses via a wound catheter at regular intervals or continuous infusion.



Local infiltration analgesia uses a systematic infiltration of the periarticular soft tissues with a mixture of ropivacaine (a long-acting local anaesthetic with a superior cardiotoxicity profile in comparison to bupivacaine as well as for its intrinsic vasoconstrictor properties), ketorolac (an NSAID), and epinephrine (a vasoconstrictor).



The analgesic effect derived from the local anaesthetic mixture is due to the actions of the constituent drug (blockage of ion-gated Na channels on A $\delta$  and C-type nociceptive nerve endings). Local anaesthetics reduce the release of inflammatory mediators from neutrophils, reduce neutrophil adhesion to the endothelium, reduce formation of free oxygen radicals, and decrease oedema formation. In conjunction, NSAID's reduce prostaglandin formation (Prostaglandins sensitize nociceptive fibers and lead to amplification and sustaining of pain).

The concept of HVLIA is a multimodal and multidisciplinary method of perioperative pain control, including patient education and rehabilitation support, as well as a potential reduction in opiate consumption, the achievement of early milestones, or a reduction in length of hospital stay.

### What is the best skin preparation for the surgical site?

What is the optimum skin preparation agent? While Chlorhexidine gluconate (CHG) is the recommended agent for preventing intravenous catheter-related infections, there is currently no recommendation of one agent over another for prevention of Surgical site infections (SSI). When compared directly, results are conflicted as to whether CHG or povidone-iodine provides superior skin antisepsis and lowers the rate of SSI. To date, there are no prospective randomized studies comparing skin preps in patients undergoing total joint arthroplasty.

Alcohol is suggested to be an important element for skin antisepsis. Alcohol is used as an antiseptic because of its rapid antimicrobial action. It is suggested that whichever agent is chosen, that it be combined with alcohol. However, caution should be taken to allow time for adequate drying of alcohol-based products, given its flammable nature.

## 2nd ISAKOS Knee Course

March 1–2, 2014

Chennai, India

The 2nd ISAKOS Knee Course 2014 was held in the beautiful city of Chennai, at Hotel Hilton. The course offered everything, starting with the well planned scientific sessions to video lectures for topics of particular interest and, last but not the least, scenic beauty of the city. The congress had a team of 28 faculty members and more than 400 delegates from across the globe, determined to bring together a conference of unprecedented academic content.

The Course Chairman of 2nd ISAKOS Knee Course was Prof. Joao Espregueira Mendes. ISAKOS President, Prof. Masahiro Kurosaka also attended this event in Chennai. The course had two full days dedicated towards mastering surgical techniques in knee surgery, edited surgical video presentations by the masters themselves so as to teach the step-wise approach to basic and advanced knee arthroscopic procedures, open joint salvage procedures, arthroplasty, and fractures around the knee. Instructional course lectures were delivered on the latest concepts and surgical indications in knee surgery followed by interactive case discussion sessions. Product workshops provided the opportunity to try the latest techniques and instrumentation in knee reconstructive surgery.

Prof. U.Holz (Germany), Willem van der Merwe (South Africa) & Prof. Luis Vargas (USA) were the international faculty who attended this course. Dr. Parag Sancheti was the Course Co-Chairman and Dr. Dinshaw Pardiwala was the Scientific Chairman for this prestigious course.

Scientific sessions had presentations covering every aspect of the knee including ACL Reconstruction, Patellar Instability, Meniscus, Cartilage, PCL and Multi-Ligament Injuries, Orthobiologics & Non TKR Management of OA Knee, Osteotomies around the knee, Fractures of the Knee and Knee Arthroplasty: Total and Unicompartmental. The highlights of the conference were the clinical case discussions which were beneficial to all delegates. They found them profoundly useful. The lectures gave an insight to the technical details of knee surgery and received great applause from the delegates.

It had been a wholesome experience and a great satisfaction that we could address issues that would go a long way in improving the quality of life in patient care. I am sure the delegates learned a great deal attending the course and went home with more knowledge on knee surgery and arthroscopic procedures.



## ISAKOS ASKED YOU ANSWERED

Results of the ISAKOS Newsletter 2014: Volume II Poll

### 1. Does hip arthroscopy require separate fellowship training program?

22%

1. No, sports fellowship with exposure to 10–20 hip scopes is enough

27%

2. Sports fellowship plus a cadaver course will suffice

49%

3. Yes, it is a stand alone subspecialty which requires high volume exposure

3%

4. Arthroscopy, in all joints, doesn't require fellowship training

### 2. What's the best way to stay current within your field?

30%

1. Annual scientific meetings

41%

2. Reading scientific papers on a monthly basis

19%

3. Work with residents and fellows

43%

4. Attend/Teach cadaver labs and hands on courses

11%

5. Conduct high level research

### 3. What is the best retirement age for an Ortho surgeon?

8%

1. Never

3%

2. < 55 years old

35%

3. 56-65 years old

54%

4. 66-75 years old





## Inaugural Congress of the Asia-Pacific Knee, Arthroscopy and Sports Medicine Society (APKASS)

April 14–15, 2014  
Nara, Japan

Mitsuo Ochi, MD, PhD

*Professor and Chairman*

*Department of Orthopaedic Surgery,*

*Graduate School of Biomedical Sciences, Hiroshima University*

*Society President of Asia Pacific Knee, Arthroscopy Sports Society*

I am very pleased to report in the ISAKOS newsletter on the inaugural Asia-Pacific Knee, Arthroscopy and Sports Medicine Society (APKASS) congress, which was held on April 14–15, 2014. The venue was the Nara Prefectural New Public Hall, located in Nara, which is one of Japan's most historical cities. The inaugural congress included 421 participants from Asia, Europe and the USA.

The Society was formed in 2013, evolving from the Asia Pacific Orthopaedic Society for Sports Medicine (APOSSM), which was established in 1995. APKASS was established with two major aims: to expand opportunities to learn and to exchange information in the fields of knee joint, arthroscopy and sports medicine, and to become the Asia-Pacific counterpart of the European Society of Sports Traumatology Knee Surgery and Arthroscopy (ESSKA), the Latin American Society of Knee Arthroscopy and Sports Medicine (SLARD), and the American Orthopaedic Society for Sports Medicine (AOSSM).

The theme of the first APKASS congress was "Let's Maximize Asia-Pacific Vitality Starting from Japan". This theme proposed the bringing together of various activities in the fields of the knee joint, arthroscopy, and sports medicine in the Asia-Pacific region.

It proved to be a highly memorable congress that included the establishment and presentation of the inaugural Takagi and Watanabe Award by APKASS. The Takagi and Watanabe Award memorial award was won by two highly respected surgeons, Prof Konsei Shino and Prof Kai-Min Chan, who also presented the Takagi and Watanabe Award lectures.



01



02



03

The famous opera singer, Michie Nakamaru, performed the Japanese national anthem solo at the opening ceremony. The congress program included six special lectures, nine lunchtime seminars, four morning seminars, and four evening seminars. In addition, there were four symposia with the themes of the ACL, Cartilage, Shoulder, and Arthroscopy, respectively.



04

APKASS received a total of 215 abstracts, but owing to time and space limitations, 66 abstracts were selected for oral presentations. The three best posters were announced at the closing ceremony.

The congress attendees were given special night admission to the famous and World Heritage-classified Todaiji Great Buddha before the very enjoyable Gala Party, which was held in the Japanese Garden at this venue.

Many APKASS member provided very positive feedback on the success of our inaugural APKASS Congress, praising the well balanced program that not only showcased the fields of orthopaedics, arthroscopy, and sports medicine, but that also highlighted the vitality of medical science in Japan and the Asia-Pacific region. We hope that all of the participants found it a rewarding and productive experience.

- 01 APKASS board member at the Nara Hotel, Japan.
- 02 APKASS President, Mitsuo Ochi, presenting the congress welcome speech in the Noh Butai room at the Nara Prefectural New Public Hall.
- 03 A group photo of APKASS President, Prof. Ochi, with the APKASS international attendees at the President's Banquet.
- 04 The memorial photograph of the inaugural Takagi and Watanabe Award recipients, Dr. Shino and Prof. Chan with APKASS President, Prof. Ochi, at the Gala Party.

## 11th International Forum of Orthopedic Sports Medicine and Arthroscopy Surgery (IFOSMA)

May 7–10, 2014  
Shanghai, China

The 11th International Forum of Orthopedic Sports Medicine and Arthroscopy Surgery (the 11th IFOSMA) was held successfully at a new set-up Shanghai Convention & Exhibition Center of International Sourcing from May 7–10, 2014. IFOSMA has been recognized as an ISAKOS approved CME course for almost 7 years. This year's congress is also sponsored collaboratively by ISAKOS, COA and CSSM together. During the pre-course on May 7, over 400 orthopaedists participated in the first Sino-United Advanced Courses on Sports Injury Imaging Diagnosis with Ultrasound and MR. More than 1,000 orthopaedists from all over China took part in the Forum from May 8–10, which was highlighted by over 80 renowned experts, domestic and abroad in the fields of Sports Medicine and Arthroscopy. The main forum contained 28 keynote speeches, 12 sessions of panel discussion (including knee, shoulder and elbow, hip, ankle, wrist, cartilage repair, tendinopathy, rehabilitation), and 6 live surgical demonstrations (a rehearsal for 2017–ISAKOS congress in China). The Chinese editorial board of *Journal of Arthroscopy* met at the same time. "It has provided an ideal platform for attendees to share latest experiences and practices on Sports Medicine and Arthroscopy, under the congress theme '**Better Life with Sports; Healthier Life with Sports Medicine**'" said Professor Shiyi Chen, MD, PhD, the chairman of the congress and the course, a director of Fudan University Sports Medicine Center at Huashan Hospital in Shanghai, China.

Since 2002, the IFOSMA has been held 11 times and each one of them turned out to be a success. So far, it has earned the common recognition in this special field both in China and abroad; and it has become a significant platform for doctors and scholars in Orthopedic Sports Medicine and Arthroscopy Surgery in China to pursue a more advanced and international career. As IFOSMA has been accepted as an international course by ISAKOS, we will continue to dedicate ourselves to developing the advanced medical educational training course in China.

We tried our best to make the IFOSMA an international, academic conference as all procedures and protocols met with the internationally recognized standards. Our success is contingent on the constant support and advice from ISAKOS, AANA, CMA and APKASS.

Besides, we could not forget to mention the previous support from other prestigious hospitals and associations, such as HSS, MGH, UPMC, Duke University, UNSW St-George Hospital Australia as well as FIMS, IOC and AFC.

During the forum, a piece of exciting news was released. Shanghai won the bid to host the 2017 11th Biennial ISAKOS Congress in 2017, which will definitely promote the development of Sports Medicine and Arthroscopy in China, due to one-year strenuous efforts leading by Professor Shiyi Chen from the Dept. of Orthopaedic Sports Medicine, Huashan Hospital, Fudan University in Shanghai. From now on, Shiyi's team will keep going to work harder with ISAKOS to prepare the 2017 ISAKOS Congress as their main work. It is our sincere hope that the 2017 ISAKOS Congress will be a splendid success in Shanghai. In order to achieve the goal, it is inevitable that we need the support and guidance from ISAKOS.

## Find us at the AAOS Annual Meeting!

March 24–28, 2015  
Venitian/Sands Expo  
Las Vegas, Nevada, USA

Booth #1562





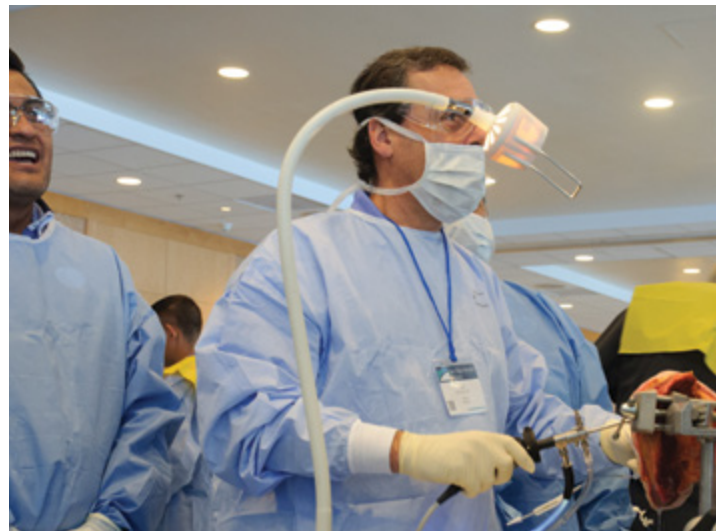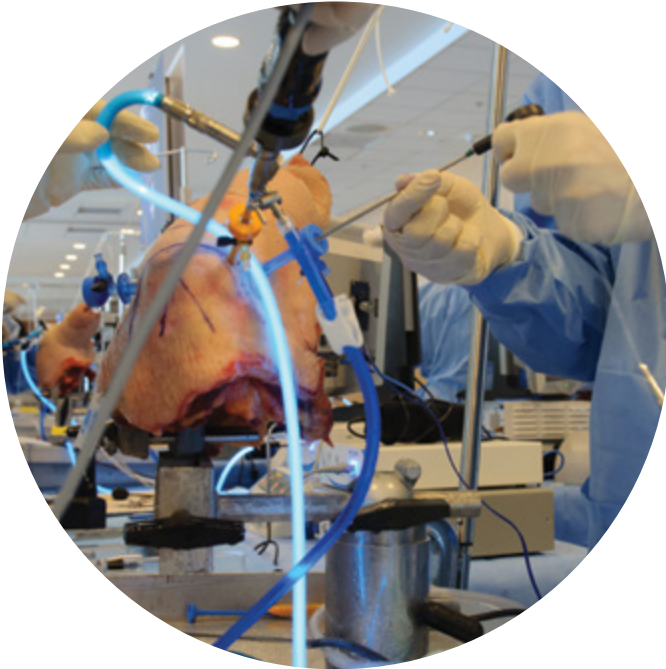
## 31st Annual San Diego Shoulder Course

June 18–21, 2014  
San Diego, CA, USA

Almost 700 Orthopaedic physicians, allied health professionals, and industry representatives gathered at the Hilton Bayfront San Diego for the 31st Annual San Diego Shoulder Course. Course attendees represented thirty-six countries.

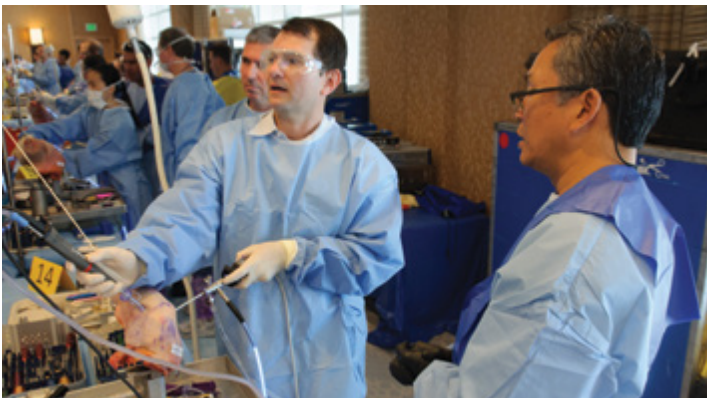


In 2013 SDSI moved the course venue to the heart of San Diego, CA. This central location affords attendees the ability to enjoy spectacular California weather, walk to various sight-seeing attractions, and maintain close proximity to course offerings.



James C. Esch, MD founded the original course in 1983. Over the years, the course has grown in reputation and popularity. San Diego Shoulder Institute (SDSI) is committed to advancing the professional practice of shoulder care and resultant patient outcomes by hosting a broad spectrum annual shoulder symposium. Recognized as “The Best Shoulder Course in the World” this year proved no exception. One registrant documented “Not only is the San Diego Course the best in the world, it is the best sub-specialty learning opportunity in the world bar none”.

In 2014 Matthew T. Provencher, MD served as course Co-Chair. Dr. Provencher’s extensive military and surgical background brought a wealth of new and diverse topics to the course agenda. The popularity of the course allows the chairs to recruit the leading shoulder experts in the field to serve as course faculty.



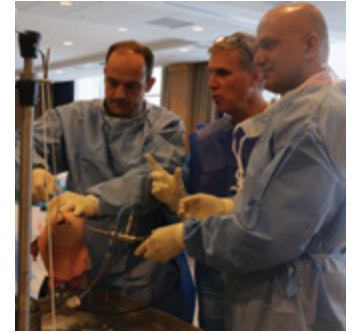
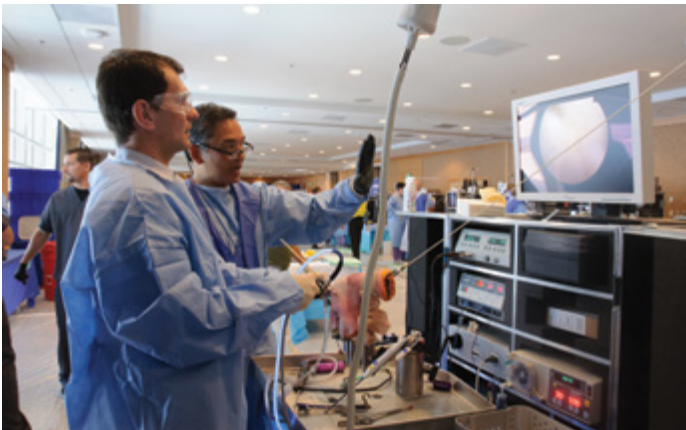
### 31st Annual San Diego Shoulder Course

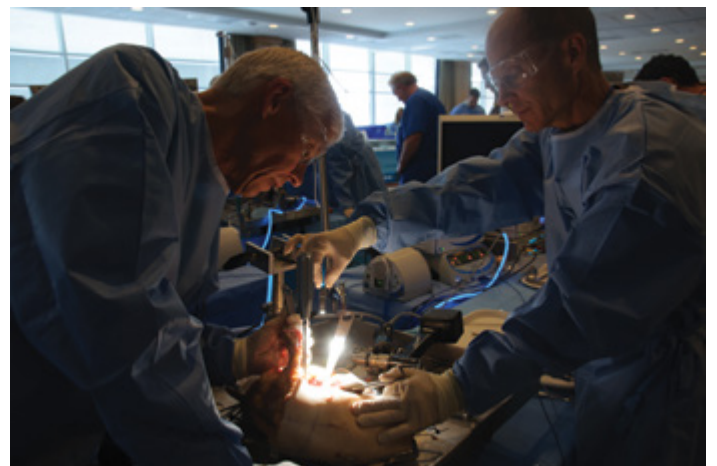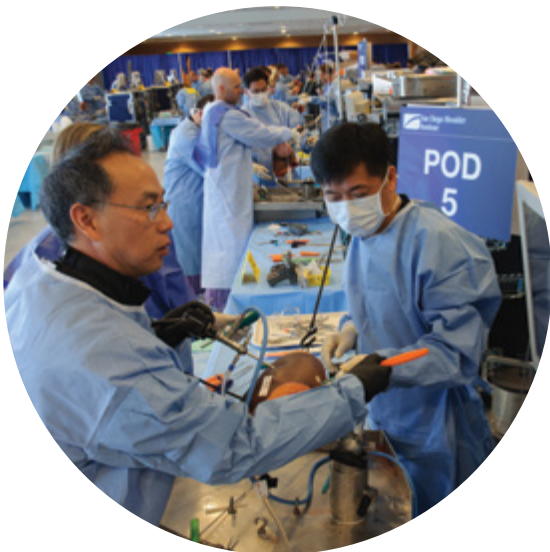
Part of SDSI's attraction is its varied and robust agenda. Participants can structure learning opportunities based on interest and level of expertise. Course lectures cover a broad spectrum of topics including arthroscopy, arthroplasty, reverse arthroplasty, instability, cuff repair, and rehabilitation. SDSI is recognized for expert faculty representing leading experts from both the United States and abroad. Lecture sessions are followed by interactive and dynamic case study panel discussions. Dispersed between lecture sessions are individualized hands on laboratories. Laboratories include: cadaveric laboratories (focusing on arthroscopy, Latarjet, and arthroplasty), a total shoulder and fracture fixation workshop, an arthroscopy model lab, and a mini-executive rotator cuff repair fellowship. The course also offers a variety of intimate break-out sessions addressing specialized interest groups. Included in the offerings are: How to Fix Big Tears, Open and Closed Latarjet Technique, Cuff Repairs, Instability, Clavicle Fractures, and Special Considerations for the High Impact Athlete (such as cross-fit).



Course laboratories are unique in that SDSI believes in individualized and customized training. With a strong compliment of expert teaching staff, laboratory participants are afforded the opportunity to perform a specialized procedure in the company of an expert practitioner in a mock surgical environment.



A DVD of course lectures is released in October of each year. The course is unique and phenomenal. You won't want to miss the next course June 17–20, 2015 at the Hilton San Diego Bayfront.



## The 6th Annual Meeting of the Japanese Orthopaedic Society of Knee, Arthroscopy and Sports Medicine (JOSKAS)

July 24 – 26, 2014  
Hiroshima, JAPAN

Masataka Deie,  
Professor  
Institute of Biomedical & Health Sciences,  
Laboratory of Musculoskeletal Functional Research  
and Regeneration  
Hiroshima University

The 6th Annual meeting of the Japanese Orthopaedic Society of Knee, Arthroscopy, and Sports (JOSKAS) was held at the International Conference Center and the neighboring Hiroshima City Bunka Koryu Kaikan, Hiroshima, Japan, from July 24–26 with additional seminars on July 26–27, 2014 under the President Professor Mitsuo Ochi, who is Professor and Chairman of the Department of Orthopaedic Surgery in the Graduate School of Biomedical Sciences, Hiroshima University, and Society President of Japanese Orthopaedic Society of Knee, Arthroscopy and Sports Medicine.

JOSKAS was established by the merger of the Japan Arthroscopy Association and the Japan Knee Society, both of which were originally founded by Prof. Masaki Watanabe in 1975. The inaugural JOSKAS annual meeting was held in 2009, and this year marks the 40th anniversary of our parent societies.



01

JOSKAS established the “Masaki Watanabe Award” at its inaugural 2009 meeting to show respect for the achievements of Prof. Watanabe, who has been called the “Father of Arthroscopy”. The Masaki Watanabe Award is not presented every year, but previous recipients include Prof. Ejnar Eriksson, Prof. Gary Poehling and Prof. Konsei Shino. In 2014, the recipients of the JOSKAS Masaki Watanabe Award are Prof. Kazunori Yasuda, Hokkaido University, Japan and Prof. Freddie Fu, Pittsburgh University, USA.



02



03

The Masaki Watanabe Award was presented to Prof. Yasuda and Prof. Fu at the 6th JOSKAS meeting in Hiroshima, to recognize their great contributions to ACL injury and reconstruction. In addition to being honored with the Award, Prof. Yasuda and Prof. Fu presented the Masaki Watanabe Award Lectures.

The theme of the 2014 congress was “Creativity Brings the Future”. Prof. Philippe Neyret, France, Prof. Mats Brittsberg, Sweden, Prof. Giuliano Cerulli, Italy, Prof. Paolo Adravanti, Italy, Prof. Alessandro Castagna, Italy, Prof. Marc Safran, USA, Prof. Christopher Chuinard, USA, Dr. Andreas Gomoll, USA, Prof. Hwa-Chang Liu, Taiwan, Prof. Chih-Hwa Chen, Taiwan, and Dr. Peter Koch, Switzerland were the invited speakers. There were three invited lectures, eight symposiums, eight panel discussions, and 17 Itsukushima lunchtime seminars. The 6th JOSKAS received 953 abstracts for the congress and 2110 attended from Japan, Korea and Saudi Arabia



04



05

JOSKAS has two important objectives: to educate young doctors about arthroscopy and joint surgery, and to enlighten the community about Locomotive syndrome (motor functional disease). The 6th JOSKAS congress included JOSKAS seminars on 26th and 27th June. The aim of the seminar was to teach young orthopaedic surgeons about arthroscopic and total knee arthroplastic surgical techniques and theory. 143 surgeons observed the techniques required for knee, shoulder, and hip arthroscopy, and for total knee arthroplasty.



**The 6th Annual Meeting of the Japanese Orthopaedic Society of Knee, Arthroscopy and Sports Medicine (JOSKAS)**



06

The special program included a discussion by the People's Honor Award winner, Mr. Sachio Kinugasa who is a former professional baseball player for the Hiroshima Carp. The famous Japanese sports journalist, Mr. Seijun Ninomiya, also presented a discussion entitled "Thinking Process of the Victor". At the President's banquet, we enjoyed a concert with Miss Mami Hagiwara who is the famous pianist from Hiroshima and the violinist, Mr. Tatsuki Narita. A regular fixture of our annual meetings is the JOSKAS Cup, which is a tug of war held at the Gala Party. The Hiroshima team won the first prize.

All participants of the seminars enjoyed watching a Japanese professional baseball game (Hiroshima Carp vs Hanshin Tigers) at the Mazda Stadium. At this night game, the JOSKAS President, Prof. Ochi, wore the uniform of the 6th JOSKAS congress when he performed the first pitch of the game. On the afternoon of June 27, a seminar for citizens about Locomotive syndrome was held with over 500 attendees.

We believe that the 6th Annual JOSKAS Meeting was very successful in providing a well-balanced program and in showing future directions for the fields of Orthopaedics, Arthroscopy and Sports Medicine. We hope that all participants found it a rewarding and productive experience.



07a



07b



07c

- 01 Presentation at the 6th JOSKAS Congress Presidential Banquet. From right to left: Prof. Kurosaka, Prof. Shino, JOSKAS President Prof. Ochi, Mrs. Ochi, Prof. Castagna, Mrs. Mazzotti, Prof. Brittberg, Prof. Yasuda,.
- 02 Presentation of the Masaki Watanabe Award. Prof. Yasuda and JOSKAS President, Prof. Ochi, are in the picture on the right.
- 03 Prof. Fu and President Prof. Ochi are in the picture on the left.
- 04 The top center picture shows the symbol of the Masaki Watanabe Award
- 05 A signboard for the 6th JOSKAS congress.
- 06 International guests and Japanese friends were invited by JOSKAS President, Prof. Ochi, to a Japanese restaurant.
- 07abc JOSKAS President, Prof. Ochi, wearing the uniform of the 6th JOSKAS congress, as he performs the first pitch at the Mazda Baseball Stadium.



## 12th Congress of Turkish Society of Sports Traumatology, Arthroscopy and Knee Surgery (TUSYAD)

September 23–27, 2014  
Izmir, Turkey

Halit Pinar, MD  
Congress President  
TUSYAD President

12th Congress of Turkish Society of Sports Traumatology, Arthroscopy and Knee Surgery (TUSYAD) was held on September 23–27, 2014 in Izmir, Turkey.

The congress was almost like a “Regional ISAKOS Congress” with great success; we have received excellent feedback. A total of 63 international participants represented 18 countries. All together 653 participants (490 physicians, 163 physiotherapists) attended the congress. 27 companies supported the congress and took part at the commercial exhibits.

A total of 190 abstracts, 64 of which were free papers, were presented in three parallel sessions, and the rest were e-poster presentations. The abstracts will be published in *Orthopedic Journal of Sports Medicine* which is listed as the official journal of TUSYAD. Besides, 13 ICLs, 10 symposia, 7 interactive symposia, 2 debates and 35 lectures, sometimes in three parallel sessions, took place in the program. ISAKOS, ESSKA, APKASS and EFOST lectures were attended with great interest. Thanks to ISAKOS, ESSKA and EFOST for their scientific support, as their logo appeared in congress materials.


Friends from AGA organized their second symposia with great success after 8 years. Simultaneous translation was provided in all Halls throughout the congress.

During the Welcome Cocktail Reception, the band “21. Peron”, formed mainly by physicians (and one orthopaedic surgeon) played their song titled “A Mini Concerto for ACL” which is the first one of its kind; it was the world premiere

Besides high level scientific discussions, this 3.5-day event also satisfied the beginners with its basic content. The participants were social and involved in a lot of cultural exchange.

The next TUSYAD Congress will be held in 2016 Autumn in Istanbul—where the continents meet.

Many thanks and best regards to all the participants!



## International Sports Medicine Fellows Conference

January 23–25, 2015  
Carlsbad, CA, USA

The International Sports Medicine Fellows Conference, held on January 23–25, 2015 in Carlsbad, California was a great success! Dr. Bert Mandelbaum wishes to thank ISAKOS for their support and patronage of this course, including approval as an ISAKOS Approved Course, and for the International Sports Medicine Fellows Scholarship that was awarded to Lukasz Andrzej Lipinski, MD and Nikolaos K. Paschos, MD, PhD of Greece and Poland.



The ISMF Conference is specifically geared towards the unique needs of the Sports Medicine Fellow, and includes a unique opportunity for fellows to learn the latest advancements in articular cartilage treatment and participate in the largest gathering of 2014–2015 orthopaedic sports medicine fellows. The Conference is a two day course including a variety of lectures, case presentations, surgical demonstrations and hands-on workshops designed to enhance Fellows’ knowledge of orthopaedic sports medicine. An interactive, case-based approach teaches the work-up, management and the rehab techniques utilized by the international expert faculty.



The 2015 ISMF Conference included 74 fellows, a spectacular international faculty and a very diverse and comprehensive group of sponsors. The program was extremely state of the art, unique and the fellows had an amazing didactic exchange.

The atmosphere was extremely positive and everyone in attendance had a great experience. We look forward to the 16th ISMF Conference on 22–24, 2016 at the Sheraton Carlsbad.

## UPCOMING ISAKOS APPROVED COURSES

Delhi Arthroscopy Cadaveric Course 2015  
Sports Injury Centre, Safdarjung Hospital  
Delhi, INDIA

**March 21, 2015**

Chair(s): Dr. Deepak Chaudhary

**For further information, please contact:**

Dr Deepak Joshi  
Tel: +919810430634  
Fax: +1-26181907  
[indiaarthroscopylearning.com](http://indiaarthroscopylearning.com),

2015 59th, 60th Severance Arthroscopy  
Cadaver Workshop  
Anatomy Center, Yonsei University Health  
System  
Seoul, KOREA

**March 28–April 11, 2015**

Chair(s): Sung-Jae Kim, MD, PhD

**For further information, please contact:**

Seong min Kim MD  
Tel: +82-2-2228-5679  
Fax: +82-2-363-6248  
[www.iseveranscopy.com/](http://www.iseveranscopy.com/)

XXIV International Conference on Sports  
Rehabilitation and Traumatology–Football  
Medicine Strategies for Player Care  
Queen Elizabeth II Conference  
Centre–Wembley  
London, UNITED KINGDOM

**April 11–13, 2015**

Chair(s): Peter Brukner & Stefano Della Villa

**For further information, please contact:**

Giulia Indelicato  
Tel: +39-0512986878  
Fax: +39-05119902200  
[www.FootballMedicineStrategies.com](http://www.FootballMedicineStrategies.com)

6th Congress of Hellenic Association of  
Arthroscopy, Knee Surgery and Sports  
Injuries “Georgios Noulis”  
Patras University Conference Centre  
Patras, GREECE

**April 22–25, 2015**

Chair(s): Ioannis Gliatis

**For further information, please contact:**

Ioannis Gliatis  
Tel: +30-6972260536  
Fax: +30-2610931025  
[www.eae-net.gr](http://www.eae-net.gr)

Vth Pune Knee Course

J W Marriott

Pune, INDIA

**April 23–25, 2015**

Chair(s): Dr. Sachin Tapasvi

**For further information, please contact:**

Sachin Tapasvi  
Tel: +91-9822018871  
Fax: +91-2030205055  
[www.punekneecourse.com](http://www.punekneecourse.com)  
[www.drsachintapasvi.com](http://www.drsachintapasvi.com)

The 12th International Forum on Sports  
Medicine & Arthroscopic Surgery  
Shenzhen Convention Center  
Shenzhen, CHINA

**April 27–29, 2015**

Chair(s): Prof. Shiyi Chen

**For further information, please contact:**

Jiwu Chen  
Tel: +86-13917731863  
Fax: +86-21-62496020  
[www.isakos-shanghai.com](http://www.isakos-shanghai.com)

14th STMS World Congress of Tennis  
Medicine  
Auditorium del Seraphicum  
Rome, ITALY

**May 8–9, 2015**

Chair(s): Giovanni Di Giacomo, MD

**For further information, please contact:**

Giovanni Di Giacomo, MD  
Tel: +39-065127186  
Fax: +39-065136655  
[www.spalla.it](http://www.spalla.it)

San Diego Shoulder 32nd Annual Course:  
Arthroscopy, Arthroplasty, and Fractures  
Hilton Bayfront  
San Diego, CA USA

**June 17–20, 2015**

Chair(s): James C. Esch, MD

**For further information, please contact:**

Larky Blunck  
Tel: +1-760-445-2874  
Fax: +1-951-695-6801  
[www.shoulder.com](http://www.shoulder.com)

15th Amsterdam Foot and Ankle Course  
Academic Medical Centre  
Amsterdam, NETHERLANDS

**June 17–18, 2015**

Chair(s): Prof. Dr. C.N. van Dijk

**For further information, please contact:**

Rogier Gerards  
Tel: +31-205662474  
Fax: +31-205669117  
[www.ankleplatform.nl](http://www.ankleplatform.nl)

Advanced Foot & Ankle Course  
Academic Medical Centre  
Amsterdam, NETHERLANDS

**June 18–19, 2015**

Chair(s): Prof. Dr. C.N. van Dijk

**For further information, please contact:**

Rogier Gerards  
Tel: +31-205662474  
Fax: +31-205669117  
[www.ankleplatform.nl](http://www.ankleplatform.nl)

Watch and Try–SIGASCOT Course  
Ceramica Florim  
Fiorano Modenese, ITALY

**June 18–20, 2015**

Chair(s): Luigi Pederzini

**For further information, please contact:**

Nives Sagramola  
Cell: +39-338-3837991  
Tel: +39-055-23991  
Fax: +39-055-4641490  
[www.sigascot.com](http://www.sigascot.com)

Delhi Arthroscopy Course 2015  
Le Meridean  
Delhi, INDIA

**June 27–28, 2015**

Chair(s): Dr. Deepak Chaudhary

**For further information, please contact:**

Dr. Deepak Joshi  
Tel: +91-9810430634  
Fax: +1-26181907  
[indiaarthroscopylearning.com](http://indiaarthroscopylearning.com),

Advanced Instructional Courses on  
Arthroscopy of Shoulder, Elbow, Wrist and  
Knee; Arthroplasty of Shoulder and Elbow  
University Medical Centre Utrecht  
Utrecht, NETHERLANDS

**July 6–10, 2015**

Chair(s): Dr. W. Jaap Willems

**For further information, please contact:**

Arthroscopy and Arthroplasty 2015  
Tel: +31-30-276 9174  
Fax: +31-30-276 9251  
[www.shoulder-elbow-knee.nl/](http://www.shoulder-elbow-knee.nl/)

2015 The Ligament Reconstruction  
Seminar & Live Surgery in Sapporo  
Faculty House “Trillium (Enreiso)” in  
Hokkaido University  
Sapporo, JAPAN

**July 30–31, 2015**

Chair(s): Kazunori Yasuda

**For further information, please contact:**

Eiji Kondo  
Tel: +81-(0)11-706-7211  
Fax: +81-(0)11-706-7822  
[hokudai-med-sports.org/en/index.html](http://hokudai-med-sports.org/en/index.html)

Innovative Techniques The Knee

Course 2015

Caesars Palace

Las Vegas, NV, USA

**September 17–19, 2015**

Chair(s): Bryan Hanypsiak, MD

**For further information, please contact:**

Susan McNair  
Tel: +1-973-290-8254  
Fax: +1-201-822-6114  
[www.knee-cme.org](http://www.knee-cme.org)

Is your Course an...

**ISAKOS**  
Approved-Course

[www.isakos.com/meetings](http://www.isakos.com/meetings)

9th International Caste Meeting with Live Surgery ATOS Hospital Heidelberg Historical Heidelberg Castle Heidelberg, GERMANY

**October 1–3, 2015**

Chair(s): Prof. Rainer Siebold, Prof. Fritz Thorey, Prof. Hajo Thermann

**For further information, please contact:**

Prof. Rainer Siebold  
Tel: +49-6221983190  
Fax: +49-6221983199  
www.kreuzband.de

Meniscus Pathology: Remove, Repair, Replace Istituto Ortopedico Rizzoli, Sala Vasari, Bologna, ITALY

**October 16, 2015**

Chair(s): Stefano Zaffagnini, MD,

**For further information, please contact:**

Nives Sagamola  
Tel: +39-055-2399112  
Fax: +39-055-4641490  
www.sigascot.com

Rome Joins the World Shoulder Instability Hotel Sheraton Roma Rome, ITALY

**October 24, 2015**

Chair(s): Dott. Giovanni Di Giacomo - Concordia Hospital - Rome, Italy

**For further information, please contact:**

Giulia de Leva  
Tel: +39-06-328121  
Fax: +39-06-3222006  
www.romeshoulder2015.ega.it

4th Biennial Congress of Iranian Society of Knee Surgery, Arthroscopy & Sport Traumatology International Convention Center, Milad Tower Tehran, IRAN

**May 17–20, 2016**

Chair(s): Dr. Javad Parvizi

**For further information, please contact:**

Keivan Ahadi  
Tel: +98-2188777176  
Fax: +98-2188777176  
www.ISKAST2016.com

10TH Biennial

# ISAKOS CONGRESS 2015

JUNE 7–11, 2015  LYON, FRANCE

**NEW FOR 2015!**

**REGISTER BY APRIL 30TH AND SAVE \$100 OR MORE!**

Add the Sports Rehabilitation Concurrent Course to Your Congress Registration for ONLY \$100!





## 2015 CONGRESS LIVE INTERACTIVE AGENDA

Visit [www.isakos.com/2015congress](http://www.isakos.com/2015congress) to view the LIVE Interactive Agenda



## myCongress

-  Your Personal Portal to the 2015 Congress
-  Manage your abstract submission, program participation, registration status and more!

[www.isakos.com/myCongress](http://www.isakos.com/myCongress)



TWEETING ABOUT THE CONGRESS?

Include #ISAKOS2015 in your Tweets and join the global conversation!





## ISAKOS Nominating Procedure 2015–2017

ISAKOS is pleased to announce the start of the Nominating Procedure for the office of 2nd Vice President of ISAKOS. The 2nd Vice President will serve as President of ISAKOS from 2019–2021.

Beginning on **Wednesday April 1, 2015**, the online process for making Online Recommendations for the position of 2nd Vice President will open. This system will remain open until April 15, 2015 at 11:59pm Pacific Time. Online recommendations can only be made by Active and Honorary Members of ISAKOS.

Candidates for Recommendation must meet the following criteria:

- Members may not recommend themselves.
- Recommended candidates must be ISAKOS Active or Honorary Members in good standing (all dues paid). There are no geographical limitations on recommendations.
- Candidates must complete the application within stated deadline of April 30th.

After the Recommending process has closed, Candidates will be required to receive 20 “seconds” from April 16–30, 2015. Once candidates have received 20 seconds, they will be considered an official candidate for the office of 2nd Vice President.

The selection of 2nd Vice President and other necessary Executive Committee positions will be made by the Nominating Committee. The Nominating Committee will be selected at the First Business Meeting, during the 2015 ISAKOS Congress.

More information on the Election Process will be sent in March. If you have any questions, please email [isakos@isakos.com](mailto:isakos@isakos.com).

### Important Dates:

<b>April 1–15, 2015</b>	Recommendations received from Membership using online system
<b>April 15–30, 2015</b>	Candidates will be listed on ISAKOS website for Seconding (each candidate must receive 20 seconds)
<b>Monday, June 8</b> 9:30–10:10am	ISAKOS Congress Business Meeting I (Selection of Nominating Committee, Nominations for Board of Directors)
<b>Wednesday, June 10</b> 9:30–10:10am	ISAKOS Congress Business Meeting II (Announcement of ISAKOS Executive Committee & Board of Directors)

## SPORTS MEDICINE INJECTIONS

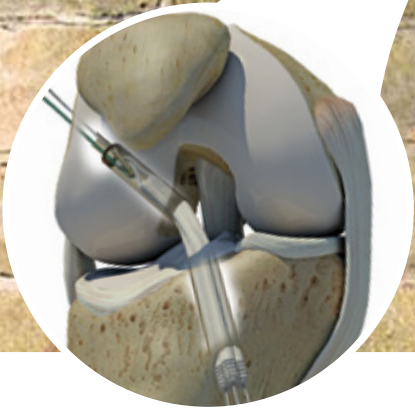Injections are a current practice not only in sports medicine but in the practice of general orthopaedics. Right at this moment, thousands are being made worldwide. Injections are used in a variety of joints and anatomical structures, with different drugs, and to treat different pathologies. Complications are rarely known as few are reported.

To understand more about the use of injections in sports medicine, the ISAKOS Orthopaedic Sports Committee has developed a brief survey to gather information that can give a better knowledge about this massive practice. The results will contribute to the goal of establishing a consensus about the use of injections, and provide guidelines for surgeons and patients for scientific use.

To complete the survey, please visit [www.isakos.com](http://www.isakos.com).







## Helping to put patients back together again.

Nobody knows anatomic ACL reconstruction like Smith & Nephew. We've been restoring the ACL using anatomic techniques from the very beginning. So whether your reconstruction preference is soft tissue or bone-tendon-bone, using an inside-out or outside-in technique, we have everything you need – including the product training to make it your own. **Smith & Nephew. The Anatomic ACL Company.**


Learn more at [smith-nephew.com/anatomicACL](http://smith-nephew.com/anatomicACL)



**ENDOBUTTON® CL  
ULTRA**  
Fixation Devices



**ACUFEX®  
PINPOINT**  
Anatomic ACL Guide System



**CLANCY™  
ANATOMIC  
CRUCIATE GUIDE**  
Flexible Drill System



**BIOSURE®  
SYNC**  
Tibial Fixation Device



Smith & Nephew, Inc.  
150 Minuteman Road  
Andover, MA 01810  
USA

[www.smith-nephew.com](http://www.smith-nephew.com)  
T +1 978 749 1000  
US Customer Service: +1 800 343 5717  
International Customer Service: +1 978 749 1140

®Trademark of Smith & Nephew. Registered  
US Patent and Trademark Office. All Trademarks  
acknowledged ©2014 Smith & Nephew. All rights  
reserved. Printed in USA. 00348 V2 03/14





**International Society of Arthroscopy,  
Knee Surgery and Orthopaedic Sports Medicine**

2410 Camino Ramon, Suite 215  
San Ramon, CA 94583-4318 USA

Telephone: +1 925 807-1197  
Fax: +1 925 807-1199  
isakos@isakos.com  
www.isakos.com



✦ Visit [www.isakos.com](http://www.isakos.com)

## ISAKOS CONGRESS PRE-COURSES

**Saturday, June 6, 2015**

*Pre-Courses are only \$200 per course if you register by April 30, 2015*

✦ **Advances in the Management of Knee Pathology: ACL, Meniscus, Patellofemoral, Osteotomy, and Chondral Pathology**

Elizabeth A. Arendt, MD, USA

David Anthony Parker, MBBS, BMedSci, FRACS, AUSTRALIA

Willem M. Van Der Merwe, MBChB, FCS, SA Ortho, SOUTH AFRICA

✦ **International Update on Surgical Controversies of the Shoulder**

Guillermo R. Arce, MD, ARGENTINA

Philippe Hardy, PhD, FRANCE

Eiji Itoi, MD, PhD, JAPAN

✦ **ISAKOS & FIFA Challenges in Safety and Health in Football 2015**

Moises Cohen, MD, PhD, BRAZIL

Joao Espregueira-Mendes, MD, PhD, PORTUGAL

Jose F. Huylebroek, MD, BELGIUM

Bert R. Mandelbaum, MD, DHL (Hon), USA

Michel D'Hooghe, MD, BELGIUM

Jiri Dvorak, Prof., SWITZERLAND

**10<sup>TH</sup> Biennial**

# ISAKOS CONGRESS

# 2015

**JUNE 7-11, 2015** ✦  
**LYON, FRANCE**

## SPORTS REHABILITATION CONCURRENT COURSE

**Sunday, June 7 – Tuesday, June 9, 2015**

✦ **Chairs:**

James J. Irrgang, PT, PhD, ATC, FAPTA, USA

Robert F. LaPrade, MD, PhD, USA

Lynn Snyder-Mackler, PT, ScD, FAPTA, USA

Erik Witvrouw, PhD, PT, QATAR