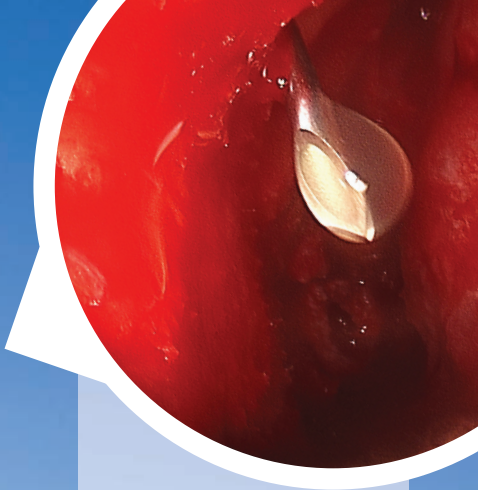
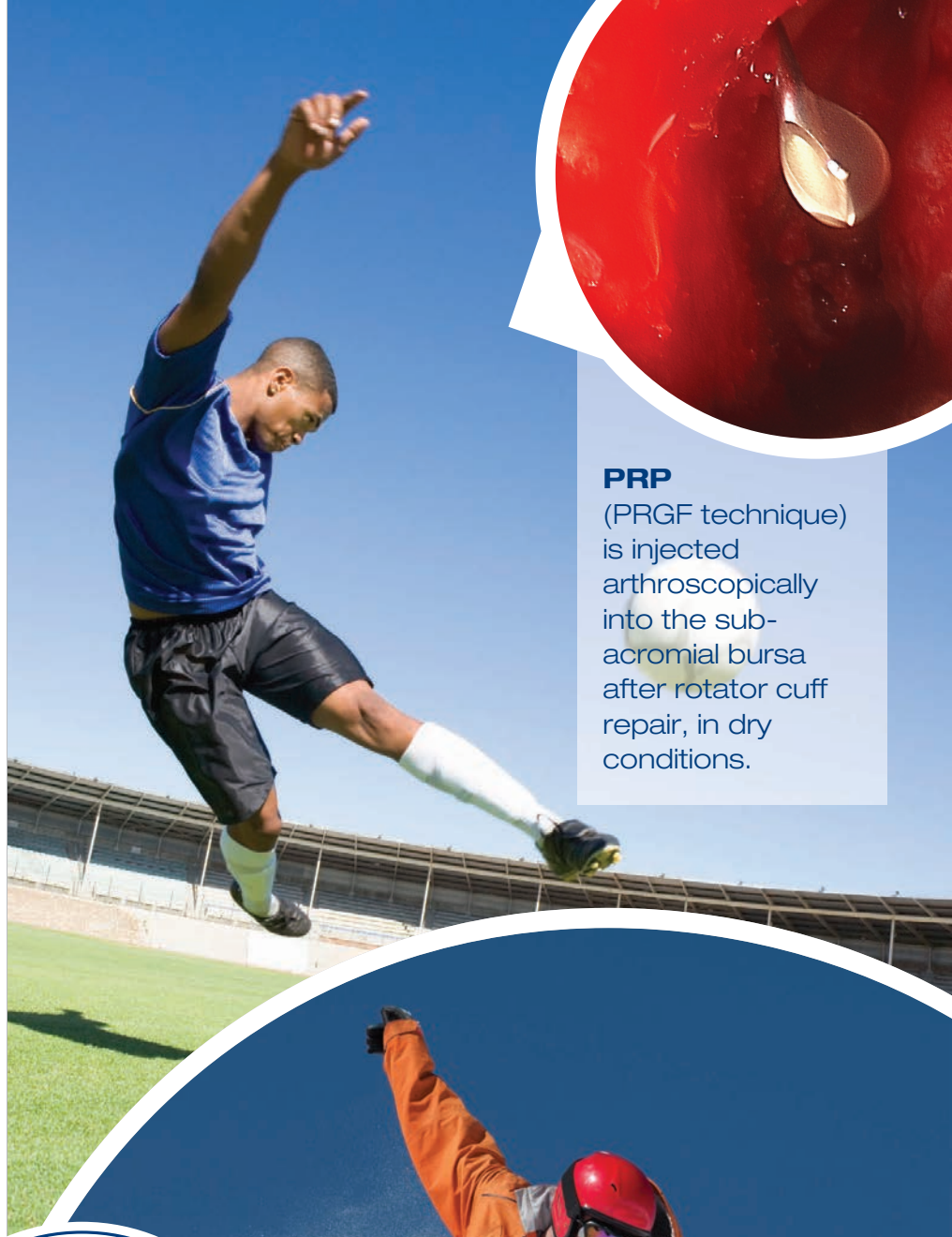


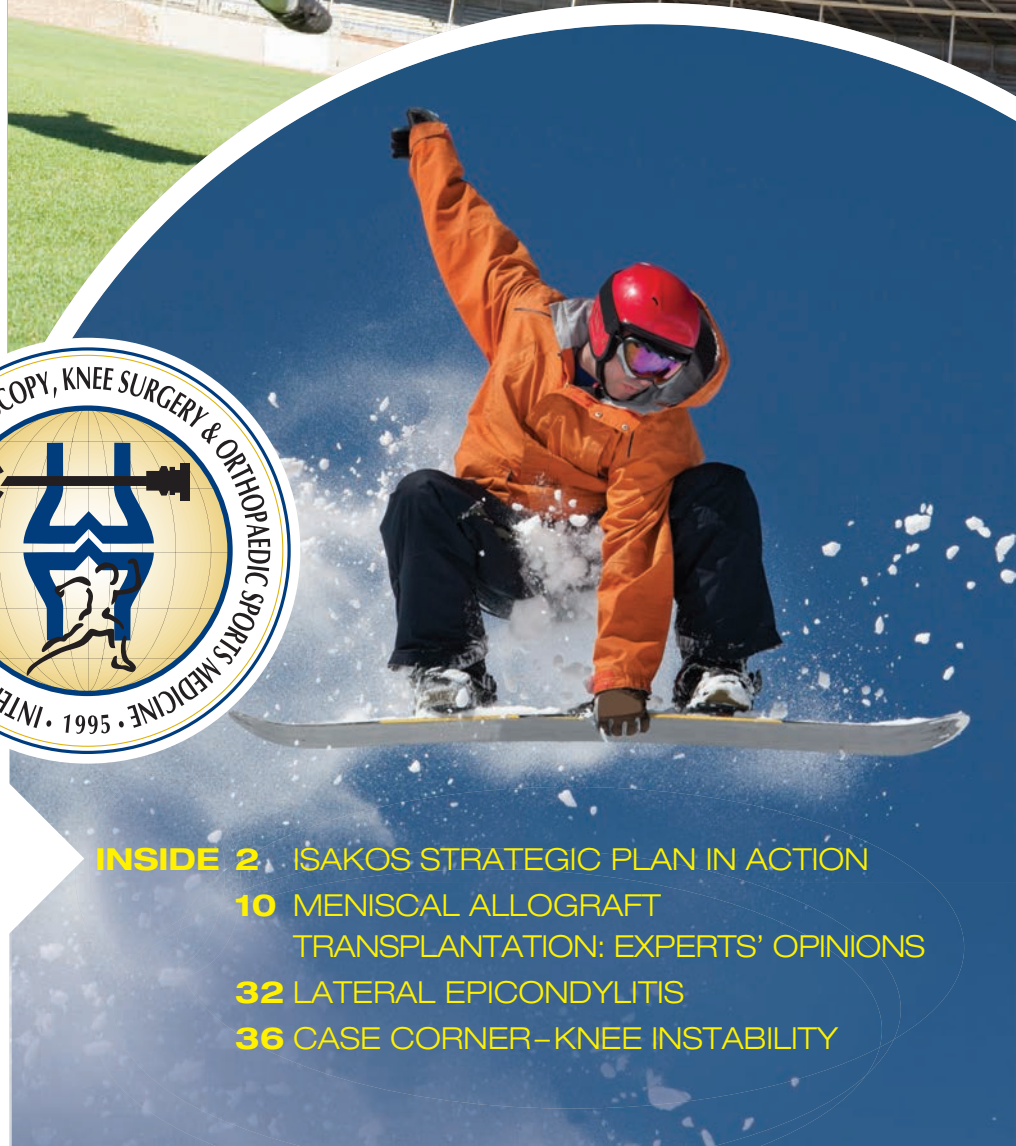ISAKOS

ISAKOS NEWSLETTER 2014 • VOLUME I

Current Concepts on Arthroscopy, Knee Surgery & Orthopaedic Sports Medicine



PRP
(PRGF technique)
is injected
arthroscopically
into the sub-
acromial bursa
after rotator cuff
repair, in dry
conditions.



- INSIDE 2** ISAKOS STRATEGIC PLAN IN ACTION
- 10** MENISCAL ALLOGRAFT
TRANSPLANTATION: EXPERTS' OPINIONS
- 32** LATERAL EPICONDYLITIS
- 36** CASE CORNER-KNEE INSTABILITY

in this issue

Editor's Message	1
ISAKOS Executive Committee Update.	2
10th Biennial ISAKOS Congress	4
ISAKOS Awards	6
Pearls & Pitfalls—Surgical Technique.	10
Current Concepts.	16
ISAKOS Asks	27
Case Corner.	36
Tip of the Day	39
Upcoming Approved Courses.	40

EDITOR

Omer Mei-Dan, MD, USA

EDITORIAL BOARD

Nadim Aslam, FRCS Orth, UNITED KINGDOM
Mandeep S. Dhillon, Prof., MS, FAMS, INDIA
Lucio S. R. Ernlund, MD, MSc, BRAZIL
Norimasa Nakamura, MD, PhD, JAPAN
David Sadigursky, MD, BRAZIL
Gonzalo Samitier, MD, PhD, USA
Daniel A. Slullitel, MD, Prof., ARGENTINA
Luis Alberto Vargas, MD, USA
James H. Lubowitz, MD, USA, Past Editor



**International Society of
Arthroscopy, Knee Surgery and
Orthopaedic Sports Medicine**

2410 Camino Ramon, Suite 215
San Ramon, CA 94583–4318 USA

Telephone: +1 925 807–1197
Fax: +1 925 807–1199
Email: isakos@isakos.com

“Year’s end is neither an end nor a beginning but a going on, with all the wisdom that experience can instill in us. Cheers to a new year and another chance for us to get it right.” –Unknown

ISAKOS would like to wish all of our members a very Happy New Year! 2013 was a great year for our society, including the celebration of the 9th Biennial ISAKOS Congress in Toronto, Canada. The ISAKOS Congress was another fantastic educational experience for all who attended, thanks in large part to our diverse faculty who created the international dialogue that ISAKOS is known for.

2013 also saw the continued expansion of the ISAKOS Website, with the introduction of the myISAKOS portal. The myISAKOS portal is a central location for everything related to your ISAKOS Membership, including online access to a variety of publications, such as Arthroscopy: the Journal of Arthroscopic and Related Surgery, and Knee Surgery, Sports Traumatology & Arthroscopy (KSSTA – by additional subscription only). NEW FOR 2014 – ISAKOS is excited to announce our partnership with OrthoEvidence - the global online source for high quality and timely orthopaedic-only evidence-based summaries, pre-appraised by orthopaedic medical experts. OrthoEvidence is the first of its kind, orthopaedic-focused evidence-based summary provider; built for the orthopaedic community by orthopaedic experts. MyISAKOS also provides access to the ISAKOS Booklets and Committee Projects.

Looking forward, 2014 promises to be another exciting year for ISAKOS! ISAKOS will be offering four collaborative courses located in Brazil, India, China, and Russia, in partnership with local organizations. For more information on these courses, we encourage you to visit the ISAKOS homepage – www.isakos.com.

Work is also underway for the 10th Biennial ISAKOS Congress in Lyon, France. Celebrating the 20th Anniversary of ISAKOS – the 10th Biennial Congress will include the same extraordinary educational content that the ISAKOS Congress is known for, including pre-courses on the Knee, Upper Extremity, and Treatment of the Football Player (in collaboration with FIFA). Other educational offerings will include Instructional Courses, Symposium, Debates, Lectures, Scientific Papers and Electronic Posters. If you are interested in presenting a scientific paper or e-Poster, please visit the ISAKOS website to submit your abstract today! Abstract submission will be available through September 1, 2014.

ISAKOS wishes all of our members and friends around the world a very Happy New Year, and we look forward to seeing you in the year ahead.



Few events inspire patriotism and rivalry as the Olympics and the World Cup! 2014 is a rare year where both events can be enjoyed mere weeks apart. *As with ISAKOS, these global events bring us all together - regardless of nation, gender, belief or even sport preference.* We admire the athlete's professionalism and perfectionism, dedication and will. We celebrate the happiness of victory, and feel the pain of defeat or injury. We have greatly enjoyed watching the snow fly at the Winter Olympics in Sochi, and look forward to turning up the heat in Rio de Janeiro as Brazil prepares to host the FIFA World Cup. Many of us will attend the Olympics and World Cup as spectators or physicians, supporting and treating some of the best athletes of our generation. ISAKOS has played our own unique role in these events, as we recently partnered with FIFA for a Football Medicine course in Sao Paolo, Brazil.

ISAKOS' new partner "OrthoEvidence" has come up with an exclusive weekly updated report of the various sports injuries the competing athletes have suffered in Sochi, most prominently ACL injury. Some unique stories feature athletes who have bounced back to win medals just weeks after being operated on for various injuries. Check this interesting list out: <http://www.myorthoEvidence.com/olympics>

Raising the global diversity flag, this ISAKOS Newsletter includes everything from basic science to cutting edge surgical techniques. From "Cytokines in Sports Medicine" to "The Sport of Cricket," and from "Scaphoid Fractures" to the world experts' opinion on hot topics like Meniscal Allograft Transplantation.


Since the last issue was published we have also learned something about us as practitioners of arthroscopy, knee surgery and orthopaedic sports medicine. We have learned that more than 80% of us use auto hamstrings as our primary ACL graft. We also learned that the average ISAKOS Member takes only 3-4 weeks of vacation per year. [How do you compare to the ISAKOS Asks responses?](#)

We will conclude our issue with the wise words of our past editor, Dr. James Lubowitz, which in a very fine way, teaches us how to conclude a patient's visit in the most "open" way.




We hope you enjoy this issue of the ISAKOS Newsletter.

Omer Mei-Dan, MD, USA

**ISAKOS Members
Now Receive Full Access to
OrthoEvidence**



ISAKOS/OrthoEvidence Portal

<p style="font-size: 2em; font-weight: bold; color: red;">1</p> <p>Go to www.isakos.com and log in to myISAKOS</p> <div style="text-align: center; margin-top: 10px;">  </div>	<p style="font-size: 2em; font-weight: bold; color: red;">2</p> <p>Click on myPublications in the myISAKOS Dashboard</p> <div style="text-align: center; margin-top: 10px;">  </div>	<p style="font-size: 2em; font-weight: bold; color: red;">3</p> <p>Click "Access" the ISAKOS/OrthoEvidence Portal</p> <div style="text-align: center; margin-top: 10px;">  </div>
---	--	--

The ISAKOS Strategic Plan in Action

On behalf of the ISAKOS Executive Committee—thank you for your membership with ISAKOS! As we begin 2014, the ISAKOS Executive Committee would like to update our membership on how the ISAKOS Strategic Plan, developed during the 2013 ISAKOS Congress, is being put into action around our Society.

Education

ISAKOS' Mission Statement is to “advance the worldwide exchange and dissemination of education, research and patient care in arthroscopy, knee surgery and orthopaedic sports medicine”. We are working towards this goal through a variety of efforts, including our many collaborative courses around the world. Our collaborative courses for 2014 include the “ISAKOS & FIFA Collaborative Course on Football Medicine”, to be held on February 15–16 in Sao Paulo, BRAZIL; the “ISAKOS & ISKSAA and IAA Collaborative Course”, to be held on March 1–2 in Chennai, India; the “11th International Forum on Orthopaedic Sports Medicine & Arthroscopic Surgery—an ISAKOS Collaborative Course with CMA, COA and CSSM” to be held on May 8–10 in Shanghai, CHINA; and the “3rd ASTAOR International Congress - in collaboration with ESSKA and ISAKOS” to be held on September 10–12 in Moscow, RUSSIA. These courses are only possible with the cooperative efforts of the local organizers, and our fantastic faculty who are willing to spread their knowledge to ISAKOS' global community.

One of ISAKOS' primary goals in recent years has been to increase online education. This effort is reaching a new height with the continued improvement of ISAKOS Global Link – ISAKOS online education platform. ISAKOS Global Link is an online access point for ISAKOS materials including Newsletter articles, Congress archives, surgical skills videos and Committee Projects. New content includes five online courses developed from Surgical Skills Demonstrations held during the 2013 ISAKOS Congress in Toronto.

ISAKOS is always looking for ways to improve, and this is especially exemplified in our Teaching Center program. Teaching Centers were recently asked to update their information, including answering additional questions about facilities, specialties, financial support and more. This information will be made available on the ISAKOS website in the coming months, and we hope it will be very helpful to any surgeon looking to expand their skills through continuing education and training. Surgeons looking to continue their education are also invited to apply for an ISAKOS Teaching Center Scholarship. The Teaching Center Scholarships are available to support travel of a deserving student to one of our ISAKOS Teaching Centers.

Membership

ISAKOS is pleased to continue our ongoing efforts to increase membership. We are working towards this goal with increased Member Benefits, including the availability of OrthoEvidence for ISAKOS Members at no additional charge! For more information on accessing OrthoEvidence, please refer to www.isakos.com or see page 1 of this Newsletter.

ISAKOS continues to reach out to young surgeons with the ISAKOS Fellowship and Residency Directory. The ISAKOS Fellowship and Residency Directory allows ISAKOS Members to register their training programs with ISAKOS for inclusion in an online database. This database will be searchable for any surgeon looking for a Residency or Fellowship Program. Participation in the Registry also gives the fellows and residents in these programs access to a discounted ISAKOS Membership valid until the end of the calendar year following the completion of their Residency or Fellowship.

ISAKOS advances
the worldwide exchange
and dissemination of
education, research
and patient care in
arthroscopy, knee surgery
and orthopaedic
sports medicine.



**International Society of
Arthroscopy, Knee Surgery and
Orthopaedic Sports Medicine**

Research

In 2012, ISAKOS embarked on a new path to support research through a competitive research grant process. The purpose of the ISAKOS Research Grants Program is to provide ISAKOS members with a major resource for funding the highest quality international research in arthroscopy, knee surgery and orthopaedic sports medicine. Research Grants have been awarded to Volker Musahl for his research on “Clinical Application of Quantitative Assessment of the Pivot Shift” (renewed for 2013-2014!); Marc Safran for his research on “Can Pre-Operative 3D Computer Simulation Improve Clinical Outcomes of Arthroscopic Surgery for FAI”; and Alan Getgood for his study on “Multicenter Randomized Clinical Trial Comparing Anterior Cruciate Ligament Reconstruction With and Without Lateral Extra-articular Tenodesis in Individuals Who Are At High Risk of Graft Failure.”

The ISAKOS Research Grants Program is currently under review, and new opportunities will be available in the coming months!

Thank you,

ISAKOS Executive Committee

Masahiro Kurosaka, MD, JAPAN, President

Philippe Neyret, MD, FRANCE, First Vice President

Marc R. Safran, MD, USA, Second Vice President

Willem M. Van Der Merwe, MBChB, FCS, SA Ortho, SOUTH AFRICA, Treasurer

Joao Espregueira-Mendes, MD, PhD, PORTUGAL, Assistant Treasurer

Jon Karlsson, MD, PhD, SWEDEN, Secretary

Guillermo R. Arce, MD, ARGENTINA, Assistant Secretary

Jack Andrish, MD, USA, Consultant

Ryosuke Kuroda, JAPAN, Consultant

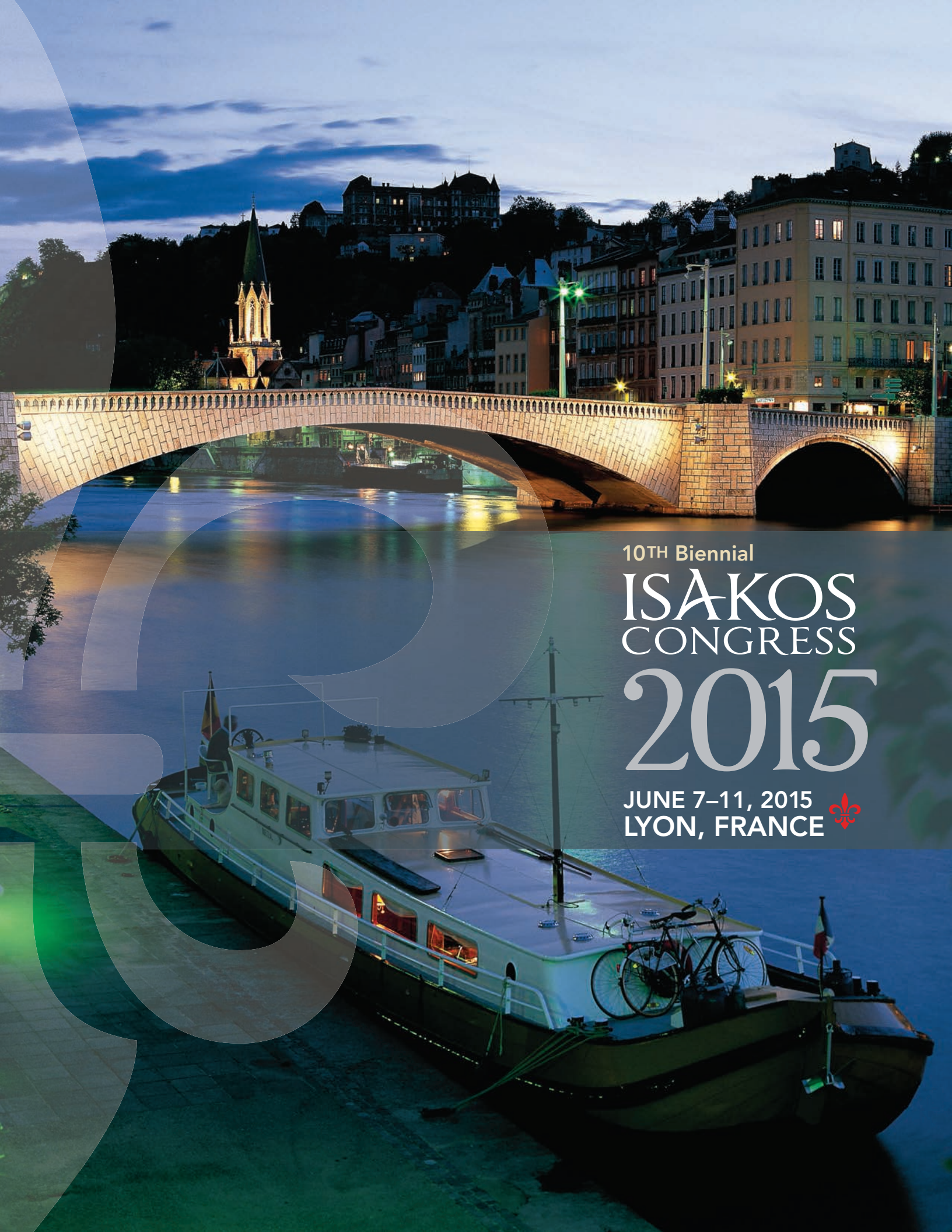Moises Cohen, MD, PhD, BRAZIL, Past President

Financial Planning

ISAKOS is delighted with the progress of the ISAKOS Global Connection Campaign for Education. We have experienced tremendous success thus far.

If you would like to participate in the ISAKOS Global Connection Campaign, please consider becoming an ISAKOS Godfather. A portion of your Godfather pledge will be allocated toward membership for a deserving individual from a developing region in the world for five years. Through your donation, you will be recognized as a Global Connection Campaign supporter, and specifically as an ISAKOS “Godfather”. Benefits to godfathers are distinct, and include special membership recognition including an invitation to a reception at the 2015 ISAKOS Congresses with the member you support, and an ISAKOS Godfather ribbon. If you are interested in becoming a Godfather, please visit www.isakos.com/campaign to learn more.

On behalf of the ISAKOS Executive Committee, we are thrilled with the progress ISAKOS has made as we approach our 20th Anniversary, to be celebrated at the 10th Biennial ISAKOS Congress in Lyon, France. We look forward to many more successes in the years to come.



10TH Biennial

ISAKOS
CONGRESS

2015

JUNE 7-11, 2015

LYON, FRANCE





ISAKOS would like to invite YOU to attend the 10th Biennial ISAKOS Congress!

The 10th Biennial ISAKOS Congress marks the 20th anniversary of the International Society of Arthroscopy, Knee Surgery and Orthopaedic Sports Medicine. The 10th Biennial Congress will be held on June 7–11, 2015 in Lyon, France.

The 10th Biennial ISAKOS Congress promises to be a hallmark celebration of all things ISAKOS—education, fellowship and collaboration!



EDUCATION:

The ISAKOS Congress Program Committee is hard at work, developing an exciting and diverse program for all Congress attendees. No matter what your specialty, you will find educational content available during the ISAKOS Congress. Educational sessions will include instructional course lectures, symposia, debates, special lectures, scientific papers and electronic posters. The diverse and multi-disciplinary faculty will present results from basic science research, as well as new operative techniques highlighting technical pearls and pitfalls.

The ISAKOS Congress will offer additional opportunities to increase your education, with three Pre-Courses and a Concurrent Course. ISAKOS Congress Pre-Courses will be offered on Saturday, June 6, 2015. Pre-Course topics will include Advances in the Knee, Upper Extremity Surgical Innovations, and ISAKOS & FIFA: Treatment of the Football Athlete. ISAKOS will offer the Sports Rehabilitation Concurrent Course for sports rehabilitation specialists on Sunday, June 7 through Tuesday, June 9. For more information on these additional educational opportunities, please see page 8.

FELLOWSHIP:

The ISAKOS Congress is an exciting and diverse event, anticipated to draw more than 4,000 participants from more than 80 countries. The spirit of ISAKOS is one of friendship, and participants are encouraged to attend the various social events offered, including the Welcome Reception on Sunday, June 7.

COLLABORATION:

The ISAKOS Congress offers a unique opportunity to learn from, and interact with a diverse international faculty. The 2013 ISAKOS Congress included more than 750 different presenters from around the world. Drawing the best and the brightest faculty, ISAKOS is pleased to offer our attendees the chance to interact with international experts in didactic sessions. Congress participants are encouraged to ask questions, and our faculty look forward to meeting you!

ISAKOS is pleased to announce that Abstract Submission for the 2015 ISAKOS Congress is now open! Abstracts are currently being accepted on all topics related to the practice of arthroscopy, knee surgery and orthopaedic sports medicine. Presenting authors are invited to visit the ISAKOS website (www.isakos.com/2015Congress) to complete the online abstract submission process. Abstracts will only be accepted through the online submission process—please do not email abstracts directly to the office. Please note—submission of an Abstract is required to apply for some of the ISAKOS Awards. For more information on ISAKOS Awards, please refer to page 6. Abstracts must be submitted by midnight on September 1, 2014.

You are a vital part of the ISAKOS Congress! We encourage you to experience the unparalleled education, and be part of the international community that is the ISAKOS Congress - we look forward to seeing you in Lyon!

Best Regards,

Anastasios Georgoulis
ISAKOS Congress Program Chair 2015

Julian Feller
ISAKOS Congress Program Deputy Chair 2015

ISAKOS Awards

The ISAKOS Fellowship and Awards Program is committed to recognizing and honoring researchers whose work has contributed to better understanding and communication within the fields of Arthroscopy, Knee Surgery and Orthopaedic Sports Medicine.

Applicants, please note: Presenting authors are allowed one submission per award. Additionally, each abstract may only be applied to one of the following awards. To be considered for an Award or Fellowship, abstracts and award applications must be submitted before September 1st, 2014, unless otherwise noted.

John J. Joyce Award

Sponsored by Smith & Nephew, Inc.

In 1981, Dr. John J. Joyce III, offered a monetary prize for the best arthroscopy paper read by an orthopaedic surgery resident during the Scientific Program of the 4th Congress of the International Arthroscopy Association in Rio de Janeiro. With characteristic generosity, he endowed a prize to be awarded at every IAA Congress thereafter. John Joyce created the award with the intention to stimulate and reward younger members who contribute high-quality data and presentations. Thus, orthopaedic residents and fellows, with a study related to arthroscopic treatment are encouraged to apply for this award.

Richard B. Caspari Award

Sponsored by Mitek Sports Medicine

Richard B. Caspari was an innovator, teacher and leader in the field of Arthroscopy. Beginning at the 2003 ISAKOS Congress in Auckland, New Zealand, a monetary prize in honor of Richard B. Caspari was awarded to the best upper extremity paper read at the scientific program of the Congress. The Richard B. Caspari Award was established with the intention of stimulating and rewarding abstracts and presentations in the subject of the upper extremity.

Scientific Research Award

Sponsored by Ossür

The Scientific Research Award began at the 2007 ISAKOS Congress in Florence, Italy. There, a monetary prize was awarded to the best scientific paper read at the scientific program of the Congress. The Scientific Research Award was created with the intention to stimulate and reward abstracts and presentations in the subject of Scientific Research.



- 01 Le Cube Orange par Jakob + Macfarlane
- 02 The Roman-era Theatre on the Fourvière hill
- 03 Lyon Convention Center



02

Albert Trillat Young Investigator's Award

Sponsored by Stryker

In 1989, The International Society of the Knee established a Young Investigator's Research Award in memory of Professor Albert Trillat. Past president and founder of the International Society of the Knee, Professor Albert Trillat was one of the pioneers in knee surgery and sports traumatology. This award provides recognition for a young researcher who has done outstanding clinical laboratory research contributing to the understanding, care or prevention of injuries to the knee.

Achilles Orthopaedic Sports Medicine Research Award

Sponsored by DJO, Inc.

The Achilles Orthopaedic Sports Medicine Research Award was created to recognize the researcher(s) who have performed the most outstanding clinical or laboratory research in the field of sports medicine, such as the care and prevention of injuries.

Patellofemoral Research Excellence Award

Sponsored by The Patellofemoral Foundation, Inc.

The Patellofemoral Research Excellence award was conceived in 2005 by the Board of Directors of the Patellofemoral Foundation and ISAKOS President John Bergfeld to encourage research and expertise in the field of patellofemoral disorders. The Patellofemoral Research Excellence Award was established to encourage outstanding research leading to improved understanding, prevention and treatment of patellofemoral pain or instability.

10TH Biennial

ISAKOS 2015
CONGRESS

JUNE 7-11, 2015  LYON, FRANCE

ISAKOS Fellowships

The Patellofemoral Traveling Fellowship

Sponsored by the Patellofemoral Foundation, Inc. and DJO Inc.

The Patellofemoral Traveling Fellowship was conceived in 2005 by the Board of Directors of the Patellofemoral Foundation and ISAKOS President John Bergfeld. The Patellofemoral Traveling Fellowship is available on a competitive basis to an orthopaedic surgeon interested in the study and advancement of understanding of the patellofemoral joint. The purpose of the fellowship is to promote better understanding and communication around the world regarding patellofemoral pain.

The Upper Extremity Traveling Fellowship

This fellowship was developed by the ISAKOS Upper Extremity Committee to promote better understanding and communication regarding injuries or conditions involving the structures of the Upper Extremity. This Traveling Fellowship is available on a competitive basis to an orthopaedic surgeon interested in the study and advancement of understanding of the Upper Extremity.

New for 2015!

The Masaki Watanabe Arthroscopy Traveling Fellowship

Dr. Masaki Watanabe developed the first device for minimally invasive surgery. In honor of Dr. Watanabe's ideas and accomplishments, the Masaki Watanabe Arthroscopy Traveling Fellowship Award is a new traveling fellowship sponsored by the Arthroscopy Committee of ISAKOS that will provide funding for two young arthroscopic surgeons to learn more about the current practice of arthroscopic surgery from well-respected experts in the field. The knowledge learned by the traveling fellows can then be taken back to their respective countries to improve patient care and advance the local teaching of arthroscopic surgery.



03

ISAKOS Congress Additional Educational Opportunities

ISAKOS Congress Pre-Courses:

ISAKOS Congress Pre-Courses offer the opportunity to start your Congress experience early, on Saturday, June 6, 2015. Pre-Courses are offered for a small additional registration fee. Registration information will be available in September 2014. Advanced Registration is encouraged – 2013 Pre-Courses sold out.

Advances in the Management of Knee Pathology: ACL, Meniscus, Patellofemoral, Osteotomy, and Chondral Pathology

This pre-course will provide a comprehensive update and overview of the latest knowledge and techniques relevant to the management of knee pathology for the orthopaedic surgeon involved in knee orthopaedic sports medicine. The course will be suitable for the subspecialist knee surgeon, and also the general orthopaedic surgeon with an interest in knee surgery, and will cover a diverse collection of topics in order to provide a clinically relevant comprehensive summary of current knowledge and latest trends. The topics covered will include Primary and Revision ACL surgery, Management of Patellofemoral Instability, Meniscal repair and Meniscectomy, Realignment Osteotomy, and Management of Chondral Pathology. The day will consist of a series of expert and evidence-based lectures in the morning on the above topics, and corresponding cadaveric practical demonstrations in the afternoon. In addition to the lectures there will be debates and panel discussions, particularly on controversial topics, and audience participation in the discussions will be encouraged.

International Update on Surgical Controversies of the Shoulder

ISAKOS is pleased to offer a surgical skills oriented pre-course on Shoulder procedures. The goal of the International Update on Surgical Controversies of the Shoulder pre-course is to evaluate the optimal use of diverse techniques for a variety of upper extremity surgical procedures. This one-day pre-course will also help participants to formulate surgical protocols for upper extremity procedures that integrate strategies to avoid potential complications. This pre-course is unique in its presentation of surgical techniques, involving demonstrations, as well as pearls and pitfalls, and discussions for each topic. Featured procedures will include Instability with Arthroscopic and Open Reconstructions, Biceps Tenodesis, Glenohumeral Arthroscopic Arthrolysis, Arthroscopic Subscapularis Repair, Double Row Rotator Cuff Repair, Latissimus Dorsi Harvesting and Shoulder Arthroplasties.

ISAKOS and FIFA: Treatment of Soccer Players

This pre-course is designed for anyone involved in the treatment or management of soccer players. As the most popular sport in the world, there is a unique need for specific information on the treatment of soccer athletes. This course will be co-sponsored with the Fédération Internationale de Football Association (FIFA), to accomplish ISAKOS' mission is to "advance the worldwide exchange and dissemination of education, research and patient care in arthroscopy, knee surgery and orthopaedic sports medicine," as well as FIFA's to "Develop the game, touch the world, build a better future". This course is a great opportunity for athletes, team physicians, athletic trainers and coaches to learn more about the treatment of soccer players!

ISAKOS Congress – Sports Rehabilitation Concurrent Course:

ISAKOS is pleased to offer the third ISAKOS Sports Rehabilitation Concurrent Course to be held during the 2015 ISAKOS Congress in Lyon. The Sports Rehabilitation Concurrent Course will be held on Sunday, June 7 through Tuesday, June 9.

The ISAKOS Sports Rehabilitation Concurrent Course is intended for physicians, athletic trainers, physiotherapists and coaches concerned with the management or prevention of injuries to the athlete. These topics will be viewed through the international perspective of a diverse and multinational faculty of orthopaedic surgeons and physical therapists.

Upon completion of this course, participants will be able to:

- Describe current developments in the management of knee, shoulder and elbow, hip, foot and ankle and muscle injuries in athletes
- Better evaluate and manage sideline or onsite issues in sports medicine
- Describe controversial issues concerning return to play in athletic events
- Understand different modalities and treatment strategies utilized in other nations when dealing with similar injuries
- Improve technical knowledge of the athlete's sports return
- Discuss the use and misuse of performance enhancement substances and techniques

The final agenda for this course is currently under development, but anticipated topics of presentation include Biomechanics of Exercise, Effects of Graft Type and Technique on Post-Operative Rehabilitation, Functional Training and Return to Activity, New Treatments for Muscle Injuries, Treatment Options for Tendinopathy, Electrical Stimulation for Rehabilitation of Muscle Injuries, and Anatomy of Major Joints.



**International Society of
Arthroscopy, Knee Surgery and
Orthopaedic Sports Medicine**



About Lyon

The beautiful and charming city of Lyon can be found half-way between sea and mountain, northern and southern Europe, Lyon in the Rhône-Alpes region is at the foot of two hills and crossed by two rivers. Located less than 300 miles from Paris, the city of Lyon is well regarded as the food and wine capital of France.

The Rhône and Saône rivers converge to the south of the historic city center forming a peninsula or “Presqu’île”. West of the Presqu’île, the original medieval city (Vieux Lyon) was built on the west bank of the Saône river at the foot of the Fourvière hill. This area is recognized as a UNESCO World Heritage Site. To the west of the city of Lyon is Fourvière, known as “the hill that prays”. This is the location for the beautiful basilica of Notre-Dame de Fourvière. To the north is the Croix-Rousse, known as “the hill that works”. This area is traditionally home to many small silk workshops, an industry for which the city was once renowned.

Lyon was historically known as an important area for the production and weaving of silk and the development by Auguste and Louis Lumière of the first motion picture (movie) camera. ISAKOS participants can enjoy the city of Lyon’s great art history at a variety of museums, including the Musée des beaux-arts de Lyon (Fine Arts Museum), a former 17th-century convent housing one of the largest art collections in France. Lovers of contemporary art can visit the Musée d’art Contemporain de Lyon and La Sucrière. History buffs should plan to visit the The Gallo-Roman Museum, displaying many valuable objects and artworks found on the site of Roman Lyon ruins.

Hungry? In modern times, Lyon has developed a reputation as the capital of gastronomy in France. Lyonnaise cuisine is renowned, largely due to the residency of Paul Bocuse and other gastronomes like Colette Sibilia in the more than 1600 restaurants located around the city. The city is famous for its morning snacks, made up of local charcuterie and usually accompanied by Beaujolais red wine. Traditional local dishes include Rosette lyonnaise and saucisson de Lyon (cured sausage); andouillette (a sausage of coarsely cut tripe); pistachio sausage; coq au vin, salade lyonnaise (lettuce with bacon, croûtons and a poached egg); marrons glacés; coussin de Lyon, sabodet and cardoon au gratin. Cerveille de canut is a cheese spread / dip, with a base of fromage blanc, seasoned with chopped herbs, shallots, salt, pepper, olive oil and vinegar. ISAKOS Congress participants can also look forward to visiting two of France’s best known wine-growing regions, which are located nearby – the Beaujolais to the North, and the Côtes du Rhône to the South.

The ISAKOS Congress will be held at the Lyon Convention Centre at the Cité Internationale. Ideally situated in a beautiful setting between the River Rhone and the Parc de la Tête d’Or, the Lyon Convention Centre will serve as a beautiful venue for another successful ISAKOS Congress.

10TH Biennial

ISAKOS 2015
CONGRESS

JUNE 7–11, 2015  LYON, FRANCE

ISAKOS NEWSLETTER 2014: Volume I

Meniscal Allograft Transplantation: The Experts' Opinion



Gonzalo Samitier, MD, PhD
Shoulder fellow at Alps Surgery
Institute–Dr Laurent Lafosse,
Annecy France

Interviews (alphabetic order):



(BC) Dr. Brian Cole, MD, MBA
Professor, Department of Orthopedics, Section
Head, Rush Cartilage Restoration Center, Rush
University Medical Center, Chicago, IL, USA



(RC) Dr. Ramón Cugat, MD, PhD
Co-Director Orthopaedic Department Hospital
Quiron Barcelona Spain,
Mutualidad Futbolistas Catalanes, Associate
Professor UB and UIC



(SIB) Dr. Seong IL Bin, MD
Professor Department of Orthopedic Surgery,
Asan Medical Center, University
of Ulsan College of Medicine, Seoul, Korea

Introduction

Meniscal allograft transplantation (MAT) has become a powerful tool in experienced hands with proven clinical and functional efficacy in relative young and active meniscectomized symptomatic patients; however there are many controversial aspects not clearly elucidated yet.

Indications have narrowed and it is not easy to acquire vast experience with this procedure so we looked for 3 experimented surgeons from 3 different continents and opened up 4 interesting topics about MAT; we led the conversation with more focused questions but they were open to discuss freely the topics or anything related to their extensive knowledge in MAT.

Indications

- Previous meniscectomy
- Femoro-tibial axis aligned
- Stable knee ligaments
- Age lower than 50–55 years
- Pain in the compartment
- Significant contribution to tibiofemoral instability

Relative Contraindications

- Advanced osteoarthritis
- Flattening of the involved condyle or significant osteophytes
- Uncorrected axial malalignment
- Uncorrected ipsilateral localized high grade chondral or osteochondral defects
- Instability of the knee joint
- Inflammatory arthritis or synovial disease
- Infection
- Skeletal immaturity
- Obesity (BMI >35)

Meniscal Transplant Q&A

1. MAT & COMPETITIVE ATHLETES

Would you indicate MAT in professional athletes?

BC: Only if they have pain that limits their ability to play at the level they wish to play; I wouldn't recommend it if they have a meniscectomized knee and pain but they can play at the level they want and I would never recommend for prophylactic purposes, because as soon as you put one in, there is yet another structure that you have to worry about that the athlete can tear in the course of their activities. Arguments against prophylactic MAT include the potential complications of the procedure itself and the limited data that suggests the MAT is chondroprotective. Athletes are more likely to tear the meniscal allograft than their own native tissue.

We have a series of high level athletes who could not play their sport because of their meniscectomized state and who did not have an extra-articular option (i.e., osteotomy), who we performed MAT and about 20% of them reinjured their transplant. However, despite this, after arthroscopic re-repair or partial meniscectomy, the entire group was able to attain their goal of achieving sufficient pain relief and stability allowing return to sport at an acceptable level of performance.

In fact, the most common reason for failure was the inability to achieve a degree of pain relief that allowed them to play at their desired level.

RC: Yes, but only if there is no other therapeutic option available

SIB: I do not strongly recommend MAT in competitive athletes. I would think about that in non-contact or non-pivoting sports and recreational athletes.

Is there any sport that you wouldn't?

BC: These patients are generally informed adults and they have to knowingly assume the risks inherent in resuming activities following a MAT. It is our responsibility, however, to thoroughly educate the patient about the risks to their MAT should they make the decision to return to high-risk activities. In general, they are no worse off should their graft fail, but for some and understandably so, they are simply happy to have reduced symptoms with lower level activities and do not wish to assume the added risk for graft failure. For some, however, such as scholarship or professional athletes, it may indeed be worthwhile to assume this risk. The typical remedy in the setting of failure is arthroscopy, re-fixation or partial meniscectomy. Our experience has been that following secondary procedures, up to 75% of the patients are restored to their post-MAT baseline.

RC: I have done in professional soccer players and soccer is very demanding for the knee, involving contact and pivoting, so, when no other option available, potentially I would consider in any sport.

SIB: Specially for pivoting and/or contact sports

Did you in the past and what sport/s?

BC: Our athlete experience includes professional baseball, Olympic wrestling and Division 1 sports in soccer and basketball.

RC: Yes I did, in professional soccer players but not 1st division. I remember also a competitive Skier; we performed on her high tibial osteotomy + ACL + MM Transplant at the end of her sports career

SIB: I have done in the past for recreational athletes; runners, bikers, etc. Also remember a few patients who confessed me after surgery that they were playing recreative soccer.

Did they return to competitive level?

BC: Many of have returned to competitive play at their pre-injury level. In the instances where this has not occurred, it is typically that the desired level of pain relief was simply not achieved.

RC: Yes they did, all of them. I remember also a 2nd division player and other in regional category. What I found is that, often in surgery, is better to deal with competitive athletes instead recreational ones as they have in general a more favorable environment for healing: better physical condition, good physical trainers aside, better facilities to train and play, etc.

SIB: Yes they did, but as I said, they were recreational or social athletes

What is the time range for returning to competition?

BC: We generally allow return to sports following MAT at 6 months, but when a concomitant procedure such as osteochondral allograft transplantation has been performed, we wait until 8 months post-operatively.

RC: 9 months. Some of them came back at 6 months

SIB: 9–10 months and when they get 90% of quadriceps strength

Did competitive sports affect the long term result on their transplants comparing with low demand transplanted patients?

BC: I don't have the sense they deteriorate their meniscus overtime because most of them are not doing this for ever. Professional athletes can have 3–5 additional years given their age in their sport and college athletes even less (e.g., 1 to 2 years). The biggest challenge is, in meniscectomized knee patients, how do we educate them about the risks of returning to sport when they are in fact asymptomatic. Further study is needed to learn more about disease progression in the meniscectomized knees and how it correlates with activity level.

RC: Definitely, even there is not comparative research studies, it is common sense to expect the more use, the more wear overtime in those knees, besides the potential increased injury rate associated to hours of exposure.

SIB: In the long term I observed some differences and we are currently evaluating and studying those differences

Arguments against prophylactic MAT include the **potential complications** of the procedure itself and the limited data that suggests the **MAT is chondroprotective.**

**Meniscal Allograft Transplantation:
The Experts' Opinion**

Meniscal Transplant Q&A

2. SURGICAL TECHNIQUE

Fresh frozen meniscus?

BC: Yes, always. Occasionally, we will use a meniscus that is preserved and subsequently sterilized using they BioCleanse process.

RC: Yes, 100%

SIB: Yes, 100%

Regarding horns fixation what is your preference for MM and LM? How do you fix the different parts of the meniscus (ant-body-post)?

BC: I use the bridge-in-slot technique for both medial and lateral MAT for the last 7 years. If I can't do a bridge due to tunnel conflict in the setting of ACL reconstruction, I use a blind tunnel with a Flip Cutter (Arthrex, Inc., Naples, FL) for the posterior horn, anterograde drilling for anterior horn and transosseous fixation for both horns.

Fixation of the bone bridge is with a biocomposite screw pushing the graft over to the ipsilateral side. My sutures are almost always inside out vertical mattress on top and bottom using #2 Fiberwire (Arthrex, Inc., Naples, FL) with small skin incision down to the capsule and a standard open meniscal repair approach.

About 30% of the time I use a single all-inside device for posterior most aspect of the repair.

RC: Soft tissue fixation: intratunnel horns fixation for MM and LM tying down sutures at the exit point in proximal tibia

SIB: MM Bone plugs (8x6 mm posterior horn and 10x10 mm anterior horn). Press-fit fixation + suture tying at the tunnel's tibial exit

LM Keyhole pressfit technique; never needed extra fixation with interference screw so far. I fix the meniscus to capsule using 10–12 non-absorbable 2–0 vertical sutures inside-out arthroscopic technique, 3–5 mm apart. I do not use any additional suture fixation device.

Open, miniopen or arthroscopically?

BC: I use an arthroscopically-assisted approach with a small trans-patellar tendon arthrotomy (i.e., 3 cm) and standard medial or lateral meniscal repair incisions.

RC: Posterior part of the meniscus with all-inside meniscal repair device. Body and anterior aspect with previously placed vertical meniscal sutures; we retrieve them from outside using a piercing suture retriever; sutures are tied extracapsular.

This is a full Arthroscopic technique

SIB: Miniopen, a 3 cm vertical incision in the front to pass the allograft and improve visualization during the meniscal allograft positioning

Do you avoid extrusion somehow?

BC: We don't fully understand why extrusion occurs; it can happen immediately or late.

I think most commonly it occurs early when there is squaring of the femoral condyle or flattening of the tibial plateau, for improperly sized menisci and in individuals with loose skin and associated loose capsule not really attached at the junction of the tibia in the periphery; it sort of falls away from the joint and just pull the meniscus with it. It is possible that extrusion can occur overtime with degeneration, but I really believe it most commonly happens early. In some cases this is more of an MRI finding without clinical relevance, but certainly we would love to prevent it from occurring.

I think the techniques designed to further constrain the meniscus are interesting and something to consider, however, I worry that anchoring it further to the tibia with additional transosseous fixation points may overly constraint the meniscus to the point where an additional failure point will occur.

RC: We see more extrusion in the soccer scene as they usually has a marked varus and external tibial rotation. From my point of view the keys are, leaving 1–2 mm of residual meniscal wall and perpendicular suture placement that we use to get an optimal capsular fixation.

SIB: Actually we don't know much about what cause extrusion; we observed that extrusion is often a preexisting condition and we are currently studying this phenomenon

What we know is:

- Too large grafts (widthwise) may favor extrusion
- Horns anatomic placement and secure fixation is very important
- A little trick is fixing the meniscus in this order, posterior, anterior and finally the mid part of the meniscus

Shrinkage?

BC: It is becoming less common. A lot of my second looks have no shrinkage and I don't know how much of an issue it is and I don't know if we can do much about it except following good laboratory practices for preservation.

Do you think there is associated morbidity to bone blocks or plugs comparing to soft tissue fixation?

BC: Certainly there is a risk of inadvertent articular cartilage damage occurring from the instrumentation used to prepare the slot. In addition, it can be challenging to place the biocomposite screw adjacent to the meniscal bone bridge within the slot.

RC: To me, soft tissue fixation allows a fully arthroscopic procedure which is my preference as I am concerned about the morbidity associated to open techniques and potential risks on cartilage and/or bone when using bone fixation techniques.

SIB: Additional operation time and surgical difficulty

Do you utilize alternative horn fixation techniques?

BC: If the meniscus should become detached from the bony insertion, I will fix it trans-osseously into a tunnel. While I prefer the initial stability afforded by the meniscal bone bridge, it occasionally is necessary to use soft tissue fixation into the tunnel. Ultimately, as long as the tissue grows into the tunnel, I do not believe the outcomes will be compromised.

RC: No never. I learned the meniscal transplant technique with bone plugs from Freddy Fu and Chris Harner in Pittsburgh and from there I decided to develop my own technique. Between 2000 and 2001 we spent many sessions in the cadaver to make work out our current all arthroscopic MAT surgical technique.

SIB: No, my cases are 100% bone fixation technique

Do you think horns fixation type does affect the clinical result in the long term?

BC: I don't know. I am not sure that the outcomes are that technique-sensitive as long as the anatomy is restored and good meniscal repair techniques are deployed.

SIB: I think so and I expect so; Bone fixation technique is more difficult and more time consuming, but that is my preference because I get more stable fixation, possibly decrease chance for extrusion and secondarily I think you can get better results in the long term

3. LONG TERM RESULTS**When was your first MAT?**

BC: 1997

RC: 2001, March

SIB: 1996, December

Is it a frequent procedure in your practice?

BC: We do about 40 to 50 a year now. It has become more frequent because we are a referral center and not because the problem itself is more common. The technique is a lot easier to do now, but there is clearly a learning curve so the tendency is to have a cluster of centers doing it. The most common transplant that we perform today is a concomitant MAT and osteochondral allograft to the femur.

RC: We perform around 15 to 20 yearly; indications are scarce and we only proceed to surgery in symptomatic meniscectomized knees.

Our results are better in young soccer players than normal population on the same age group, possibly due to the higher healing potential in those individuals.

SIB: Yes, and it is becoming more and more frequent; during the last 2–3 years I am doing 50 cases per year as a reference surgeon in Korea for this specific surgical technique.

Besides in Korea we have a 15% incidence of discoid meniscus, many of these patients needed extensive meniscectomy in the past and for this reason nowadays 70–80% of my transplants are LM

often in surgery, it is better to deal with **competitive athletes** instead of recreational ones as they have, in general, a more favorable **environment for healing**

**Meniscal Allograft Transplantation:
The Experts' Opinion
Meniscal Transplant Q&A**

Did you observe deterioration of the meniscus and/or clinical results over the years?

BC: After 5 to 7 years there is a tendency to deteriorate, however, it does not always relate to tissue-specific deterioration. While MRI surveillance is interesting, I do not believe it necessarily correlates with clinical outcomes or with the risk for clinical failure. Workers compensation patients still have the most challenging outcomes in terms of their willingness to report subjective improvement.

RC: Yes but just in some of them, interestingly, some others show no changes over the years.

SIB: I didn't analyze the results in the long term yet; In some patients I observed degenerative changes but, despite this, transplanted patients have less pain than preoperatively and do better than the non transplanted ones.

What options do you offer for those who fail over the years?

BC: It depends upon how and when they fail. We have a growing series of patients who undergo simple revision MAT. There is another group who develops concomitant femoral condyle or tibial articular cartilage disease that can be managed accordingly with revision surgery. The most challenging is the group of patients that simply have progressive bipolar disease that cannot be managed by anything other than arthroplasty.

RC: Revision of Meniscal transplant; we did it in 3 cases, all of them posttraumatic tears.

SIB: In case of good articular cartilage, I would offer 2nd meniscus transplantation.

4. INNOVATIONS TO COME IN MAT

Would you change anything regarding the current indications/Contraindications?

BC: Patients who are more advanced chronologically (i.e., > 45 years old) often have less predictably good outcomes. I think this is due to the fact that despite the fact that their articular surfaces look grossly intact, they often have chondropenia that compromises their ability to achieve higher degrees of pain relief. Thus, most of our patients are between 18–25 years of age. The most challenging are females who are otherwise active and undergo a functional lateral meniscectomy with subsequent rapid deterioration of their lateral compartment. Concomitant articular cartilage disease can often be restored. We have a very large population, more than 150 patients, who have undergone combined meniscal and osteochondral allograft transplantation. While intuitively it makes sense to consider prophylactic transplantation, especially on the lateral side, I am still unwilling to do this in the asymptomatic patient given the absence of convincing data that confirms articular cartilage protection and because not all patients will become symptomatic despite missing their meniscus.

RC: I am mostly agree with current indications. About the contraindications I have to say that our 1st meniscal transplant was a female patient with RA; Patient is 12 years out, I saw her past Dec, ordered a MRI and it showed a meniscus allograft clearly identifiable and patient is asymptomatic ever since. I wouldn't do it now but I think this case is interesting to remember.

SIB: I mostly agree with current indications; just want to add that cartilage defects, if this is not diffuse, is not an absolute contraindication for me; as literature shows even full defects mainly when smaller <1–1.5 cm and localized can be repaired or restored; microfracture for small, and OATS for larger defects are my preference.

Scaffolds can be promising,
but we need to see
long term results

Are we close to get reliable meniscal scaffolds/ xenografts/tissue engineered meniscus?

BC: Conceptually, I still have difficulty accepting the model where portions of a synthetic meniscus are used as a “prosthesis” for partial meniscal reconstruction. As an acute intervention, it challenges current clinical thinking where most meniscectomy patients at index meniscectomy do well for decades, if not forever. In addition, I think that when necessary and appropriately indicated, a meniscus allograft will always have better biomechanical properties than even the best synthetic graft. That being said, I will maintain an open mind about this possibility in the future. The regulatory burden in the US is going to be extraordinarily difficult for any synthetic device to make it to the clinic in the near term.

RC: The current scaffolds don't satisfy my expectations so I do not use them.

The best combination to me in the future would be a collagen-proteoglycans compatible scaffold combined with stem cells and growth factors in a physiologic amount.

SIB: I do not have experience on those. For me, in total defects, MAT is the only option, for partial meniscal defects there is a need for scaffolds but the current ones in Europe are not available in Korea yet. Scaffolds can be promising, but we need to see long term results.

Do you use any biological enhancer for healing?

BC: Occasionally I use PRP, I soak the graft and inject it intraarticularly at the end of the procedure. I am not sure if it makes any difference.

RC: I use PRGF injected intraarticular at the end of the surgery

SIB: No. Seeing my healing rate over 95% I don't think I need additional biologics. Regarding healing potential, the most important to me is to have a good blood supply from the capsule and bone. Sometimes I pierce the capsule and do multiple puncturing around the capsule to promote blood supply.

Something you want to add:

BC: I think we are in a good place with MAT and believe we can predictably make a difference in the lives of appropriately indicated patients. I have narrowed my indications and my patients, when they do well, are extraordinarily happy; quality life improvement is comparable to the reverse shoulder arthroplasty in Rotator cuff Arthropathy, but that is because we are generally treating very symptomatic patients. I don't know if this is because of the allograft or the cartilage repair but I think ignoring one or the other is not a good idea, you always have to respect the concomitant comorbidities. I have very low threshold for osteotomy for example.

SIB: MAT is a very important procedure for the patient; we need prospective long term studies focusing not only in clinical results but also in objective results from MRI or second look arthroscopy; only this way we can be more objective and accurate in our answers.

Surgical Technique In Detail

BC: Alford W, Cole BJ. The indications and technique for meniscal transplant. *Orthop Clin North Am.* 2005 Oct;36(4):469-84.

Saltzman BM, Bajaj S, Salata M, Daley EL, Strauss E, Verma N, Cole BJ.

Prospective long-term evaluation of meniscal allograft transplantation procedure: a minimum of 7-year follow-up. *J Knee Surg.* 2012 May; 25(2):165-75.

RC: E Alentorn-Geli, R Seijas-Vázquez, M García Balletbó, P Alvarez-Díaz, G Steinbacher, X Cuscó Segarra, M Rius Vilarrubia & R Cugat Bertomeu. Arthroscopic meniscal allograft transplantation without bone plugs. *Knee Surg Sports Traumatol Arthrosc.* 2010 Apr 14.

SIB: Kim JM, Lee BS, Kim KH, Kim KA, Bin SI. Results of meniscus allograft transplantation using bone fixation: 110 cases with objective evaluation. *Am J Sports Med.* 2012 May; 40(5):1027-34.

High Tibial Osteotomy or Unicompartmental Knee Replacement?



Dr. David A. Parker FRACS

Additional Author:

Dr. Gavin J. Macpherson FRCS

The successful management of young patients with symptomatic medial compartment osteoarthritis of the knee is a challenge faced by orthopaedic surgeons worldwide. In this patient population, as distinct from the more common older patients with arthritis, there is a higher expectation and need for returning to work and maintaining a high level of recreational activity, whilst also achieving a sustained reduction of knee pain.

Joint registry data confirm that the use of total knee replacements (TKR) in this young and active patient population should be a last resort due to the increased rates of early failure and need for revision¹. Uni-compartmental knee replacement (UKR) and high tibial osteotomy (HTO) are two alternative surgical approaches. Each technique has specific indications and contraindications which will often guide the surgeon towards the most appropriate procedure. There remains a small group of patients in which either procedure is suitable.

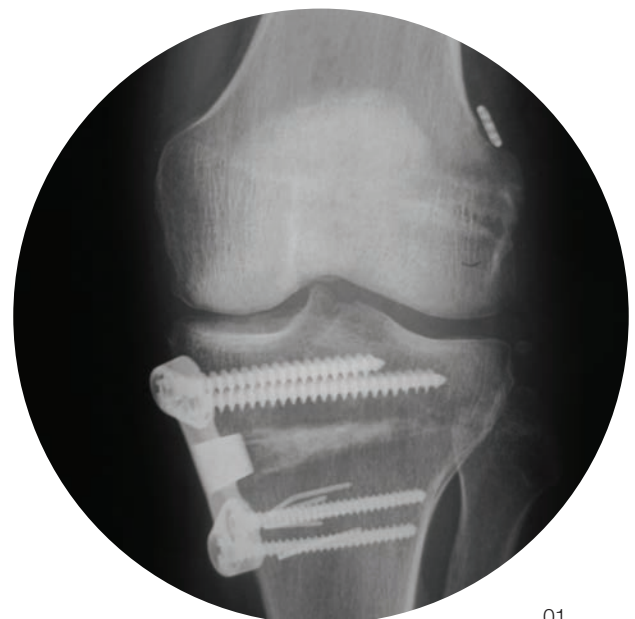It is very difficult to make direct comparisons of HTO results to those of UKR with the available literature. There are no studies in which a true randomised comparison has been done and the patient populations are often very different for the two procedures. In particular, HTO is almost exclusively performed on younger, more active patients, whereas UKR, although sometimes done in younger patients, is on average done on an older group than HTO.

In this article we will discuss the relative merits of HTO and UKR, including reviewing the current available evidence for each procedure, in order to attempt to give some useful guidelines for surgeons in their management of this often difficult group of patients. For the purpose of this article we will focus on HTO for medial compartment arthritis, but the same principles apply to other realignment osteotomies around the knee joint.

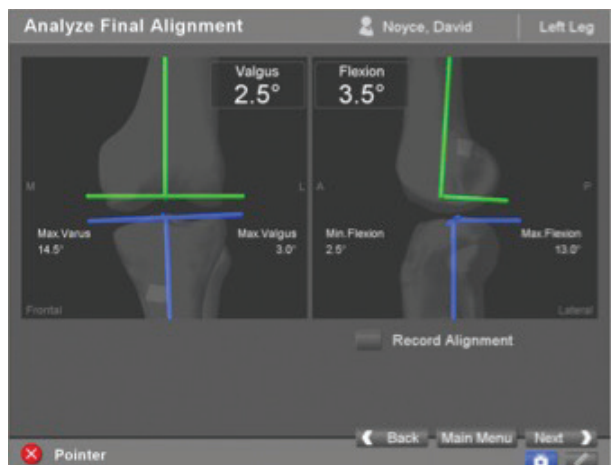High Tibial Osteotomy (HTO)

HTO is a well established procedure for the management of arthritis, and in some developing countries, in which arthroplasty is unavailable, may remain the main surgical technique. In developed countries it is generally indicated in young and active patients who wish to maintain an active lifestyle post operatively, and who have varus malalignment of their lower limb mechanical axis with isolated medial compartment degenerative disease. The aim of the procedure is to realign the mechanical weight bearing axis of the lower limb such that the weight is more evenly distributed across the knee, thus offloading the arthritic medial compartment. The clinical goal is to relieve pain and improve function, as well as slowing the progression of the arthritis, hopefully delaying the need for joint replacement surgery, and preserving the patient's native knee joint. Several studies have indeed shown recovery of joint surface in the diseased compartment, demonstrating the ability to alter the natural history of arthritis.

Although earlier studies showed relatively poor long-term survival, more recent studies with contemporary techniques and appropriate patient selection have shown excellent outcomes and survivorship in younger patients. Patient selection is critical, and best results seem to be in younger patients who are not overweight, with well localised arthritis and flexible joints. Clinical outcomes are often excellent at short and medium term follow up but may deteriorate over time. Survivorship data varies but more recent studies have shown over 90% survival at 10 years, whereas some older data suggest up to 25–30% will have been converted to a TKR at 15 years. Clearly longer term follow up with newer techniques is necessary to see whether or not this can be improved.



01



02

Interest in HTO has increased in recent years, and the surgical technique continues to evolve and improve. The introduction of computer navigation has improved the accuracy of the realignment intraoperatively and this will hopefully be reflected in improved clinical outcomes and long term survivorship. Additional research is required to determine the ideal correction for each scenario, and the literature has varying recommendations. The author's preference is to aim for 2.5° to 3° mechanical valgus via computer navigation. Improved fixation is allowing earlier weight bearing and range of motion. Previously, instability was considered a contraindication to HTO, but more recently this has actually become an indication with greater understanding of the relationship of tibial slope change to cruciate ligament function. Combining HTO with additional procedures such as ligament reconstruction or chondral resurfacing has also expanded the indications of this procedure. The long term outcomes of these combined procedures are promising and are an area of interest for the future.

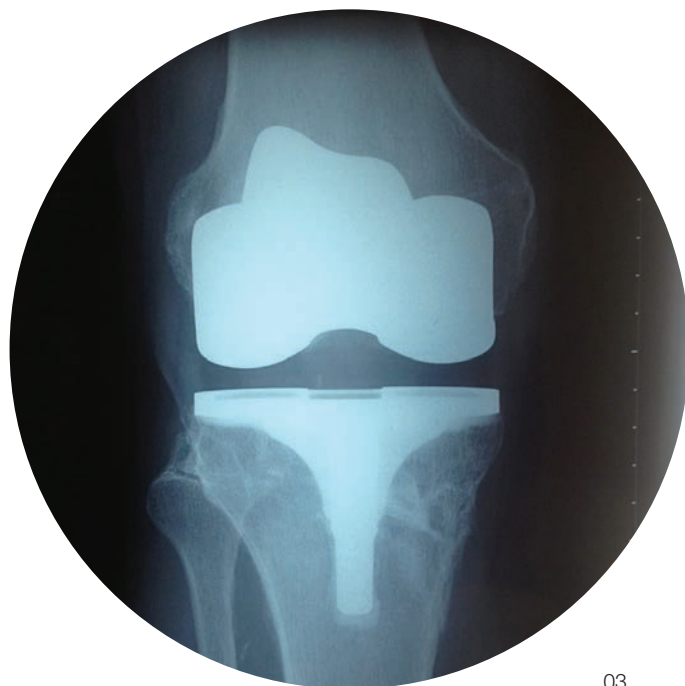
For medial compartment degeneration a valgus osteotomy of the proximal tibial metaphysis can be achieved by either a medially based opening wedge (OWHTO) or laterally based closing wedge osteotomy (CWHTO). Much of the published literature on HTO relates to CWHTO but the advent of modern plating techniques has led to a rise in the popularity of OWHTO. A 2011 meta-analysis of high tibial osteotomies comparing opening and closing wedges concluded that there was no difference in clinical outcomes for function, pain or complications between the two techniques. The increasing use of OWHTO has decreased the concern relating to conversion of HTO to TKR. A 2013 meta-analysis comparing primary TKR with TKR post-HTO concluded that an HTO prior to TKR does not negatively influence the outcome of the joint replacement.

Uni-Compartmental Replacement (UKR)

UKR for varus osteoarthritis is a partial joint replacement which preserves the lateral and patella-femoral compartments. Although the use of UKR increased markedly in the late 1990's, this has been declining in Australia and other countries in recent years, influenced heavily by poorer than expected clinical outcomes and a higher than expected revision rate in medium term follow up.

The popularity of UKR was based largely on the proposed advantages of it being less invasive than TKR with reduced recovery time, length of hospital stay and potential for complications. Preservation of the lateral and patellofemoral compartments, and cruciate ligaments, was felt to provide improved function, range of motion, and proprioception, and also allow for easier revision when compared to TKR.

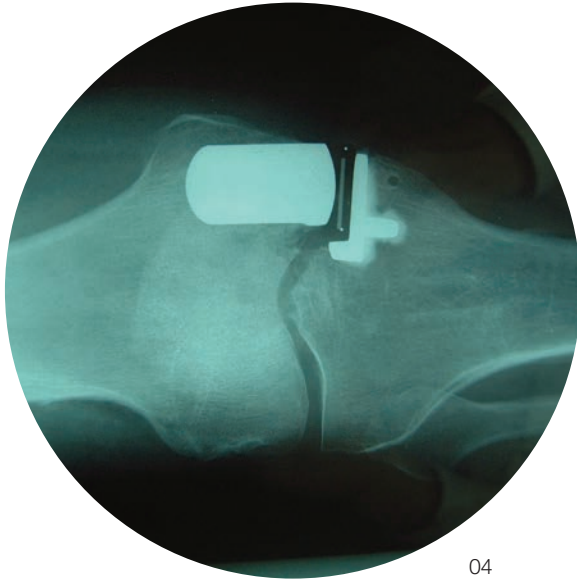
Whilst there have been several studies focusing on specific implants reporting good results and excellent survival, registry data has been less impressive. The Australian joint registry reported a cumulative percentage UKR revision of 18% at 12 years with loosening or lysis being the most common cause of failure. When subdivided by age and gender the revision rate is seen to be highest in the younger patients for whom this procedure is often recommended. Surgeons must therefore be mindful of the need for revision to TKR and the outcomes associated with this procedure. New Zealand joint registry data has reported that the outcome of a TKR converted from a failed UKR is inferior to a revision of a TKR undertaken for pain, whereas conversion of an HTO to a TKR has equivalent results to a primary TKR.



03

- 01 Medial Opening Wedge HTO
- 02 Computer Navigation Alignment Assessment
- 03 TKR Post Medial Opening Wedge HTO

High Tibial Osteotomy or Unicompartmental Knee Replacement?



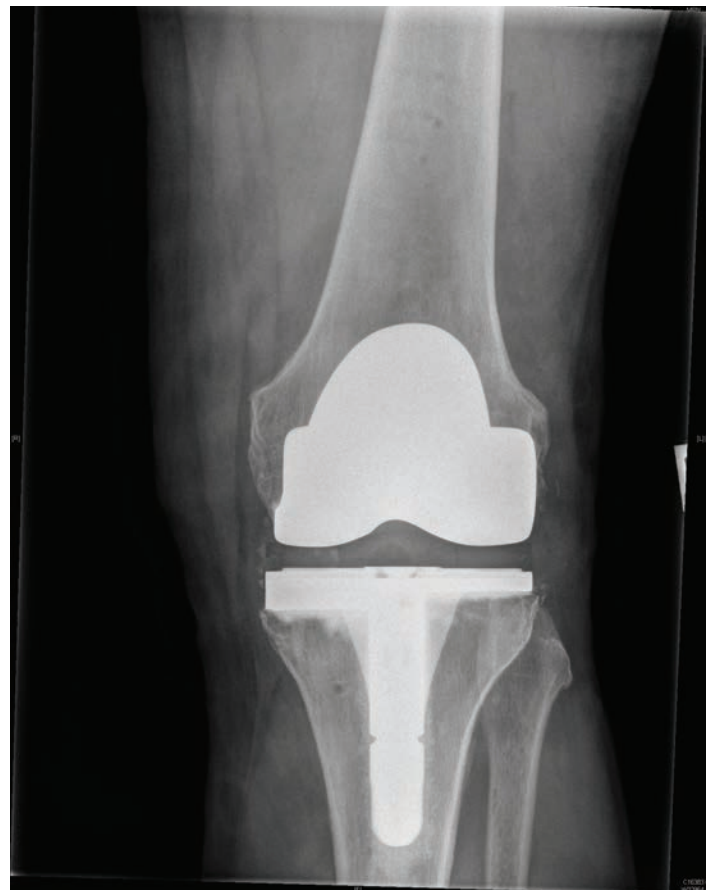Many UKR clinical studies have demonstrated that with appropriate patient selection and good surgical technique good outcomes and survivorship can be achieved. Computer navigation can also improve the accuracy of the procedure in obtaining appropriate alignment and balancing intraoperatively, and thereby hopefully improve outcomes. Certainly, for those appropriately selected patients who obtain a good outcome, this can be sustained over the longer term, with excellent function and pain relief. However, the higher revision rates seen on many national registries mean that a significant number of patients will come to early revision, with possible unsatisfactory outcomes. When these earlier failures are examined, it would seem that improved patient selection and surgical technique could minimise these problems and improve the overall outcome of UKR. Although no equivalent registry exists for HTO, when survival for HTO from contemporary studies is compared to registry results for UKR survival in a comparable age group, HTO survival is slightly higher. In addition, with HTO revision to TKR often more straightforward and achieving better results than revision of UKR to TKR, HTO would seem a better choice in young active patients with medial compartment OA. In middle-aged patients with bilateral pathology requiring surgery, the need to restrict weight bearing postoperatively in HTO may make simultaneous bilateral UKR a more convenient option for the patient rather than 2 staged HTO procedures, and this also need to be considered in the decision making process.

04 Medial UKR
05 TKR Post UKR

Conclusion

Following an examination of the current literature our procedure of choice for isolated medial compartment arthritis in young patients, particularly those with aspirations of a return to recreational activities is HTO, with the author's current preference being for a medially based opening-wedge high tibial osteotomy using a locking plate and femoral head allograft. This would certainly seem to be the preferred option for patients less than 50 years of age. For those patients between 50 and 65 the treating surgeon should consider the relative merits of each procedure and decide on the best option for each individual after appropriate discussions with the patient.

The recent resurgence in interest in HTO has corresponded to ongoing improvements in surgical technique, as well as a better understanding of patient selection and appropriate degree of correction. This in turn has led to improved outcomes, and the recent reports of improved survivorship and clinical outcomes, as well as the avoidance of compromise to future TKRw should make HTO an ongoing main option in the management of symptomatic unicompartmental OA in the younger patient. Future longer term studies, and possibly the establishment of an osteotomy registry will further define the place of this procedure in our management algorithm.



05

Scaphoid Fractures in Athletes



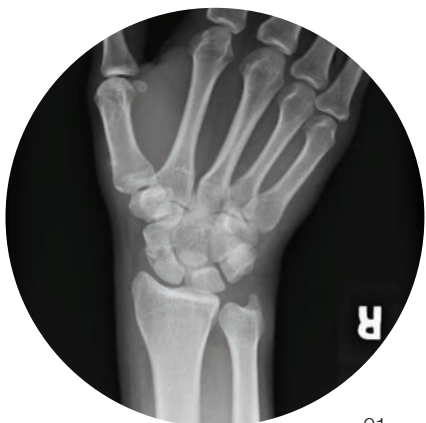Michael R. Redler, MD

Additional Author:
Ashley Batchelder, MS, LAT

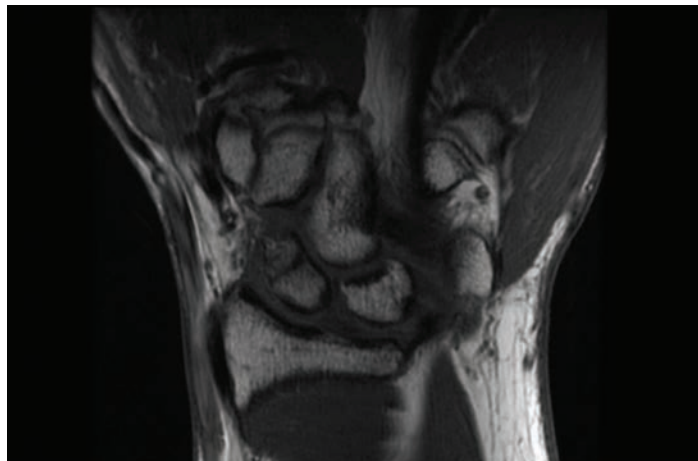
Fractures of the scaphoid are perhaps the most common of all carpal bone fractures. Scaphoid fractures are often seen in adolescents and young adults with the incidence being much higher in men than in women. Despite this prevalence, diagnosis can often be a challenge and a high index of suspicion is therefore imperative for the health-care professional treating athletes with wrist pain.

Fractures of the scaphoid most commonly occur after a blunt fall onto a dorsiflexed wrist. Many of these injuries seem to occur with the arm in an outstretched position to protect the athlete from a fall; however, as is true in treatment of athletes in the heat of competition, exact mechanism cannot always be determined. Athletes, especially in collision sports, who injure their wrists during the course of the game often will “shake it off” and do not always seek medical care. This, of course, creates a situation whereby scaphoid fractures may often go undiagnosed for an indeterminate period of time.

Delay in diagnosis for many athletic injuries can be problematic; for a scaphoid fracture this is even truer given its propensity for poor or delayed healing. As the most commonly injured of all carpal bones, the scaphoid spans the proximal to the distal row of carpal bones. It functions to give support and stability to the wrist by providing a linkage between the two rows. The blood supply of the scaphoid enters the distal pole of the scaphoid and therefore, the overall blood supply of the more proximal portion of the scaphoid is somewhat more precarious in nature. Given the precarious nature of the blood supply, fractures of the scaphoid that go undiagnosed can often go on to non-union.



01



02

To help minimize the incidence of a non-union, the sports medicine professional needs to have a high index of suspicion regarding a potential scaphoid fracture when examining any athlete with wrist pain after a sports injury. The most common finding for a scaphoid fracture is point tenderness over the anatomic snuff box along the more dorsal radial aspect of the wrist. Tenderness over the bony prominence of the more palmar aspect of the wrist over the area of the scaphoid tubercle, and pain with extremes of motion, especially dorsiflexion are also commonly seen. Other positive findings can include pain with resisted pronation, pain with an attempted scaphoid shift test and pain with axially loading of the thumb towards the area of the scaphoid. Swelling may or may not be present; instead, positive findings can include limited motion and weakness.

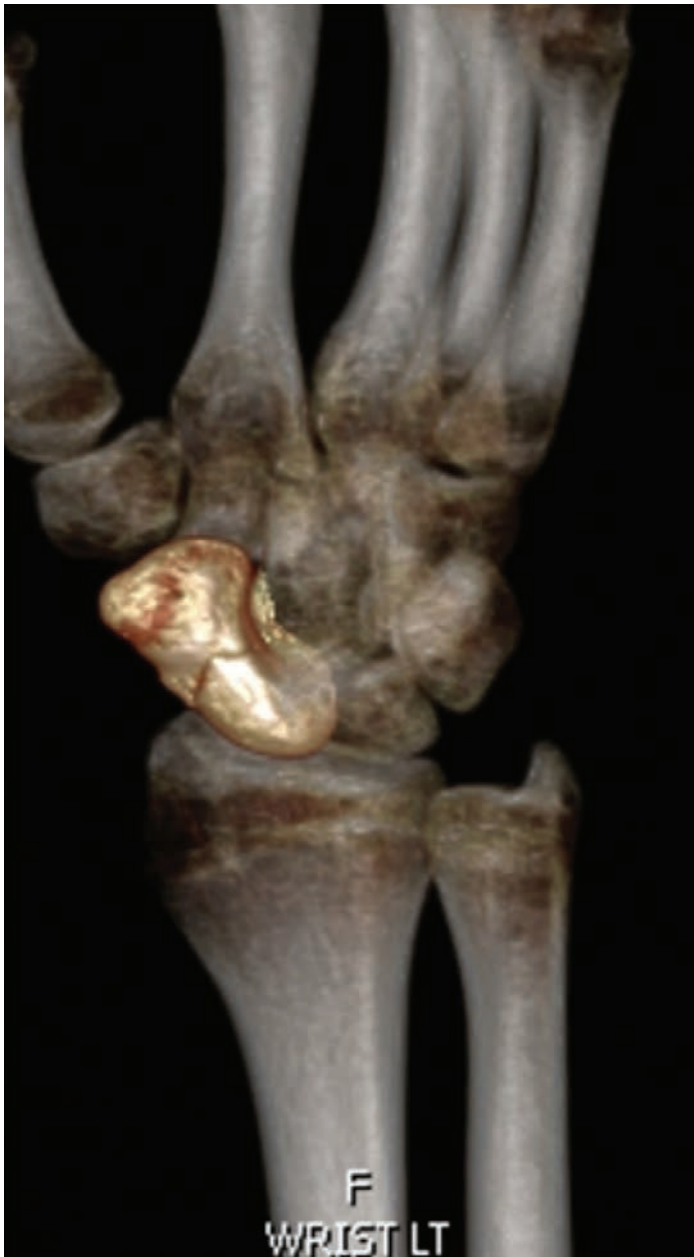Standard radiographs, including AP, lateral, and “scaphoid” view x-rays can often make the diagnosis of a scaphoid fracture. (Figure 1.) However, as has been well delineated in the literature, initial radiographs may not demonstrate a scaphoid fracture.

Past teachings were to splint or cast the patient and perform new-x-rays two weeks from injury, however with the advent of additional radiographic studies, this is probably not the most efficient means of confirming diagnosis. An MRI will show a scaphoid fracture well even when the plain x-rays are normal. (Figure 2.) Having a dedicated wrist coil for the MRI can certainly increase the incidence of accuracy. The literature also speaks about a bone scan to demonstrate an active fracture and/or a CT scan if there is a concern regarding displacement. (Figure 3.)

01 Scaphoid View X-Ray demonstrating displaced scaphoid fracture

02 MRI demonstrating non-displaced fracture of the waist of scaphoid

Scaphoid Fractures in Athletes

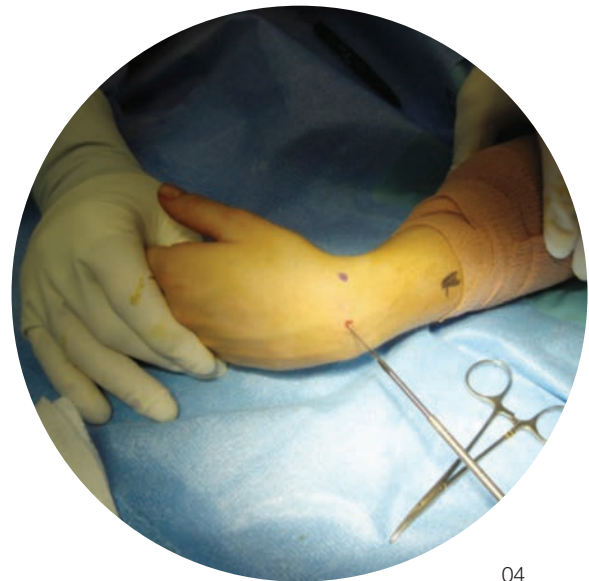

03

Once the diagnosis of a scaphoid fracture has been confirmed, treatment options must then be discussed with the athlete. Traditionally a non-displaced, waist-level fracture of the scaphoid can be treated with either a long-arm thumb spica cast, or in some series, a short-arm thumb cast. In some series, a long-arm thumb spica cast which will prevent rotation may have a slightly higher incidence of healing, but there are certainly studies that will support either method of casting. Again, given the precarious nature of the blood supply, scaphoid fractures can take a 6–12 week period to heal with casting.

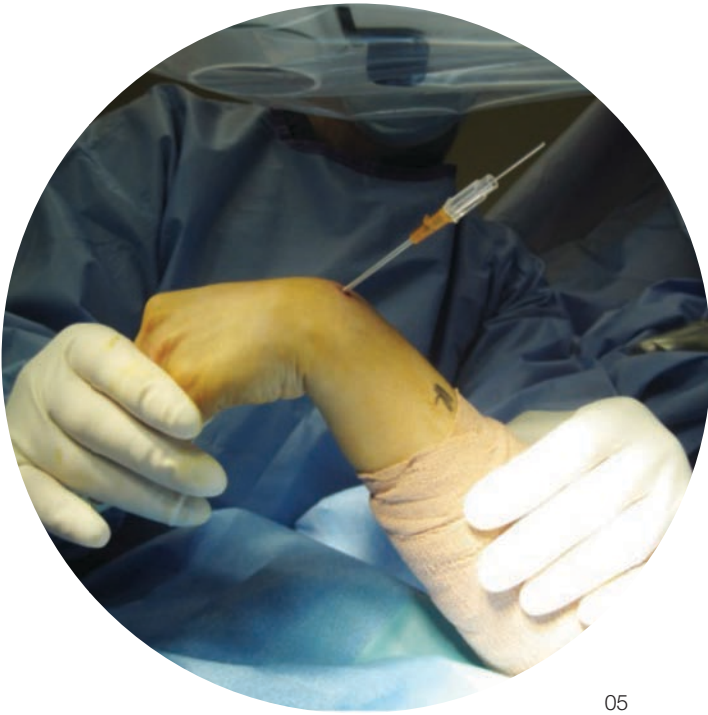Displaced scaphoid fractures require surgical intervention. It is clear that a displaced scaphoid fracture, unless proper alignment has been achieved, will have a lower incidence of healing. Surgical options in the past have included open reduction internal fixation with a Russe bone graft and placement of K-wires or a headless compression screw. There are several manufacturers that make a headless compression screw and in most centers, this is now the preferred method for internal fixation. (Figure 4.)

Many scaphoid fractures can now be treated with a percutaneous technique whereby a headless screw can be placed over a K-wire under fluoroscopic control. (Figure 5.) The advantages of this technique are clear in terms of the decreased morbidity of dissection and the minimally invasive technique. Technically this method of fixation can be more challenging and should be performed by surgeons with a higher volume of scaphoid-fracture treatment within their practice. For some patients who cannot tolerate the long period of casting or need to get back to work or sports in a more rapid fashion, even non-displaced scaphoid fractures are being treated with this percutaneous technique (Figure 6.). The immobilization period is much shorter and return to activity more rapid. Obviously the athlete must carefully consider the ramifications and risks of a non-operative versus operative approach.



04

If the athlete presents with a non-union scaphoid fracture, this will require not only internal fixation but also bone grafting. Classically bone graft can be taken from the distal radius. In cases where there is a larger area of bone loss, iliac bone graft can also be used. In some centers, significant non-unions are treated with vascularized bone graft. This is a microsurgical technique that allows for blood supply for the bone graft to increase the rate of healing of these difficult non-unions.



05

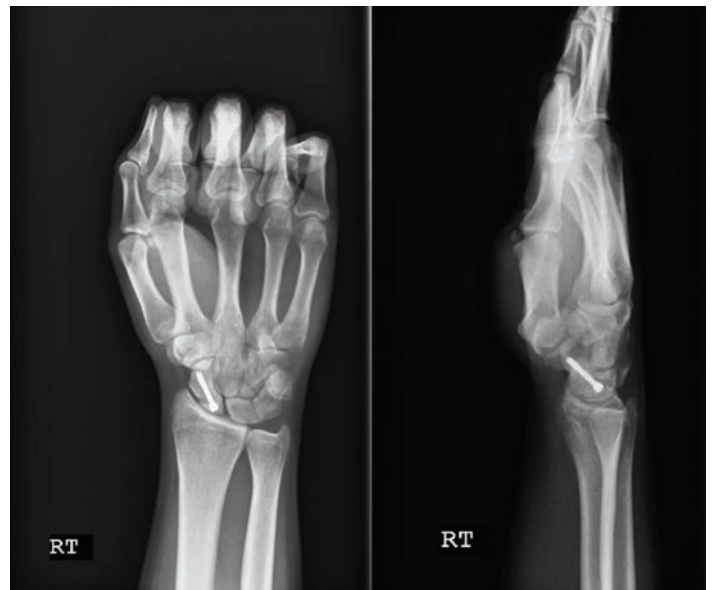No matter what technique is used for treatment of a non-union, the incidence of healing is lower and some of these wrists may ultimately go on to collapse of the bony architecture of the scaphoid. This will create long-term problems regarding pain, stiffness and loss of motion.

It is with the risk of non-union in mind that we feel it is contraindicated to treat a scaphoid fracture with casting and then allow the patient to return to a collision sport. At the OSM Center, we have seen too many patients over the years who have been placed into a thumb spica cast, sometimes short-arm in nature, sometimes only a gauntlet length, and allowed to return to football or other collision sports. The incidence of non-union after this mode of treatment is significant and is not in the best interest of the athlete. If early return to sports is to be attempted, these fractures should undergo internal fixation, even if they are non-displaced in nature. There is a great role for percutaneous placement of a headless screw in this situation. This allows for early union and stabilization.

It is imperative that whenever dealing with an athlete with a scaphoid fracture, the risks and benefits of all of the treatment options are discussed. It is important that the athlete and his/her family understand the precarious blood supply of the scaphoid, and therefore, the risks of non-healing, no matter what method is used for treatment.

Return to play after scaphoid fracture treatment has many variables. Certainly, with good, stable, internal fixation return may be anticipated in an earlier time frame. Non-collision athletes will be able to get back to the sport before collision athletes. Whether or not a sport allows for adaptive or protective devices on the wrist will have impact. The most important criteria is level of healing. Regardless of the treatment option selected for a scaphoid fracture, documentation of healing will be imperative. Plain x-rays can often be very helpful to allow for noting the level of healing; however, in certain circumstances a CT scan with 3D reconstruction may be required in order to be able to see bridging callus. Non displaced fractures with internal fixation will be able to return to play earlier than displaced fractures. Acute fractures will normally heal more quickly than non unions. All of these factors must be taken into consider when allowing the athlete to return his or her sport in a safe and efficient fashion.

With early diagnosis and appropriate treatment, scaphoid fractures can have a healing rate of greater than 90% with an ultimate return to athletics. The ability to make the diagnosis shortly after injury certainly goes a long way in terms of allowing for the best possible outcome.



06

- 03 3D Reconstruction CT Scan showing non-displaced fracture at the waist of the scaphoid.
- 04 Percutaneous technique with a guide wire placed through a dorsal puncture wound.
- 05 Lateral view of K-wire placement with wrist flexion.
- 06 AP and Lateral X-Ray status post scaphoid percutaneous pinning

Sesamoid Stress Fractures



Gideon Mann, MD
Meir General Hospital, Orthopedic
Department

Additional Authors:

- Iftach Hetsroni, MD¹
- Naama Constantini, MD²
- Eran Dolev, MD¹
- Ezequiel Palmanovich, MD¹
- Alex Finsterbush, MD²
- Eran Keltz, MD¹
- Omer Mei-Dan, MD¹
- Iris Eshed, MD³
- Niv Marom, MD¹
- Eugene Kots, MD¹
- Meir Nyska, MD¹

1 Meir General Hospital, Orthopaedic Department, Kfar Saba, Israel

2 Hadassah University Hospital, Unit of Sports Medicine, Department of Orthopedics, Jerusalem, Israel

3 Sheba Medical Center, Tel Hashomer, Department of Diagnostic Imaging, Israel

Affiliations:

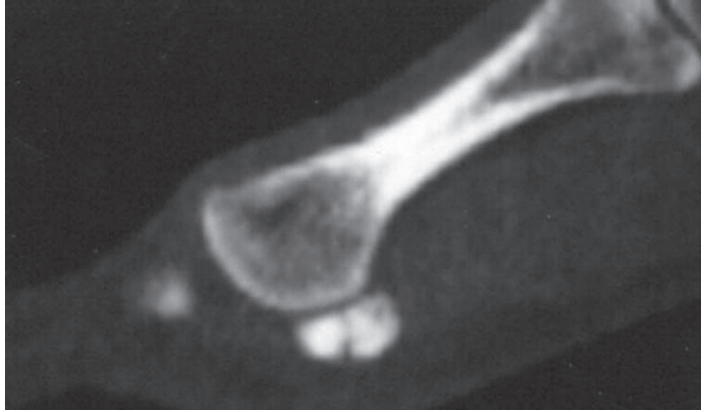
Orthopedic Department, Meir General Hospital, Kfar Saba, Israel

The Sackler Faculty of Medicine, Tel Aviv University, Tel Aviv, Israel

Ribstein Sports Medicine & Research Center, Wingate Institute, Netanya, Israel

Abstract

Stress Fractures of the Sesamoid occur in a wide variety of sports. They occur more frequently in the medial Sesamoid though they may occur in either lateral or medial bone. They have a strong tendency for non-union. Diagnosis would include imaging modalities as x-ray; Bone Scan and CT, as differential diagnosis is often difficult. Treatment would be initially conservative with an orthosis preventing Hallux dorsiflexion and relative rest for three to six weeks, or cast for a similar period. Surgical treatment may be eventually needed performing a Bone Graft or advancing to partial or full excision of the injured bone.



02c

Introduction:

The term “sesamoid” is derived from the Greek word “sesamum” due to the resemblance of the bone to the seeds of the plant *Sesamum Indicum* used as a purgative by the ancient Greeks (Figure 1).

Sesamoid stress fractures occur in a wide variety of sports such as football, long distance running, sprinting, dancing, basketball, tennis and figure skating. Injury of the sesamoid could cause incapacitating pain on athletic activity.

Pathophysiology:

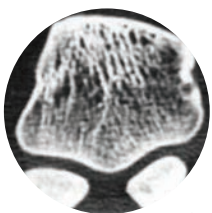
The Sesamoid Bones are located plantar to the First Metatarsal head where they are imbedded within the plantar plate, as part of the tendon of the Flexor Halucis Brevis. The plantar plate transmits 50% of body weight and more than 300% body weight during push-off. The large forces of weight bearing and traction, expose the sesamoids to a variety of pathologies, inclusive of Sesamoiditis, Chondromalacia, Osteochondritis Dissecans, Avascular Necrosis (Osteonecrosis), Osteoarthritis, Osteochondral Fractures and Stress Fractures.

Stress fractures of the sesamoid comprise approximately 5% of foot stress fractures. They usually evolve following repeated traction while acute fractures could occur following both direct compression injuries such as a fall and traction injuries. The stress fracture involves mostly the medial sesamoid, though either sesamoid could be involved, the lateral or the medial (Figure 2a, 2b, 2c).

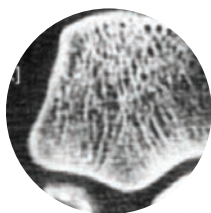
Sesamoid stress fractures have a strong tendency to non-union, probably more than any other bone. Orava and Hulkko have shown non-union in 15 of 37 cases and only 10 of 15 showed union after using modified foot wear and relative rest.

Clinical Presentations:

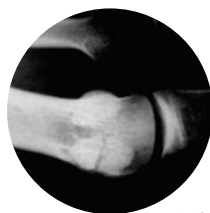
Pain is of insidious onset and unusually long standing. It is poorly localized, occurring during or after activity and relieved by rest. Pain is increased by hyperextension of the great toe and by local pressure. Occasionally, pain is severe and could be devastating to an athlete.



01



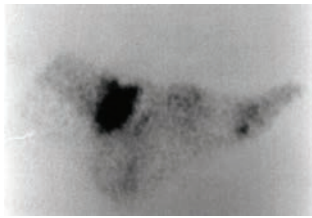
02a



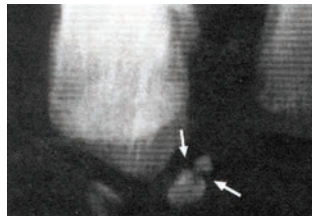
02b

Diagnosis:

Diagnosis is confirmed by x-rays inclusive of an anterior-posterior projection, a lateral projection and an axial projection, and by a bone scan (Figure 3) which would differentiate a fracture from a bipartite sesamoid. It should be mentioned that bone scans have been claimed to show some uptake in the sesamoid of normal feet in up to 30% of the population. Serial x-rays in intervals of 3 weeks and up to 3 or 6 months would be helpful if a pre-injury x-ray showing no partition is unavailable, which is usually the case. A Computerized Tomogram (CT) gives an accurate and clear image of the injury.



03



04

A fractured sesamoid would usually show equal sized fragments, ragged in texture, while a bipartite sesamoid would have smooth and unequal fragments (Figure 4).

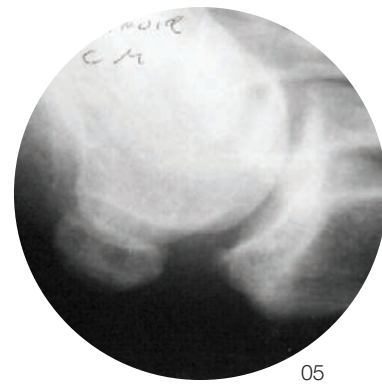
75% of bipartite sesamoids are bilateral.

The fracture line would usually be transverse, with osteoporotic edges which would become smoother in time. Further fragmentation could be seen. Both computerized tomograms (CT) and magnetic resonance (MRI) have been suggested for accurate diagnosis. Osteochondritis Dissecans or Osteonecrosis (Figure 5) could occur and radiologically could be difficult to differentiate from a bipartite sesamoid or a fragmented stress fracture (Figure 6).

Treatment:

Treatment would therefore be relatively aggressive with orthoses preventing Hallux dorsiflexion, and padding along side with relative rest probably for 3 to 6 weeks. If symptoms are severe a platform cast for 6 weeks with protection from toe dorsiflexion may be used, controlled by repeated x-ray. Others recommend a cast, possibly non weight bearing, for 6 weeks as the initial treatment, with appropriate padding to reduce pressure on the injured bone.

If symptoms persist bone grafting may be attempted, though excision of the fractured sesamoid is probably more often practical a procedure allowing return to full activity often an initial 3 week period of immobilization. Excision could be total or partial. Shaving has been practiced. Excision of both sesamoids is not advised. Medial partial sesamoidectomy has also been described as an arthroscopic procedure.

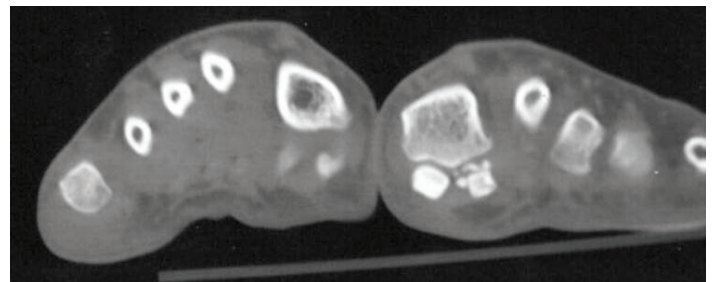


05

Summary:

Stress fractures of the sesamoids occur following repeated traction and usually involve the medial sesamoid. Acute injury caused either by crush or by traction ("Turf Toe") would involve either sesamoids. Pain is insidious and long standing. Diagnosis is clinical, as pain is caused by both toe dorsiflexion as by local pressure. Diagnosis is assisted by x-rays and bone scan and occasional CT or MRI. Radiological Differential Diagnosis includes bipartite or multipartite sesamoid or osteochondritis. Clinical Differential Diagnosis includes mainly sesamoid chondromalacia or osteoarthritis, the later of which could be apparent on x-ray. The sesamoid stress fracture has a strong tendency to non-union. Treatment should be initiated immediately after diagnosis and includes orthoses or cast for 6 weeks with a platform to prevent toe extension.

If clinical and radiological healing fails to occur, surgical treatment by partial or total excision of the sesamoid should be initiated followed by 3 weeks of immobilization before gradually returning to sports. In selected cases, bone graft to the fracture could be considered.



06

- 01 The Sesamoid bones of the great toe, as seen on an axial x-ray.
- 02 Stress Fracture of the sesamoids:
 - 02 a. In the axial view.
 - 02 b. In the anterior-posterior view.
 - 02 c. In the lateral view.
- 03 A bone scan showing high uptake of the great toe Sesamoids, representing a stress fracture. The injury to the ankle is unrelated.
- 04 A bipartite Sesamoid shows unequal size fragments with smooth surfaces as opposed to the equal sized fragments with ragged surfaces seen in a stress fracture as in figure #2.
- 05 The picture represents most probably avascular necrosis of the Sesamoid. The cause, in this case, was unknown.
- 06 A fragmented stress fracture of the Sesamoid.

Cytokines in Sports Medicine



Tahsin Beyzadeoglu, MD
*Prof. of Orthopaedics & Traumatology,
 Beyzadeoglu Sports Medicine Clinic,
 Istanbul, Turkey
 Team Physician for Turkish Men's
 National Basketball Team*

Additional Author:
 Murat Demirel, MD
Orthopaedic Surgeon, Bayindir Hospital, Ankara, Turkey

Cytokines are relatively small protein molecules carrying signals from cell to cell. The nomenclature of cytokines is heterogenic. Interleukins (IL) were numbered in the order of their discovery: IL-1 to IL-37. Others were named according to one or more of their initially described functions (Tumour necrosis Factor = TNF, GCSF = Granulocyte Colony-Stimulating Factor) or primary cellular origin (Monokine = Monocyte Derived). Other cytokines are commonly referred to as growth factors (e.g. transforming growth factors (TGF-βs), bone morphogenetic proteins (BMPs), platelet derived growth factor (PDGF), insulin like growth factors (IGFs)). Cytokines such as IL and interferons (IFN) have immunomodulatory effects, cytokines such as erythropoietin and thrombopoietin have different functions. Obviously the mentioned functions are of considerable interest in sports medicine. They appear to have a potential to act more specific than for example NSAID or Corticosteroids do. Especially tissue healing for tendons or cartilage may be less impaired than with the mentioned substances.

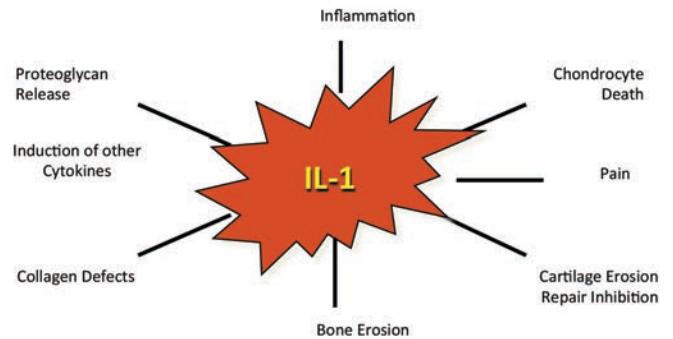
Cytokines in acute inflammation

Cytokines are essential in acute inflammation enabling the creation of an immune response. By activating leukocytes and endothelial cells in an insult, cytokines help to initiate a host of protective and reparative responses. IL-1, TNFα and IL-6 are cytokines playing an important role in formation of the acute phase response. This response, when transient, will eventually lead to a good outcome in tissue healing.

Cytokines in chronic inflammation

Chronic inflammation may have detrimental effects on tissues. In case of impairment of the local or systemic immune system (e.g. autoimmune disease, chronic osteoarthritis, chronic tendinitis) cytokines such as IL-1, and TNFα can cause and sustain chronic inflammation with no apparent injury left. This can impair the healing outcome of the tissues involved [Fig. 1].

IL-1 in chronic inflammation



01

Local treatment of injury and the following acute or chronic inflammation

Since 1980s, inhibition of pro-inflammatory cytokine production or receptors became major targets in research and, ultimately, treatment. Interleukin-1 is one of the main mediators in cartilage destruction and therefore a main target for new biological treatment methods. Interleukin-1 Receptor Antagonist (IL-1Ra) is the naturally occurring competitive receptor antagonist of IL-1 [Fig. 2]. It binds to the IL-1 receptor without turning on the inflammatory biochemical switches. IL-1Ra is virtually free of side effects, can be used in high doses and is eliminated within several hours by urinary excretion. Other cytokines such as IL-4, IL-10 and IL-13 have been shown also to exert significant anti-inflammatory action by increasing the synthesis of IL-1Ra and/or reducing pro-inflammatory cytokine production. Table 1 gives a -by far- non complete list of important cytokines.

Production of cytokines with recombinant DNA techniques is technically demanding. A limited number of cytokines have been approved for clinical treatment in a wide range of clinical indications. These include IL-1Ra, PDGF BB, IL-2, EPO, IFN, G-CSF, GM-CSF, BMP2+7 and IGF-1. Other cytokine related approvals are for neutralizing antibodies or decoy receptors in a variety of immune diseases. Because of their strong potency these recombinant factors are to be used with care within the safe dosages. All pure recombinant growth factors are banned by WADA (World Anti-Doping Agency) as doping.

Pro inflammatory cytokines	Regulatory and anti-inflammatory cytokines	Growth factors
IL-1a + IL-1 β	IL-1Ra	FGF
IL-2	IL-4	PDGF
IL-3	IL-6	VEGF
IL-6	IL-10	TGF β
IL-7	IL-37	EGF
IL-9		HGF
IL-12		IGF
TNF		

02

Other sources of cytokines are blood preparations often prepared at site of care utilizing official medical devices. They range from platelet concentrates (PRP) to autologous conditioned serum (ACS). The use of these preparations is exempt from WADA prohibition because they appear to have little effect on athletic performance. The authors of a recent study showing some circulatory increase of growth factors after PRP injection “believe that PRP will at best restore athletes to preinjury levels of competition but is unlikely to provide a competitive advantage relative to uninjured”. Some reviewers arrive to the conclusion that there is not sufficient evidence for the clinical effectiveness of PRP. However, given their apparent safety, autologous blood preparations are popular methods in the effort to supply athletes with a locally effective reparative stimulus in case of injury.

What can we do now?

There are many papers covering wildly varying PRP preparation and treatment techniques. Not only is the yield in platelets variable between preparations but also the yield in white blood cells and residual erythrocytes. Cells, even when autologous, leave a “footprint”. They either have to leave the site of injection or their debris be phagocytosed. This opens the field for speculation if amongst the possibly beneficial activities of cells like platelets and leucocytes there might be counterproductive aspects in case of their excessive presence [Fig. 3]. On the other hand controlled trials have been published that show effect, if variable, of different PRP preparations in osteoarthritis.

We shall discuss another, more controlled option that also makes use of autologous cytokines and growth factors from blood: Autologous Conditioned Serum (ACS). Table 2 shows the respective cytokine profiles in ACS and a single spin low platelet PRP version.

Autologous Conditioned Serum (ACS)

Publications about ACS treatment have increased in recent years. The basis is a technology that takes advantage of anti-inflammatory IL-1Ra generated from autologous blood at site of care. In 2003 a publication described the technique: strong IL-1Ra elevation in patient's blood serum when whole venous blood is incubated at 37°C in a special device. At that time recombinant IL-1Ra had been shown to have potential in the treatment of osteoarthritis in dogs and other species. In ACS additional anti-inflammatory cytokines such as IL-4 and IL-10 accumulate along with growth factors. The cytokines so produced become available in the autologous blood serum, which is subsequently used for local injection into the injury. Several studies have shown good results for musculoskeletal indications. We shall summarize a few significant publications relevant for sports medicine.

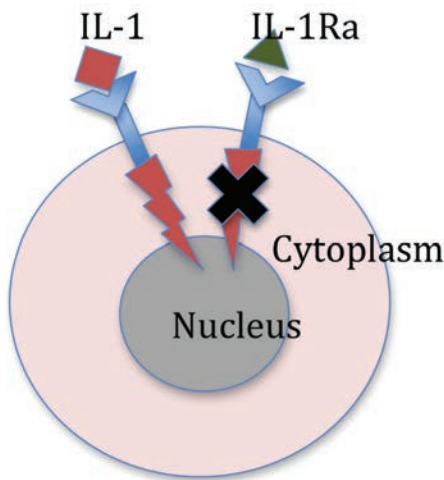
Intramuscular injection

In a much cited clinical pilot study with professional athletes with a variety of muscle lesions and in a mouse model study, Wright-Carpenter et al. proved that muscle injuries can be treated successfully with local intra-lesional ACS injections. The clinical effect of ACS injections was compared to Actovegin®/Traumeel® injections. Return-to-full-training time for the athletes in the ACS group was reduced by a means of 5.7 days (16.6 vs 22.3 days). The mouse model (severe contusion injury to the gastrocnemius muscle) histologically showed at 30 and 48 hrs more activated satellite cells and accelerated tissue recovery when three local injections of ACS was used compared to three saline injections. After seven days histology of the ACS group displayed a much further developed muscle tissue. IL-1Ra contained in ACS may play an additional beneficial role, being able to block IL-1a that has been described to inhibit myogenic terminal differentiation.

- 01 Interleukin 1 as a central player in acute and chronic inflammation. Schematic view of some of the pathologic effects IL-1 can have on tissues. IL-1Ra for this reason is a very interesting molecule.
- 02 Non complete list of cytokines playing an important role in acute and chronic inflammation and tissue regeneration. Note: IL-6 is an example of a pleiotropic cytokine that can have different functions. IL-6 amongst other functions is important in tendon, skin and liver regeneration. Interestingly, also TGF β may act anti-inflammatory in addition to it's growth factor function.

Achilles tendon injection

Majewski et al. showed that healing of Achilles tendon in a rat model improves when ACS is applied locally three times after dissection and re-suturing. Histologically, tendon tissue showed a remarkably superior orientation and deposition of collagen vs placebo. Biomechanically tested tendon strength in the ACS group was superior at four weeks but similar to the placebo (saline) group at eight weeks after the treatment. An interpretation is that tendon regeneration may not gain in speed but may ultimately gain in quality when inflammation is reduced and regenerative growth factors are supplied. Since single growth factors usually are not sufficiently effective or have side effects, Majewski et al. conclude that the complex combination like in ACS is possibly one key to the effects observed.



03

Intra-articular injection after ACL Reconstruction

Two studies by Darabos et al. describe the use of ACS after Anterior Cruciate Ligament (ACL) reconstruction. IL-1 has been implicated in bone lysis of the tibial tunnel after ACL surgery. Darabos et al. showed in an RCT study that intra-articular IL-1 β concentration and tibial tunnel widening were reduced compared to placebo (saline) when ACS was injected post-surgically intra-articularly. The clinical significance of laxity is open to debate. However, substantial tunnel widening can become an issue during revision surgery. Darabos et al. showed that ACS with its strong anti-inflammatory action significantly reduces tibial bone tunnel widening at twelve months after surgery.

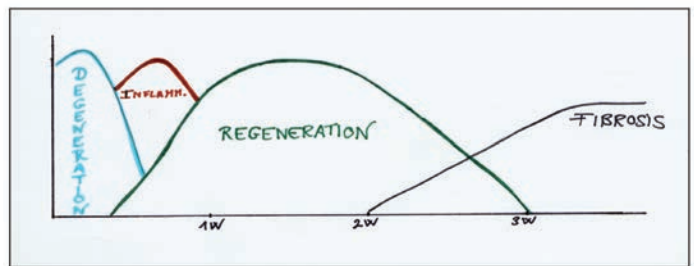
Epidural peri-radicular injection for lumbar back pain

Chronic inflammation of spinal nerve roots is a cause for radicular pain. Anti-inflammatory cytokine studies had shown that lumbar radicular pain may be influenced beneficially. A controlled clinical study by Becker et al. showed that injections of ACS show superior pain reduction after six months when compared to 2 groups (5mg and 10mg) Triamcinolone after application via epidural peri-radicular approach.

Intra-articular injection for knee osteoarthritis

Several studies on ACS relate to its wide spread use for joint disease. In a placebo-controlled equine study with a trauma induced osteoarthritis model, a clear clinical and histological superiority of the ACS group over placebo was reported and judged significant after 7 weeks. In another placebo-controlled clinical trial for osteoarthritis, the ACS treated group reported significant superiority in specific KOOS and KCRS parameters after one year. A randomized controlled osteoarthritis study comparing ACS injections to Hyaluronan and saline proved that ACS injection is significantly superior in effect size and has an effect duration of two years in osteoarthritis grades II-III. A recently presented case series with 118 ACS-treated patients by Baselga et al. showed outstanding symptomatic relief in osteoarthritic patients with initially high pain intensity (mean VAS 8 reduced to 3) and osteoarthritis grades I-IV when combined with physiotherapy.

ACS has shown potential for use in muscle injuries, Achilles tendon injuries, spinal nerve root inflammation, in osteoarthritis and after ACL surgery. It offers an easy and safe technique to use cytokines for the treatment of injuries and chronic syndromes. For further reading, published reviews are recommended.



04

	IL-1Ra pg/mL	IL-10 pg/mL	IL-6 pg/mL	EGF pg/mL	bFGF pg/mL	HGF pg/mL	IGF-1 ng/mL	PDGF AB ng/mL	TGF β 1 ng/mL	VEGF pg/mL
Baseline	161.4	3.6	17.1	0.1	2.1	396	69.2	0	1	6.1
low PRP	250.3	4.5	18.9	289.2	33.6	550.1	81.9	18.6	34.5	177.8
ACS	1642.7	12.7	117.7	1019.2	14.2	1238.3	107.1	28.1	41.0	409.5

05

What may we be able to do in future?

Some of the clinically approved recombinant cytokines may have benefit for clinical use in sports injuries. Especially the IL-1Ra is to be judged extremely safe. As pointed out, single factor injection has so far not produced the striking improvements looked for. Obviously the correct cytokine has not been yet identified. There remains the fact that recombinant cytokines are still considered performance enhancing and not therapeutic by WADA. The use of blood born cytokines will therefore recommend itself to be improved in terms of cytokine profile and growth factor profile, in terms of dosage and in terms of purity of the compounds injected into a lesion.

For PRP this possibly means optimized fractionation of thrombocytes, of white blood cell populations and of plasma. The problem of dosage has occasionally been discussed. Too high concentrations of growth factors may have a quite paradox effect on tissue healing.

For ACS further research and studies should be performed to better define the mechanisms that make ACS such a promising option. It is desirable to more clearly define its clinical scope and limitations. In distinction to PRP, ACS delivers cell free, anti-inflammatory and growth factor rich blood serum for autologous use at site of care. Dosage does not appear to be a very big problem because no cells are concentrated above in vivo levels. Therefore local cytokine concentrations at injection site can hardly exceed physiological levels.

Ultimately, the often chronic nature of musculoskeletal diseases might be a good target for gene therapy approaches. Both for humans and animals first trials have been performed in the past. New studies and data are to be expected in coming years. IL-1Ra is a favorite cytokine gene, for it is very well tolerated, is cleared very rapidly and is capable of resolving chronic degenerative inflammation. The viral transfer vehicles for the IL-1Ra gene may probably be Adeno Associated Virus vectors. Expression of the transgene is stable over an extended period of time and it is expected to be an immunologically well tolerated transfer system. This leaves open the regulatory hurdles associated with an approval for gene therapy for a non-lethal disease. And, IL-1Ra gene therapy would be considered gene doping by WADA even if no performance enhancing effect is to be expected.

- 03 Example of cytokine (e.g. IL-1) binding to cell surface receptors. Binding generates a signal that is transported into the target cell nucleus. This signal will then activate genes and promote mRNA production. In the alternative case shown here IL-1 receptor antagonist (IL-1Ra) binding does not generate such signal but occupies the IL-1 receptor. Thereby IL-1 signaling and inflammatory gene expression is blocked.
- 04 It is generally accepted that after an injury (here: "Degeneration") regeneration and inflammation overlap. An important goal is to accelerate regeneration in order to reduce fibrosis of the tissue. One of the rationales for the use of cytokines is to augment healing.
- 05 Comparison of Cytokine content in ACS and low platelet PRP (≤ 2 fold increase over baseline). N=9 voluntary donors. Table modified according to Weisshaar and Gaji [13]. Note that all concentrations are in pg/mL except for IGF-1, PDGF AB and TGF β 1 (ng/mL)



ISAKOS ASKS

Tell us about yourself, and we will tell you where you sit in the crowd.

The ISAKOS Newsletter Poll questions are available on the ISAKOS homepage—www.isakos.com. Results and additional comments will be published in the next ISAKOS Newsletter.

1 What's your common working day hours?

1. <8
2. 9
3. 10
4. >12

2 What's the common turnover between cases in your outpatient OR?

1. <15m
2. 15–30m
3. 30–45m
4. 45m–60m
5. >60m

3 How many educational meetings do you attend per year?

1. None
2. 1–3
3. 4–6
4. 7–10
5. 10+

4 When do you plan to retire....?

1. <55
2. <60
3. 65
4. 70
5. never



Visit Page 35 for the results of the ISAKOS Newsletter 2013: Volume II Poll

Reconstruction of the Medial Patello-Femoral Ligament



David Sadigursky, MD
*COT–Orthopedic and Traumatologic
Clinic–Bahia, Brazil
University of Bahia–HUPES*

Additional Authors:

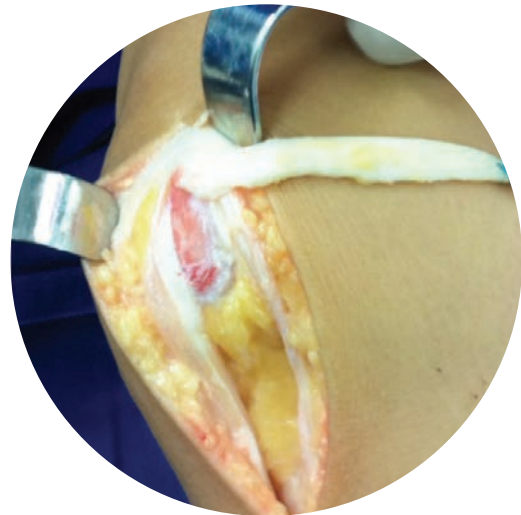Riccardo Gomes Gobbi, MD
Marco Kawamura Demange, MD, PhD
José Ricardo Pécora, MD, PhD
Gilberto Luis Camanho, MD, PhD
*Institute of Orthopedic Surgery and Traumatology-HC-FMUSP
University of São Paulo, Brazil*

In 1957 Kaplan, in an article discussing knee stabilizers, described on the region of the medial aspect, a transversal reinforcement of the patella toward the tendon of the gastrocnemius medial head. This has been regarded as the first reference in the literature of medial patelofemoral ligament (MPFL).

Warren and Marshall's 1979 classic work, in which they described the three anatomic layers of the antero-medial region of the knee, was the first to describe and name the MPFL and its location in the second layer, between the medial epicondyle and the patella

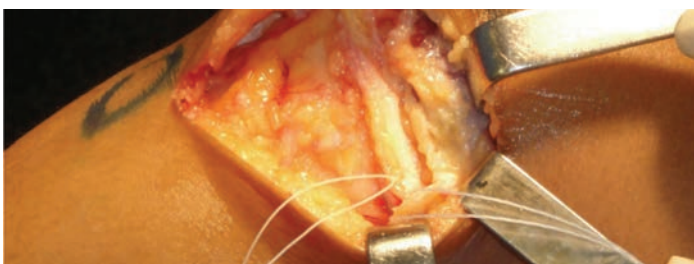After its anatomic description, studies carried out on specimens showed that the MPFL is responsible for 50–60% of the resistance against patellar lateralization, allowing its rupture to be accepted as the essential lesion of the lateral luxation of the patella.

Despite this biomechanical importance, the valorization of MPFL reconstruction is relatively recent, having occurred in the last two decades, mainly. In spite of the great variety of techniques described for its reconstruction, with different sources of graft and fixing methods, evidence that shows good clinical results of this surgical procedure has been gathered, with a very low instability relapse rate.



In this article, we shall discuss some points which have been considered controversial when it comes to MPFL reconstruction surgery. We will do it taking current evidence into consideration.

Firstly, it's necessary to discuss the anatomy of the region. The femoral origin of the ligament has already been described in the adductor tubercle, at the fore portion of the medial epicondyle, at the posterior portion of the medial epicondyle distal to the adductor tubercle, at the medial and proximal epicondyle itself and posterior to the epicondyle, immediately distal to the adductor tubercle. The variation of these descriptions shows that the femoral origin of this ligament is not a clearly identifiable structure, with the convergence of several anatomic structures, making its individualization a difficult task. Our team, based on both the literature and our own studies, agrees with Nomura et al, that the femoral origin of the MPFL is located between the medial epicondyle and the adductor tubercle. This point is also consistent with what was described in radiographies by Schottle et al, in 2007. With the objective of making MPFL reconstruction more reproducible, they carried out a study in which a metallic marker was placed in the femoral insertion of MPFL, and side radiography was produced afterwards. The average point can be reproduced by positioning the femoral center of the MPFL insertion 1 mm prior to the distal projection of the posterior femoral cortical line, 2,5 mm distal to the posterior origin of the femoral condyles and proximal to the level of the posterior point of Blumensaat line. A study that may also be mentioned is the one by Stephen et al in 2012 about MPFL, finding as the most isometric point, and thus the most recommended for the reconstruction, the same point between the medial epicondyle and the adductor tubercle. Servien et al published a critical analysis of the positioning of its points of femoral fixation. They found 65% (using RNM to confirm the localization) to 69% (using radiographies) of well positioned tunnels, showing the difficulty to obtain good positioning of the tunnels during surgery. They, therefore, suggest a routine of radiographic checking of the tunnel as often as possible.



Another important concern is the consequence of a positioning mistake when applying a graft during the MPFL reconstruction. It is known that small mistakes of 5 mm from the ideal position or the tensioning of the graft $> 2N$, have led to the increase of the articulate forces in the medial patellar facet, increasing the risk of pain and the degeneration of the patellar cartilage. So, during the MPFL reconstruction, the surgeon must never over tension the graft. It must be positioned without loosening and fixed in the anatomic position. The graft only becomes tense with the lateralization of the patella. Mistakes in the positioning of the graft on the proximal-distal axis generate much more anisometry than mistakes in the anterior-posterior axis. The changes of the patellar insertion exert a minor effect on the MPFL isometry.

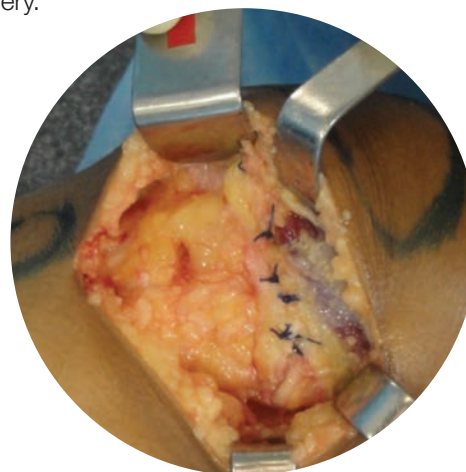
However, where exactly in the knee must the graft be tensioned? It is known for sure that this ligament does not present an isometric behavior, showing itself to be more tense between 0° and 60° of flexion, relaxing with more intense flexion. Once more the literature is conflicting. It is possible to find fixations recommended between 30° and 45° , 45° and 60° , and 60° and 90° of flexion. A recent study analyzed in vivo the change in length of the MPFL from its total extension to 120° of flexion through RNM. The results showed a minimal diminution in the MPFL length until 60° , and a significant diminution from 60° . In addition, when analyzing fiber orientation, they concluded that MPFL is tenser around 60° of flexion. This angle is also introduced by our team, based on findings in the study by Sadigursky et al in 2012.

Another point to be observed is the choice of the graft fixation method. The resistance to the MPFL traction and of some ways of mending and reconstruction were studied by Mounthey et al. The resistance found in the experiment was 208N in the full MPFL, 37N with the isolated suture (Kessler), 142N with anchors associated to the sutures, 126N with tendon grafts fixed in a blind tunnel and 195N with tendon grafts fixed in a bone tunnel going through the femur up to the lateral cortical. The series registered in the literature include the most varied fixations, all of which presenting satisfying results. Considering the native MPFL resistance around 200N, the graft choice should be a personal choice of the surgeon, since the commonly used grafts present satisfactory resistance. It is possible to find, in the literature, series using synthetic grafts, part of the adductor tendon, semitendinosus, gracilis, part of the quadriceps tendon, part of the patellar tendon and allograft, all presenting favorable results. Therefore, the only recommendation based on evidence that is possible to make about the graft and its fixation is that isolated suture must be avoided. Our choice is the use of the medial third of the patellar tendon as described by Camanho et al. We consider this technique easy to apply and a low cost one as well.

After the fixation of the MPFL graft, there is discussion concerning its dynamization through a solidarization with the vastus medialis obliquus. Several anatomic studies have described the close relation between these two structures, with real connection fibers between them. Moreover, several clinical studies describe its use in series of cases with good results. As a consequence, our team always recommends this solidarization.

To sum up, it is important to find in the literature the evidence of the effectiveness of the surgery. The first systematic review of the results of MPFL reconstruction was published in 2007 by Smith et al. The review included 8 papers with the total of 186 MPFL reconstructions. Despite the favorable clinical and radiographic results, the critical analysis revealed methodological problems in the available published material, including small samples, lack of control for confusion variables, absence of data concerning rehabilitation, works limited to case series, varied surgical techniques and limited statistical analysis. It was not possible to reach a consensus about the choice of graft, positioning, tensioning or between static or dynamic reconstruction. In 2010, two more systematic reviews were published, one by Buckens and Saris and the other by Fisher et al, with conclusions which were similar to the ones in the study by Smith et al.

Even if the surgery is performed in the ideal way, it is not known for sure what its effect will be on the biomechanics of this articulation, mainly when it comes to patients with multiple anatomic variations (trochlea and patellar dysplasia and height) as it is frequent in this population. The literature is still poor in terms of objective criteria to provide the correction of these factors, which must always be taken into account. Only the medialization of the anterior tibial tuberosity on knees with TT-TG measured over 20 mm is more established. The studies on the results of MPFL reconstruction were limited to describing the clinical aspects, with the incidence of pain, functional improvement and the occurrence of luxation relapse. The dynamic biomechanical evaluation of this articulation is very difficult, since the available exams for its study are static (radiography, CT and MRI). Studies of better methodological quality are still necessary, since for the treatment of chronic patellar instability the current level of evidence for MPFL reconstruction is "C". Only for acute luxation there is level "A" evidence for the effectiveness of this surgery.



Cricket and Injury: The Gentleman's Game Revisited



Prof. Dr. Mandeep S. Dhillon

Additional Author:

Dr. Sharad Prabhakar,
PGIMER Chandigarh, India

For many readers of this article, especially those from the Americas and Europe, the word Cricket may bring to mind many things, only some of which would be related to sports. In fact Cricket is a very popular game in some countries, mainly those that constituted the former British Empire, and now form the Commonwealth group of Nations. South-East Asian countries, Britain, Australasia, South Africa and the small group of Islands called the West Indies constitute 10 test playing nations, with many more nations involved in one-day cricket. This makes up almost 2 billion people who avidly follow the game, mostly from the developing world, and this in itself brings up issues related to injury prevention, injury documentation and appropriate management. The first recorded international game of Cricket took place in 1844, at St George's Park, New York, between the United States and Canada; many don't know that Canada won. The inaugural cricket "Test match" was played between Australia and England at the Melbourne Cricket Ground in 1877; the rest as they say is history.

The unique thing about cricket is the fact that the game has evolved with changing times; today it is played in multiple formats, from a long five day test format to an ultra short, highly competitive Twenty20 format, with issues and problems related to the players being different in the different formats.

Although cricket is a non-contact sport, ball related impact injuries are common, and have been documented as far back as 1751, when Frederick, Prince of Wales (son of George II), died from an abscess in his head as a consequence of a blow he had received from a cricket ball. Now-a-days these impact injuries are relatively uncommon, as the evolution of safety equipment in the game has brought about a tremendous change in the protective armamentariums in modern cricket. Special positions like the wicketkeeper are now so protected that impact injuries are rare. The batsman, who bears the brunt of the bowler's ferocity, is also extremely well protected; nevertheless some injuries are documented and issues related to contact in the hands, face and elbow are still commonly seen.

Injury surveillance and reporting in cricket is the need of the hour. Orchard et al defined cricket injury surveillance definitions in 2005. In the Western Cricket playing nations, several studies have been carried out focusing on the patterns of cricket related injuries, causative factors and outcomes of preventive measures in Cricket. The Australian Cricket Board reported an injury incidence as high as 38.5 injuries per 10,000 player hours in one day internationals, the British Sports Council reported 2.6 injuries per 10,000 hours played in the cricketers surveyed, and South African cricket surveys that 49% of all players injure themselves at some part of season. This makes for a significant problem, and preventive efforts are now being seriously undertaken.

The Feb 2013 issue of the BJSM contains three cricket injury surveillance studies, including the first published multi-country surveillance project. John Orchard in his editorial in the BJSM has recognized not only the rise of cricket injuries in Twenty20 cricket, but also the fact that the first multi-country study has come out 8 years after injury surveillance definitions were standardized.

The first international study to use recommended injury surveillance guidelines has been published by Ranson et al this year, as a report of five teams competing in the ICC Cricket World Cup in 2011. The authors have reported 23 time-loss and 97 non-time-loss injuries. The injury incidence was 3.7/100 player-days with time-loss incidence for match injury being 20.1/1000 player-days, bowling injury 3.3/100 bowling days and batting injuries 2.2/10,000 balls faced. High muscle strain and medical illness were the diagnoses with the highest incidence. The authors have stated that non-time-loss injury incidence appears to be high, and further investigations for progression to time loss are required. Interestingly both fast and slow bowlers had a similar injury prevalence of about 5%.



Ranson et al have published their second paper in the BJSM highlighting that significant head and facial injuries occur in cricket even today, and involve batsmen. The authors have reported that 30% of the injuries have occurred due to the ball penetrating the gap between the helmet peak and faceguard. They have suggested improving the cricket helmet design. In an article written by us, we have also highlighted the fact that wicketkeepers can also be seriously injured; in recent times one South African player had to retire due to an eye injury sustained by a ball hit.

In addition to direct blows, overuse injury are seen in specific players like fast bowlers, with predominant injuries being in the back, posterior ankle, shoulder and elbow. There is limited published data on bowlers' injury, although anecdotal reports exist. Nevertheless, with the accumulated data, it has been noted that the fast bowler in cricket is the most commonly injured player across all kinds of sports, and specific protocols to manage workloads, playing hours and biomechanical correction are now being put in place. There are 3 distinct phases of the bowling action: the run-up, the delivery stride and the follow through. Overuse injuries could be related to the elbow of the bowling arm, but are rare compared to baseball pitchers; we have published one such case of Valgus Overload syndrome. More commonly the issue is related to the back, and stress fractures and pre-stress lesions have been documented in fast bowlers across the world, and involve many young players early in their careers.

Morton et al have identified risk factors and successful interventions for cricket related low back pain. The authors have emphasized that screening for bone stress on MRI should be considered by physicians managing developing cricketers to identify the risk of lumbar stress fracture development. Oliver et al have also emphasized that lumbar position sense, as a measure of proprioception, was related to injuries sustained during the bowling action, and, especially, low back injury sustained in the past. The authors have stressed that if the proprioception of the lumbar spine is improved in pace bowlers, their risk of lumbar injury can potentially be reduced.

In one of the first studies from the Indian subcontinent, we have published data about the nature and incidence of upper limb injuries in professional; cricket players. Our data noted that the majority of injuries (10/16) occurred while fielding. Out of 16 injuries, 11 were seen in hand, 3 were observed in elbow, while 2 patients suffered from shoulder problem. Twelve were acute injuries while 4 were classified as repetitive stress injuries (RSI). We found that the incidence of upper limb injuries in cricketers at the professional and semi-professional level is significant, causing them to miss matches or practice for a significant number of days. The study highlights the importance of injury surveillance for Indian cricket.



02

Injuries common in other sports like tibial Stress fractures are rare, but have been noted. Hamstring strains are common, due to the explosive nature of running between the wickets, which often involves quick turning and diving, and is also a problem with bowlers during the run up and delivery strides.

Cricket actually has lagged behind other major international sports in adopting universally acceptable injury definitions; unlike most other sports, these are still not fully clarified, and this tends to skew the data collation somewhat with different previously published studies using different definitions. Fortunately, with acceptance of the definitions laid down by John Orchard and colleagues, some harmony of data compilation has ensued. However these also leave some scope for variation, as was pointed out by an our Indian study; many injuries related to Cricket maybe overlooked, as they do not occur during matches, but in practice, and the true epidemiology may not be accurately reflected. This is something that the International Cricket Council, based in Dubai is looking at with significant interest.

Injury surveillance in cricket, appropriate documentation and usage of common denominators is thus a major concern of the Cricketing world. This needs to be addressed by the administrators and medical personnel involved with cricket, and should percolate down to all levels of the game.

- 01 The author examining Muthiah Muralitharan, SriLankan spin bowler, who holds the World record of maximum wickets taken in Test Matches
 02 The Principal author at an International match between India and Australia in 2013

Lateral Epicondylitis

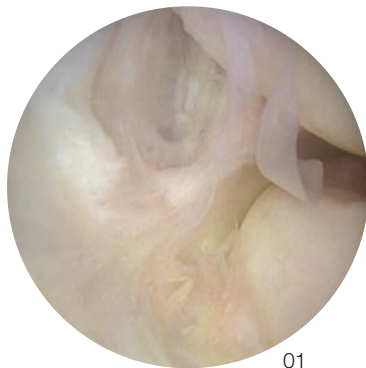


Felix H. Savoie, MD

Additional Authors:
Michael O'Brien, MD
Greg Bain, MD

Introduction

Lateral Epicondylitis, often referred to as tennis elbow is the most common disorder of the elbow, affecting 1 to 3% of adults during their lifetime. Degeneration of the origin of the extensor carpi radialis brevis (ECRB) tendon, termed angio-fibrotic dysplasia by Nirschl, is thought to be the essential lesion. Over the many years since its original description many other pathologic entities have also been noted to produce lateral elbow pain, including hypertrophy of the annular ligament, inflammation of the poster-lateral synovial plica, compression of the posterior interosseous nerve in the radial tunnel, radio-capitellar chondromalacia, and postero-lateral instability.



01

Patient History:

In most cases the symptoms begin insidiously, with no apparent defining injury. The patient will begin to notice pain on the lateral side of the elbow with tight grip and lifting. Most patients will self-treat with anti-inflammatory medication and topical analgesics prior to seeking treatment. On arrival in the office the patient indicates the outer side of the elbow as the area of discomfort. They will usually indicate that lifting, gripping and the use of vibratory equipment such as a drill or lawn equipment increases their pain. Patients may also describe the elbow having increased pain at night as well as an increase in pain when initiating movement after having the elbow at rest for a period of time.

Physical Examination

The physician may note slight swelling along the lateral side of the elbow. The patient will be tender directly anterior to the tip of the lateral epicondyle and gentle palpation may allow an estimation of the size of the involved area of the dysplasia of the ECRB origin. Placing the elbow in full extension and having the patient extend the wrist against resistance will often reproduce the pain. O'Driscoll has described the moving tennis elbow stress test where the patient tries to maintain the wrist in extension against resistance while the elbow is moved from flexion to extension and back. Other pathology can co-exist with lateral Epicondylitis: Often the posterior synovial plica will also be inflamed and can be "pinched" between the radial head and the capitellum with valgus stress and extension and if there is hypertrophy of the annular ligament this can be palpated anteriorly and laterally. Additional pathology to be ruled out include radio-capitellar chondromalacia (pain and crepitation with pronation and supination while elbow flexed to 90 and a slight valgus force applied), radial tunnel syndrome (tenderness in the interval between the two parts of the brachio-radialis muscle, and postero-lateral rotatory instability (a + shift with valgus and rotational stress).

Imaging

Radiographs are usually normal. Magnetic Resonance Imaging will always show the degenerative area of the ECRB origin, and is useful to rule out co-existing pathology. Ultrasound will also demonstrate the extent of damage to the tendon.

Nonoperative Management

Lateral Epicondylitis is often thought to be a self-limiting disorder, lasting less than a year. However, this time frame presumes there will be an avoidance of aggravating activity, which is not always possible. Non operative management therefor centers on changing the local environment to allow healing to occur while protecting the elbow from further injury.

PROTECTIVE BRACING: The use of a volar wrist splint to position the wrist in slight dorsiflexion is the best way to protect the ECRB. An elbow sleeve with or without a pad placed directly over the ECRB origin can also be helpful. Many patients will have already tried one of the commercially available counterforce braces, which require a pad to be positioned over the ECRB muscle and away from the radial tunnel to be effective.

TOPICAL MEDICATION: The use of anti-inflammatory creams has gained much popularity. The use of these creams seems to both decrease symptoms and allow increased use. The process of massaging the cream into the area of injury may stimulate increased blood flow, improving healing.

ORAL MEDICATION: The use of oral anti-inflammatory medication is common in Lateral Epicondylitis, although there is usually no evidence of inflammation in tissue specimens taken during surgery. However, their use may allow better rehabilitation and function.

PHYSIOTHERAPY: Nirschl has noted benefit from several physical therapy modalities over controls in which they were not used. Cryo-therapy and iontophoresis seem to improve healing and decrease symptoms. Deep tissue massage may stimulate better healing. Dry needling has been used with reported success.

INJECTIONS: Steroid injections have been used for many years with reported success, despite the lack of inflammatory cells noted in the pathology. Recent studies have been performed utilizing different variants of platelet rich plasma with similar success. Injection remains the hallmark of non-operative management.

Surgical Intervention

INDICATION: The indication for surgery is continued pain and functional impairment despite an adequate trial of non-operative management. In most cases at least 90% of patients will improve sufficiently with non operative treatment that surgery is not necessary.

Arthroscopic Procedure 1: Release: The initial arthroscopic procedure was described by Baker with excellent results. The procedure was an arthroscopic modification of the open tennis elbow release. In the Baker procedure, the Arthroscope is introduced via a proximal antero-lateral portal and the lateral aspect of the elbow joint visualized. A small window is made in the lateral capsule to visualize the degenerative area of the ECRB (Figure 1). The degenerative area is then excised, essentially releasing the ECRB origin from the lateral epicondyle while avoiding any damage to the overlying extensor carpi radialis longus muscle or tendon (Figure 2).

Arthroscopic Procedure 2: Repair: In some cases the lesion may be too large for a simple debridement of the surgeon may feel that repair would provide better strength or endurance. In these cases a simple needle retrieve technique may be used to plicate the ECRB to the overlying ECRL (Figure 3). An alternative to the plication would be to place an anchor into the lateral epicondyle, retrieve the sutures through the ECRB distal to the lesion and in a mattress configuration and repair the tendon back to the lateral epicondyle.

Arthroscopic Procedure 3: Repair to anchor: In some cases the Nirschl lesion may be too large or may be associated with damage to the lateral ligaments. In these cases a standard anterior lateral portal may be used to place an anchor into the anterior aspect of the lateral epicondyle. A double loaded anchor is used so that one set of the sutures may be placed around the ECRB tendon and a second set around the lateral ligaments, repairing both to the lateral epicondyle.

Open Repair: Open repair has been described by many authors, but the Nirschl procedure as reported by Nirschl and Pettrone has been the most widely used and reproduced. In these cases a small incision is made anterior to the tip of the epicondyle. The ECRL is split, allowing access to the ECRB origin. The dyplastic area of tendon is removed, and the underlying bone surface of the lateral epicondyle is abraded. The tendon may be repaired at this point to the bone, to the more posterior soft tissues, or to the overlying ECRL.

Post Operative Rehabilitation

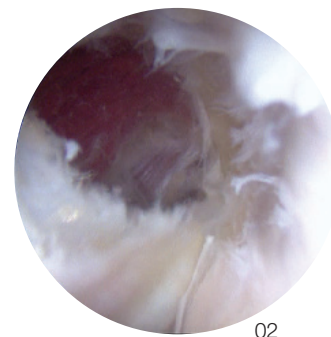
In all cases the post op rehabilitation is fairly similar. The elbow is protected for the first week to allow some healing to occur. The goal for the first 2–3 weeks is to restore full range of motion, eliminate swelling and allow the tendon to recover. Pain free strengthening is started at 2–4 weeks and progressed as tolerated. Most arthroscopic patients resume routine daily activity by 6 weeks with a full recovery by 3–4 months. The open procedure usually takes a little longer.

Results

Most series document excellent results with surgical intervention. In both series by Baker the arthroscopic debridement was effective in over 90% of patients managed by arthroscopic techniques. Nirschl and Pettrone showed similar results with open surgery, and Szabo et al showed similar results in a comparison study of the 2 techniques.

Conclusion

Lateral Epicondylitis is a common, painful condition of the elbow. It may be managed without surgery with a high rate of success. In patients in whom non-operative treatment fails surgical intervention can provide satisfactory results.



- 01 A view from the medial portal shows a defect in the capsule with the degenerative ECRB tendon visible through the defect, with the radiocapitellar joint to the right.
- 02 In this view from the medial portal the degenerative tendon has been excised, revealing the normal overlying ECRL muscle and tendon

Operative Treatment for Complete Rectus Femoris Avulsion



Cecilia Pascual-Garrido, MD

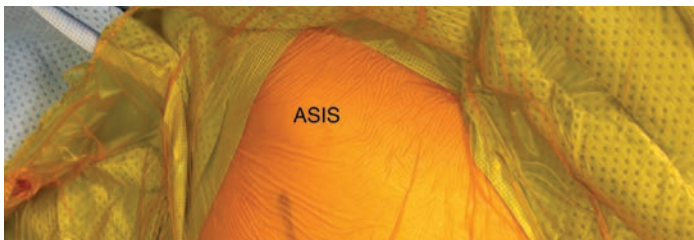
Additional Authors:

Jonathan T. Bravman, MD

Omer Mei-Dan, MD

Introduction:

Quadriceps injuries are common in sports requiring kicking activities, such as soccer and football. Among the muscles in the quadriceps group, the rectus femoris has a unique biarticular span across the hip and knee joints, which predispose it to stretching injuries during kicking. The direct head of the rectus femoris originates from the anterior-inferior iliac spine, proximal to the hip joint, whereas the reflected head originates from the anterior acetabular ridge and anterior hip joint capsule. Reports of proximal avulsion of the direct head of the rectus femoris are rare.



01

Surgical Technique:

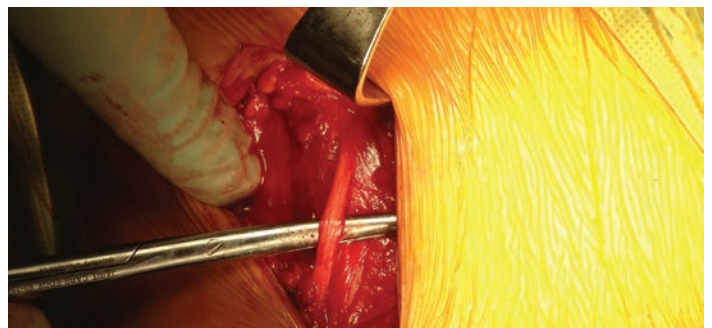
After induction of general anesthesia, the patient is placed supine on the operating table. The patient's hip and entire lower extremity are prepped and draped in a sterile fashion. A mini open incision following the line of the anterior Smith-Petersen approach to the hip is then initiated (Figure 1). The gap between the fascia lata and sartorius is identified and incised. Dissection through the subcutaneous fat is performed. The lateral femoral cutaneous nerve is identified and protected, and then retracted laterally with the tensor fascia lata (Figure 2). Next, the deep fascia is incised to expose a bulge of expected large hematoma pocket, and the tendinous portion of the rectus femoris is identified. The AIIS is then exposed and the anatomical location for re-insertion is identified and prepared for drilling. The muscle belly is then mobilized from its fascial sheath back towards its iliac attachment site reducing the central aspect of the large diameter tendon to its origin, maximizing surface contact area for healing (Figure 4). Two double loaded corkscrew anchors (Arthrex, Largo, FL) with #5 Fiberwire are placed in the AIIS and the respective stitches are then sutured in a whipstitch fashion in the superior and inferior aspects of the tendon (Figure 3).

Postoperative:

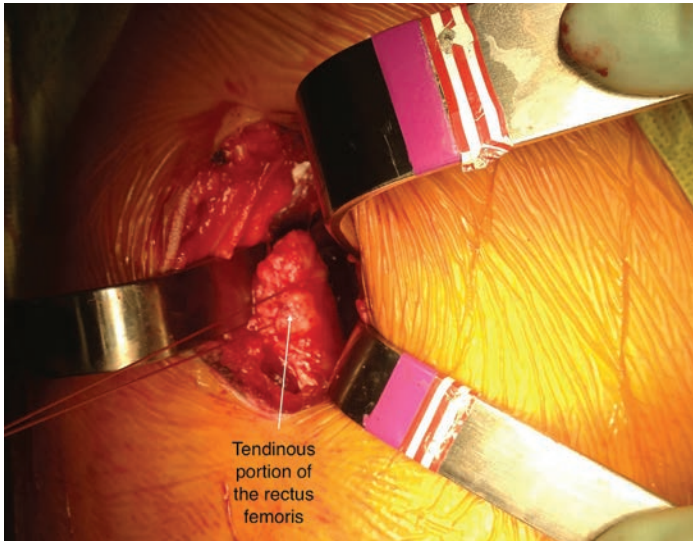
The postoperative time period is divided into four phases: protective, intermediate, advanced phase and return to play. During the Protective Phase (0–6 weeks) the goals is to protect the surgically repaired tissue by minimizing pulling stress on the repair and to reduce pain and swelling associated with the surgery. During this phase, the patient progresses from non-weight bearing protected in a long hinged knee brace locked at 20° (0–4 weeks) to full weight bearing with hinged knee brace at full extension (4–6 weeks). The goals of the Intermediate Phase (6–12 weeks) are to establish full range-of-motion, and continue to increase tensile strength of the surgically repaired tissue. The goals of the Advanced Phase (12–20 weeks) are to simulate sport and position-specific demands upon the patient, ensure adequate power and endurance of the patient and initiate a running program. Return to Play Phase (20–32 weeks) is to safely return the patient to pre-injury levels of performance.

Clinical Results:

The currently available literature has not yet established the best treatment option or technique for this injury, as this is limited to successful case reports only at this time. In high-level athletes, both operative and non-operative treatments have demonstrated good results. Clinical results with non-operative treatments have been published, suggesting good outcomes and return to play in an average of 10 weeks. Hsu et al reported on 2 professional American football kickers who sustained avulsions of the direct head of the rectus femoris with 1 and 3.5 cm of retraction. Gradual rehabilitation resulted in a return to kicking duties at approximately 6 weeks after the injury. Straw et al reported on a chronic rupture of the rectus femoris muscle in a 22-year-old soccer player sustained while attempting to kick a ball. After 12 months of nonoperative treatment, the athlete still could not sprint or kick. Irmola et al reported on 5 cases of rectus femoris avulsion treated surgically in 4 professional soccer players and 1 hurdler. Surgery was performed between 18 and 102 (mean 53) days after the injury. These avulsions were repaired with 2 to 4 suture anchors and protected with hip bracing at 45° of flexion for 1 week. Running was initiated at 8 weeks, but the players took an average of 9 months to return to sport. Garcia et al recently published the outcomes in soccer players with rectus femoris avulsion surgically treated. Results showed good results at 34 months with low recurrence rate and complete functional recovery.



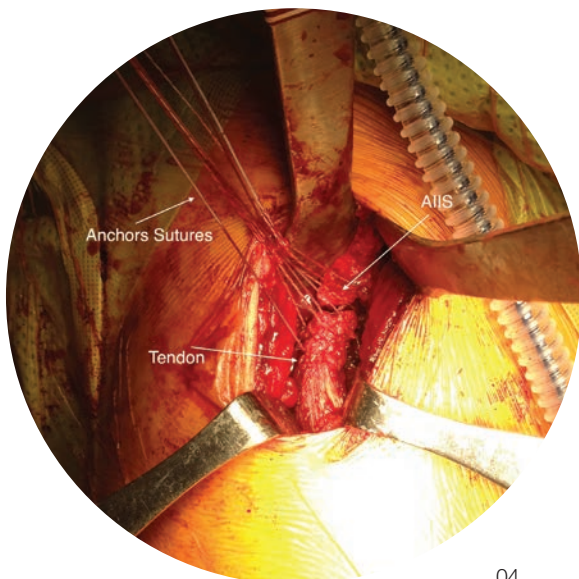
02



03

Conclusion:

The unique biarticular span, high stress of eccentric contraction, and the considerable intensity of muscular contraction, especially with the kicking motion, expose the direct head of the rectus femoris to high stress and strain and ultimately to failure. Surgical treatment is our best treatment option for high level athletes where return to play and low level of recurrence is crucial.



04

- 01 The ASIS (anterior superior iliac spine) is identified. The Smith-Peterson approach is marked, corresponding to the area inferior to the ASIS in the direction of the lateral patella. Palpate the interval between the TFL (tensor fasciae latae) and Sartorius.
- 02 Note the LFCN (lateral femoral cutaneous nerve) identified.
- 03 Insertion of the anchors at the ASIS.
- 04 Note the rectus tendon reattached to the bone.



**ISAKOS ASKED
YOU ANSWERED**

Results of the ISAKOS Newsletter 2013: Volume II Poll

1 What is your primary ACL graft?

- 10% 1. Auto BTB
- 81% 2. Auto Hamstrings
- 8% 3. 50/50
- 1% 4. Allograft

2 How long does your average Cuff repair take?

- 8% 1. < 45m
- 43% 2. 60m
- 39% 3. 90m
- 10% 4. > 2h

3 How many weeks off do you take a year?

- 29% 1. 0-2
- 49% 2. 3-4
- 19% 3. 5-6
- 2% 4. 7-8
- 1% 5. > 8

4 Do you work in a private or academic institution?

- 22% 1. Academic only
- 32% 2. Private only
- 46% 3. 50/50

5 How involved are you in research?

- 26% 1. Not interested, don't publish at all
- 69% 2. I publish 1-2 research works a year
- 5% 3. I Conduct several studies a year and publish 4-5 papers
- 0% 4. I spend much time on research work and publish more than 7 papers a year



CASE PRESENTER
Daniel A. Slullitel, MD, Prof.,
ARGENTINA

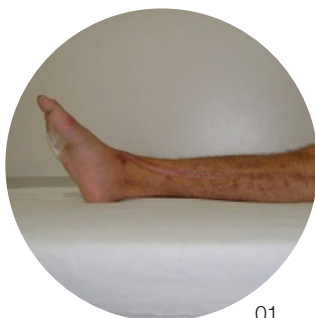CASE DISCUSSION

The patient is a male, 23 years old, who sustained a frontal collision against a rock while riding a motorcycle during a motocross race. Two hours later, the racer was admitted in an Emergency Hospital with a complete right Sciatic Nerve Palsy below knee, no distal pulses, anteroposterior +++ drawer test and signs of posterolateral instability. Vascular Ecodoppler revealed no distal perfusion signs. Also, the left knee had anteroposterior +++drawer, posterolateral instability but no nerve damage and no vascular signs.

He was admitted to surgery and a vascular exploration showed a complete Popliteal artery thrombosis that lead to a bypass. An external fixation frame was used to stabilize the joint. Distal signs of ischemia and a compartmental syndrome developed that lead to a re-exploration of the bypass and a fasciotomy. Finally distal perfusion was reestablished, but slight hallux valgus ischemia developed. Sciatic nerve palsy lead to anterior tibialis dysfunction with good recovery of sensorial nerves.

Three months later, the left knee underwent an All-inside Posterior Cruciate double bundle anterior tibialis allograft, Anterior Cruciate Reconstruction also with Anterior Tibialis allograft, and Posterolateral reconstruction also with allograft was performed in one stage.

The right foot at present time has an equinus flexible deformity, with deficient skin.



01

01, 02 Anteroposterior drawer test and dial up.
 MRI Angiography showed good perfusion

What goes first in an unstable knee with a neurological equinus foot?

Reconstruction of equinus or knee reconstruction?

If you have a vascular reconstruction, how do you perform knee surgery?

Tourniquet or not?

Also What are your thoughts about the nerve palsy?

In your experience will it be deteriorate by ischemia caused by a tourniquet?

How is the staging of knee instability surgery?

Which are your choices in ligamentous reconstruction?

With an equinus foot also with severe knee laxity a what different behavior of the knee will you expect?

Are the reconstructed ligament at risk?

In which cases will you suggest a varus osteotomy for the varus thrust that could cause the corrected equinus foot?

Any other comments?

RESPONSE TO “CASE CORNER” FOR ISAKOS NEWSLETTER

ISAKOS Knee Committee with Contributions from



Timothy S. Whitehead,
MBBS, FRACS
AUSTRALIA



Annunziato Amendola, MD
USA



Christopher John Vertullo,
MBBS, FRACS (Orth), FA Orth A
AUSTRALIA



Elizabeth A. Arendt, MD
USA



Shuichi Matsuda, MD, PhD
JAPAN



David Anthony Parker, MBBS,
BMedSci, FRACS
AUSTRALIA

The case is clearly a complex one and there are some details which are incomplete, making definitive recommendations difficult. In particular, we are not clear on the patient's alignment, whether or not the knee is stiff or has a good functional range of motion, and whether or not the equinus deformity is fixed or correctable. The nerve injury is described as a “sciatic nerve palsy below knee” which presumably means common peroneal and tibial nerve injuries at the level of the knee. The functional recovery of the other knee is not described. Further clarification of these issues would be important before definitive advice is given, but some general recommendations can be made.

For the purpose of these recommendations, we will assume that the other knee has had a good functional recovery, and that the knee in question has a good range of motion, but with significant residual bicruciate and posterolateral laxity. There appears to be complete motor function loss of common peroneal nerve, possibly contributed to by the compartment syndrome, some sensory recovery, and partial recovery of tibial nerve. We are told the equinus deformity is flexible. We are not aware of the time post injury now, but let us assume it is approximately 6 months.

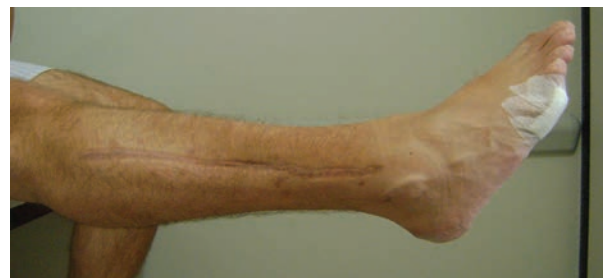QUESTIONS SUBMITTED

What goes first in an unstable knee with a neurological equinus foot? Reconstruction of equinus or knee reconstruction?

With the acute injury it is important to splint the foot to avoid a fixed equinus contracture, and this should be continued either until nerve recovers or is addressed surgically usually with a tendon transfer. If there is a tibial nerve palsy, then this transfer would just be a static tenodesis. If the knee is operated, particularly in the acute setting, the nerve can be explored to help guide prognosis. Time to demonstrate recovery can be as long as 9–12 months so this should be observed before deciding on tendon transfer, and splinted to avoid contracture developing during this period. If a fixed equinus deformity has developed then this should be addressed by TA release and subsequent splinting. Otherwise the knee reconstruction should be addressed first.

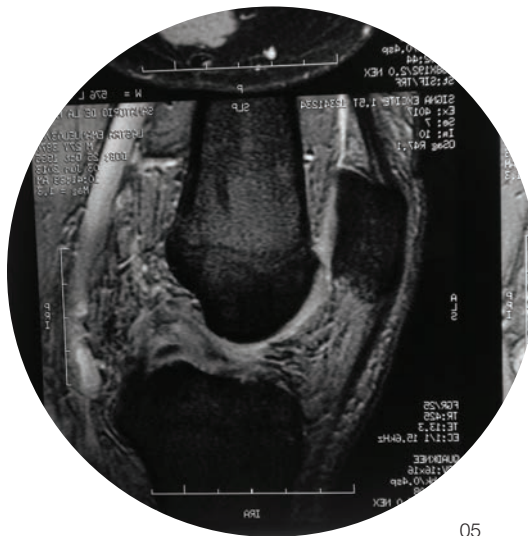
If you have a vascular reconstruction, how do you perform knee surgery? Tourniquet or not. Also, what are your thoughts about the nerve palsy? In your experience will it deteriorate by ischaemia caused by a tourniquet?

A tourniquet should definitely not be used in this setting. In particular, with a previous vascular reconstruction there is a significant risk of thrombosis. The risk to the nerve is more theoretical, but is an additional factor against the use of a tourniquet. It is good practice to try and avoid use of a tourniquet in all of these multiligament injuries if possible, but particularly in those with a history of prior vascular injury.



How is the staging of knee instability surgery? Which are your choices in ligamentous reconstruction?

The general preference is for reconstruction of both cruciates as well as the lateral/posterolateral structures in the one sitting. Most critical are PCL and posterolateral reconstructions, so can leave ACL at this stage if time or graft limited. The choice of graft will often depend on what is available in the specific country, but assuming that allograft is available most would use allograft for all reconstructions. This is assuming that good quality non-irradiated allograft is available. Autograft can be considered, but would probably avoid ipsilateral hamstring harvest in the presence of previous vascular surgery, and use of BTB or contralateral hamstring would add to the trauma but could be considered if necessary. Synthetic ligament could be considered for the extra-articular component, but not for cruciate reconstruction.



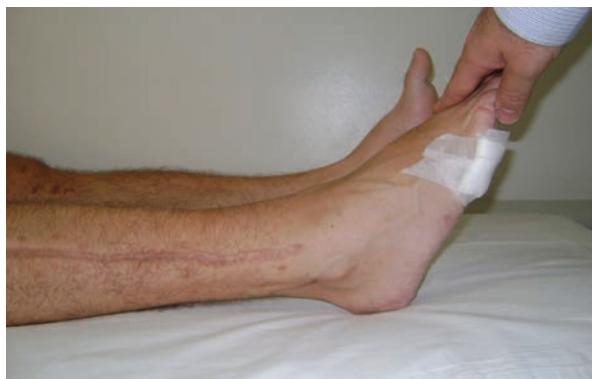05

With an equinus foot also with severe laxity what different behavior of the knee would you expect? Are the reconstructed ligaments at risk? In which cases would you suggest a varus osteotomy for the varus thrust that could cause the corrected equinus foot?

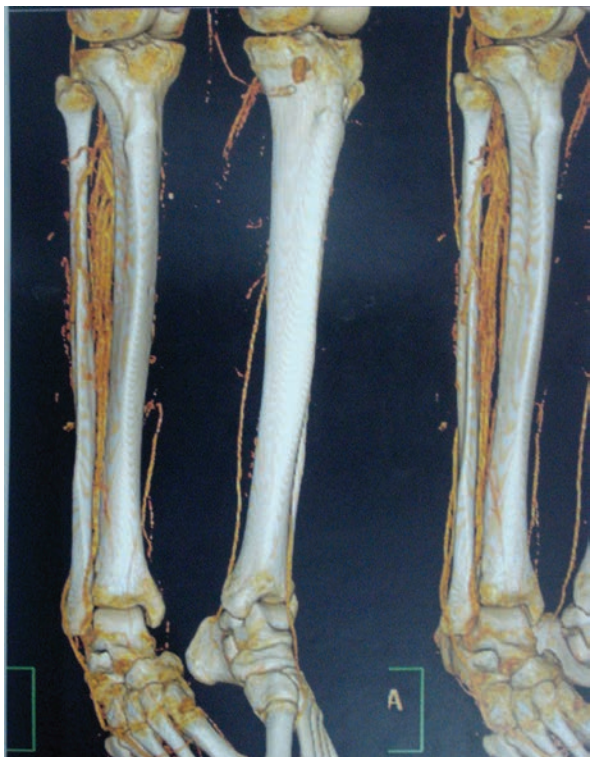This question is not entirely clear and we are not aware of the alignment or gait pattern of the patient. In general, a fixed equinovarus deformity could drive the knee into hyperextension and varus, hence the discussion about correcting or preferably preventing this in the answer above to question 1 ie a plantigrade foot should be achieved, either by splintage or surgery if necessary. An osteotomy is appropriate in cases of chronic posterolateral laxity associated with varus alignment and a varus thrust in gait, in which cases soft tissue reconstructions alone would fail. From the history supplied we suspect that and osteotomy is probably not appropriate in this case.

The case illustrates the difficulties in dealing with these injuries, which often involve multiple local and general associated comorbidities. This is why it is rarely possible to achieve normal or near normal functional recovery in this injuries despite the best management, and demonstrates the importance of clear explanations to the patient and family about the severity of the injury and expectations for outcome. Often the “treatment” also requires considerable counseling about this and likely modifications to future sporting and vocational activities.

- 03 How is the staging of knee instability surgery. Which are your choices in ligamentous reconstruction?
- 04 With an equinus foot also with severe knee laxity a what different behavior of the knee will you expect? Are the reconstructed ligament at risk? In which cases will you suggest a varus osteotomy for the varus thrust that could cause the corrected equinus foot ?
- 05 MRI showing extensive ACL PCL damage



03



04

Tip of the “Day”



James H. Lubowitz, MD
Taos, New Mexico, USA

Is there anything else?

In order to insure that a patient doesn't leave our clinic dissatisfied, or with a negative experience, it is important to do our best to be certain that all of our patient's questions are answered. However, patients may be intimidated, or for various other social or cultural reasons, afraid or reluctant to ask questions of their health care providers. Therefore, as most providers know, it is essential to make sure to ask the patient if they have questions before they leave. The tip of the day is that words are important, and after 20 years in practice, I have learned that there are better ways to achieve the goal than simply asking, "Do you have any questions?"—which is what I used to ask when I first started my practice.

The problem is that the query, "Do you have any questions?", is closed-ended, and closed-ended questions have the disadvantage of allowing people to answer only in a very narrow manner, with limited response options. In this case, patients can either ask their questions, which is our goal, or they might say, "I have no questions." However, while they might say they that have no questions, and might even think that they do not have questions, it may be that they do have concerns which they would like to discuss. In addition, some patients may lack the verbal skills or mental agility or confidence to respond with a coherent, well formulated question. Thus, over the years, I have learned and improved as a clinician, by changing what I asked at the end of the visit to, "What questions do you have?"

That's the tip of the day. “Is there anything else?”

This small change in language is subtle. The subtle difference is that "Do you have any questions?", in addition to being closed-ended in nature as above, puts a patient on the spot, and may intimidate them or give them the impression that we are trying to wrap things up. Whereas when we ask, "What questions do you have?", we give our patient a very different message, because "What questions do you have?," tells our patients that we already assume that they do have questions, and this lets our patients know that it is appropriate for patients to have questions, and that we really do care, and really do desire to answer our patient's questions.

However, "What questions do you have?," while more open-ended in that it implicitly requests a response, is still really a closed-ended question, because the possible responses are limited. And so, I learned, and improved, and changed again.

So, without further ado, the tip of the day is: Ask a patient, **“Is there anything else?”** This is an entirely open-ended question. "Is there anything else?," implicitly requests a response, and in addition, allows a wide variety, or even unlimited number of ways in which the patient may express their thoughts or concerns. After a patient is asked, "Is there anything else?," and that patient is given a chance to reply and discuss, it very unlikely that the patient will leave their visit with a feeling of dissatisfaction with the encounter. Therefore, if we want to know what a patient is thinking, or wondering, or about what they are worried, we should ask, "Is there anything else?," before we conclude the office visit.

That's the tip of the day. "Is there anything else?"

UPCOMING ISAKOS APPROVED COURSES

Football Medicine Strategies for Joint and Ligament Injuries
MiCo–Milano Congressi
Milan, ITALY

March 22–23, 2014

Chair(s): Peter Brukner and
Stefano Della Villa

For further information, please contact:

Giulia Indelicato
Tel: +39–051–2986878
Fax: +39–051–6133197
www.FootballMedicineStrategies.com

2014 57th, 58th Severance
Arthroscopy Cadaver Workshop
Anatomy Center, Yonsei University
Health System
Seoul, KOREA

April 5–13, 2014

Chair(s): Sung-Jae Kim, MD, PhD

For further information, please contact:

Se-Won Lee, MD
Tel: +82–2–2228–5679
Fax: +82–2–363–6248
www.iseveranscopy.com

XIII International Arthroscopy
Meeting–Argentina 2014
Hilton Buenos Aires Hotel
Caba, ARGENTINA

June 4–7, 2014

Chair(s): Dr. Daniel Slullitel

For further information, please contact:

Laura Espósito
Tel: +54–11–4811–2089
Fax: +54–11–4811–2389
www.artroscopia.com.ar

San Diego Shoulder 31st Annual Course:
Arthroscopy, Arthroplasty, and Fractures
San Diego Hilton Bayfront
San Diego, CA, USA

June 18–21, 2014

Chair(s): James C. Esch, MD

For further information, please contact:

Larky Blunck
Tel: +1–760–445–2874
Fax: +1–961–695–6801
www.shoulder.com

14th Amsterdam Foot and Ankle
Course 2014
AMC

Amsterdam, NETHERLANDS

June 19–20, 2014

Chair(s): Prof. Dr. C.N. van Dijk

For further information, please contact:

Rogier Gerards
Tel: +3–12–0566–2474
Fax: +3–12–0566–9117
www.ankleplatform.com

The ICRS Focus Meeting–The Knee
FIFA Auditorium Sonnenberg
Zurich, SWITZERLAND

July 3–4, 2014

Chair(s): Christoph Erggelet

For further information, please contact:

Lei Ji
Tel: +41–44–503–7373
Fax: +41–44–503–7372
www.cartilage.org/index.php?pid=203

2014 The Ligament Reconstruction
Seminar & Live Surgery in Sapporo
Faculty House “Trillium (Enreiso)” in
Hokkaido University
Sapporo, JAPAN

July 31–August 1, 2014

Chair(s): Kazunori Yasuda

For further information, please contact:

Yasuyuki Kawaguchi
Tel: +81–11–706–7211
Fax: +81–11–706–7822
www.hokudai-med-sports.org/en/index.html

Knee Dislocation and Multi-Ligament
Knee Reconstruction
Mayo Clinic
Rochester, MN, USA

September 18–19, 2014

Chair(s): Bruce Levy

For further information, please contact:

Jenna Pederson
Tel: +1–800–323–2688
Fax: 507–538–7234
www.mayo.edu/cme

Is your Course an...



12th Congress of Turkish Society of
Sports Traumatology Arthroscopy and
Knee Surgery (TUSYAD 2014 Congress)
Kaya Convention Center
Izmir, TURKEY

September 23–27, 2014

Chair(s): Halit Pinar, MD

For further information, please contact:

Emin Taskiran, MD
Tel: +90–532–416–55–46
Fax: +90–232–463–95–15
www.tusyad.org

13th Indian Arthroscopy Society
Congress
Hotel Taj Krishna
Hyderabad, INDIA

October 10–12, 2014

Chair(s): Dr. Raghuvveer Reddy K

For further information, please contact:

Dr. Raghuvveer Reddy K
Tel: +91–98–4902–9934
Fax: +91–40–2335–0696
www.ias2014.org

16èmes Journées Lyonnaises de
Chirurgie du Genou–The Young
Arthritic Knee
Convention Center
Lyon, FRANCE

October 16–18, 2014

Chair(s): Michel Bonnin, MD

For further information, please contact:

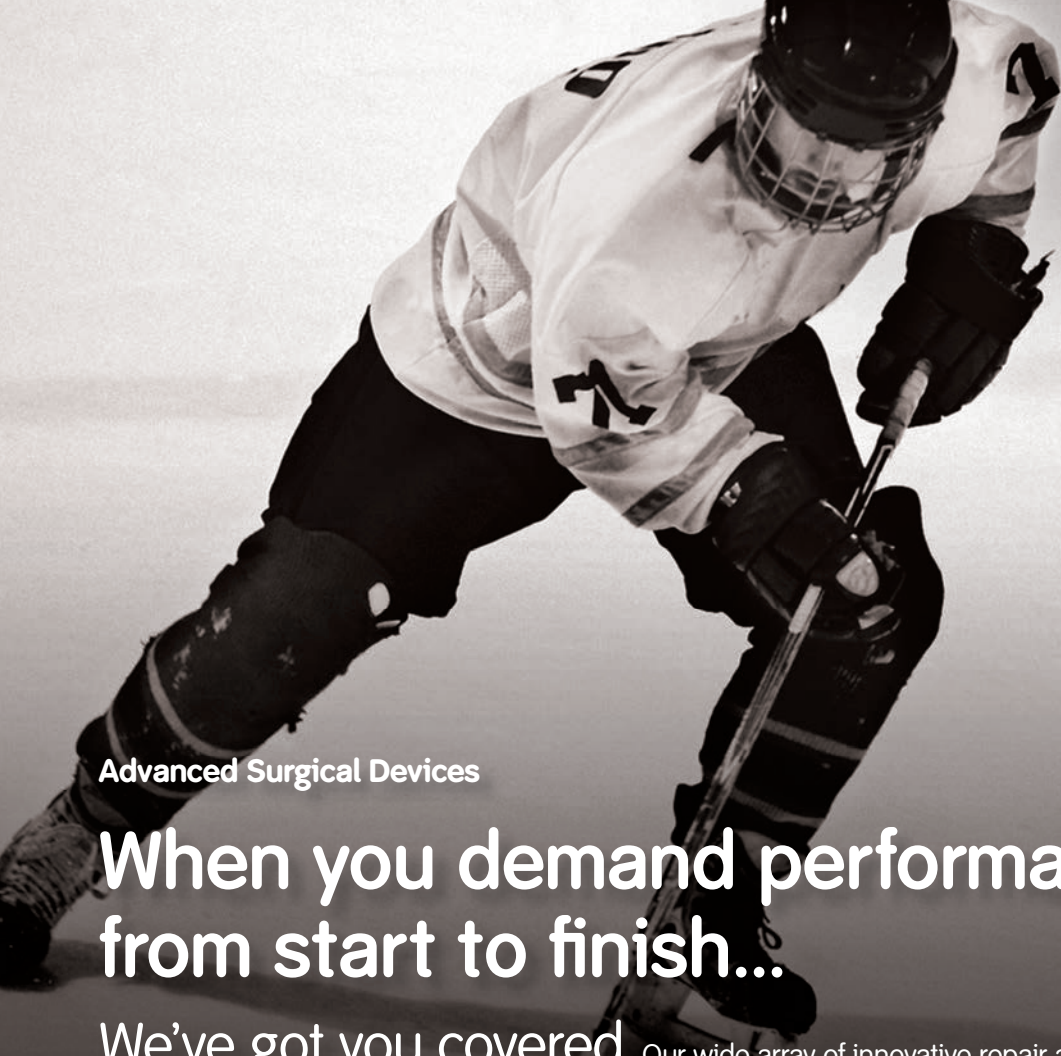MCO Congrès
Tel: +33–49–509–3800
Fax: +33–49–509–3801
www.lyon-genou.com

ISAKOS Approved Course & Teaching Center
Applications now available online!

Applications for ISAKOS Approved Courses and Teaching
Centers may now be completed online at www.isakos.com

Apply today!





Advanced Surgical Devices

When you demand performance from start to finish...

We've got you covered. Our wide array of innovative repair and replacement solutions for the knee, shoulder and hip provides surgeons with a comprehensive line of products, and accommodates a wide range of techniques. From patient positioning and fixation solutions to total joint arthroplasty, we have what it takes to overcome your specific challenges.

To learn more about our comprehensive product offerings and solutions, go to www.smith-nephew.com.

Committed to being the world's premier provider of advanced surgical devices.


HEALICOIL®
REGENESORB
Suture Anchor



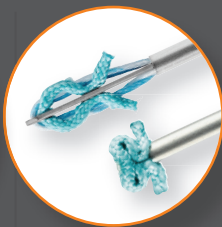
VERILAST®
Technology



PROMOS®
Modular Shoulder System



SURTUREFIX ULTRA
Suture Anchor



BIOSURE® HEALICOIL® PK
Interference Screw*



HEALICORE®
Trepine System*



*Product not for distribution in the United States and its territories.



**International Society of Arthroscopy,
Knee Surgery and Orthopaedic Sports Medicine**

2410 Camino Ramon, Suite 215
San Ramon, CA 94583-4318 USA

Telephone: +1 925 807-1197
Fax: +1 925 807-1199
isakos@isakos.com
www.isakos.com



10TH Biennial

ISAKOS
CONGRESS

2015

JUNE 7-11, 2015
LYON, FRANCE



To submit an abstract, visit www.isakos.com/2015Congress

AWARD APPLICATIONS
FOR THE 2015 CONGRESS ARE OPEN!

awards

The ISAKOS Fellowship and Awards Program is committed to recognizing and honoring researchers whose work has contributed to better understanding and communication within the fields of Arthroscopy, Knee Surgery and Orthopaedic Sports Medicine.

Presenting authors are allowed one submission per award. Additionally, each abstract may only be applied to one award.

To be considered for an Award or Fellowship, abstracts and award applications must be submitted before September 1st, 2014.