



ISAKOS

NEWSLETTER

Auckland, New Zealand, to Host 2003 Congress

SUMMER 2001

Volume 5, Issue 1

EDITOR

Stephen S. Burkhart, M.D., USA

ASSOCIATE EDITOR

Roland P. Jakob, M.D., Switzerland

EDITORIAL BOARD

Moises Cohen, M.D., Brazil
 Mark Ferguson, M.D., South Africa
 Philippe Hardy, M.D., France
 Nicola Maffulli, M.D., United Kingdom
 Peter Myers, M.D., Australia
 Mitsuo Ochi, M.D., Japan
 Fernando Radice, M.D., Chile
 Kurt Spindler, M.D., USA
 Terry Whipple, M.D., USA



Preparations are under way to bring the ISAKOS Congress back to the Asia-Pacific Region. In March 2003, ISAKOS will travel to Auckland, New Zealand, the renowned host of the 2000 and 2003 America's Cup, the proclaimed "City of Sails."

New Zealand's largest city is vibrant and clean, surrounded by subtropical islands, rainforests and shimmering harbors. Congress attendees are sure to enjoy the relaxed cafés, world-class wines, fresh seafood, sand-filled beaches and art museums. Hike, kayak, bungee jump, sail, ride horseback, bicycle ... the outdoor lifestyle of the residents of Auckland combines perfectly with the relaxed sophistication of the urban advantages of this friendly South Pacific metropolis. ISAKOS attendees will find there is much to do and that a visit to this gorgeous city and

region is well worth a long airplane ride.

Auckland alone claims 23 regional parks, 100 kilometers of coastline, 500 kilometers of walking and hiking paths and 48 volcanic cones. It has the largest concentration of Polynesian people in the world. The "Kiwis" have much to be proud of, and they are eager to welcome ISAKOS.

The ISAKOS Congress will be held at the Auckland Edge, the city's center for conventions, cultural and entertainment events. The congress hotels are all nearby, within walking distance, and no place in Auckland is ever far from the waterfront. This unpretentious city is well priced for the international traveler, and the feel of the city is that of a cosmopolitan small town. Guests will feel safe and welcome in Auckland.

Mark your calendars now – the Fourth Biennial ISAKOS Congress will take place March 10-14, 2003. (Note, this is two months earlier than usual. It does not conflict with the AAOS Annual Meeting, which will be held in February of that year.) The Call for Abstracts will be available this fall, and a Preliminary Program will be available in the fall of 2002.

We look forward to seeing you in Auckland.

INSIDE THIS ISSUE

Editor's Note	2
President's Message	2
2001 Congress Report	3
Your Committees at Work	4
2001-2003 Committee	
Members Appointed	5
Knee Committee Hosts	
Meeting in Florence	6
Symposia Summaries	7
Scenes From the 2001 Congress	12
Current Concepts: Posterior Cruciate Ligament Reconstruction	19
Upcoming ISAKOS-Approved Courses	20
Current Concepts: Modularity in Total Knee Arthroplasty	21



ISAKOS Welcomes New Members

ASSOCIATE MEMBERS

Sergio Aguirre, M.D. • Rodolfo Alonso, M.D. • Sergio Avondo, M.D. • Michel Bitar, M.D. • Paolo Bulgheroni, M.D. • Antonio Dal Poggetto, M.D. • Masataka Deje, M.D., PhD • Sanjay Desai, M.D. • Aires Duarte Jr., M.D. • Rolaudo Fabian • Paulo Faria, M.D. • Eisaku Fujimoto, M.D. • Hugo Gonzales, M.D. • Michiya Hara • Rikito Hokama, M.D. • Sadfumi Ichinohe, M.D. • Michael Iosifidis, M.D. • Takashi Kawada, M.D., Ph.D. • Kenji Kobayashi, M.D. • Hideji Kura, M.D. • Cleberson Lima • Hin Fai Lung • Leopoldo Marco, M.D. • Mihkel Mardna, M.D. • Silvio Maschke, M.D. • Ferran Montserrat, M.D. • Hany Morsy, M.D. • Hirotaka Mutsuzaki, M.D. • Hironori Numazaki, M.D., Ph.D. • Afzal Osman, F.C.S.(SA)Orth. • Stergios Papastergiou, M.D. • Dirk Petre, M.D. • Rubens Pitangueira, M.D. • Charles Ruotolo, M.D. • Esteban Santos, M.D. • Murilo Santos • Nilson Severino, M.D. • Masaki Sonoda, M.D., Ph.D. • Toshiaki Takahashi, M.D. • Hideaki Takeda, M.D., Ph.D. • Enrique Troncoso, M.D. • Yuji Uchio, M.D., Ph.D. • Bruno Walsler, M.D. • Andreas Weiler, M.D. • Ethan Wiesler, M.D. • Rogerio Winkler, M.D. • Haruyasu Yamamoto, M.D., Ph.D. • Shinichi Yoshiya, M.D. • Athanasios Zacharopoulos, M.D.

ACTIVE MEMBERS

Gustavo Acuna • Jose Alemparte • Abbas Al-Muaimry • Alberto Araujo-Alvarez • Guillermo Arce, M.D. • Pierre Bachelin, M.D. • Klaus Bak, M.D. • Fernando Barclay, M.D. • Gabriel Baron • Ariel Barrera Oro • Walter Besser, M.D. • Carlos Bianchi • Seong-Il Bin, M.D. • Emanuele Bocchieri, M.D. • Anita Boecksteiner, F.R.A.C.S. (Ortho), M.B.B.S. • Julio Botello • Lecio Bourbon, M.D. • Edward Buess, M.D. • David Caborn, M.D. • Sergio Canuto • Renato Castro, M.D. • Amit Chandratreya, FRCS • Chih-Hwa Chen, M.D. • Po-Yih Chen, M.D. • Pascal Christel, M.D. • Jaehoon Chung, M.D., PhD • Daniel Comba, M.D. • Luis Costa, M.D. • Antonio Cruz, M.D. • Mario David • Joe De Beer, M.D. • Manuel Diaz-Samada • Oscar Donadio • Jose Duarte • Richard Feinstein, M.D. • Horacio Garcia • Mark Gittins, D.O. • Alberto Gobbi, M.D. • Alvarez Golano, • Joao Gomes, M.D. • Javier Gonzalez Garcia, M.D. • Adel Hamed • Ezequiel Hidalgo, M.D. • Kotaro Ikeda, M.D. • Ernest Irha, M.D. • Yasuyuki Ishibashi, M.D. • Yasunobu Iwasaki, M.D., PhD • Varughese Jacob • Anand Jadhav, F.R.C.S., M.Ch.Orth., D.Orth. • Jose Jones • Amos Kidron, M.D. • Kyung Kim, Ph.D., • Roger Kwok, M.D. • Pablo Lacroze, M.D. • Philippe Landreau, M.D. • Miguel Laperla • Gursel Leblebicioglu, M.D. • Dong Chul Lee, Associate Professor • Young-Soo Lee, M.D., Ph.D. • Pedro Lemos, M.D. • Wilson Li, M.D. • Paulo Lobo Jr., M.D. • Sergio Maass • Pedro Machado, M.D. • Carlos Martin, M.D. • Tetsuya Matsuura, M.D. • John May • David McAllister, M.D. • Marco Merlo, M.D. • Ernst-Otto Muench, M.D. • Edward Nebel, M.D. • Roberto Negrin Vynreister, M.D. • Lei Ni, M.D. • Tahir Ogut, M.D. • Juraci Oliveira, M.D. • Margaret Olmedo, M.D. • Alejandro Orizola, M.D. • Ilhan Ozkan, M.D. • Vicente Paus • Ehud Rath, M.D. • Antonio Rosato • Nahum Rosenberg, M.D. • Ruben Ruiz • Christoph Saager, M.D. • Valdet Saciri, M.D. • Marc Safran, M.D. • Guillermo Sagasta, M.D. • Jose Serbino Jr., M.D. • Sahir Shaikh, M.D. • Carlos Silva, M.D. • Emir Soendoro, M.D. • Kevin Speer, M.D. • Klaus Steinbrueck, M.D. • Carlos Stierling • Yoshitsugu Takeda, M.D., Ph.D. • Omer Taser, M.D. • Christopher Tong • Carlos Vandeputte, M.D. • Robert Verklon, M.D. • Carlos Vottola • Nobuyuki Yoshino, M.D., Ph.D. • Giovanni Zaccherotti, M.D. • Oscar Zicaro

FROM OUR LEADERSHIP

Editor's Note

Stephen S. Burkhart, M.D., San Antonio, Texas, USA, ISAKOS Newsletter Editor



I have recently returned from a truly remarkable orthopaedic meeting in one of the world's most beautiful locations; a venue that far surpassed the already high expectations of the orthopaedic pilgrims who traveled from around the world to attend. It was a scientific assembly that achieved

new highs in education, entertainment and fellowship. For those of you who attended, you already know that I am referring to the ISAKOS Congress in Montreux, Switzerland. For those who were unable to attend, I offer my condolences – you missed a good time.

From an educational perspective, the program was outstanding. The quality of the papers, symposia and instructional courses was very high. The program format of multiple lecture halls allowed for maximum flexibility of physicians to attend lectures of


interest, and the crisp digital presentation format optimized the impact of each paper.

All of this was orchestrated in a seemingly effortless and seamless manner. Effortless though it seemed, I can assure the reader that the smoothness of execution was the result of continual hard work by a number of key people who deserve credit and recognition: our President, Roland Jakob, MD, who inspired us with his presidential address and who, I am sure, never fully relaxed until the end; Program Chairman Per Renström, who prepared a tremendous educational event and who carefully watched over every detail the entire time; our talented and tireless Executive Director Michele Johnson and her associates Kathryn Grady and Gigi Agius, who put the ideas together and “made it all happen”; and the digital audiovisual team of Bill Masheter, Mark Rosenthal and Alan Dwan, who created ultimate digital serenity from the pandemonium of the speaker ready

Continued on page 20

President's Message

Barry R. Tietjens, F.R.A.C.S., Auckland, New Zealand, 2001-2003 ISAKOS President



Greetings to my friends and colleagues from Auckland, New Zealand, venue for our next congress. We have not long ago returned home from Montreux, Switzerland, where the 2001 ISAKOS Congress was an outstanding success. More than 1300 surgeons from

66 countries attended our largest meeting to date. The picturesque setting of lakeside Montreux was a perfect venue. The scientific program was very strong and well-received. The President's Dinner at the Chillon Castle and the Farewell Banquet at the Nock Circus were unforgettable.

Our heartfelt thanks go to Roland and Jeanette Jakob, our hosts in Switzerland. Roli's leadership over the last two years has been inspirational. His passionate commitment to ISAKOS has led to greater awareness and recognition of our society in all corners of the world. Membership has grown past

1500 and our future is secure.

The strength of our society comes first from our biennial congress and we must all pay tribute to Per Renström, M.D., Ph.D., Program Chairman, and his team for the outstanding scientific and educational program in Montreux. I am delighted that John Bartlett from Melbourne, Australia, will be Program Chairman for the 2003 Congress in Auckland. We will make every effort to build on the success of our last meeting.

I am committed to developing more benefits for members between each biennial congress. Our Education Committee has already made progress with ISAKOS-approved teaching centers and ISAKOS-approved courses. Last year the Knee Committee held a workshop focused on total knee replacement in the relatively young and active patient with osteoarthritis. This led to a symposium on the topic at the 2001 ISAKOS Congress and the publication of workshop presentations in a booklet distrib-

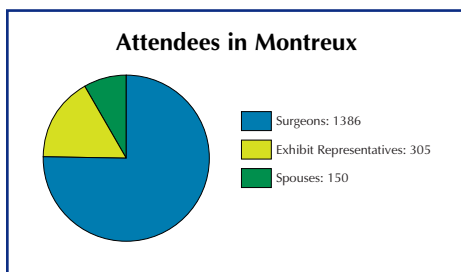
Continued on page 4

2001 CONGRESS REPORT

Attendees Make Montreux a Success

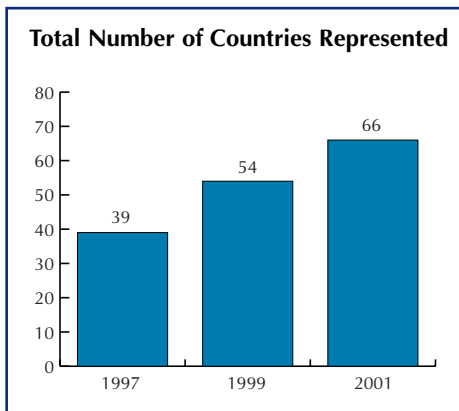
Continued Growth Expected: 98% of Evaluations Say Attendees "Would Recommend This Congress to Colleagues"

The 2001 ISAKOS Congress was the largest and most well-received to date, as 1,386 orthopaedic surgeons convened in Montreux for the five-day scientific program chaired by Per Renström, M.D., Ph.D., Sweden. An array of "optional events," from tours to banquets, kept attendees busy into the evenings throughout the week.



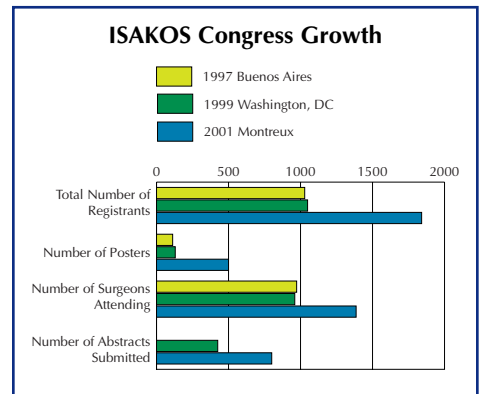
More Countries Attend Than Ever Before

Sixty-six countries were represented in Montreux, the greatest number to date.



Continued Growth From 1997 & 1999

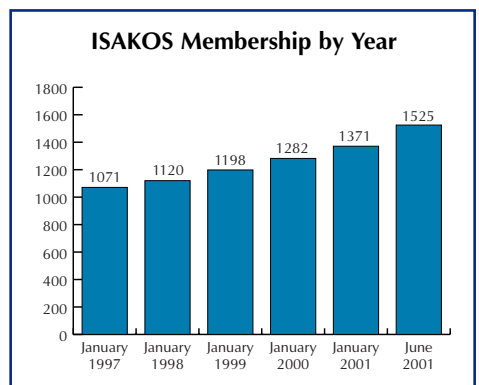
The 2001 ISAKOS Congress was a hallmark of growth as congress registrations continued to climb. More than 800 abstracts were submitted for consideration for the 2001 Congress. This was a steep jump from the 1999 congress, where 400 abstracts had been submitted. Surgeon attendance grew by 400, and poster submissions jumped, from 150 at the 1999 Congress to almost 500 in Montreux.



Attendance By Country					
Argentina80	India6	Puerto Rico2
Australia35	Indonesia3	Romania3
Austria13	Iran4	Russian Federation1
Belgium35	Israel29	Saudi Arabia7
Brazil65	Italy99	Singapore3
Canada15	Japan111	Slovak Republic2
Chile31	Korea3	Slovakia1
China7	Kuwait2	Slovenia10
Croatia2	Latvia6	South Africa17
Czech Republic7	Lebanon2	South Korea28
Denmark10	Liechtenstein1	Spain29
Egypt5	Lithuania1	Sweden37
England1	Luxembourg1	Switzerland115
Estonia2	Malaysia3	Taiwan5
Finland17	Martinique1	Thailand9
France49	Mexico4	Tunisia1
Germany48	Netherlands20	Turkey35
Greece48	New Zealand7	United Kingdom54
Guatemala1	Norway3	Uruguay2
Holland1	Peru1	USA163
Hong Kong3	Poland12	Venezuela5
Hungary1	Portugal23	Yugoslavia3

ISAKOS Membership Grows

ISAKOS membership continues to climb. More than 85 membership applications were collected in Montreux, and more are expected.



2003 Call for Abstracts Available Online in October

The Call for Abstracts for the 2003 ISAKOS Congress in Auckland, New Zealand, will be available on the ISAKOS Web site in October 2001. Abstract submissions will only be accepted online. The deadline for receipt of abstracts is April 1, 2002.

Society Communications Continue to Expand

Don Johnson, M.D., Ottawa, Ontario, Canada, 2001-2003 Communications Committee Chairman

The very successful meeting in Montreux was a sign of the current strength of membership and the future of ISAKOS. This is an international organization that makes one proud. The number of papers and the excellent symposia presented are a tribute to the Program Committee and to the faculty who presented. The international flavor of the venue was evident and made the meeting unique. This clearly is one of the meetings to attend in the future.

The Communication Committee is hoping to make it easier for you to reach your colleagues with a new initiative, the ISAKOS *Mailing List*. This will be a list serve that any ISAKOS member with an e-mail address can subscribe to. This service will only be available to members, not to patients who want to have their medical problems solved online. When any member has a clinical,

sports medicine, arthroscopy or knee problem that they would like an opinion on from the members, they can e-mail a brief note to ISAKOS, and that question will be sent to all members who have an e-mail address. Anyone who would like to reply can simply type a reply and have his opinion sent to everyone on the e-mail list. This stimulates great discussion, is easy to do, and can be as helpful as presenting a case at rounds. You will be receiving an e-mail when this service is available. Remember to keep the office informed of your new e-mail address.

The newsletter will continue to grow: this issue features the summaries of the symposia, one of the main attractions of the Montreux meeting.

The ISAKOS Web site has a link to the *Arthroscopy* journal, where the abstracts from the Montreux meeting have been posted.

Multi-Center Studies to Commence

The Arthroscopy Committee will conduct multi-center studies in the following areas:

- Endoscopic Apex Resections for Infrapatellar Tendinitis;
- Arthroscopic Treatment of Osteochondromatosis of the Hip; and
- Revision Arthroscopy After Meniscectomy.

ISAKOS Members who are interested in participating should contact Andre Frank, 2001-2003 Arthroscopy Committee Chairman, at awfrank@wanadoo.fr.

Fort Lauderdale, Florida, Chosen as 2005 Meeting Site

The Site Selection committee has chosen a stunning new resort property in Fort Lauderdale, Florida, USA, for the 2005 ISAKOS Congress.

The 2005 Congress will be held from April 9-13, 2005. The Saturday-Wednesday meeting pattern will allow surgeons to attend without missing many days of work.

The Diplomat Hotel, site of the 2005 congress, is set to open in January 2002. It is a

modern, lavish hotel and conference center that boasts 1,000 guest rooms and thousands of square feet of meeting space. Its beachfront location, comprehensive health spa, private cabanas, two swimming pools, and adjoining country club will allow congress attendees to enjoy the advantages of a resort property when not attending conference sessions.



President's Message

(Continued from page 2)

uted to everyone who attended the congress. Over the next two years all the clinical and scientific committees will be working on projects to benefit all members of ISAKOS.

During the 2001 ISAKOS Congress, an international leaders' meeting was held under the banner of the World Council of Orthopaedic Sports Medicine, ably chaired by Rene Verdonk. It was agreed that in the future ISAKOS will host an International Presidents' Council, which will bring together leaders of the major continental societies

from North America (AOSSM and AANA), Europe (ESSKA), South America (SLARD) and the Asia-Pacific region (APOSSM, APOA). ISAKOS will maintain and publish on our Web site a meeting schedule to avoid clashes of major meetings. This council will continue to foster relationships between these major organizations.

The Executive Board met with the Board of Trustees of the journal *Arthroscopy* under the chairmanship of Jerome Jennings. Our goal is to strengthen the relationship between ISAKOS and our official journal for the benefit of all members of ISAKOS.

The Executive Board also held preliminary

discussions with industry leaders to establish an education fund for ISAKOS. As soon as we can improve our financial resources, we can, through our committee structure, develop more educational activities for ISAKOS members between each biennial congress. In November the Executive Board will be meeting again with the journal's Board of Trustees and also with industry leaders.

It is a great honour for me to lead ISAKOS through to the next congress. I am proud to represent my country and the Asia-Pacific Region. I shall do my very best to climb carefully on the shoulders of the great leaders who have gone before me.

2001-2003 Committee Members Appointed

BOARD OF DIRECTORS

Executive Board

Barry R Tietjens, President, *New Zealand*
Per A Renstrom, 1st Vice President, *Sweden*
John A Bergfeld, 2nd Vice President, *USA*
Don H Johnson, Secretary, *Canada*
Kai-Ming Chan, Treasurer, *Hong Kong*
Freddie H Fu, Vice Treasurer, *USA*
Roland P Jakob, Past President, *Switzerland*

Members-at-Large

F Alan Barber, *USA*
John Bartlett, *Australia*
Gilberto Luis Camanho, *Brazil*
Ramon Cugat, *Spain*
M Nedim Doral, *Turkey*
Mark Ferguson, *South Africa*
Andre Frank, *France*
Anastasios Georgoulis, *Greece*
Masahiro Kurosaka, *Japan*
Mitsuo Ochi, *Japan*
Alberto Pienovi, *Argentina*
W Jaap Willems, *Netherlands*

ARTHROSCOPY

Andre Frank, Chairman, *France*
Romain Seil, Deputy Chairman, *Germany*
J.W. Thomas Byrd, *USA*
Rodolfo Carpignano, *Argentina*
Ezequiel C. Hidalgo, *Venezuela*
Bent Wulff Jakobsen, *Denmark*
Hideshige Moriya, *Japan*
Halit Pinar, *Turkey*
Niek van Dijk, *Netherlands*
Eduardo Zamudio, *Chile*

BYLAWS

Per A Renstrom, Chairman, *Sweden*
John A Bergfeld, Deputy Chairman, *USA*
James Chiu-Yung Chow, *USA*
Moises Cohen, *Brazil*

COMMUNICATIONS

Don H Johnson, Chairman, *Canada*
F Alan Barber, Deputy Chairman, *USA*
Vladimir Bobic, *United Kingdom*
Fernando Radice, *Chile*
Ronald M Selby, *USA*

EDUCATION

W Jaap Willems, Chairman, *Netherlands*
Torsten Wredmark, Deputy Chairman, *Sweden*
Ramon Cugat, *Spain*
James C Esch, *USA*
Vicente Gutierrez, *Chile*
Hideo Matsumoto, *Japan*
David V Rajan, *India*

FINANCE

Kai-Ming Chan, Chairman, *Hong Kong*
Freddie H Fu, Deputy Chairman, *USA*
John A Bergfeld, *USA*
Roland P Jakob, *Switzerland*
Don H Johnson, *Canada*
Per A Renstrom, *Sweden*
Barry R Tietjens, *New Zealand*

KNEE

Paolo Aglietti, Chairman, *Italy*
James Rand, Deputy Chairman, *USA*
David Stuart Barrett, *United Kingdom*
Michael A Kelly, *USA*
Tomihisa Koshino, *Japan*
Urs Munzinger, *Switzerland*
Philippe Neyret, *France*
Mitsuo Ochi, *Japan*
Paulo Roberto Rockett, *Brazil*
Michael Soudry, *Israel*

MEMBERSHIP

Moises Cohen, Chairman, *Brazil*
Jose Mario Beca, *Portugal*
Walton W Curl, *USA*
Mark Ferguson, *South Africa*
Kyosuke Fujikawa, *Japan*
Robert Wen-Wei Hsu, *Taiwan*
Dieter M Kohn, *Germany*
Luis A Vargas, *USA*

ORTHOPAEDIC SPORTS MEDICINE

Annunziato Amendola, Chairman, *Canada*
Peter T Myers, Deputy Chairman, *Australia*
Arnaldo Jose Hernandez, *Brazil*
Jose F Huylebroek, *Belgium*
Hartmut E A Krahl, *Germany*
Joao Alves Grangeiro Neto, *Brazil*
Hans H Paessler, *Germany*
Christer Rolf, *United Kingdom*
Kurt P Spindler, *USA*

PROGRAM

John Bartlett, Chairman, *Australia*
Christopher D Harner, Deputy Chairman, *USA*
Rene Jorge Abdalla, *Brazil*
Paolo Aglietti, *Italy*
Annunziato Amendola, *Canada*
Stephen S Burkhart, *USA*
M Nedim Doral, *Turkey*
Lars Engebretsen, *Norway*
Andre Frank, *France*
Anastasios Georgoulis, *Greece*
Stephen M. Howell, *USA*
Alexandra Kirkley, *Canada*
Masahiro Kurosaka, *Japan*
Anthony Miniaci, *Canada*

Alberto Pienovi, *Argentina*
Per A Renstrom, *Sweden*
Konsei Shino, *Japan*
Russell JA Tregonning, *New Zealand*
W Jaap Willems, *Netherlands*
Savio L-Y Woo, *USA*

SCIENTIFIC

Alexandra Kirkley, Chairman, *Canada*
Nicola Maffulli, Deputy Chairman,
United Kingdom
Lars Engebretsen, *Norway*
Robert J Johnson, *USA*
Jon Karlsson, *Sweden*
Jaime Mayer Wageck, *Brazil*
Savio L-Y Woo, *USA*
Kazunori Yasuda, *Japan*

SITE

Roland P Jakob, Chairman, *Switzerland*
John A Bergfeld, Deputy Chairman, *USA*
Peter J Fowler, *Canada*
Don H Johnson, *Canada*
Gary G. Poehling, *USA*
Barry R Tietjens, *New Zealand*

STRATEGIC PLANNING

Gary G. Poehling, Chairman, *USA*
Wahid Al-Kharusi, Deputy Chairman, *USA*
John A Bergfeld, *USA*
Gilberto Luis Camanho, *Brazil*
Brian H Casey, *Australia*
Walton W Curl, *USA*
David J Dandy, *United Kingdom*
Kenneth E De Haven, *USA*
Freddie H Fu, *USA*
M Mike Malek, *USA*
Gideon Mann, *Israel*
John B McGinty, *USA*
Konsei Shino, *Japan*
Rene E Verdonk, *Belgium*

UPPER EXTREMITY

Stephen S Burkhart, Chairman, *USA*
Philippe P Hardy, Deputy Chairman, *France*
James J Lam, *China*
Mario Victor Larrain, *Argentina*
Daniel Adolfo Slullitel, *Argentina*
Kevin P Speer, *USA*
W Jaap Willems, *Netherlands*

Knee Committee Hosts Meeting in Florence:

Total Knee Replacement in Relatively Young Patient With Osteoarthritis Generates Discussion and Consensus

James Alan Rand, M.D., USA, 2001-2003 Knee Committee Deputy Chairman

The Knee Committee of ISAKOS met in Florence, Italy on January 11 to January 13, 2001 to discuss the issues of management of the young patient under age 55 with unicompartmental tibial femoral arthrosis. After extensive presentations and deliberation, a consensus has been reached.

Osteotomy

Patient selection and surgical technique are critical factors to obtain an optimal result following tibial osteotomy. Patients selected for osteotomy should be of physiological age of less than 60 to 70 although, occasionally, an older patient may be selected. Both men and women can be selected for osteotomy, although men are usually preferred due to the concerns about cosmesis in women. Individuals who prefer heavy activities, such as laborers or farmers, are better selected for osteotomy than arthroplasty. Those individuals who wish to continue with high recreational activities, which include impact loading sports or rapid directional change, are better candidates for osteotomy than arthroplasty.

The patient should have pain localized to the diseased compartment. Radiographs should show Ahlback grade 1 to 3 arthrosis. Malalignment should not exceed 10 to 15 degrees of varus or valgus. AP laxity of the knee should be less than 5 to 10 mm and medial lateral laxity less than 10 degrees. Range of motion should be no more than a 10-degree flexion contracture and flexion should be at least 90 degrees.

Relative contraindications to osteotomy would be significant patellofemoral pain, advanced patellofemoral arthritis on radiographs, night or generalized pain.

Patient expectations following osteotomy should include moderate to good pain relief, continued ability to participate in laboring activities and impact loading sports. Cosmesis is fair. The durability of the osteotomy should be at least 60 percent survival at ten years, but can be considerably longer, if ideal alignment is achieved. Morbidity associated with osteotomy is moderate with a six month rehabilitation time.

Options for osteotomy include closing wedge proximal tibial or distal femoral osteotomy, opening wedge, or occasionally unicompartmental osteotomy to correct fracture malunion. The patient with severe axial malalignment may require osteotomy in the distal femur and proximal tibial as a combined procedure. The importance of over correcting limb alignment in the varus knee, such that the mechanical axial of the limb falls in the lateral compartment was emphasized. In the case of valgus deformity, correction should be to 180 degrees, not overcorrection as is done for valgus osteotomy for medial compartment disease. Some of the committee members felt that minimizing joint line obliquity during osteotomy was important. In the management of valgus deformity, it is extremely important to avoid joint line obliquity; therefore, distal femoral varus osteotomy is preferred to proximal tibial varus osteotomy.

Unicompartmental Total Knee Arthroplasty

The patients selected for unicompartmental total knee arthroplasty are generally over the age of 40. Females and males can both be treated, but the female is more likely to be selected for unicompartmental arthroplasty than osteotomy to avoid cosmetic concerns associated with the extent of correction necessary for a good result after osteotomy. The patients selected for unicompartmental arthroplasty should be sedentary or only involved in light labor.

Ideally, the patient with unicompartmental arthroplasty has pain localized in the diseased compartment. Radiographs should show Ahlback grade 1 to 3 arthrosis. Malalignment should not exceed 15 degrees. AP laxity should be less than 5 mm and the anterior cruciate ligament should be intact at the time of surgery. Medial lateral laxity should be less than 10 degrees. Range of motion should be no more than a 15 degree flexion contracture and at least 90 degrees of flexion.

Relative contraindications to unicompartmental total knee arthroplasty would be significant patellofemoral pain or advanced patellofemoral arthritis on radiographs.

The patient can expect good pain relief with return to limited non-impact sports. Cosmesis following unicompartmental arthroplasty is good, although the morbidity is moderate. The durability of unicompartmental arthroplasty was debated. Some committee members felt that the unicompartmental arthroplasty should be considered as a pre-total knee arthroplasty and would accept a duration of function of up to 5 to 10 years. Other members felt that well-performed unicompartmental arthroplasty can provide very durable results with a greater than 90 percent success rate at 10 years. The ability to perform a mini-invasive surgical exposure for unicompartmental arthroplasty in both flexion and extension was extremely important to obtain a satisfactory result.

Total Knee Arthroplasty

Patients selected for total knee arthroplasty are generally older than 60 but younger patients may be candidates if they have severe tricompartmental arthrosis. Either gender may be selected for knee arthroplasty. Patients selected for total knee arthroplasty should be sedentary in occupation and only participate in light recreational activities. Impact loading sports should be discouraged. Patients selected for total knee arthroplasty should have severe pain. Generalized or night pain is common in this group of patients. The radiographic extent of the arthritis should be Ahlback grade 3 to 4. Any degree of varus or valgus malalignment can be appropriately treated with TKA. Total knee arthroplasty is able to manage laxity, flexion contracture, patients with limited flexion, and patellofemoral degenerative arthritis. In the young patient, the patella should not be resurfaced if the cartilage damage is mild. The patella is congruent with the femoral component and tracks correctly.

The patient's expectations would include good pain relief, limited non-impact sports, and fair to good cosmesis. The morbidity after total knee arthroplasty is moderate, but the results are durable with 90 percent success rate after 10 to 15 years.

SYMPOSIA SUMMARIES

HOW I DO PRIMARY TOTAL KNEE ARTHROPLASTY

Chairman: James Alan Rand, MD, USA

Faculty: David Stuart Barrett, MD, United Kingdom; Richard Laskin, MD, USA; Michael Soudry, MD, Israel; Shinro Takai, MD, Japan; Russell E. Windsor, MD, USA

The ISAKOS Knee Committee presented a Symposium in Montreux on May 15 titled "How I Do a Primary Total Knee Arthroplasty."

Dr. Laskin and Dr. Aglietti debated the issue of preoperative planning and templating. The routine use of templating for the patient without prior existing deformity is probably unnecessary as the bone is measured intraoperatively. However, in the case of prior fracture deformities, ipsilateral hip replacement, unusual deformities, or if there is a need for use of long stems, templating should be performed for these difficult patients to avoid problems with implant fitting at the time of surgery.

Dr. Barrett and Scuderi reviewed the role of different exposures in primary knee arthroplasty. The anteromedial approach is utilitarian and can be used for most patients. Alternative exposures of midvastus or subvastus approach may result in decreased pain and faster rehabilitation but they reduce overall exposure and run the potential risk of injury to neurovascular structures. They should be limited to the thin patient who has non-inflammatory arthritis and good range of motion.

Drs. Aglietti and Windsor reviewed the issue of PCL retention versus sacrifice. If the posterior cruciate ligament is retained it must not be excessively tight. A controlled release of the PCL can assist with balance. The knee must remain balanced throughout the range of motion both in flexion and extension to prevent abnormal kinematics with posterior polyethylene wear or knee instability. An alternative technique is to substitute for the posterior cruciate ligament, providing controlled roll-back to improve knee motion. Excellent long-term results have been achieved with posterior stabilized knees with no osteolysis or loosening in 101 knees at 10 years.

Drs. Scuderi and Rand discussed the issues of intramedullary versus extramedullary alignment for knee replace-



ment. For femoral intramedullary alignment the entrance hole is critical, being just medial to the notch and just above the posterior cruciate ligament. Longer intramedullary guide rods are better than shorter and are probably more reliable than extramedullary alignment landmarks on the femur. On the tibial side, extramedullary alignment is usually just as accurate as intramedullary alignment because of the subcutaneous position of the tibia. Intramedullary alignment of the tibia should be avoided in knees with valgus bowing. On the femoral side in cases of prior fracture or internal fixation device, extramedullary alignment may be required. The accuracy of extramedullary alignment on the femoral side can be improved by placing a radiographic marker over the femoral head prior to surgery.

Drs. Windsor and Barrett discussed the sequence of bone preparation. Preparing the femur first is easy because visualization is good and allows soft tissue balancing prior to bone cuts. Femoral implant orientation will be based on the bony anatomy with the epicondylar axis being a useful technique for rotational alignment. By preparing the femur first, the joint line and appropriate soft tissue balance can be maintained by a measured resection technique. By preparing the tibia first and then using a tensor, it is possible to achieve correct implant rotation and balance of the flexion space. This avoids problems of flex-

ion extension space mismatch or the need to recut the distal femur after preparing the knee using a measured resection technique.

Drs. Takai, Soudry and Laskin discussed the issue of rotational alignment of the femoral component and the best technique. The epicondylar axis provides the optimal functional axis of the knee and is little influenced by bony deformity. It is applicable to all primary and revision knees including those with varus or valgus deformity. Multiple studies have shown that the angle between the posterior condylar axis and the epicondylar axis are between 3 and 6 degrees allowing for proper balance of the flexion space. The advantage of using the posterior condyle for rotational alignment is that they are easily identified. The posterior condyles cannot be used reliably if they are deficient, which commonly occurs in the case of a valgus knee. The AP axis of Whiteside, using the center of the trochlear groove, is another excellent technique for rotational alignment. The trochlear groove, however, is deficient in up to 20 percent of patients with arthritis undergoing knee replacement and cannot be used in these individuals. Using the flexion space for rotational alignment after resection of the tibia provides an excellent way to balance the flexion space provided that any residual soft tissue contractures have been released. The best approach is to use a combination of all of these rotational positioning techniques to insure proper femoral component

rotation.

Drs. Rand and Windsor discussed the issue of tibial component rotational alignment. Rotational options include the tibial tubercle using the transmalleolar axis, aligning it congruent with the femoral component with the knee in extension, or to rotate off the posterior aspect of the tibia. All these techniques can work reasonably well for low conforming articulations. In more conforming articulations, a closer rotational alignment between the femoral and tibial component are required in order to maximize contact areas and provide optimal mechanics. In these knees, careful rotation of the tibial components referable to femur is essential.

Drs. Aglietti and Laskin discussed the assessment of soft tissue balance. Spacer blocks, trials, and tensors can all be utilized to assess soft tissue balance. An equal flexion extension space must be the goal throughout a range a motion not just at 90 degrees and 0 degrees. It is extremely important neither during the soft tissue balancing process not to place the knee in excessively tight, which will limit motion, nor to place it in lax, which can result in symptomatic instability.

Drs. Soudry and Windsor discussed soft tissue balancing for the varus knee. The first step in balancing the varus knee is removal of osteophytes from beneath the collateral ligaments. In most knees release of the deep portion of the medial collateral ligament from the tibia and, if necessary, the posterior medial corner of the knee will result in soft tissue balance. Releases should be done in a staged manner with assessment of soft tissue balance between each stage of the release. The pes anserine tendons are generally left intact to provide some intrinsic stability on the medial side of the tibia. Medial epicondylar osteotomy is an advantage in the severe varus knee and is done by release with an osteotomy leaving the periosteal and soft tissue attachments intact proximally. The epicondylar osteotomy is repaired with sutures and has provided 83 percent good or excellent results.

Drs. Laskin and Aglietti discussed the issue of soft tissue balancing for the valgus knee. The technique of balancing the knee with valgus deformity has evolved from

striping of the lateral femoral condyle attachments of the popliteus and fibular collateral ligament to release of the capsule from the tibia with multiple pie crusting of the posterior lateral capsule. The pie crusting technique has the advantage of gradual release and reduced risk of flexion instability. Selective release of the valgus knee should be considered based on the extent of deformity. If the knee has fixed valgus only in extension but the valgus is passively correctable in flexion, only the IT band and posterior lateral capsule need to be released. If the knee is fixed both in flexion and extension then the fibular collateral ligament and popliteus will need to be released from the lateral femoral epicondyle. The IT band may need to be released in the case of severe contracture as a final step. The PCL can be retained in many valgus knees and will provide some intrinsic stability. One must be careful to do all releases in the valgus knee sequentially to prevent an excessively lax knee.

An alternative in the elderly low demand patient may be simply to do no releases and use a more constrained prosthesis to provide intrinsic stability in place of soft tissue balancing.

Drs. Soudry, Scuderi and Rand discussed the issue of patellar resurfacing. Dr. Soudry felt that patellar resurfacing was not necessary if the patella had good articular cartilage and tracked congruently with the femoral component, especially in the younger patient requiring knee arthroplasty. If patellar bone is insufficient, then patellar resurfacing should not be attempted. In the patient with patellofemoral arthritis or inflammatory arthritis, patellar resurfacing should be utilized. Patellar resurfacing should be performed if there is severe damage to the articular cartilage of the patella, patellar maltracking or lack of congruence between the patellar geometry and the geometry of the trochlear aspect of the femoral component. During patellar resurfacing it is important not to thicken the resurfaced patellar composite over its preoperative value and to ensure absence of patellar tilt or subluxation. The use of an inset patella should be considered in those cases of patellofemoral arthritis with a concave patella and appears to provide less tilt and less subluxation that those knees in

which an onlay patellar design is utilized. The inset patellar has the disadvantage of providing less coverage of the patellar bone compared to an onlay patellar implant.

In summary, there are multiple important steps in knee replacement including correct alignment of the implants in the coronal, sagittal and transverse planes, restoration of the joint line and soft tissue balance that are critical to achieving optimum results. The selection of posterior cruciate retention, sacrifice or substitution should be dependent on the patient's anatomy and the ability of the surgeon to correct the deformity.

PCL SURGERY

Chairman: John Bartlett, Australia

Faculty: Christopher D. Harner, USA; Konsei Shino, MD, Japan

John Bartlett described the anatomy of the PCL and its broad attachment to the medial femoral condyle, with the isometric point being mid-way along a line drawn parallel to Blumensaat's line from the widest part of the medial femoral condyle posteriorly. The antero lateral part of the PCL is tight in flexion and three times stronger and stiffer (1120N, 120N/mm) than the posteromedial part (419N, 57N/mm). The menisco femoral ligaments also contribute to the posterior stability (297N, 49N/mm).

Other structures resisting posterior translation and external rotation include the lateral co-lateral ligament (750N) and the popliteo fibular ligament (425M). More than 10 mm of posterior drawer, instability in extension, or excessive external rotation indicates a complex and combined injury to structures other than the PCL. X-ray (including alignment, and stress views), MRI and arthroscopy all have a place in defining the pathology. The natural history of "isolated" PCL is benign, but complex lesions will be disabling and may require corrective surgery.

EVALUATION AND MANAGEMENT OF EARLY OSTEOARTHRITIS IN THE ACTIVE POPULATION

Symposium Chairman: Joseph A. Buckwalter, MD, USA

Symposium Faculty: Annunziato Amendola, MD, Canada; K.M. Chan, MD, Hong Kong; Harald Roos, MD, PhD, Sweden; Kurt P. Spindler, MD, USA

This symposium focused on methods of aiding patients with mild to moderate osteoarthritis with maintaining a high level of activity. This is an important goal, as helping these individuals allows them to enjoy life, improve their overall general health, and possibly increase their longevity.

Speakers identified a number of strategies. One strategy included avoiding activities that expose joints to a level of torsion and impact loading, possibly causing or accelerating the progression of osteoarthritis. Other strategies included weight loss, appropriate shoe wear, use of heel wedges and knee braces and the importance of muscle strengthening for treatment of mild to moderate osteoarthritis. The role of glucosamine and hyaluronan was discussed at length, as well as the role of anti-inflammatory medications and analgesics.

Presentations were given concerning the role of osteotomy in the treatment of mild to moderate osteoarthritis in patients who want to maintain a high level of activity, as well as the roles of joint debridement and abrasion. The panel agreed that the strategies for maintaining high levels of activity for patients with mild to moderate osteoarthritis should become a central part of sports medicine practice.

TREATMENT OF ROTATOR CUFF DISEASE

Chairman: Stephen S. Burkhart, MD, USA

Faculty: James Esch, MD, USA; Peter Habermeyer, MD, Germany; Philippe P. Hardy, MD, France; Kevin Speer, MD, USA

The goal of this symposium was to cover the spectrum of pathology (subacromial impingement, complete and partial rotator cuff tears, subscapularis tears, biceps

pathology) and the broad range of treatment options (open, mini-open, and arthroscopic).

Dr. Hardy gave the opening presentation on current arthroscopic techniques of subacromial decompression. He discussed a number of technical hints to enable the surgeon to perform this procedure more easily, and demonstrated the advantages of arthroscopic subacromial decompression over open techniques.

Dr. Habermeyer then discussed mini-open rotator cuff repair techniques and results, pointing out the decreased deltoid morbidity with this technique compared to standard open techniques.

Dr. Esch presented his philosophy and technique of arthroscopic rotator cuff repair, pointing out that even large and massive tears are amenable to arthroscopic repair. Following Dr. Esch, Dr. Kevin Speer discussed pathologic features of the long head of the biceps. He showed arthroscopic examples of failure of the medial "sling" or "pulley" of the biceps (composed of the superior glenohumeral ligament and coracohumeral ligament), which allowed the biceps to sublux over the superolateral border of the subscapularis, eventually causing subscapularis disruption.

Finally, Dr. Burkhart presented his technique and preliminary results of arthroscopic subscapularis repair, a technique which is the first of its kind for the subscapularis.

A panel discussion focused on specific areas of interest from the audience. It was suggested that good results can be obtained by open, mini-open, and arthroscopic techniques, but that the trend is toward greater use of arthroscopic repair.

OSTEOCHONDRITIS DISSECANS OF THE ANKLE

Chairman: K.M. Chan, MD, Hong Kong

Faculty: Andre Frank, MD, France; Mitsuo Ochi, MD, Japan; Christer Rolf, MD, PhD, United Kingdom

We began with an overview of the history of the first recognition of the condition, and proposed etiologies mentioned in the literature. The clinical features, classification systems used based on plain radi-

ographic and MRI images, and controversies regarding the natural history and clinical significance of such lesions were highlighted. For our treatment strategy, we raised the question of which parameters (clinical or radiological) should be the main consideration in decision-making.

Mitsuo Ochi demonstrated how he treated one case successfully by autologous chondrocyte transplantation into the lesion in the talus. It cannot be concluded at this stage if this should be the standard treatment since the sample size was too small and there was too short a follow-up time.

Andre Frank gave a brief introductory summary of the condition. He regarded anterolateral talar lesions as fractures and separated this group from the posteromedial group. His clinical study included a large number of osteochondral fractures resulting from Pott's fractures and he used drilling, curettage for a number of his cases. It was therefore not clear if his interpretation of ankle OCD was the same as the other speakers' or not.

Christer Rolf pointed out that osteochondral fractures resulting from Pott's fractures are different. He also queried the clinical significance of OCD found incidentally on diagnostic arthroscopy for other conditions. In fact, he believed that many of the symptoms of pain might be attributable to unrecognized syndesmosis injuries.

The treatment of OCD by mosaicplasty was not discussed in great detail although one member of the audience from Korea apparently had a reasonable amount of experience.

THE KNEE AFTER MENISCECTOMY

Chairman: K.E. DeHaven MD, USA

Faculty: C.D. Harner MD, USA; J.R. Andrews MD, USA

This symposium addressed three options for patients who continue to have significant disability and functional limitations following meniscectomy, typically due to the development of degenerative changes in that compartment.

Dr. DeHaven discussed the Collagen Meniscus Implant (currently in FDA trial in the US) as an example of tissue engineering to replace lost meniscus tissue. It is made

of reprocessed bovine collagen, induces cellular ingrowth and tissue regeneration, and is biodegradable. The indications, technique, aftercare and current update of the US FDA trial were presented. Based on the clinical and second-look arthroscopic data to date, this approach appears to have promise as a means to decrease post-meniscectomy problems in the future.

Dr. Harner discussed the role of allograft meniscus transplantation using fresh-frozen, non-irradiated allografts from young (age 15-35) donors. The important selection factors of age, localized pain after meniscectomy, state of articular cartilage (no more than moderate loss), and neutral limb alignment were stressed. Donor/recipient matching, surgical technique, aftercare and outcomes were presented. He concluded that meniscus transplantation remains a viable option in this select group of patients.

Dr. Andrews discussed the more severe end of the arthritis spectrum and compared the advantages and disadvantages of osteotomy, total knee replacement and uni-compartmental replacement. He specifically addressed the option of uni-compartmental replacement and how more recent refinements of component design, improved patient selection, stricter indications and improved techniques have improved outcomes. Current indications, contraindications and personal experience since 1997 were presented. He concluded that in properly selected patients uni-compartmental replacement is a practical alternative for the treatment of uni-compartmental arthritis of the knee.

KNEE BRACES

Co-Chairmen: Per Renström, MD, PhD, Sweden and Braden C. Fleming, PhD, USA

Functional knee braces (FKBs) are commonly used to protect the anterior cruciate ligament (ACL), to protect an ACL graft particularly during healing, and to restore function to the ACL-deficient knee. Knee bracing remains controversial. This symposium was organized to look at knee bracing from biomechanical and clinical perspectives.

Biomechanical evaluations of knee braces should be performed under weight bearing, muscle activated conditions since

athletes depend on them this way. The biomechanical questions addressed were: 1) Does a FKB protect an ACL-intact or ACL-reconstructed knee during weight bearing? and 2) Does a FKB restore normal kinematics to the ACL-deficient knee during weight bearing?

The first question was addressed by measuring the strain in the ACL-intact knee assuming that these data would be similar to a properly positioned ACL graft. Subjects were tested both with and without a brace while the knee was weight bearing (WB) or non-weight bearing (NWB) and in combination with externally applied loads (Fleming et al, *Am J Sports Med* 28:815, 2000). It was determined that the knee brace significantly reduced but did not eliminate ACL strains as the knee made the transition from non-weight bearing to weight bearing. The brace also reduced ACL strain values when anterior shear loads were applied to both the NWB and WB knee.

The second question involved ACL-deficient patients. Anterior-posterior (A-P) laxity values were measured when the knee was WB and NWB. The braces restored the A-P laxity of the ACL-deficient knee to normal. However, the braces did not eliminate the anterior shift of the tibia relative to the femur that occurs as the knee makes the transition from NWB to WB.

Biomechanically, there are some questions that still need to be answered. Can FKBs protect an ACL, or ACL graft, during loads that are sufficient to produce injury? Can they reduce the incidence of knee re-injury and arthritis in the ACL-deficient knee?

ARTHROSCOPY AND ANTERIOR INSTABILITY OF THE SHOULDER Symposium Presented by the French Arthroscopy Association (SFA)

Symposium Chairman: Andre Frank, MD
Symposium Faculty: M. Allard, P. Beaufils, P. Boileau, O. Chaix, H. Coudane, P. Desmoineaux, P. Devallet, P.H. Flurin, G. Gartsman, D. Gazielly, P. Gleyze, Ph. Hardy, A. Imhoff, A. Iserin, F. Kelbérine, F. Kempf, L. Lafosse, C. Levigne, S. Messens, J.C. Meynet, D. Molé, H. Thomazeau, B. Toussaint, G. Walch

The French Arthroscopy Association presented the results of several different

studies in its afternoon symposium at ISAKOS:

CORRELATION BETWEEN CLINICAL AND ARTHROSCOPIC FINDINGS IN SHOULDER ANTERIOR CHRONIC INSTABILITY

A Prospective Multicenter Study of 224 Cases

The purpose of this multicenter prospective study was to compare anatomical findings to clinical data in 224 patients who underwent an arthroscopic stabilization of the shoulder. Each procedure was recorded on videotape, showing the lesions and the final aspect after treatment.

Ten centers took part in this continuous study from October 1999 to October 2000. 243 shoulders were operated on; the two first authors controlled the videotapes. 224 cases were included into this study. Mean age was 27.5 (16 to 56); 74% of the patients were males; 84% were involved in sports activities and 70% were involved in overhead sports. Indications for surgery included: recurrent dislocation (56%), subluxation (26%), and painful shoulder (18%). A bony lesion was found in 28% of the cases on the glenoid rim and, in 58% of the cases, on the humeral head. The average delay between the first symptoms and the index procedure was three to five years.

To assess the location of the periglenoid lesion we divided the glenoid rim into 6 sections (A,B,C,D,E,F) of 2 hours. The first section (A), located from 11 to 1 o'clock, was correlated to a SLAP lesion. Significant correlations were found between preoperative clinical symptoms and anatomical findings:

- Anterior lesions "BC" (32%) were 4/5 correlated to painful shoulders or subluxations, and only 1/5 were correlated to dislocations;
- Anterior lesions with SLAP extension "ABC" (30%) represented 80% of the painful shoulders;
- Anterior lesions with inferior extension "BCD" (22%) were correlated to dislocations or subluxations (95%), and only 5% were correlated to painful shoulders;
- Anterior-inferior lesions with posterior extension "BCDE" (9%) were also corre-

- lated to dislocations (62%);
- In 88% of the cases, global detachment "ABCDEF" (4%) was correlated to dislocations or subluxation;
 - 3% of the cases had no detachment.

Anterior ligaments (axillary pouch, anterior band of LGHI, MGHI) were considered normal in 50%, torn in 39%, or stretched in 11% of the cases. The humeral attachment of the anterior glenohumeral ligament was torn in 22% of the cases.

A classification of the arthroscopic findings has been established in order to improve our indications:

- **Type A – (50%) Periglenoid lesion only, with no ligament injury, nor humeral detachment.** This type seems to be the best indication for an arthroscopic stabilization.
- **Type B – (28%) Periglenoid lesion + ligament lesion.** The low quality of the soft tissues may be responsible for recurrent instability after an arthroscopic procedure.
- **Type C – (22%) Ligament detachment on the humeral side.** Isolated arthroscopic periglenoid ligament reattachment is not indicated; open surgery is necessary.

In conclusion, correlation between arthroscopic anatomical findings and clinical symptoms has been found. A classification according the arthroscopic lesions has been proposed to allow better indications.

The arthroscopic visualization of both the lesions and the final aspect after repair represents an important database that will allow a better assessment of the clinical results after a minimum two-year follow-up.

ARTHROSCOPIC SHOULDER STABILIZATION IN CHRONIC ANTERIOR SHOULDER INSTABILITY

209 patients with a chronic anterior shoulder instability entered into a multicenter retrospective study. Four techniques using an arthroscopic procedure were performed in four different centers: Fastak (35 cases), Mitek G II (75 cases), Suretac (58 cases) and Shrinkage (42 cases). The average age of the patients was 28 years old (14

to 59) and 78% were involved in sports activities.

Surgery was indicated for: recurrent dislocation (63%), subluxation (21%), and painful shoulder (16%). In 80% of the cases bony lesions were present on the glenoid rim, and in 86% of the cases they were present on the humeral head (Hill Sachs lesion). Delay between first symptoms and surgery was three to five years. Immobilization varied from three to six weeks. Recurrent dislocation occurred in 13% of the cases (Suretac 12%, Fastak 23%, Mitek 14%, Shrinkage 9%).

Comparisons between the different techniques used in this series are difficult because the indications were different. In the Mitek and Fastak groups there were more dislocations than in the Shrinkage and Suretac groups. Patients were graded according to the Duplay score. The average score was 82/100 (Suretac 85.4, Fastak 71.9, Mitek 89.3, Shrinkage 85.8). 71% returned to the same sport at the same level, 75% had no pain and the average range of motion was 176° in elevation with a mean loss of 8° in external rotation. The results according the Duplay score were excellent in 49%, good in 31%, fair in 6% and unsatisfactory in 15% of the cases. 82% were very satisfied or satisfied. Results were badly influenced by different factors: age inferior to 25, strenuous sports, throwing athletes, high rate of dislocation and hyperlaxity.

In conclusion, arthroscopic stabilization is efficient in more than 80% of the case. Improvement in techniques and indications should improve our results.

ACUTE FIRST ANTERIOR GLENOHUMERAL DISLOCATION: ARTHROSCOPIC ANATOMICAL FINDINGS. A PROSPECTIVE MULTICENTER STUDY OF 30 CASES.

Thirty patients underwent an arthroscopic evaluation without stabilization after an acute primary anterior glenohumeral dislocation. The purpose of this study was to assess the initial anatomical lesions and to correlate them to the clinical outcome after a conservative treatment.

Material: All patients were male under 30 years old (average age: 22 years). 81% were involved in sports activities.

The post-arthroscopic conservative treatment consisted of sling immobilization for 4 weeks. A CT scan was performed six weeks later.

Arthroscopic findings:

- Anteroinferior Labrum detachment + IGHL: 89%
- IGHL detachment on the humeral side: 23%
- Anterosuperior Labrum detachment + MGHL: 66%
- SLAP: 33%
- Hill Sachs: 100% (Minor 81%, Major 19%)
- Glenoid rim avulsion: 7%

Results: 21 patients were reviewed after 24 months mean follow-up. A recurrent dislocation occurred in two cases (15 and 27 months). The Apprehensive Test was positive in four other cases. Fifteen patients (71%) had a perfect stable shoulder.

Prognosis factors: Glenoid rim avulsion, major Hill Sachs lesion, extended lesion to the anterosuperior part of the labrum, and SLAP lesion did badly influence the final results.

Conclusions of this study: In acute anterior glenohumeral dislocation, arthroscopy shows a great variety of lesions.

The rate of recurrent dislocation in this study is low: 9.5%. Why? Arthroscopic lavage? Level of activity? Four weeks of post-operative immobilization?

Such studies remain necessary in order to understand the recurrence factors before achieving initial stabilization.

LESIONS OF THE GLENOID LABRUM (STABLE SHOULDER). ARTHROSCOPIC TREATMENT

In 1998, the Society of French Arthroscopy organized a symposium devoted to isolated lesions of the glenoid labrum in the stable shoulder.


This was a multicenter study with arthroscopic shoulder surgeons from six centers participating. (Fourteen were solicited.) Approximately 3000 shoulder arthroscopies performed over a three-year period were reviewed, ultimately yielding 151 cases (5%) of isolated labral lesions.

Continued on page 14

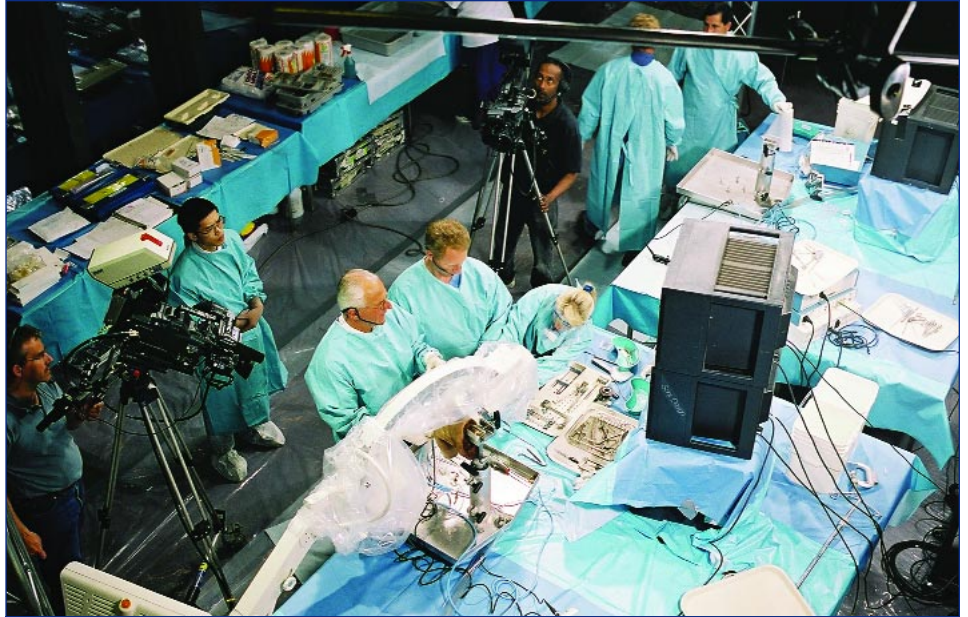
SCENES FROM THE 2001 CONGRESS



President's Reception



Past President Roland P. Jakob introduces current President Barry R. Tietjens



Drs. Paessler and Thal perform a Live Surgical Demonstration




Honorary Members (left to right) Lamberto Perugia, James Andrews for Jack Hughston, John B. McGinty, and Robert Jackson



Welcome Reception at the Petit Palais



Fun Run




Attendees in the Exhibit Hall



Farewell Banquet at the Nock Circus



Poster Exhibits



Past President Roland P. Jakob

SCENES FROM THE 2001 CONGRESS



500 posters were on display



Mini Hands-on Workshops



Poster & New Member Reception



President's Reception at the Chillon Castle



Multimedia Center



Stravinsky Auditorium



Technical Exhibits



Knot-Tying Station

Frequency of isolated pathogenic labral lesions:

Posterior superior lesions	115 cases	70%
(posterosuperior impingement)		
SLAP lesions	16 cases	10%
Anterior superior lesions	22 cases	15%
Posterior inferior lesions	8 cases	5%

Posterior Superior Lesions

Posterior superior lesions of the glenoid labrum were defined as "pathological lesions of the segment of glenoid labrum, from the insertion of the long head of the biceps superiorly, extending posteriorly to the equator of the glenoid". One hundred fifteen cases constitute this group and represent our 1998 experience with these lesions and their treatment.

This study demonstrated that posterior superior lesions of the glenoid labrum occur mainly in the overhead athlete and are the result of posterosuperior glenoid impingement as described by Walch. Arthroscopy is not necessary to establish this diagnosis if the clinical, radiographic, and computed tomographic arthrography data are consistent with posterosuperior glenoid impingement.

When the diagnosis is established, a trial of functional rehabilitation is always indicated. Failing nonoperative treatment, arthroscopic debridement of the labral and rotator cuff lesions gives inconsistent results, but remains an acceptable operative alternative. Surgical treatment using humeral derotational osteotomy as described by Walch can only be recommended in selected cases in which the patient has already failed less invasive therapeutic alternatives.

Lesions of the Superior Part of the Glenoid Labrum

Snyder originally described these lesions, located at the insertion of the long head of the biceps, in 1990. Since that time, controversy has existed regarding this lesion's etiology, frequency, and clinical and pathological relevance.

In this series, the authors found sixteen SLAP lesions as described by Snyder. These patients were reviewed extensively, including preoperative, intraoperative, and postoperative findings, insuring that these were

isolated SLAP tears and that these patients did not have any associated pathological lesions, i.e. instability, rotator cuff pathology.

From the evaluation of these patients, it is apparent that the preoperative findings in patients with this lesion are nonspecific. Despite this lack of specificity, an individual between the ages of twenty and forty years old sustaining a traumatic injury, usually as a result of athletics involving the upper extremity, with mechanical shoulder pain caused by the cocking maneuver, palpation of the bicipital groove, or pain with resisted forward flexion of the shoulder with a supinated extremity, must arouse suspicion of a SLAP lesion.

Computed tomographic arthrography and MRI demonstrate a SLAP lesion in approximately 50% of the cases. Ultimately, it is arthroscopy that establishes the diagnosis. We discovered four Type I, nine Type II, one Type III, and two Type IV SLAP lesions in our series. In all cases the lesion appeared indisputably pathologic, in contrast to a normal anatomic variant. Because of this necessary distinction, precise anatomical criteria must be considered.

Analysis of the results of this series affirmed that debridement of Type III lesions and repair of Type II and Type IV lesions are appropriate treatment.

When we evaluated the postoperative results according to the Constant score, we obtained twelve "excellent" and "good" results, two "fair" results, and two "poor" results. Overall, the results were satisfactory in 75% of the cases, with resumption of previous employment in 90% of the cases and resumption of sports activity at the pre-injury level in 75% of the cases.

In conclusion, lesions of the superior glenoid labrum exist but are rare. When they are present, SLAP lesions can be effectively treated by arthroscopy.

Anterior Superior Lesions

Twenty-two cases of lesions in the anterior superior segment of the glenoid labrum were found. These consisted of a complete disruption in eleven cases, a flap tear in seven cases, fibrillation of the labrum in two cases, and a labral fissure in one case.

These isolated lesions of the anterior superior labrum without known instability are rare in France, especially if lesions which extend superiorly or inferiorly are excluded from this category. The greater frequency of these lesions in the English literature is probably related to several factors: throwing sports are less commonly practiced in France, a less rigorous selection criteria for lesions located in this zone, and unclear distinctions between fibrillation, flap tears, and complete disruption of the labrum may exist.

The complete tear seems to be a distinct entity with, perhaps, a degenerative mechanism. Treatment with simple resection yields good results. Attention must be given to the status of the superior and middle glenohumeral ligaments, which may be involved in this lesion.

Lesions of the Posterior Inferior Labrum

Posterior inferior labral lesions are defined as all lesions within zones VI and V of Snyder. Often these labral lesions are associated with chondral pathology in the adjacent glenoid and/or a posterior capsular abnormality, usually in the form of capsular distension.

Since the arthroscopic identification of posterior capsular distension is extremely difficult, we were not able to establish whether these lesions were associated with posterior instability. We have therefore included all of the lesions within this anatomic location in this study.

After thoroughly reviewing the 3000

Keep Your Member Information Current!

ISAKOS Members: Help us keep your information current! Please visit the ISAKOS Web site at www.isakos.com and check your listing in the online Membership Directory to verify that we have your correct address, telephone numbers and e-mail address. Please notify the ISAKOS office if any of your information is missing or incorrect.

cases collected from the six centers of arthroscopic surgery, we discovered only eight isolated posterior inferior labral lesions. Epidemiologically, it was a very homogeneous population. The diagnosis was suspected in all cases on computed tomographic arthrography and confirmed arthroscopically.

- Six cases were isolated lesions without any apparent posterior capsular pathology. Arthroscopic resection of the lesion was successful in all cases.
- Two cases were associated with a subjectively-appearing distended posterior capsule, although no findings on preoperative clinical examination were suggestive of posterior instability. Treatment was successful only if the posterior capsular was plicated.

Lesions of the posterior inferior glenoid labrum exist, however, they rarely necessitate surgical treatment (0.3% of the shoulder arthroscopies we reviewed). Overall, our results confirmed that of the available literature, which indicates arthroscopic treatment of these lesions yields good results provided that occult posterior instability is addressed.

ARTHROSCOPY OF THE SHOULDER AND ROTATOR CUFF TEARS

The tremendous development of endoscopic procedures represents a recent and major evolution in the treatment of the rotator cuff pathology. To investigate its ability to substitute for open procedures, the French Arthroscopy Society conducted a multicenter symposium to retrospectively review 487 patients with three major questions:

- Is arthroscopy reliable enough to assess the anatomical extent of a rotator cuff tear (i.e., will it be able to become the "Gold Standard" for scientific prospective investigations)?
- Is Arthroscopic Subacromial Decompression (ASD) without repair a long-term efficient procedure for the treatment of rotator cuff tears?
- Are arthroscopic repair procedures anatomically and functionally efficient?

The following articles offer their findings.

ARTHROSCOPIC ASSESSMENT OF FULL-THICKNESS ROTATOR CUFF TEARS. (117 cases)

Evaluation of open or endoscopic procedures requires a precise, reliable and reproducible intraoperative assessment of the rotator cuff lesions. It is now well established that the anatomical extent of a full-thickness rotator cuff tear represents the major predictive factor of the anatomical and functional results following treatment. Description of this tear can no longer be limited to a simple classification using grades or centimeters, but must specify the anatomical state of each structure of the rotator cuff, including the rotator interval.

To evaluate the reliability of the arthroscopic assessment of full-thickness rotator cuff tears, 117 cases were prospectively investigated with imaging arthroscopy, immediately followed by open repair. The confidence of the operator, his accuracy, and the operator-dependent character of arthroscopic assessment were evaluated for the description of the main anatomical parameters.

Confidence in the method of investigation was judged on the percentage of non-communicated responses (nc) for each of the 3 types of investigation (imaging, endoscopic, open surgery). Comparing endoscopic data to open surgery data taken as a reference test then assessed accuracy. Re-analyzing the "confidence" and "accuracy" criteria of the operators who were divided in 4 different groups assessed the operator-dependent character of the endoscopic evaluation.

The operators felt confident and were accurate in diagnosing a full-thickness tear of the supraspinatus, but they clearly underestimated its coronal and sagittal extent, and its reducibility to the great tuberosity. Conversely this technique appeared very accurate for the description of the rotator interval. Endoscopic assessment was particularly operator-dependent for the antero-posterior analysis of the tear.

This study demonstrated the limits of the endoscopic assessment of rotator cuff full-thickness tears. The main limitations

are the sagittal analysis of the tear of SSN, especially when the lesion extends to the ISN and to a lesser degree to the SSC. This difficulty, already significant in this study despite experienced and motivated operators, is probably worse for less experienced operators. The influence of sagittal extent of the lesion on the final prognosis of a rotator cuff repair emphasizes the importance of a perfect and precise preoperative imaging. It also requires an adequate arthroscopic technique with a good knowledge of the limits of endoscopic assessment, and of the normal and pathological anatomy of the rotator cuff. These conditions are essential to precisely appreciate the lesion and its reparability before discussing the indication and the type of repair if chosen.

ARTHROSCOPIC SUBACROMIAL DECOMPRESSION WITHOUT REPAIR OF FULL-THICKNESS ROTATOR CUFF TEARS (283 cases)

The purpose of this study was to assess results and clinical evolution of full-thickness rotator cuff tears treated by Arthroscopic Subacromial Decompression (ASD), an/or biceps tenotomy without tendon repair, with a minimal 3 years follow-up, and to discuss our surgical indications according to the patient and the anatomical lesions.

283 patients entered this study, with a mean age of 63.1 years (range 32 to 82). A complete tear of the supra-spinatus tendon in the sagittal plane was noticed in 93.2% of the cases. The lesions extended to the infra-spinatus tendon in 57.3% of the cases, and to the sub-scapularis tendon in 29%. The long head of the biceps was stable and intact in only 27% of the cases.

All patients were evaluated pre and post-operatively using the Constant score and a radiological A-P view for sub-acromial space measurement. 218 ASD and 116 biceps tenotomies were performed. The two procedures were combined in nearly 25% of the cases. At the final revision (mean follow-up of 4.77 years), 98 patients (34.6%) were very satisfied, 122 (43.1%) satisfied, 43 (15.2%) moderately satisfied and 20 (7.1%) were disappointed. The average Constant score was 67.6 points/100 with a final gain

of +27.3 points. The radiological study showed a 1 mm narrowing of the sub-acromial space (7.6mm to 6.6mm).

Patients were divided in 4 groups according to their age: Group I (19 cases less than 50 years), Group II (88 cases from 51 to 60 years), Group III (58 cases from 61 to 65 years) and Group IV (118 cases over 65 years). The anatomical extent of the tear increased with age and the final objective result depended more on the extension of the lesions than on age (except for Group I).

This series did not demonstrate any major secondary clinical or radiological deterioration after the arthroscopic treatment without repair. Subacromial decompression and/or biceps tenotomy indications depend on age and extension of the tear. ASD can be considered as a reliable but also a "limited goal" procedure for the treatment of full-thickness rotator cuff tears (final Constant score: 67.6 points). Repair must be discussed for younger patients.

ARTHROSCOPIC ROTATOR CUFF REPAIR: WHEN AND WHY ?

In the presence of a symptomatic tear of the rotator cuff, should the cuff be repaired and the humeral head re-covered? In theory, the answer can only be affirmative, for is it not our role to restore function and, if possible, anatomy?

This is not always technically easy, however. Is it always necessary ?

An MRI study of 96 **totally painless** shoulders revealed that after the age of 60 years 28% of the individuals have a full thickness rotator cuff tear involving the supraspinatus tendon.

Another well-known study clearly demonstrated that there are 50% of recurrences after the repair of tears extending beyond the supraspinatus.

Various other studies showed the benefits of arthroscopic "debridement" without repair of rotator cuff tears, especially pain relief.

Recent studies also showed excellent results after anatomical repair (open, mini-open, arthroscopic)

Therefore, the fundamental questions are: Repair: when and why? If repair, then when and why arthroscopic?

Repair: When and Why ?

Depends on the lesion and the patient:

- The lesion: Size, Tissue Trophicity (Imaging +++)
- The patient (Age, Activity, Functional Demand...)

What can we expect after treatment? Arthroscopic subacromial decompression (ASD): palliative treatment for pain ++. Good and durable results.

Repair: Better functional result ++

If repairable and non degenerative tissue = excellent result

Arthroscopic Repair: When and Why

- Arthroscopy + Miniopen. Simple. Excellent exploration. Permit any kind of suture
- All arthroscopic: Recent studies are encouraging with promising results.
- Necessity of anatomical control +++.
Rerupture = 7 to 50 %
- Ideal indication = Small non retracted supra-spinatus lesion

CONCLUSIONS

The operative indication must be evaluated considering all pertinent parameters: age, pain, physical examination data (strength, mobility, etc.), tear extension (arthrography, arthroCT-scan, MRI), social and professional background, etc.

An operative indication is therefore easy to establish for younger manual workers who have a post-traumatic tear with a cuff susceptible to easy reinsertion (by open or arthroscopic technique). It is likewise easy to establish for the elderly patient whose functional demands are more modest but who complains about pain and for whom an arthroscopic debridement should provide a positive analgesic effect.

Between these two extreme situations, the definition of the operative indication becomes more complex, particularly because one must take into consideration the **intratendineous degenerative disease** (MRI and computerized arthrotomography) so that the **repair is lasting**. The future will certainly enable us to specify the respective operative indications, restricting the debate to "palliative" or "curative" treatment, and not to "arthroscopic" or "open surgery".

GOTS SYMPOSIUM

Symposium Chairman: Ernst-Otto Muench, MD, Germany

Faculty: Manfred Dingerkus, MD, Germany; Hubert Hoerterer, MD, Germany; Karl-Heinz Kristen, MD, Austria

About GOTS:

GOTS stands for the Gesellschaft für Orthopädisch-Traumatologische Sportmedizin, meaning the "Society of Orthopedic Sports Medicine and Traumatology". Physicians of sports medicine from Germany, Austria and Switzerland founded the German-speaking society in 1986. With more than 600 members working in private hospitals, sports federations, clubs, and at universities for the improvement of diagnosis, therapy and rehabilitation in amateur and professional sports, GOTS is behind the American Orthopaedic Society for Sports Medicine (AOSSM) as the world's largest and most important society for orthopaedics and trauma in sports.

GOTS understands sports medicine as a far-reaching and dialogue-oriented medicine. The society strives to unite the synergies of orthopaedists, surgeons, physiotherapists, psychologists and sports science researchers.

The self-image and function of GOTS is characterized by a combination of research, sports medicine, special events, work with international institutes, procurement of current research results for sports medicine applications, integration of industry, and dialogue with athletes, trainers, federations and the public.

The GOTS Symposium at ISAKOS:

Chairman of the GOTS Symposium at the ISAKOS Congress was former Vice-President E. Otto Muench. Hubert Hoerterer, Manfred Dingerkus and Karl-Heinz Kristen presented epidemiology, technique, injury patterns and prevention of injuries for sports skiing, inline skating and carving skiing.

Dr. Hoerterer demonstrated the difference between carving skies and traditional skies. Carving skies are characterized by broader ski-tips and tails and are usually shorter than traditional skies. It is easier for beginners to start skiing with this kind of ski

and more fun for the advanced skier. Dr. Hoerterer stated that he couldn't see negative aspects in the new development, but there is not enough data at present to point out a difference in injury patterns in carving skies compared to traditional skies. Knee injuries and especially ruptures of the ACL are still the most common injuries, occurring about 40% of the time.

In snowboarding, injuries are more frequently located at the upper extremity. This is also the case in inline skating. The most common and typical severe injury is the fracture of the distal radius.

The estimated number of active inline skaters, alpine skiers and snowboarders is about 50 million worldwide. All of these kinds of sports have a high potential for injury. A lot can be done for prevention by using protective equipment and devices, learning and using a proper technique, and training for physical fitness all year round.

Sports medicine physicians should possess a good knowledge of differing sports techniques, the mechanisms of injuries and the possibilities of injury prevention. Only then is adequate treatment likely.

CRITERIA FOR RETURN TO PLAY

Chairman: W. Ben Kibler, MD, USA

Faculty: John Bergfeld, MD, USA; Barry Tietjens, FRACS, New Zealand

This symposium presented information regarding the planning and implementation of strategies to safely and effectively return athletes to normal athletic function. It defined "function" as the capability to withstand the anatomic, physiological and biomechanical demands inherent in the sport or activity. The general criteria were optimization of the anatomy, by surgery or other treatment, and normalization of the physiological alterations, such as muscle strength, flexibility, or endurance, and biomechanical alterations, such as reduced joint motion or adaptations in jumping, running, or throwing.

W. Ben Kibler, MD, USA, presented information about return for throwing activities. He discussed the need to develop normal kinetic chain activations from the lower extremity, because this is the source of over 1/2 of the power development. Other issues

are accurate repair of all of the injuries around the shoulder and stabilization of the scapula before trying to optimize rotator cuff strength and balance. Return to throwing progressions are well established and should be gradually accomplished before full play.

John A. Bergfeld, MD, USA, then presented information about return to play for a specific sport: basketball. He emphasized the endurance and lower body and upper body strength requirements of basketball and the importance of healing of the tissues before return to play. He illustrated a program of progressions from work in the rehabilitation facility (strength, flexibility, power) to an on-court session emphasizing activities of running, pivoting, and shooting.

Barry Tietjens, FRACS, New Zealand, presented information about return to play for a specific injury: ACL injury. A successful outcome requires a high strength graft with stable fixation, followed by a physiologic rehabilitation program emphasizing full weight bearing and early restoration of full motion. Patients can expect to return to play between 5-10 months, depending on competition and physical status.

The discussion session concentrated on the gray areas of when to allow play while tissues were still healing, and when braces should be used. It ended with a discussion of how vigorous the rehabilitation protocols should be, and what should be the content of the protocols, thus re-emphasizing the importance of rehabilitation in returning athletes to optimal function.

ARTHROSCOPIC TREATMENT OF TRAUMATIC ANTERIOR SHOULDER INSTABILITY

Chairman: Mario V. Larrain MD, Argentina

Faculty: Philippe P. Hardy MD, France; Seung-Ho Kim MD, Korea; Anthony A Romeo MD, USA.

Topic and discussion highlights at this symposium included the following:

Traumatic Anterior Shoulder Instability: has high incidence of labrum detachment

Bone Defects: Rx, CT scan and Arthroscopic evaluation

Humeral: engaging Hill Sachs lesion over

25% / Increasing risk of redislocation

Glenoid Deficiency: > 25% / consider OPEN SURGERY

Anatomical Restoration: labrum GHJ complex attachment, adequate capsule and ligaments tension

Biomechanical Restoration: dish effect, effective glenoid arc, concavity-compression, and intraarticular pressure.

Acute Repair After First Dislocation: Good and excellent results with different arthroscopic techniques (suture anchor, transglenoid repair) because the tissues are in the best condition (major healing potential, minor capsular plastic deformity, less bone alterations).

Suture Anchor Technique:

Correct Arthroscopic Diagnosis

(type and grade of instability, evaluation of bone effects)

Proper Tissue Release

Accurate Placement and Sufficient

Number of Anchors

(at least 3, just at the edge of the cartilage surface on the osteochondral junction)

Good Knot-Tying Technique, Non-Sliding and Sliding Knots

(must be able to tie both types of knots)

Adequate Reduction and Tension of the Capsulolabral Complex

(not to lateral - reduce the articular surface. Not to medial create and ALPSA lesion)

Capsulorrhaphy: Special instrument required. Plication 0.5 to 1.5 cm.

Thermal Assisted Capsulorrhaphy: Useful adjunct in some surgeon's hands. Be aware of potential complications (axillary neuropathy).

Results with suture plications in the hands of an experienced shoulder arthroscopist will be better than thermal capsulorrhaphy in anyone's hands, and may equal results of open surgery.

With correct patient selection, identification of the type and characteristic of the lesions, and an accurate reconstruction surgical technique, we can obtain a 90% rating of good and excellent results in anterior traumatic instability, even in collision sports athletes.

Revision surgery: Identify the cause of failure of the primary Bankart repair (Pre-Operative, Intra-Operative, and/or Post-Operative)

If it is possible to correct and treat the cause of failure with arthroscopic technique (suture anchor), then we can perform an arthroscopic revision surgery when taking into account the type of patient population.

OSTEOTOMIES ABOUT THE KNEE FOR INSTABILITY AND ARTHROSIS

Chairmen: Peter Fowler, FRCS, Canada and Giancarlo Puddu, MD, Italy

The symposium, "Osteotomies About the Knee for Instability and Arthritis" was divided into three parts.

"Osteotomy Planning" was presented by Giancarlo Puddu and was dedicated to the radiographic assessment of lower limb alignment through full standing radiographs. Puddu recommended double stance, full length anteroposterior radiographs showing both lower extremities from femoral heads to the ankle joints. The use of a single stance radiograph was not recommended because of the increased lateral joint opening that occurs with deficient lateral ligament restraints.

To provide satisfactory clinical results HTO must create a valgus alignment to the lower extremity. The target of the correction has to be the movement of the mechanical axis from the medial compartment to 62% of the lateral tibial plateau. To the contrary, if the knee needs an antivalgus osteotomy, the mechanical axis has to be translated to the center of the tibial plateaux or within a few degrees of varus. A valgus knee should never be transformed in a varus knee.

"Upper Tibial Valgus Producing Osteotomies," presented by Peter Fowler, was dedicated to the indications: malalignment and arthritis, malalignment and instability, and malalignment and arthritis and instability.

The medial tibial opening wedge technique was suggested because fibular osteotomy can be avoided, it is easier to do for small corrections, and there is only one cut. Dealing with arthritis and instability, Fowler dedicated an important part of his presentation to the tibial slope and its relationship with the anterior tibial translation in the ACL deficient knee.

He suggested that surgeons keep in mind the following: increasing posterior tibial slope increases tendency for anterior tibial translation; and increasing posterior tibial slope worsens ACL deficit and helps PCL deficit.

Fowler preferred the opening wedge surgical technique for HTO, while Puddu preferred plate fixation, allograft or bone substitute graft.

The third part of the symposium was presented by Puddu and was dedicated to "Tibial and Femoral Antivalgus Osteotomies." Puddu suggested using a closing wedge medial tibial osteotomy in cases of a minor valgus knee, as it is efficient in both extension and in flexion. If the osteotomy has to produce more than 10° of correction, it creates an oblique joint line that can be dangerous for the future of the knee.

To the contrary, a opening wedge lateral osteotomy is efficient only in extension but does not create an oblique joint line. Puddu suggested this type of osteotomy using the femoral Arthrex opening wedge plates, as it is an easy and more precise operation in respect of the medial femoral closing wedge.

HTO and antivalgus tibial and femoral osteotomies have very precise and useful roles in the modern surgery of the knee dealing with initial arthritis. With respect to the past, the age class of patients is younger and the HTO especially has to be made in the unstable knee in association with ACL reconstruction, with special attention to the tibial slope.

After a lateral meniscectomy the cartilage damage of the lateral compartment can be very frequent and it happens very quickly: in these cases an antivalgus osteotomy can be very useful and has to be done as soon as possible.

ISAKOS Newsletter Translated to Spanish

ISAKOS thanks Fernando Radice, M.D., Chile, for translating the upcoming issues of the newsletter to Spanish.

The Spanish version of the ISAKOS Newsletter will be available on the ISAKOS Web site in September.

New Membership Directory Available Early September

The 2001-2003 ISAKOS Membership Directory will be printed and mailed to all ISAKOS members by early September.

In addition to a complete member listing, the directory will include the society bylaws and committee member listings.

Get a Free, Reliable E-mail Address

ISAKOS Encourages All Members to Get Online for Better Communication

As ISAKOS continues to grow, it will continue to communicate via e-mail. Sign up for a free and reliable e-mail address today.

1. Visit <http://mail.yahoo.com/> or <http://www.hotmail.com>.
2. Follow the steps to "Sign Up Now". It's anonymous and free of charge.

You can then access your e-mail account from any computer, anywhere in the world, if that computer has Internet access.

Posterior Cruciate Ligament Reconstruction: Single vs. Double Bundle Technique

Peter J. Fowler, F.R.C.S., London, Ontario, Canada, and David A. Parker, M.D., Canada



Historically, many observers have considered injuries to the posterior cruciate ligament (PCL) to be relatively benign. However, investigators such as

Harner and his colleagues have shown more recently that in the longer term, instability and arthrosis can result. Most surgeons would agree that PCL reconstruction or repair is indicated in the multiple ligament-injured knee. It is the treatment of isolated tears that remains controversial. This is especially so since results of PCL reconstructions have not been as satisfactory as those of ACL reconstruction in restoring and maintaining stability. Despite procedures that have been technically well carried out, residual laxity or over-constraint of the joint have been significant problems. Studies of the functional anatomy of the PCL have prompted a rethinking about the adequacy of single bundle reconstruction techniques to restore its function.

Covey et al. and others have shown in cadaver studies that the attachments of the PCL at both femur and tibia are quite extensive and that it is not possible to achieve true single isometric tunnel sites for reconstruction. The PCL consists of an anterolateral and a posteromedial bundle which are structurally and functionally distinct. Each occupies approximately one-half of the ligament insertion site. The anterolateral bundle is twice the size of the posteromedial at mid-substance, has stronger mechanical properties and is tight in flexion. It is the aim of most single bundle techniques to reconstruct this component. The posteromedial bundle is tight in extension, has a more posterior and distal femoral attachment and a more medial tibial attachment. The femoral attachment of the PCL spans approximately 32mm, is 8-10mm posterior to the articular margin and large enough to accommodate a two bundle reconstruction. The tibial attachment is approximately 15mm distal to the

tibial plateau, 12mm across and oval-shaped.

The results of cadaver studies comparing single to double bundle reconstruction strongly support the latter. Harner et al. found that this technique best reproduced normal knee kinematics throughout full range of motion and restored normal translation from 0-12° of flexion. They also concluded that the posteromedial bundle is important in resisting posterior tibial loads in flexion and hypothesized that load-sharing between the two bundles may offer protection from excessive stress during graft healing. In a similar study Race et al. compared "isometric" grafts to single and double bundle grafts. They found that the single "isometric" grafts over constrained the knee in extension, became lax in flexion and produced near normal constraint only from 0 to 60°. On the other hand, there was near normal constraint across full range of motion with the double bundle grafts. They concluded, as did Harner et al., that an isometric reconstruction was not possible and confirmed the role of the posteromedial bundle in resisting posterior translation at higher flexion angles. Although not yet supported clinically, the data from these in vitro studies clearly suggest that PCL reconstruction techniques, which address both bundles, may lead to the satisfactory results that have not as yet been realized.

The many technical aspects of such a reconstruction require careful preoperative planning and intra-operative attention to detail. Graft sources, which include autograft or allograft hamstrings, patellar or quadriceps tendon, or allograft Achilles tendon, are all suitable options with varied risks and benefits. Selection should be based on the individual patient. Tunnel placement is obviously critical and should, as closely as possible, mimic normal anatomy. The double bundle technique can utilize two femoral and one tibial tunnel. The work of Covey et al., which demonstrated that the femoral attachment is the primary determinant of fibre length, supports this approach. Ideally, the anterolateral tunnel should be placed 8-10mm behind the articular margin near the junction of the roof and side wall of the

femoral notch, with the posteromedial tunnel distal and posterior to this. The bony bridge between the tunnels should be at least 3-4mm. Making the tibial tunnel parallel to the tibiofibular joint and aiming for the lateral and distal margin of the footprint from a start point near the midline on the tibia will decrease somewhat the so-called "killer curve." Miller et al. have described the tibial inlay technique using a bone block with patellar tendon to avoid this curve. This does require a separate posterior approach. With respect to fixation there are numerous suitable choices. It is critical however, to tension each bundle individually. Harner recommends tensioning the anterolateral bundle at 90° with an anterior drawer and the posteromedial at 30°.

Techniques of PCL reconstruction continue to evolve. Current procedures have not been successful in consistently restoring stability and range of motion – a fact that tends to influence the indications for reconstruction. Cadaver study data have provided an explanation for the unsatisfactory results of single bundle reconstruction and certainly support the transition to a two bundle procedure. As with all innovative surgical techniques, clinical experience in multiple centers with sufficient patient numbers and long-term follow-up is necessary to accurately determine its feasibility and success.

References:

1. Harner CD, Jansushek MA, Kanamori A, Yagi M, Vogrin TM, Woo S-Y: Biomechanical analysis of a double-bundle posterior cruciate ligament reconstruction. *Am J Sports Med* 2001; 28: 144-151.
2. Covey DC, Sapega AA, Sherman GM: Testing for isometry during reconstruction of the posterior cruciate ligament. *Anatomic and biomechanical considerations.* *Am J Sports Med* 1996; 24: 740-746.
3. St.Pierre P, Miller M: Posterior cruciate ligament injuries. *Clinics in Sports Medicine* 1999; 18: 199-221.
4. Race A, Amis A: PCL reconstruction. In vitro biomechanical comparison of 'isometric' versus single and double-bundled 'anatomic' grafts. *IJBS (B)* 1998; 80: 173-179.

Editor's Note

(Continued from page 2)

room.

The entertainment was magnificently presented by our host, ISAKOS President Roland Jakob. Throughout the elegant President's Reception, the President's Dinner at Chillon Castle, and the Farewell Dinner at the Nock Circus, Dr. Jakob was the epitome of European grace, charm and hospitality. And in the end, at the Nock Circus, he proved to be quite a showman as he incorporated his official presidential duties into the circus acts. But the entertainment was not limited to official ISAKOS functions. Many of the physicians and their families were able to venture out into the countryside to enjoy the magnificent sightseeing opportunities offered by the Swiss Alps and Lake Geneva region.

Finally, there was the fellowship. A major factor in the appeal of ISAKOS is the opportunity for professional interchange and interaction with colleagues from around the world. This has brought a spirit of camaraderie to ISAKOS that is unmatched in other organizations. Nowhere was this

camaraderie and fellowship more evident than at the Farewell Banquet at the Nock Circus. Throughout the circus tent, physicians and their families enjoyed visiting with their counterparts from far-flung regions of the globe. Language and geography were not barriers.

An unexpected opportunity presented itself when an orthopaedic surgeon from Russia sat down across from me at our table. We began a discussion about the status of arthroscopy in Russia and compared the Russian system of health care delivery with the American system. Such a conversation between American and Russian orthopaedic surgeons could not have taken place a few short years ago. How the world has changed.

Modern travel and instantaneous communication have brought us all much closer together. We truly are becoming a worldwide orthopaedic community, a global community of peers and of friends.

The spirit of Montreux stirred an old memory from my past. When I was in college at Rice University, an engraved plaque outside the history lecture hall displayed a quote by Ralph Waldo Emerson: "The educated man is at home in the world; his

International Societies, Presidents and Meetings Online

To further communication between societies of related specialties, ISAKOS has listed international societies, their presidents, and their upcoming meetings on the ISAKOS Web site.

Members are encouraged to visit the Web site at www.isakos.com. Societies that are not listed may submit a request to the ISAKOS Office. Online forms will be available in November 2001.

hearth the earth, his roof the azure dome." It was good to be in Montreux with friends, at home in the world, under such a peaceful and beautiful azure dome.

Upcoming ISAKOS-Approved Courses

Knee Cadaveric Training Course

October 20-21, 2001
Singapore General Hospital
SINGAPORE

Registration Fee: SING \$950.00. For further information, please contact:

C.M. Wang
1 Jalan Kilang Timor
#08-03 Pacific Tech Centre
Singapore 159303
SINGAPORE
Tel: 65 270 0552
Fax: 65 272 6698
E-mail: cmwang@attglobal.net

18th International Jerusalem Symposium on Sports Medicine

March 20-21, 2002
Jerusalem, ISRAEL

For further information, please visit www.sportsmedicine.co.il or contact:

Dr. Gideon Mann
Unit of Knee Surgery & Arthroscopy,
Meir Hospital, Kfar Saba, Israel
Regin Medical Center
P.O. Box 34400, Givat Shaul
Jerusalem 95483, ISRAEL
Fax: +972-2-6528231
E-mail: gmann@sportsmedicine.co.il

Argentina 2002 Arthroscopy Congress

May 22-25, 2002
Sheraton Hotel & Convention Center
Buenos Aires, ARGENTINA

For further information, please contact:

ASOCIACION ARGENTINA
DE ARTROSCOPIA
Montevideo 1546 1st floor
1018 - Capital Federal
Buenos Aires - Argentina
Tel: +54 11 4811-2089
Tel: +54 11 4816-8191
Fax: +54 11 4811-2389
E-mail: artroscopia_arg@ciudad.com.ar

Modularity in Total Knee Arthroplasty: An Essential Advance or a Source of More Problems?

James Alan Rand, M.D., Scottsdale, Arizona, USA



Total knee arthroplasty with modern era designs began with the total condylar prosthesis with a one piece all polyethylene tibial component. The long-term results with the original

total condylar prosthesis have been excellent with implant survivorship to revision of 89-96% at fifteen to twenty years (1,2). Metal backing was added to the tibial component based on laboratory studies that showed decreased stresses in the cancellous bone and the cement of the proximal tibia (3,4). The addition of the metal backing to the tibial component was anticipated to decrease the prevalence of mechanical loosening. Two series of total condylar prostheses comparing an all polyethylene to a metal backed tibial component have found no significant differences in survival between the two designs (5,6).

Metal backing of the tibial component has some disadvantages. For any given thickness of the component, polyethylene thickness will be diminished by the thickness of the metal backing. Failure from wear of the polyethylene through to the metal backing has been identified with several different implant designs (7, 8,9,10). The cost of manufacture of the metal backed tibial component is increased compared to an all polyethylene implant. Initially, the polyethylene was fixed to the metal backed tibial component at the factory. The results of fixed metal backed tibial components have been good with survivorship to revision of 88 to 96 % at 10 to 15 years with several designs (11,12,13). The use of metal backed tibial components compared to all polyethylene components of newer implant designs has not have been prospectively studied for many designs. In one randomized, prospective study of 213 knees at three years, there were no significant differences in survivorship or radiolucency between the metal

backed and all polyethylene tibial components (14). The Anatomic Graduated Component (AGC) design has a compression molded polyethylene metal-backed tibial component. The results of the AGC metal-backed component have been excellent with survivorship of 98% at ten years (15). However, when the AGC prosthesis with an all polyethylene component of the same design was utilized in a series of 536 knees, failure occurred in 95 knees at four years (16). Therefore, the total condylar experience cannot be generalized to all other implant designs.

The addition of a metal backing to the tibial component provided the option for modularity. Modularity was first applied to the polyethylene for the tibial component. There are several advantages to a modular polyethylene. A modular polyethylene allows the ability to adjust soft tissue tension once the implants are fixed to bone. Acrylic bone cement can be removed from the back of the joint prior to placement of the polyethylene to prevent third body wear from entrapped cement particles. The conformity of the polyethylene can be varied to provide differing constraint options for ligament laxity or deficiency. The disadvantage of a modular polyethylene relates to the locking mechanism of the polyethylene to the metal tibial tray. The locking mechanism must allow ease of insertion of the polyethylene at the time of implantation. However, the locking mechanism for the polyethylene must be secure enough to prevent dislodgement of the polyethylene *in vivo*. A variety of locking mechanisms have been used including snap-fit, pins, clips, and combinations of these mechanisms. Dislodgement of polyethylene components from the tibial tray have occurred *in vivo*. Motion between the undersurface of the polyethylene articulating against the metal tray has been recognized as a generic problem in total knee design and as a source of wear debris (17,18). In a recent study, micromotion between the polyethylene and the tibial tray in a newly assembled implant was 70mm (19). Motion was increased upon retrieval at revision to 413mm or at autopsy to 420mm (19). The

micromotion between the polyethylene and the metal tray is a source of wear debris which has been associated with osteolysis and failure of some implant designs. In a recent study of a posterior stabilized prosthesis design, the failure rate at five years of the metal reinforced tibial component was 2.9% of 557 knees at 56 months for loosening and osteolysis (20). Motion and wear on the undersurface of the polyethylene was considered as a factor contributing to these failures (20). In a comparison of metal backed and all polyethylene posterior stabilized components of one design in 243 knees at 5 years, survivorship was 96% for the all polyethylene and 75% for the metal-backed components (21). Therefore, the use of a modular polyethylene has had some unanticipated adverse consequences in some designs.

Should modular polyethylene tibial components be abandoned in favor of either all polyethylene or non-modular metal backed tibial components? The answer is difficult to determine as some designs with a modular polyethylene tibial component have had excellent results. For one posterior cruciate preserving design with a semi-conforming tibial geometry, the survivorship at ten years in 1000 knees was 97% (22). Therefore, prosthetic geometry is an important variable influencing the potential for wear between the polyethylene and the metal tray. Other variables that must be considered are the quality of finish of the tibial tray, the finish of the undersurface of the polyethylene, and the adequacy of the locking mechanism for the polyethylene to the metal backing. It is essential that as new designs are introduced into the market place that both laboratory testing and clinical trials be performed to document the performance of these designs both for all polyethylene and metal-backed tibial trays.

Another advantage of a modular design has been in the management of complex knee deformities and revisions. The addition of modular augments for bone deficiency to assist in bone defect management and joint line restoration has facilitated revision total knee arthroplasty. Metaphyseal non-unions and osteotomies can be managed by fixation

with modular stems at the time of total knee arthroplasty. Curved stems can be used to gain fixation in the presence of offsets between the metaphysis and diaphysis that occur after prior fracture. However the locking mechanism of these modular implants must be adequate to prevent fretting with the creation of wear debris or dissociation *in vivo*. Recent reports have identified problems with dissociation of locking screws and fracture through the coupling mechanism of modular stems utilized in revision (23,24). Therefore, appropriate laboratory testing and correct clinical use of modularity in revision and complex total knee arthroplasty is essential to prevent these failures.

In summary, modularity is widely accepted in total knee arthroplasty design at the present time. The surgeon must carefully evaluate the design characteristics of each implant and not generalize from one design to another. An all polyethylene component of a moderately conforming design similar to the total condylar is a reasonable choice for many primary knee arthroplasty patients. The use of a modular metal backed tibial component for the patient with osteoporotic bone or need for modular augments or stems is an appropriate choice. Each implant must be carefully evaluated for its design characteristics and clinical results.

References:

- Ranawat, C.S.; Flynn, W.F.; and Deshmukh, R.G. Impact of Modern Technique on Long-Term Results of Total Condylar Knee Arthroplasty. *Clin. Orthop.* 309:131-135, 1994.
- Gill, G. and Joshi, A. Performance of the Cruciate Retaining Knee Arthroplasty: 15 Years and Beyond. Presented at the Annual Meeting of the American Academy of Orthopedic Surgeons 2000.
- Walker, P.S.; Greene, D.; Reilly, D.; Thatcher, J.; Ben-Dov, M.; and Ewald, F.C. Fixation of the Tibial Components of Knee Prostheses. *J. Bone and Joint Surg.* 63A:258-267, 1981.
- Bartel, D.L.; Burstein, A.H.; Santavicca, E.A.; and Insall, J.N. Performance of the Tibial Component in Total Knee Replacement. *J. Bone and Joint Surg.* 64A:1026-1033, 1982.
- Appel, D. M.; Tozzi, J.M.; and Dorr, L.D. Clinical Comparison of All-Polyethylene and Metal-Backed Tibial Components in Total Knee Arthroplasty. *Clin. Orthop.* 273:243-252, 1991.
- Rand, J.A. Comparison of Metal-backed and All-polyethylene Tibial Components in Cruciate Condylar Total Knee Arthroplasty. *J. Arthroplasty* :307-313, 1993.
- Kilgus, D.J.; Moreland, J.R.; Finerman, G.A.; Funahashi, T.T.; and Tipton, J.S. Catastrophic Wear of Tibial Polyethylene Inserts. *Clin. Orthop.* 273:223-231, 1991.
- Peters, P.C.; Engh, G.A.; Dwyer, K.A.; and Vinh, T.N. Osteolysis after Total Knee Arthroplasty without Cement. *J. Bone and Joint Surg.* 74A:864-876, 1992
- Tsao, A.; Mintz, L.; McRae, C.R.; Stulberg, D.S.; and Wright, T. *J Bone and Joint Surg.* 75A:19-26, 1993.
- Cadambi, A.; Engh, G.A.; Dwyer, K.A.; and Vinh, T.N. Osteolysis of the Distal Femur After Total Knee Arthroplasty. *J. Arthroplasty* 9:579-594, 1994.
- Malkani, A.; Rand, J.A.; Bryan, R.S.; and Wallrichs, S.L. Total Knee Arthroplasty with the Kinematic Condylar Prosthesis. *J. Bone and Joint Surg.* 77A:423-431, 1995.
- Colizza, W.A.; Insall, J.N.; Scuderi, G. R. The Posterior Stabilized Total Knee Prosthesis. *J. Bone and Joint Surg.* 77A:1713-1720, 1995.
- Thadani, P.J.; Vince, K.G.; Ortaaslan, S.G.; Blackburn, D.C.; and Cudiamat, C.V. Ten- to 12-Year Followup of the Insall-Burstein I Total Knee Prosthesis. *Clin. Orthop.* 380:17-29, 2000.
- Gioe, T.J. and Bowman, K.R. A Randomized Comparison of All-Polyethylene and Metal-Backed Tibial Components. *Clin. Orthop.* 380:108-115, 2000.
- Ritter, M.A.; Worland, R.; Saliski, J.; Helphenstine, J.V.; Edmondson, K.L.; Keating, E.M.; Faris, P.M.; and Meding, J.B. Flat on Flat, Nonconstrained Compression Molded Polyethylene Total Knee Replacement. *Clin. Orthop.* 321:70-85, 1995.
- Ritter, M.A. The Cemented All-poly Tibia. *Orthopedics* 17:841, 1994.
- Wasielowski, R.C.; Parks, N.; Williams, I.; Surprenant, H.; Collier, J.P.; and Engh, G. Tibial Insert Undersurface as a Contributing Source of Polyethylene Wear Debris. *Clin. Orthop.* 345:53-59, 1997.
- Parks, N.L.; Engh, G.A.; Topoleski, L.D.T.; and Emperdo, J. Modular Tibial Insert Micromotion. *Clin. Orthop.* 356:10-15, 1998.
- Engh, G.A.; Lounici, S. and Rao, A. In Vivo Deterioration of Contemporary Tibial Baseplate Locking Mechanisms with Modular Total Knee Components. Presented at the Knee Society, San Francisco 2001.
- Mikulak, S.A.; Mahoney, O.M.; Dela Rosa, M.A.; and Schmalzried, T.P. Loosening and Osteolysis with the Press-Fit Condylar Posterior-Cruciate-Substituting Total Knee Replacement. *J. Bone and Joint Surg.* 83A:398-403, 2001.
- Rodriguez, J.A.; Baez, N.; Rasquinha, V.; and Ranawat, C.S. Modular Metal-Backed and All-Polyethylene Tibial Components in the PFC Knee. Presented at the Annual Meeting of the American Academy of Orthopedic Surgeons, San Francisco 2001.
- Berry, D. and Whaley, A. Ten Year Results of the Press Fit Condylar Total Knee. Presented at the Annual Meeting of the American Association of Hip and Knee Surgeons, Dallas 2000.
- Westrich, G.H.; Kidaka, C.; and Windsor, R.E. Disengagement of a Locking Screw from a Modular Stem in Revision Total Knee Arthroplasty. *J. Bone and Joint Surg.* 79A:254, 1997.
- Lim, L.A.; Trousdale, R.T.; Berry, D.J.; and Hanssen, A.D. Failure of the Stem-Condyle Junction of a Modular Femoral Stem in Revision Total Knee Arthroplasty. *J. Arthroplasty* 16:128-132, 2001.

Search the ISAKOS Membership Directory Online

ISAKOS encourages members who are looking for e-mail addresses or other contact information for colleagues to utilize the online ISAKOS membership directory. Visit www.isakos.com and click on the "Directory" icon.



*The First Choice
in Arthroscopy**

**Constant
Innovation**

Smith & Nephew, Inc., Endoscopy Division is a world leader in the development and commercialization of endoscopic techniques.

As the recognized world leader in Arthroscopy, Smith & Nephew offers a complete line of anatomically targeted products.

Smith+Nephew

First Choice in Endoscopy

www.endoscopy1.com

*No. 1 in Arthroscopy, U.S. and European markets, Millenium Research Group, USOVE, March, 2000; EUEOO, February, 2000.



***International Society of Arthroscopy,
Knee Surgery and Orthopaedic Sports Medicine***
145 Town & Country Drive, Suite 106
Danville, CA 94526-3963 USA

Telephone: +1 (925) 314-7920

Fax: +1 (925) 314-7922

E-mail: isakos@isakos.com

Web: www.isakos.com

**SUMMER 2001
ISAKOS NEWSLETTER**

2003 ISAKOS CONGRESS

MARCH 10-14, 2003

AUCKLAND, NEW ZEALAND



**CALL FOR ABSTRACTS
AVAILABLE OCTOBER 2001**