

ISAKOS

ISAKOS NEWSLETTER 2018 • VOLUME II

Current Concepts on Arthroscopy, Knee Surgery & Orthopaedic Sports Medicine



- INSIDE 4** 2019 CONGRESS PROGRAM
- 16** BROKEN DRILL BIT – HIP ARTHROSCOPY
- 18** STIFF ELBOW CLASSIFICATIONS
- 27** MENISCAL ALLOGRAFT TRANSPLANTATION
- 39** CRITICAL SHOULDER ANGLE – RTC REPAIR

in this issue

Editor's Message	1
President's Message	2
2019 ISAKOS Congress Program	4
Pearls & Pitfalls	16
Current Concepts	18
Approved Course Reports	45
Upcoming ISAKOS Approved Courses	51

EDITOR

Robert G. Marx, MD, MSc, FRCSC UNITED STATES

EDITORIAL BOARD

Iftach Hetsroni, MD ISRAEL, Associate Editor

Tahsin Beyzadeoglu, Prof., MD TURKEY

Raju Easwaran, MS (Orth) INDIA

Yee Han Dave Lee, MBBS, FRCS(Ortho), MD
SINGAPORE

Bruce A. Levy, MD UNITED STATES

Stephen L. Lyman, PhD UNITED STATES

Tatsuo Mae, MD, PhD JAPAN

Dipak Raj, FRCS (Tr & Orth), MCh Orth., MS Orth.
UNITED KINGDOM

Samuel A. Taylor, MD UNITED STATES

Daniel Whelan, MD, MSc, FRCSC CANADA

Kyoung Ho Yoon, MD, PhD, Prof.
REPUBLIC OF KOREA

Omer Mei-Dan, MD UNITED STATES, Past Editor



**International Society of
Arthroscopy, Knee Surgery and
Orthopaedic Sports Medicine**

2410 Camino Ramon, Suite 215
San Ramon, CA 94583-4318 USA
Telephone: +1 925 807-1197
Fax: +1 925 807-1199
Email: isakos@isakos.com

ISAKOS Welcomes Change & Opportunity

We are less than a year away from the 12th Biennial Congress in Cancun, Mexico! What a difference a year can make. So much can happen in that short amount of time, especially in the fast-paced world of ISAKOS. But without such change, there can be no growth or progress. Change is an inevitable force that allows us to evolve into a stronger, more impactful society—and ISAKOS welcomes that opportunity!

After the last Congress in Shanghai, we switched gears and opened Abstract Submission for the 2019 Congress in Cancun. As we did in 2017, we are expecting an overwhelming number of submissions for 2019. ISAKOS also opened applications for eight award opportunities and four fellowships—including the new Global Traveling Fellowship! We hope you had a chance to apply when submitting your abstracts or before the application deadline. Registration for the Congress is now open as well! Register today for the best rate—a \$200 discount off of the on-site price. Hotel accommodations and tour opportunities can also be found at isakos.com/2019congress. Register and book early!

Technology often changes faster than one can keep up with it. As an elite and global society, ISAKOS strives to match pace and offer a universal platform for education. With that, the ISAKOS Congress Interactive Agenda has been given a revitalized look and interface! Now more mobile friendly—save this web app to your phone or tablet for easy access on the go! Access Faculty profiles and schedules, outlines and presentations, a customizable mySchedule, and more. We have also added new features such as; search and sort filters, collapsible/expandable viewing, and continuous scrolling. Take a peek today at isakos.com/interactiveagenda.

As many of you already know, the Congress next May will be ISAKOS Executive Director, Michele Johnson's, last biennial meeting with the Society. After more than 20 years with ISAKOS, Michele Johnson has made the decision to transition out of her role as Executive Director. Since her start, the Society has grown from a small group of fewer than 900 members to the powerhouse it is today with more than 3,000 members from 93 countries. Under her wing, the Society has experienced so much change—evident in the Biennial Scientific Congresses, workshops, collaborative meetings, publications, fellowships and most recently, the establishment of the *Journal of ISAKOS*. The ISAKOS Family and Office Staff will be forever grateful for her service and contributions to the Society—she will be missed greatly!

“ We are all profoundly indebted to Michele for her leadership, creativity, and ability to work effectively and professionally with people from all over the globe. ”



Marc R. Safran, MD
ISAKOS President, 2017-2019

REMEMBERING

Sandy Kirkley



I was invited to attend the Fowler Fellow Society meeting this past June. As I worked on my talks, I reflected on my initial contact with the faculty from the Fowler Kennedy Sport Medicine Clinic in London, Ontario, Canada. It was 2000 and I had just finished my fellowship at HSS. Dr. Sandy Kirkley from London called to ask me if I would participate in an instructional course with her and her mentor Pete Fowler at the third bi-annual ISAKOS meeting coming up in Switzerland in 2001. She was putting together a course on research methodology. I had just started practice and had not yet been asked to give an invited talk in my life. I had barely heard of ISAKOS and didn't know anyone who was going to the meeting, but I said "yes of course!" At the ICL early that morning there weren't many people who showed up to learn about clinical research, but Jon Karlsson from Sweden and Lars Engebretsen from Norway were in the audience. How lucky for me to meet such accomplished surgeons and leaders in clinical research in sports medicine. I was so grateful to Sandy for the opportunity. Tragically, she died the following year with her husband in a plane crash. I will never forget her passion for improving the quality of sports medicine research and including me on her journey, which unfortunately ended far too soon. I remain grateful to her to this day for that invitation which led me to my first ISAKOS congress and allowed me to meet many international colleagues, make friends with surgeons from around the world, and to learn much from them over the years. If you have not attended an ISAKOS congress yet, make this one in Mexico your first – it could change your life. It changed mine!

If you have not attended an ISAKOS congress yet, make this next one in Cancun, Mexico your first—it could change your life. It changed mine!

Robert G. Marx, MD

ISAKOS Newsletter Editor 2017–2019



Greetings from ISAKOS

It is an exciting midway point of my ISAKOS presidency—very exhilarating times, as we have accomplished a lot in the last year, and have lots to do before our fantastic Biennial Congress in Cancun in May 2019. Sometimes, I have to sit back and comprehend the fact that I *really am* the President of ISAKOS (a fact that continues to humble me)—it's a role that I continue to be honored to hold. This past year, ISAKOS has accomplished many projects that were started by my predecessors as well as some projects that I initiated with the help of the Executive Committee and other ISAKOS Committees.

This past year, the Executive Committee and/or the Board of Directors have had monthly video conference calls, inviting Committee Chairs to join and share their projects and progress. These calls have helped keep ISAKOS moving forward. They have also allowed the Board to assist committees as issues arise, thus, allowing committees to accomplish their goals without delay. Our committees really have been doing a great job—it is truly a privilege to work with colleagues in our Society who are dedicated to the fields of arthroscopy, knee surgery and orthopaedic sports medicine. By volunteering their time, expertise, and experience, they continually prove their commitment to our Society. In addition, many thanks are due to Drs. David Parker and Jon Karlsson for their constant support of the ISAKOS Committees and for being reliable liaisons between the committees and Board of Directors.

ISAKOS continues to be active supporters of courses around the world and also strives to further develop relationships with partner societies and their meetings. We recently participated in the ISKAST Congress in Iran, SRATS in Romania, SLAHOC in Bolivia, and also had a presence at the ESSKA and APKASS Congresses and AOSSM Annual Meeting. ISAKOS will also be participating in the SIA National Congress in Milan in October. Additionally, I have been working towards the addition of international interim meetings and laboratory courses. Last year, ISAKOS held a lab course at Aspetar, and more recently, collaborated with AOSSM on the Hip Arthroscopy Surgical Skills Course in Chicago. In 2019, we will further collaborate with AOSSM through a combined surgical skills course, "Osteotomies Around the Knee" in April (Chicago, USA), and through a soccer course in September (Milan, Italy) along with Major League Soccer. Further down the road, in 2020, ISAKOS will be partnering with ESSKA on an exclusive educational course. Details of this meeting will be forthcoming, as the planning continues.

In addition to our traditional Congress awards, there will be new awards presented at the Congress in Cancun. Due to the generosity of Dr. Nicolas Budhiparama, ISAKOS has introduced the Paolo Aglietti Knee Arthroplasty Award and is also in the planning stages for a Knee Arthroplasty Fellowship with the Knee Arthroplasty Committee. The Fellowship, which will open applications in 2019, will give young surgeons the opportunity to travel and learn cutting-edge knee arthroplasty skills from world-renowned ISAKOS surgeons. Another new award this year is the ISAKOS Global Traveling Fellowship, which gives five fellows (45 years of age or under) the opportunity to travel for two weeks to several centers in the region of the Biennial Congress. For 2019, the region will be South America and the ISAKOS Godfather accompanying the fellows will be ISAKOS Executive Committee member and SLARD President, David Figueroa, MD, from Santiago, Chile. At the time of this writing, more than 150 surgeons have already applied for the Global Traveling Fellowship—a promising indicator that this will be a very well accepted and successful fellowship. Lastly, the ISAKOS Young Investigator's Scholarship & Research Mentoring Program awardees are currently visiting teaching centers all over the world—we look forward to receiving reports of their travels and experiences at the Congress.

The Publications Committee has continued to be very active and has several new publications set to be released prior to the ISAKOS Congress in Cancun. In conjunction with ESSKA, *Basic Methods Handbook for Clinical Orthopaedic Research* by M. Hirschmann, V. Musahl, J. Koh, O. Ayeni, R. Marx, N. Nakamura, and J. Karlsson, is one such book soon to be published. As always, these publications are ISAKOS Member benefits and complimentary access will be available to Members.

The *Journal of ISAKOS* continues to grow. For the past six months, *JISAKOS* has been accepting original research articles. This is a very exciting time for our journal—we have had many high-quality submissions! Many articles and editorials are being cited and discussed worldwide. The Journal Advisory Group (JAG), under the leadership of Dr. John Bartlett has changed its name to the Journal of ISAKOS Board of Trustees (JIBOT). Sadly, John Bartlett will be stepping down from this position, after successfully guiding the Journal from its inception. Many thanks are owed to John for his dedication and hard work with our journal. The *Journal of ISAKOS* is quickly becoming a crown jewel for our society, and it is becoming very apparent as to why.

As most of you already know, after nearly 25 years at ISAKOS, Michele Johnson is retiring from her role as Executive Director. Michele will sorely be missed, and certainly cannot be replaced. Fortunately, Michele will serve as a consultant for ISAKOS after the Congress in Cancun. Additionally, the current staff will be hired on to join the new, full-time, ISAKOS Office. All of these pieces will help make this transition as smooth as possible. ISAKOS has hired a search firm and consultant, and are currently in the throes of an active search for a new CEO. While transitions can often be uncomfortable, ISAKOS is in excellent shape and position. ISAKOS is continuing to grow and mature, all while maintaining a solid financial state and thousands of committed members.

Lastly, the 12TH Biennial ISAKOS Congress in Cancun is fast approaching! This Congress will host 47 Symposia, 30 Instructional Course Lectures, 5 Debates, 37 surgical demonstrations, and 5 Partner Society Symposia. Additionally, there will also be a Sports Rehabilitation Concurrent Course (tell your physical therapists!), six Pre-Courses (including two presented in Spanish), and live surgical demonstrations. As you can see from the numbers alone, this meeting is sure to be spectacular! The science will be a highlight, as always, but the offerings will be broad, current, and cutting-edge. Not to mention, the areas surrounding Cancun are breathtaking—it is a destination not to miss! Also, a surprise Guest Speaker is in the works and promises to be very engaging. If you haven't done so already, register for the Congress and be a part of the premier, global scientific exchange of knowledge!

I want to personally thank Dr. Stefano Zaffagnini and Dr. Volker Musahl for their great efforts on the 2019 ISAKOS Congress Program. I also want to thank the Executive Committee, Board of Directors, Committee Chairs, Co-Chairs, and members, for all of their contributions as well. Things are really moving along at a nice, steady pace, and it would not be possible without everyone involved. Most importantly, I want to thank Michele Johnson and the entire ISAKOS Office for their hard work, support and commitment to ISAKOS. I feel very honored to have support from such a great Executive Committee, Board and Office.

See you all in Cancun!

Marc R. Safran, MD

ISAKOS President, 2017–2019



12TH Biennial

ISAKOS

CONGRESS

2019

Cancun, Mexico • May 12–16, 2019

REGISTRATION

NOW OPEN!

isakos.com/2019congress



#ISAKOS2019



PRE-COURSES

SATURDAY, MAY 11, 2019

MORNING PRE-COURSES

UPDATING AND UPGRADING THE KNEE SURGICAL TECHNIQUES / ACTUALIZACIÓN Y PERFECCIONAMIENTO DE LAS TÉCNICAS QUIRÚRGICAS DE LA RODILLA (PRESENTED IN SPANISH)

**Chairs: Guillermo Arce, MD ARGENTINA
Moises Cohen, MD, PhD, Prof. BRAZIL
Joao Espregueira-Mendes, MD, PhD PORTUGAL
David Figueroa, MD CHILE**

During this pre-course, tips and tricks of the latest knee surgical techniques will be presented and thoroughly discussed in Spanish.

CURRENT CONCEPTS IN SHOULDER SURGERIES: NEW INSIGHTS IN INSTABILITY AND ROTATOR CUFF REPAIR

**Chairs: Andreas B. Imhoff, MD, Prof. GERMANY
Felix Henry Savoie, III, MD UNITED STATES**

This pre-course will present the latest techniques in shoulder stabilization and also new insights in rotator cuff repair, including tendon to bone healing and superior capsule reconstruction. Each presentation will be moderated separately to involve attendees.

KNEE ARTHROPLASTY: ALL YOU NEED TO KNOW

**Chairs: Myles R.J. Coolican, FRACS AUSTRALIA
Sebastien Lustig, MD, PhD, Prof. FRANCE**

Following this pre-course, participants will be able to understand how to do a primary TKA and how to treat more difficult cases such as severe varus or valgus deformity by total knee arthroplasty. Indications and surgical techniques for unicompartmental knee arthroplasty and BCR TKA will also be reviewed and discussed.

AFTERNOON PRE-COURSES

UPDATING AND UPGRADING THE SHOULDER SURGICAL TECHNIQUES / ACTUALIZACIÓN Y PERFECCIONAMIENTO DE LAS TÉCNICAS QUIRÚRGICAS DEL HOMBRO (PRESENTED IN SPANISH)

**Chairs: Guillermo Arce, MD ARGENTINA
Emilio Calvo MD, PhD, MBA SPAIN
Benno Ejnisman, MD BRAZIL**

Case-based pre-course approaching the latest shoulder controversies and surgical techniques with a thorough discussion in Spanish.

THE SPORTS MEDICINE PHYSICIAN

**Chairs: Sérgio Rocha Piedade, MD, PhD,
Assoc. Prof. BRAZIL**

**Scott C. Faucett MD, MS UNITED STATES
Alan Getgood, MD, FRCS (Tr&Orth), DipSEM CANADA
Mark Robert Hutchinson, MD UNITED STATES**

The goal of this pre-course is to promote understanding of topics in sports medicine, discussing and sharing academic and clinical experiences of a sports medicine physician practice, and offering up-to-date information on such topics as: sports practice principles, special clinical conditions, biologic treatment in sports injuries, sports trauma of the head, face, spine, abdomen, groin, and the role of the sports medicine physician at major events in sports including extreme sports, winter games, Olympic games and martial arts.

MASTERCLASS IN KNEE SPORTS AND PRESERVATION SURGERY: A CASE BASED APPROACH

**Chairs: Mark Clatworthy, FRACS NEW ZEALAND
Elizabeth A. Arendt, MD UNITED STATES
Seth L. Sherman, MD UNITED STATES
Sachin R. Tapasvi, MBBS, MS, DNB, FRCS INDIA
Christopher J. Vertullo, MBBS, FRACS (Orth),
FAOrthA AUSTRALIA
Timothy S. Whitehead, MBBS, FRACS
AUSTRALIA**

This pre-course will offer participants advanced case-based surgical techniques in knee sports and preservation. The following topics will be presented: complex ACL and revision, PCL and multi-ligament knee surgery, meniscal repair, root and ramp lesion repair, combined ACL and HTO surgery, osteotomies for lateral compartment OA, treatment for large chondral defects, patella instability and OA treatment in the young and athletic.



SPORTS REHABILITATION CONCURRENT COURSE: THE GLOBAL PERSPECTIVE

**Chairs: Lynn Snyder-Mackler, PT, ScD, FAPTA
UNITED STATES**

Luciana De Michelis, PT, PhD BRAZIL

Eric Witvrouw, PT, PhD BELGIUM

ISAKOS is pleased to offer the fourth ISAKOS Sports Rehabilitation Concurrent Course. The Sports Rehabilitation Concurrent Course will be held on Sunday, May 12 through Tuesday, May 14. The Course is intended for physicians, athletic trainers, physiotherapists and coaches concerned with the management or prevention of injuries to the athlete. These topics will be viewed through the international perspective of a diverse and multinational faculty of orthopaedic surgeons and physical therapists.

INVITED FACULTY

Annunziato Amendola, MD
UNITED STATES

Clare L. Ardern PT, PhD
SWEDEN

Jeremie Michael Axe, MD
UNITED STATES

Michael James Axe, MD
UNITED STATES

Klaus Bak, MD DENMARK

Eduardo Benegas, MD BRAZIL

Charles H. Brown, Jr., MD UAE

E. Lyle Cain, Jr., MD
UNITED STATES

Paula R. Camargo, PhD, PT
BRAZIL

Jacob John Capin PT, DPT, MS
UNITED STATES

Roman Cugat, MD SPAIN

David H. Dejour, MD FRANCE

Stefano Della Villa, MD ITALY

Jeffrey R. Dugas, MD
UNITED STATES

Benno Ejnisman, MD BRAZIL

Todd Sidney Ellenbecker, DPT,
MS UNITED STATES

Joao Espregueira-Mendes MD,
PhD PORTUGAL

Julian A. Feller, FRACS
AUSTRALIA

Magnus Forssblad, MD, PhD,
Assoc. Prof. SWEDEN

Karin Gravare Silbernagel, PhD,
PT, ATC UNITED STATES

Bryan Heiderscheit, PT, PhD
UNITED STATES

Timothy E. Hewett, PhD
UNITED STATES

Per Hölmich, MD, DMSc
DENMARK

James J. Irrgang, PT, PhD, FAPTA
UNITED STATES

Elizaveta Kon, Prof., MD ITALY

Robert F. LaPrade, MD, PhD
UNITED STATES

Nicola Maffulli, MD, PhD, MS,
FRCS(Orth)
UNITED KINGDOM

Robert A. Magnusson, MD
UNITED STATES

Anthony Miniaci, MD, FRCS
UNITED STATES

Volker Musahl, MD
UNITED STATES

John Nyland, PT, PhD
UNITED STATES

Luke O'Brien, PT, MPhty, SCS
UNITED STATES

Rebecca Russo, PhD ITALY

Marc R. Safran, MD
UNITED STATES

Laura C. Schmitt, PT, PhD
UNITED STATES

Sachin R. Tapasvi MBBS, MS,
DNB, FRCS INDIA

Peter Verdonk, MD BELGIUM

Kevin Wilk, PT, DPT
UNITED STATES

Barbara Wondrasch, PT, PhD
AUSTRIA

ELBOW

- Medial and Lateral Epicondylitis of the Elbow
- Management of Tennis Elbow
- UCL Rehab
- Innovations in Arthroscopic UCL

FOOT & ANKLE

- Orthopaedic Management of Ankle Instability
- Achilles Tendinopathy
- Rehabilitation After Achilles Tendon Repair
- Rehabilitation of Running Injuries

HIP

- Growth Factors and Healing
- Procedure Modified Rehabilitation
- Hip Arthroscopy
- Rehabilitation After Hip Arthroscopy

KNEE-DEGENERATIVE DISEASE

- Overview of Articular Cartilage Surgery
- Rehabilitation After Articular Cartilage Surgery
- Non-Operative Management of Knee Osteoarthritis
- Surgical Options for Osteoarthritis
- Functional Testing Algorithm for the Knee

KNEE-SPORTS MEDICINE

- Biomechanics of Exercise for the Knee and Lower Extremity
- Non-Operative Management of ACL Injuries
- Advances in ACL Reconstruction
- Immediate Post-Operative Rehabilitation After ACL Reconstruction
- Return to Sports After ACL Reconstruction: A Surgeon's Perspective
- Return to Sports Training After ACL Reconstruction
- Criteria for Return to Sports After ACLR
- Procedure Modified Rehabilitation
- Orthopaedic Outcomes: Measuring What We Do
- Objective Testing of Knee Ligaments
- PCL and PLC Reconstruction
- Osteotomy for the Management of Knee Ligament Injuries
- Meniscus Repair and ACL Reconstruction in Athletes
- Rehabilitation for Meniscus Injuries
- Non-Operative Management of Patellofemoral Pain
- Surgical Management of Patellofemoral Pain and Instability
- Evidence for Lower Extremity Injury Prevention
- Advanced Rehab and Training After ACL
- Rehabilitation of the Multi-ligament Injured Knee

MUSCLE & TENDON SPORTS INJURIES

- Evidence Based Prevention of Muscle and Tendon Injuries in Soccer Players
- Rehabilitation of Lower Extremity Muscle Injuries in Football
- Rehabilitation of Patellar Tendiopathy
- Treatment Options for Tendinopathy: What is the Evidence
- Rehabilitation of Hamstring Injuries

SHOULDER

- Biomechanics of Shoulder Function
- Operative Management of Shoulder Instability
- Biceps Tenodesis and SLAP
- Post-Operative Rehabilitation After Rotator Cuff Repair
- Biceps and SLAP Rehabilitation
- Functional Testing of the Shoulder
- Scapular Dysfunction

SPORTS MEDICINE

- Olympic Sports Medicine: Lessons from Korea
- Report from the Knee Registries
- Evidence-Based Rehabilitation – The View of a Journal Editor
- New Horizons: BEAR ACL Repair



LECTURES

BIOLOGICS FOR MENISCAL HEALING

Christopher Harner, MD UNITED STATES
Takeshi Muneta, MD, PhD JAPAN
Isato Sekiya, MD, PhD JAPAN

MIDDLE-AGED ACTIVE ATHLETE'S KNEE OSTEOARTHRITIS

Tahsin Beyzadeoglu, Prof. MD TURKEY
Iftach Hetsroni, MD ISRAEL

STEM-CELL-BASED THERAPY IN CARTILAGE REPAIR: FROM BENCH TO CLINIC

Bert R. Mandelbaum, MD, DHL (hon) UNITED STATES
Norimasa Nakamura, MD, PhD JAPAN

UNDERSTANDING THE HISTORY OF ARTHROSCOPY, KNEE SURGERY, AND ORTHOPAEDIC SPORTS MEDICINE

Philippe Landreau, MD QATAR
Stefano Zaffagnini, MD, Prof. ITALY



DEBATES

ANKLE ARTHRODESIS VS. ANKLE PROSTHESIS: THE UPDATED BATTLE

Chair: Rodrigo Maestu, MD ARGENTINA
Matteo Romagnoli, MD ITALY

THE LATARJET PROCEDURE: FIVE CONTINENTS' APPROACH

Chair: Philippe Landreau, MD QATAR

Eiji Itoi, MD, PhD JAPAN
Laurent Lafosse, MD FRANCE
Matthew T. Provencher, MD UNITED STATES

MEDIAL OSTEOARTHRITIS IN THE YOUNG AND ACTIVE ADULT: UKA VS. HTO

Chair: Myles R.J. Coolican, FRACS AUSTRALIA

Sebastien Lustig, MD, PhD, Prof. FRANCE
Andrew J. Price, D.Phil, FRCS(Orth) UNITED KINGDOM

THE ROLE OF SYNTHETIC LIGAMENTS IN FOOT AND ANKLE SURGERY: THE FUTURE?

Chair: Stéphane Guillo, MD FRANCE

Nasef M.N. Abdelatif, MD, PhD EGYPT

WHAT WORKS BEST FOR THE ATHLETE: MENISCAL REPAIR OR RESECTION?

Chair: Andy Williams, MBBS, FRCS, FRCS (Orth), FFSEM(UK) UNITED KINGDOM

Moises Cohen, MD, PhD, Prof. BRAZIL
Darren L. Johnson, MD UNITED STATES

INSTRUCTIONAL COURSE LECTURES

ANKLE & FOOT

ANKLE CARTILAGE REPAIR: HOW TO INDICATE THE APPROPRIATE TREATMENT

Chairs: MaCalus V. Hogan, MD UNITED STATES

Yasuhito Tanaka, Prof. JAPAN

Pieter D'Hooghe, MD, MSc, MBA, PhD(c) QATAR

Umile Giuseppe Longo, MD, MSc, PhD ITALY

HOW TO DIAGNOSE AND TREAT ISOLATED ATHLETIC SYNDESMOTIC ANKLE INJURIES

Chair: Pieter D'Hooghe, MD, MSc, MBA, PhD(c) QATAR

Carlo Angelo Virrey Borbon, MD, FPOA,
PHILIPPINES

MaCalus V. Hogan, MD UNITED STATES

Kenneth J. Hunt, MD UNITED STATES

Hélder M.D. Pereira, MD, PORTUGAL

MINIMALLY INVASIVE SURGERY: DOES IT PLAY A ROLE IN ORTHOPAEDIC FOOT AND ANKLE SURGERY?

Chair: Thomas Bauer, MD, PhD FRANCE

Mohammad Razi, MD, ISLAMIC REPUBLIC OF IRAN

Jordi Vega, MD, SPAIN

ELBOW, WRIST & HAND

ELBOW ARTHROSCOPY: FROM BASIC TO ADVANCED

Chair: Luigi A. Pederzini, MD ITALY

Deepak N. Bhatia, MS(Orth), DNB(Orth) INDIA

Jeffrey Raymond Dugas, MD UNITED STATES

Gregory A. Hoy, FRACS, FAOrthA, FACSP,
FASMF AUSTRALIA

Gary G. Poehling, MD UNITED STATES

HAND AND WRIST INJURIES IN SPORTS

**Chair: Margaret W.M. Fok, FRCSEd (ortho), MBChB
(Otago) HONG KONG**

Gregory I. Bain, MBBS, FRACS, PhD AUSTRALIA

Shanlin Chen, MD, PhD CHINA

Bo Liu, MD CHINA

Toshiyasu Nakamura, MD, PhD JAPAN

TENDON AND LIGAMENT INJURIES IN THE ELBOW

Chair: Gregory I. Bain, MBBS, FRACS, PhD AUSTRALIA

Deepak N. Bhatia, MS(Orth), DNB(Orth) INDIA

Michael T. Freehill, MD UNITED STATES

Alessandro Marinelli, MD ITALY

Luke S. Oh, MD UNITED STATES

Kilian Wegmann, MD, PhD GERMANY

HIP

GETTING STARTED IN HIP ARTHROSCOPY

**Chair: Olufemi R. Ayeni, MD, MSc, PhD,
FRCSC CANADA**

Nicolas Bonin, MD FRANCE

Matthew J. Brick, MBChB, FRACS NEW ZEALAND

Nick Mohtadi, MD, MSc, FRCSC CANADA

Marc R. Safran, MD UNITED STATES

MANAGING DIFFICULT CASES: INNOVATIONS AND EVIDENCE IN HIP ARTHROSCOPY

Chair: Marc R. Safran, MD UNITED STATES

Nicolas Bonin, MD FRANCE

Leandro Ejnisman, MD, PhD BRAZIL

Anil S. Ranawat, MD UNITED STATES

Soshi Uchida, MD, PhD JAPAN

Ivan Wong, MD CANADA

KNEE

MANAGEMENT OF THE MULTI-LIGAMENT INJURED KNEE

**Chair: Bruce C. Twaddle, Prof., MD,
FRACS NEW ZEALAND**

David Figueroa, MD, Prof. CHILE

Brett A. Fritsch, MBBS, BSci(Med) AUSTRALIA

Fabrizio Margheritini, MD ITALY

Claudio Zorzi, MD, ITALY

MEASUREMENT OF KNEE STABILITY: IS IT IMPORTANT IN FOOTBALL?

Chair: Moises Cohen, MD, PhD, Prof. BRAZIL

Joao Espregueira-Mendes, MD, PhD PORTUGAL

Christophe H. Hulet, MD, Prof. FRANCE

Ryosuke Kuroda, MD, PhD JAPAN

Volker Musahl, MD UNITED STATES

Stefano Zaffagnini, MD, Prof. ITALY

MENISCAL ALLOGRAFTS

**Chair: Peter T. Myers, MBBS, FRACS,
FAOrthA AUSTRALIA**

Jin-Goo Kim, MD, PhD REPUBLIC OF KOREA

Tim Spalding, FRCS(Orth) UNITED KINGDOM

Kevin R. Stone, MD UNITED STATES

Peter Verdonk, MD, PhD BELGIUM

KNEE CONTINUED**PCL RECONSTRUCTION: TIPS AND TRICKS****Chairs: Francesco Giron, MD, PhD ITALY****Timothy S. Whitehead, MBBS, FRACS AUSTRALIA**

Keith W.G. Holt, MBBS, FRACS, FAOrthA AUSTRALIA

Matthew J. Matava, MD, UNITED STATES

Bruce C. Twaddle, Prof., MD, FRACS NEW ZEALAND

KNEE: ACL**HOW DO I PERFORM A STANDARD, SAFE ACL RECONSTRUCTION?****Chair: Julian A. Feller, FRACS AUSTRALIA**

Arturo Almazan, MD MEXICO

Darren L. Johnson, MD UNITED STATES

Takeshi Muneta, MD, PhD JAPAN

Peter T. Myers, MBBS, FRACS, FAOrthA AUSTRALIA

Kristian Samuelsson, Prof., MD, PhD, MSc SWEDEN

HOW TO REPAIR THE MENISCUS IN A DIFFICULT SITUATION**Chair: Philippe Beaufils, MD FRANCE**

Felipe E. Camara, MD MEXICO

Jean-Marie Fayard, MD FRANCE

Robert F. LaPrade, MD, PhD UNITED STATES

Romain Seil, MD, Prof. LUXEMBOURG

Joon Ho Wang, MD, PhD REPUBLIC OF KOREA

MANAGEMENT OF REVISION ACL**Chair: Nobuo Adachi, MD, PhD JAPAN**

David H. Dejour, MD FRANCE

Rodrigo Maestu, MD ARGENTINA

Jacques Ménétreay, Prof. SWITZERLAND

John Xerogeanes, MD UNITED STATES

PREVENTION AND MANAGEMENT OF INFECTION IN ACL RECONSTRUCTION**Chair: Christopher J. Vertullo, MBBS, FRACS (Orth), FAOrthA AUSTRALIA**

Martin Lind, Prof., MD, PhD DENMARK

Joan C. Monllau, MD, PhD, Prof. SPAIN

Rick W. Wright, MD UNITED STATES

**KNEE: ACL CONTINUED****RETURN TO SPORT TESTING AFTER ACL RECONSTRUCTION: SHOULD WE BE DOING IT?****Chair: James J. Irrgang, PT, PhD, FAPTA UNITED STATES**

Eduard Alentorn-Geli, MD, PhD SPAIN

Ricardo P. Bastos Filho, MD, PhD, Prof. BRAZIL

Timothy E. Hewett, PhD UNITED STATES

Philippe Landreau, MD QATAR

Bert R. Mandelbaum, MD, DHL (hon) UNITED STATES

Kate E. Webster, PhD AUSTRALIA

KNEE: PATELLOFEMORAL JOINT**PATELLAR DISLOCATION IN THE SKELETALLY IMMATURE PATIENT****Chair: Petri J. Sillanpää, MD, PhD FINLAND**

Jack T. Andrish, MD UNITED STATES

Franck Pierre Daniel Alix Chotel, Prof., MD, PhD FRANCE

Masataka Deie, MD, PhD, Prof. JAPAN

Daniel W. Green, MD UNITED STATES

PATELLOFEMORAL CARTILAGE DEFECTS: THE ISAKOS PERSPECTIVE**Chairs: Andreas H. Gomoll, MD UNITED STATES****Seth L. Sherman, MD UNITED STATES**

David Figueroa, MD, Prof. CHILE

Yasuyuki Ishibashi, MD JAPAN

Mario Ronga, MD, Prof. ITALY

SOFT TISSUE AND BONY PROCEDURES FOR PATELLOFEMORAL INSTABILITY: INDICATIONS AND TECHNIQUES**Chair: David Sadigursky, MD, MSc BRAZIL**

Roland M. Biedert, MD, Prof. SWITZERLAND

Jorge Chahla, MD, PhD UNITED STATES

David H. Dejour, MD FRANCE

Betina B. Hinckel, MD, PhD UNITED STATES

Martin Lind, Prof., MD, PhD DENMARK



INSTRUCTIONAL COURSE LECTURES CONTINUED

KNEE: TOTAL KNEE REPLACEMENT

CHALLENGES OF DIFFICULT PRIMARY TOTAL KNEE ARTHROPLASTY

Chair: Daniel C. Wascher, MD UNITED STATES

Felipe Ambra, MD, PhD BRAZIL
Myles R.J. Coolican, FRACS AUSTRALIA
Francois M. Kelberine, MD FRANCE
Mihai Vioreanu, MD, MCh, FFSEM, FRCSI(Tr&Orth) IRELAND

PARTIAL KNEE REPLACEMENT: INDICATION, TECHNIQUE, AND RESULTS

Chair: David Figueroa, MD, Prof. CHILE

Gabriel Baron, MD CHILE
David A. Parker, MBBS, BMedSci, FRACS AUSTRALIA
Sébastien Parratte, Prof., MD, PhD FRANCE
Andrew J. Price, D.Phil, FRCS(Orth) UNITED KINGDOM
Anders Troelsen, MD, PhD, DMSc, Prof. DENMARK

TARGET FOR APPROPRIATE ALIGNMENT

Chair: Nicolaas C. Budhiparama, MD, Assoc. Prof., FICS INDONESIA

Stephen M. Howell, MD UNITED STATES
Shuichi Matsuda, MD, PhD JAPAN
Emmanuel Thienpont, MD, MBA, PhD BELGIUM

SHOULDER

THE AC JOINT AND SCAPULA

Chair: Augustus D. Mazzocca, MS, MD UNITED STATES

Guillermo Arce, MD ARGENTINA
Klaus Bak, MD DENMARK
Knut Beitzel, MD, MA GERMANY

REVERSE SHOULDER REPLACEMENT: INDICATIONS, RESULTS, COMPLICATIONS, AND FAILURES

Chair: Anthony A. Romeo, MD UNITED STATES

Mike H. Baums, MD, PhD GERMANY
Alessandro Castagna, MD ITALY
Peter Habermeyer, MD, PhD GERMANY

SHOULDER: INSTABILITY

CASE-BASED MDI/POSTERIOR INSTABILITY OF THE SHOULDER

Chair: Felix H. Savoie III, MD UNITED STATES

Jeffrey S. Abrams, MD UNITED STATES
Knut Beitzel, MD, MA GERMANY
Bancha Chernchujit, MD THAILAND
Eiji Itoi, MD, PhD JAPAN

INSTABILITY OF THE SHOULDER: A CASE-BASED APPROACH

Chair: Andreas B. Imhoff, MD, Prof. GERMANY

Emilio Calvo, MD, PhD, MBA SPAIN
Augustus D. Mazzocca, MS, MD UNITED STATES
Manuel Fernando Mosquera, MD COLOMBIA

SHOULDER: ROTATOR CUFF

COMPLEX ISSUES IN RCR SURGERY AND ADVANCED TECHNIQUES TO SOLVE THEM

Chair: Guillermo Arce, MD ARGENTINA

Jeffrey S. Abrams, MD UNITED STATES
Giuseppe Milano, MD ITALY
Kevin D. Plancher, MD, MPH UNITED STATES
Daniel A. Slullitel, MD, Prof. ARGENTINA

EVERYTHING ROTATOR CUFF

Carina Cohen, MD BRAZIL
Francesco Franceschi, MD, PhD ITALY
Albert Lin, MD UNITED STATES

SPORTS MEDICINE

PRACTICAL APPLICATIONS OF GROWTH FACTORS, CELLS, AND NOVEL THERAPIES IN SPORT MEDICINE

Chair: Ramon Cugat, MD, PhD SPAIN

Chih-Hwa Chen, MD, Prof. TAIWAN
Alberto Gobbi, MD ITALY
Johnny Huard, PhD UNITED STATES
Rodrigo Mardones, MD CHILE



SYMPOSIA & PARTNER SOCIETY PRESENTATIONS

ANKLE & FOOT

ADVANCED INDICATIONS FOR POSTERIOR ANKLE ARTHROSCOPY

Chair: Pieter D'Hooghe, MD, MSc, MBA, PhD(c) QATAR
 Annunziato Amendola, MD UNITED STATES
 Umile Giuseppe Longo, MD, MSc, PhD ITALY
 Yasuhito Tanaka, Prof. JAPAN
 C. Niek Van Dijk, MD, PhD NETHERLANDS

ATHLETIC FOOT AND ANKLE STRESS INJURIES

Chair: Jon Karlsson, Prof. SWEDEN
 Gian L. Canata, MD ITALY
 Nicola Maffulli, MD, PhD, MS, FRCS(Orth)
 UNITED KINGDOM
 Kevin Varner, MD UNITED STATES

OPEN VS. ARTHROSCOPIC TECHNIQUES IN INSERTIONAL ACHILLES TENDINOPATHY: WHEN AND WHY?

Chair: Umile Giuseppe Longo, MD, MSc, PhD ITALY
 Gian L. Canata, MD ITALY
 Nicola Maffulli, MD, PhD, MS, FRCS(Orth)
 UNITED KINGDOM
 Hélder M.D. Pereira, MD PORTUGAL
 Mohammad Razi, MD, ISLAMIC REPUBLIC OF IRAN

CARTILAGE

CARTILAGE REPAIR OPTIONS 2019

Chair: Norimasa Nakamura, MD, PhD JAPAN
 Constance R. Chu, MD UNITED STATES
 Alberto Gobbi, MD ITALY
 James H.P. Hui, MBBS, MD, FRCS (Orth) SINGAPORE
 Aaron J. Krych, MD UNITED STATES
 Christian Lattermann, MD UNITED STATES
 Daniel Saris, MD, Prof. UNITED STATES

EDUCATION

ISAKOS GLOBAL TRAVELING FELLOWSHIP

Chair: Julian A. Feller, FRACS AUSTRALIA
 David Figueroa, MD, Prof. CHILE
 Rainer Siebold, Prof., MD GERMANY
 Dean C. Taylor, MD, UNITED STATES

ELBOW, WRIST & HAND

TREATMENT OF THE STIFF ELBOW

Chair: Luigi A. Pederzini, MD ITALY
 Gregory I. Bain, MBBS, FRACS, PhD AUSTRALIA
 Christian Lozano, MD PERU
 Alessandro Marinelli, MD ITALY
 Felix H. Savoie III, MD UNITED STATES

HIP

CAMERA OR EYEBALL? ARTHROSCOPIC VS. OPEN HIP INDICATIONS

Chair: Omer Mei-Dan, MD UNITED STATES
 Matthew J. Brick, MBChB, FRACS NEW ZEALAND
 Thierry Pauyo, MD FRCSC CANADA
 Jin Zhang, MD CHINA

HIP AND GROIN INJURIES IN ATHLETES - MANAGEMENT FROM AN INTERNATIONAL HIP PRESERVATION PERSPECTIVE: A DYNAMIC, INTERACTIVE CASE BASED DISCUSSION

Chair: Marc R. Safran, MD UNITED STATES
 Yi-Sheng Chan, MD, Prof TAIWAN
 Omer Mei-Dan, MD UNITED STATES
 Filippo Randelli, Prof. A.C. ITALY

KNEE

ANTEROLATERAL KNEE INSTABILITY: THE ISAKOS EXPERIENCE

Chair: Philippe Landreau, MD QATAR
 Andrew A. Amis, FEng, PhD, DSc UNITED KINGDOM
 Alan Getgood, MD, FRCS (Tr&Orth), DipSEM CANADA
 Camilo Helito Neto BRAZIL
 Yuichi Hoshino, MD, PhD JAPAN
 Volker Musahl, MD UNITED STATES
 Bertrand Sonnery-Cottet, MD FRANCE
 Andy Williams, MBBS, FRCS, FRCS (Orth), FFSEM(UK)
 UNITED KINGDOM

BEYOND MENISCUS REPAIR: A CASE-BASED APPROACH

Chair: Christopher C. Kaeding, MD UNITED STATES
 Roland Becker, MD, PhD, Prof. GERMANY
 Alan Getgood, MD, FRCS (Tr&Orth), DipSEM CANADA
 Bryson P. Lesniak, MD UNITED STATES
 Peter Verdonk, MD, PhD BELGIUM

SYMPOSIA & PARTNER SOCIETY PRESENTATIONS CONTINUED

KNEE CONTINUED

CASE-BASED POSTEROLATERAL CORNER RECONSTRUCTION

Chair: Robert F. LaPrade, MD, PhD UNITED STATES

José María Busto Villarreal, MD MEXICO
Brett A. Fritsch, MBBS, BSci(Med) AUSTRALIA
Timothy Lording, MBBS, FRACS AUSTRALIA
Vincenzo Madonna, MD ITALY

COMPLEX KNEE OSTEOTOMY MADE SIMPLE

Chair: Yong In, MD, PhD REPUBLIC OF KOREA

Annunziato Amendola, MD UNITED STATES
Mark Clatworthy, FRACS NEW ZEALAND
Andreas B. Imhoff, MD, Prof. GERMANY
Jacques Ménétrey, Prof. SWITZERLAND
Antonio Manuel Ortega-Basulto, MD MEXICO

FACTS ABOUT ALL RECONSTRUCTION

Chair: Masahiro Kurosaka, MD JAPAN

Steven Claes, MD, PhD BELGIUM
Alan Getgood, MD, FRCS (Tr&Orth), DipSEM CANADA
Camilo P. Helito, MD, PhD BRAZIL
Elmar Herbst, MD GERMANY
Ryosuke Kuroda, MD, PhD JAPAN
Bertrand Sonnerly-Cottet, MD FRANCE
Andy Williams, MBBS, FRCS, FRCS (Orth), FFSEM(UK)
UNITED KINGDOM
Stefano Zaffagnini, MD, Prof. ITALY

GENETICS IN KNEE INJURIES

Chair: Willem M. van der Merwe, MBChB, FCS, SA Ortho SOUTH AFRICA

Diego C. Astur, MD, PhD BRAZIL
Mario Ferretti, MD, PhD BRAZIL

INDICATIONS FOR MENISCAL TRANSPLANT IN COMPLEX KNEES

Chair: Stefano Zaffagnini, MD, Prof. ITALY

Matias Costa-Paz, MD ARGENTINA
Jong-Min Kim, MD REPUBLIC OF KOREA
Nicolas Pujol, MD FRANCE

KNEE CARTILAGE LESIONS IN ATHLETES

Chair: Andreas H. Gomoll, MD UNITED STATES

Nobuo Adachi, MD, PhD JAPAN
Stefano Della Villa, MD ITALY
Giuseppe Filardo, MD, PhD ITALY
Alberto Gobbi, MD ITALY
Bert R. Mandelbaum, MD, DHL (hon) UNITED STATES
Ken R. Zaslav, MD UNITED STATES

KNEE DISLOCATION: FROM THE EMERGENCY DEPARTMENT TO FINAL TREATMENT

Chair: Christopher Harner, MD UNITED STATES

Fabio J. Angelini, MD BRAZIL
Michail E. Chantes, Prof. GREECE
Robert F. LaPrade, MD, PhD UNITED STATES

MANAGING THE COMPLICATIONS OF KNEE OSTEOTOMY

Chair: Christopher J. Vertullo, MBBS, FRACS (Orth), FAOrthA AUSTRALIA

Annunziato Amendola, MD UNITED STATES
Marco K. Demange, MD, PhD BRAZIL
Yong In, MD, PhD REPUBLIC OF KOREA
Eiichi Nakamura, MD, PhD JAPAN

RETURN TO SPORTS AFTER KNEE SURGERY: HOW TO TEST FOR READINESS

Chair: Robert A. Magnussen, MD, MPH UNITED STATES

Roald Bahr, MD, PhD NORWAY
Julian A. Feller, FRACS AUSTRALIA
Christian Fink, Prof., MD AUSTRIA
Alli Gokeler, PhD, PT NETHERLANDS
Lynn Snyder-Mackler, PT, ScD, FAPTA UNITED STATES
Mihai Vioreanu, MD, MCh, FFSEM, FRCS(Tr&Orth) IRELAND

AANA SYMPOSIUM: STATE OF THE ART ARTHROSCOPIC MENISCAL REPAIR

Chair: Louis F. McIntyre, MD, UNITED STATES

Kevin F. Bonner, MD UNITED STATES
Christopher P. Dougherty, DO UNITED STATES
Nicholas Sgaglione, MD UNITED STATES

AOSSM: CURRENT TREATMENT STRATEGIES OF THE MULTILIGAMENT-INJURED KNEE

Chair: Annunziato Amendola, MD UNITED STATES

Steven B. Cohen, MD UNITED STATES
Christopher Harner, MD UNITED STATES
Robert G. Marx, MD, MSc, FRCSC UNITED STATES

ESSKA: TECHNICAL TIPS AND TRICKS FOR KNEE OSTEOTOMY

Faculty to be Determined

KNEE: ACL

ACL WITH REMNANT PRESERVATION: SO WHAT?

Chair: Freddie H. Fu, MD UNITED STATES

Anastasios D. Georgoulis, MD, Prof. GREECE
Eiji Kondo, MD, PhD JAPAN
Rainer Siebold, Prof., MD GERMANY
Joon Ho Wang, MD, PhD REPUBLIC OF KOREA
Kyoung Ho Yoon, MD, PhD, Prof. REPUBLIC OF KOREA

ANATOMY OF THE ACL: FROM BUNDLES TO RIBBONS AND BEYOND

Chair: Rainer Siebold, Prof., MD GERMANY

Freddie H. Fu, MD UNITED STATES
 Mirco Herbort, MD, Prof. GERMANY
 Andrew D. Pearle, MD UNITED STATES
 Robert J. Smigielski, MD POLAND
 Timothy S. Whitehead, MBBS, FRACS AUSTRALIA

THE BIOLOGICAL APPROACH TO ACL INJURY AND MANAGEMENT

Chair: Karl Eriksson, MD, PhD, Asst. Prof. SWEDEN

Peter Annear, FRACS(Orth) AUSTRALIA
 Johannes Barth, MD FRANCE
 Ryosuke Kuroda, MD, PhD JAPAN
 Timothy S. Whitehead, MBBS, FRACS AUSTRALIA

CONTROVERSIES IN ACL RECONSTRUCTION

Chair: Jon Karlsson, Prof. SWEDEN

David Figueroa, MD, Prof. CHILE
 Christian Fink, Prof., MD AUSTRIA
 Robert G. Marx, MD, MSc, FRCSC UNITED STATES
 Volker Musahl, MD UNITED STATES
 Kristian Samuelsson, Prof., MD, PhD, MSc SWEDEN
 Romain Seil, MD, Prof. LUXEMBOURG

THE FEMALE ACL: SHOULD IT BE MANAGED DIFFERENTLY?

Chair: Elvire Servien, MD, PhD, Prof. FRANCE

Constance R. Chu, MD UNITED STATES
 Mario Ferretti, MD, PhD BRAZIL
 Justin P. Roe, FRACS, A/Prof. (UNSW) AUSTRALIA
 Carola F. van Eck, MD, PhD UNITED STATES

GRAFTS IN ACL RECONSTRUCTION: YOUR CHOICE?

Chair: Jon Karlsson, Prof. SWEDEN

Shiyi Chen, MD, PhD CHINA
 Robert G. Marx, MD, MSc, FRCSC UNITED STATES
 Philippe N. Neyret, MD, PhD FRANCE
 Willem M. van der Merwe, MBChB, FCS, SA Ortho
 SOUTH AFRICA

MANAGEMENT OF THE PEDIATRIC ACL: DO WE NEED TO PROTECT PHYSIS?

Chair: Timo J. Järvelä, MD, PhD FINLAND

Arturo Almazan, MD MEXICO
 Mark Clatworthy, FRACS NEW ZEALAND
 Jonathan Riboh, MD UNITED STATES
 Justin P. Roe, FRACS, A/Prof (UNSW) AUSTRALIA
 Jeremy Stanley, BHB, MBChB, FRACS NEW ZEALAND

RETURN TO SPORT TESTING AFTER ACL RECONSTRUCTION: SHOULD WE BE DOING IT?

Chairs: John A. Bergfeld, MD UNITED STATES

Julian A. Feller, FRACS AUSTRALIA

Mark Clatworthy, FRACS NEW ZEALAND
 Moises Cohen, MD, PhD, Prof. BRAZIL
 Ryosuke Kuroda, MD, PhD JAPAN
 David A. Parker, MBBS, BMedSci, FRACS AUSTRALIA

TIME OR CRITERION BASED RETURN TO SPORT AFTER ACL RECONSTRUCTION?

Chair: Karl Eriksson, MD, PhD, Asst. Prof. SWEDEN

Parag K. Sancheti, MS (Orth), DNB (Orth), Mch (Orth),
 FRCS (Ed) INDIA
 Seth L. Sherman, MD UNITED STATES
 Simon W. Young, MD, FRACS NEW ZEALAND

WHAT HAVE WE LEARNED FROM ACL REGISTRIES AND LARGE COHORT DATA?

Chair: Tim Spalding, FRCS(Orth) UNITED KINGDOM

Magnus Forssblad, MD, PhD SWEDEN
 Christopher C. Kaeding, MD UNITED STATES
 Martin Lind, Prof., MD, PhD DENMARK
 Gregory B. Maleis, MD UNITED STATES
 Nick Mohtadi, MD, MSc, FRCSC CANADA

WHY DO ACL GRAFTS FAIL?

Chair: Timothy S. Whitehead, MBBS, FRACS AUSTRALIA

Robert G. Marx, MD, MSc, FRCSC UNITED STATES
 James R. Robinson, MBBS, MRCS, FRCS(orth), MS
 UNITED KINGDOM
 Seth L. Sherman, MD UNITED STATES
 Willem M. van der Merwe, MBChB, FCS, SA Ortho
 SOUTH AFRICA

APKASS OPTIMIZING MANAGEMENT OF ACL INJURIES: FROM INDIVIDUALIZED RECONSTRUCTION TO SAFE RETURN TO PLAY. AN ASIA-PACIFIC PERSPECTIVE

Chairs: Chih-Hwa Chen, MD, Prof. TAIWAN

Parag K. Sancheti, MS(Orth), DNB(Orth), MCh(Orth), FRCS(Ed), INDIA

Nobuo Adachi MD, PhD JAPAN
 Shiyi Chen MD, PhD, Prof. CHINA
 David A. Parker MBBS, BMedSc, FRACS AUSTRALIA
 Patrick S. Yung, FRCS(Orth), FHKCOS, FHKAM, FRCS,
 MBChB HONG KONG

SYMPOSIA & PARTNER SOCIETY PRESENTATIONS CONTINUED

KNEE: PATELLOFEMORAL JOINT

FAILURE OF PATELLOFEMORAL STABILIZATION

Chair: David H. Dejour, MD FRANCE

Elizabeth A. Arendt, MD UNITED STATES
Florian Dirisamer, MD AUSTRIA
Julian A. Feller, FRACS AUSTRALIA
Deepak R. Goyal, MBBS, MS (Ortho), DNB (Ortho) INDIA

PATELLOFEMORAL ARTHROPLASTY (PFA): INDICATIONS, TECHNICAL ASPECTS, COMPLICATIONS, AND RESULTS

**Chair: Pieter J. Erasmus, MBChB, MMed
SOUTH AFRICA**

Elizabeth A. Arendt, MD UNITED STATES
Diane L. Dahm, MD UNITED STATES
David H. Dejour, MD FRANCE
Shuichi Matsuda, MD, PhD JAPAN

THE ROLE OF TORSION IN PATELLOFEMORAL DISEASE: PAIN AND INSTABILITY

Chair: Elizabeth A. Arendt, MD UNITED STATES

Michael C. Liebensteiner, MD, PhD AUSTRIA
Christopher Powers, PhD UNITED STATES
Gerd Seitlinger, MD AUSTRIA
Robert A. Teitge, MD UNITED STATES

KNEE: TOTAL KNEE REPLACEMENT

ALIGNMENT IN TOTAL KNEE ARTHROPLASTY: IS A NEUTRAL MECHANICAL AXIS THE TARGET?

Chair: Stephen M. Howell, MD UNITED STATES

Johan Bellemans, MD, PhD BELGIUM
Michel P. Bonnin, MD, PhD FRANCE
Myles R.J. Coolican, FRACS AUSTRALIA
Shuichi Matsuda, MD, PhD JAPAN
Philippe N. Neyret, MD, PhD FRANCE

CURRENT CONTROVERSIES IN TKA

Chair: Sébastien Parratte, Prof., MD, PhD FRANCE

Paolo Adravanti, MD ITALY
Nicolaas C. Budhiparama, MD, Assoc. Prof.,
FICS INDONESIA
Yong In, MD, PhD REPUBLIC OF KOREA
Mojieb M. Manzary, MD, FRCS SAUDI ARABIA
Peter K. Sculco, MD UNITED STATES
Christopher J. Vertullo, MBBS, FRACS (Orth),
FAOrthA AUSTRALIA

HOW TO MANAGE REVISION KNEE ARTHROPLASTY

Chair: Daniel C. Wascher, MD UNITED STATES

Roland Becker, MD, PhD, Prof. GERMANY
Myung-Chul Lee, MD, PhD, Prof. REPUBLIC OF KOREA
David A. Parker, MBBS, BMedSci, FRACS AUSTRALIA
Sébastien Parratte, Prof., MD, PhD FRANCE

INFECTION MANAGEMENT IN KNEE REPLACEMENT

Chair: Sebastien Lustig, MD, PhD, Prof. FRANCE

Nicolaas C. Budhiparama, MD, Assoc. Prof.,
FICS INDONESIA
Umile Giuseppe Longo, MD, MSc, PhD ITALY
Maurilio Marcacci, MD ITALY
Akos Zahar, MD, PhD GERMANY

NEW TECHNOLOGIES IN KNEE ARTHROPLASTY

Chair: Sebastien Lustig, MD, PhD, Prof. FRANCE

David Figueroa, MD, Prof. CHILE
Fares S. Haddad, BSc, MCh (Orth), FRCS (Orth)
UNITED KINGDOM
Myung-Chul Lee, MD, PhD, Prof. REPUBLIC OF KOREA
Maurilio Marcacci, MD ITALY
Andrew D. Pearle, MD UNITED STATES

RESEARCH

ISAKOS RESEARCH SYMPOSIUM

Chair: Volker Musahl, MD UNITED STATES

Alfonso R. Barnechea Rey, MD PERU
Michael T. Hirschmann, MD SWITZERLAND
Yuichi Hoshino, MD, PhD JAPAN
Stephen L. Lyman, PhD UNITED STATES
Robert G. Marx, MD, MSc, FRCS UNITED STATES

SHOULDER

HOW TO HANDLE MAJOR AND MINOR BONE LOSS IN THE SHOULDER

Chair: Giovanni Di Giacomo, MD ITALY

Jiwu Chen, MD, PhD CHINA
Eiji Itoi, MD, PhD JAPAN
Denny T.T. Lie, MBBS, FRCS, FAMS SINGAPORE
Nahum Rosenberg, MD, FRCS ISRAEL

SHOULDER FRACTURES AND REPLACEMENTS: WHEN TO IGNORE, WHEN TO FIX, AND WHEN TO REPLACE

Chair: Felix H. Savoie III, MD UNITED STATES

Mike H. Baums, MD, PhD GERMANY
Michael T. Freehill, MD UNITED STATES
Andreas B. Imhoff, MD, Prof. GERMANY
Stephen C. Weber, MD UNITED STATES

SHOULDER: INSTABILITY

COMPLEX ISSUES IN INSTABILITY SURGERY: A CASE-BASED APPROACH

Chair: Michael T. Freehill, MD UNITED STATES

Kevin D. Plancher, MD, MPH UNITED STATES
 Kevin P. Shea, MD UNITED STATES
 Andreas Voss, MD GERMANY
 Stephen C. Weber, MD UNITED STATES

SLARD: A TEN YEAR FOLLOW-UP OF SHOULDER INSTABILITY SURGERY

Chair: Daniel A. Slullitel, MD, Prof. ARGENTINA

Guillermo Arce, MD ARGENTINA
 Fabio Restrepo Tello, Profesor COLOMBIA
 Vicente Gutierrez, MD CHILE
 Melchor Iván Encalada-Díaz, MD MEXICO

SHOULDER: ROTATOR CUFF

THE FAILED ROTATOR CUFF REPAIR

Chair: Giuseppe Milano, MD ITALY

Francesco Franceschi, MD, PhD ITALY
 Dan Guttman, MD UNITED STATES
 Soheil Mehdipoor, MD ISLAMIC REPUBLIC OF IRAN
 Anthony A. Romeo, MD UNITED STATES

MASSIVE ROTATOR CUFF TEARS: WHEN TO REPAIR OR REPLACE

Chair: Guillermo Arce, MD ARGENTINA

Angel Calvo, MD SPAIN
 Andreas B. Imhoff, MD, Prof. GERMANY
 Eiji Itoi, MD, PhD JAPAN
 Richard K.N. Ryu, MD UNITED STATES

ROTATOR CUFF REPAIR: A CASE-BASED APPROACH

Chair: Angel Calvo, MD SPAIN


Michail E. Chantes, Prof. GREECE
 Mark Ferguson, MD SINGAPORE
 Mauricio Gutierrez, MD COLOMBIA
 Daniel A. Slullitel, MD, Prof. ARGENTINA

SPORTS MEDICINE

TEAM PHYSICIAN: AN INTERNATIONAL PERSPECTIVE

Chair: Marc R. Safran, MD UNITED STATES

Ryuichiro Akagi, MD, PhD JAPAN
 José F. Huylebroek, MD BELGIUM
 Peter A. Indelicato, MD UNITED STATES
 Antonio Maestro, MD, PhD SPAIN
 Fernando Radice, MD CHILE



THE INTERACTIVE AGENDA HAS A NEW LOOK!

Save the ISAKOS Congress Web App for Access on the Go!

isakos.com/interactiveagenda

Now more mobile, tablet and computer friendly! The Interactive web app includes:

- LIVE agendas by day, room, or session type
- Faculty Profiles
- Linked Abstracts, Outlines & Presentations
- Search and Sort Filters
- Collapsible and Expandable Viewing
- Save Favorites to mySchedule
- 5-Star Rating System
- Electronic Question Queue (On-Site)
- Interactive Exhibits Floorplan & Directory
- Congress PDF Programs & Downloads
- *And More!*

Extraction of Broken Drill Bit During Hip Arthroscopy: A Technical Note



Allston J. Stubbs, MD
Wake Forest University
School of Medicine
Winston Salem, UNITED STATES

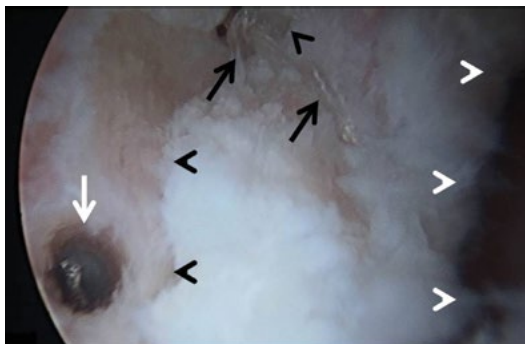


Halis Atıl Atilla, MD
Ankara, TURKEY

Introduction

Labral repair is one of the most commonly performed procedures during hip arthroscopy¹, and labral reconstruction continues to be on the rise. Suture anchors are routinely used to secure the labrum back onto the acetabulum, but their use presents certain technical challenges^{2,3,4}. Reported intraoperative complications associated with the use of implants and instrumentation during hip arthroscopy include breakage of the tip of the arthroscope, grasper, and guide wire; articular cartilage damage; penetration of the labrum; and fixation failure^{5,6,7}. To our knowledge, breakage of the drill bit during predrilling for anchor placement and subsequent retrieval of the retained drill bit from the acetabular rim during hip arthroscopy has not been reported.

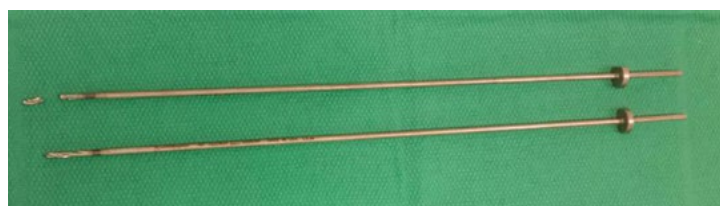This article and accompanying video demonstrate a technique for the extraction of a broken drill bit from the acetabular rim with use of standard hip arthroscopy equipment. The described technique demonstrates that replacing the broken drill bit with a bigger anchor is a potential salvage option.



01

Pearls

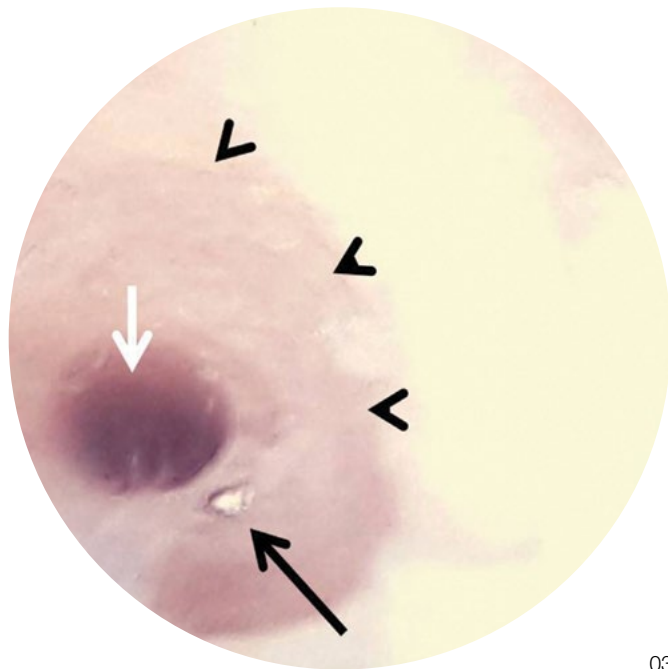
1. Checking the tip of the instruments prior to use is important in order to recognize a broken instrument.
2. An awareness of the traction time is important in order to prevent additional complications when trying to retrieve the broken drill bit. Consider revisiting the broken bit after addressing all other pathologies that had already been present preoperatively.
3. Wash out the involved area and remove the debris from around the broken drill bit hole in order to estimate the extent of embedment.
4. The new holes should be placed on the extra-articular side of the failed hole to ensure an intact articular side wall for the final hole.
5. When levering the embedded drill bit from the new hole, slightly shallowing and combining the entrances of both holes is important in order to avoid excessive levering forces against the walls of the combined holes.
6. Levering of the broken drill bit should be started with a 30° microfracture awl, proceeding to a 45° awl if needed.
7. During all steps, washing out the debris with a suction shaver is important in order to more clearly visualize the end of the broken drill bit.
8. In order to achieve a good trajectory without penetrating a second cortex or forcing the drill bit in difficult angles, consider additional portals.
9. In muscular patients, intraoperative muscle relaxation is crucial in order to obtain adequate distraction and handling.
10. The hole left behind after extraction of the broken drill bit can be salvaged with a larger-diameter anchor for labral repair.
11. Consider using magnetic instruments for the retrieval of broken instruments.



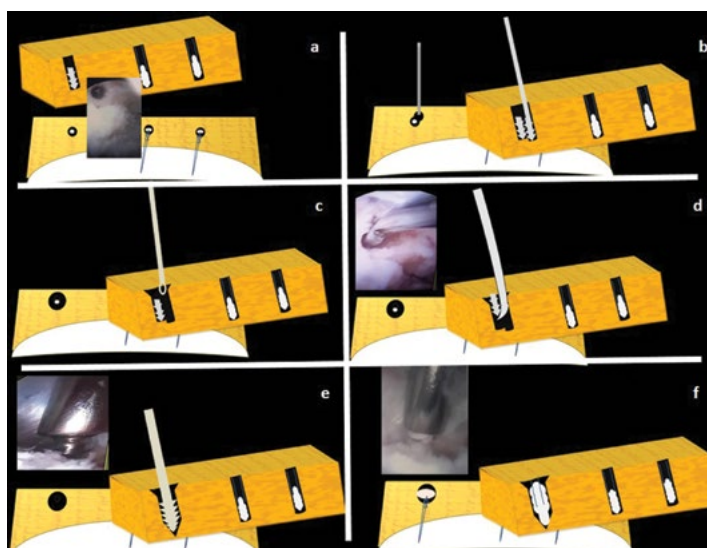
02

Pitfalls

1. In order avoid pushing the broken bit deeper, care should be taken to ensure that the new adjacent hole is parallel to, adjacent to, and in the same orientation as the broken drill hole.
2. Levering with a microfracture awl should be gentle in order to avoid breakage of the awl, creation of a larger defect, or fracture of the bone.
3. Care should be taken when extracting the broken drill bit so that it is not lost in the soft tissue.



03



01 A-F

Reference

1. Kelly BT, Weiland DE, Schenker ML, Philippon MJ. Arthroscopic labral repair in the hip: surgical technique and review of the literature. *Arthroscopy*. 2005;21:1496-504.
2. Weigel DP, Callaghan JJ. Use of anchor sutures to repair labral avulsions of the hip: a brief report. *Iowa Orthop J*. 1997;17:141-3.
3. Stubbs AJ, Andersen JS, Mannava S, Wooster BM, Howse EA, Winter SB. Arthroscopic hip labral repair: the iberian suture technique. *Arthrosc Tech*. 2014; 27:3:e351-4.
4. Hernandez JD, McGrath BE. Safe angle for suture anchor insertion during acetabular labral repair. *Arthroscopy*. 2008; 24: 1390-94
5. Park MS, Yoon SJ, Kim YJ, Chung WC. Hip arthroscopy for femoroacetabular impingement: the changing nature and severity of associated complications over time. *Arthroscopy*. 2014 ;30:957-63.
6. Lertwanich P, Ejnisman L, Torry MR, Giphart JE, Philippon MJ. Defining a safety margin for labral suture anchor insertion using the acetabular rim angle. *Am J Sports Med*. 2011;39 Suppl:111S-6S.
7. Matsuda DK, Bharam S, White BJ, Matsuda NA, Safran M. Anchor-induced chondral damage in the hip. *J Hip Preserv Surg*. 2015;29:2:56-64.

- 01 Broken Drill Bit Within Acetabular Rim: White arrow indicates the broken and embedded drill bit within acetabular rim. Black arrows indicate the adjacent labral repair and sutures. White arrow heads indicate the articular side, and black arrow heads indicate the bony labral interface.
- 02 Broken Drill Bit after Extraction: Broken drill bit after extraction in comparison with an intact one.
- 03 New Opened Hole for The Extraction: Black arrow shows end on view of the broken and retained drill bit, white arrow shows newly made adjacent drill hole, black arrow heads indicate the circumferentially curetted and shallowed bony area to have a clear view.
- 01A Broken drill bit embedded in the acetabular rim presented with 2D and 3D illustrations and arthroscopic views of the event. White crescent shaped structure represents the labrum which had already secured with two suture anchors.
- 01B A adjacent hole is opened slightly deeper than embedded drill bit
- 01C An open arthroscopic curette is used to enlarge the entrance of the holes.
- 01D A 30 degree microfracture pick is used to dislodge the broken drill bit.
- 01E Tapping for a larger size anchor.
- 01F Replacement of the broken drill bit hole with a 4.5 suture anchor.

The Stiff Elbow: Classification and Treatment Algorithm



Alessandro Marinelli, MD
Istituto Ortopedico Rizzoli
Bologna, ITALY

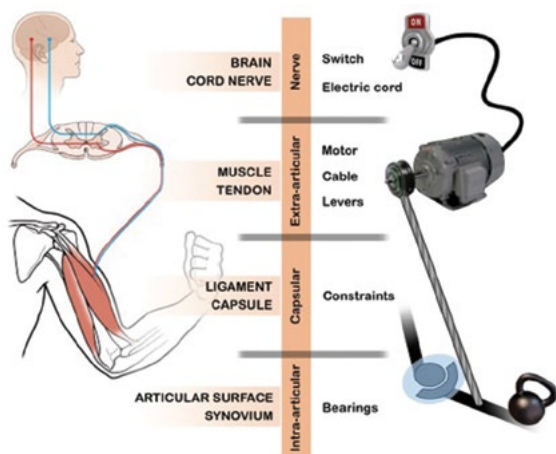


Gregory Bain, MD, PhD
Flinders University
Adelaide, AUSTRALIA

Introduction

Elbow motion, which is essential for upper-extremity function and the ability to position the hand in space, is created by a cascade of anatomical zones that enable the “elbow machine” to be mobilized (Fig. 1). The normal physiological motion of the elbow is 140° to 150° of flexion-extension and 140° to 150° of pronation-supination.

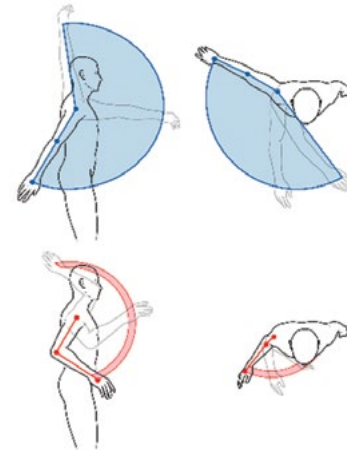
Elbow stiffness is the most frequent presentation in the outpatient elbow clinic. The reason is that the elbow is prone to stiffness after injury or surgery and the adjacent joints provide only limited compensatory motion.



01

Therefore, even mild or moderate loss of elbow motion is perceived as disabling (Fig. 2).

Morrey noted that most activities of daily living can be performed with an arc of 100° of elbow flexion (30° to 130°) and 100° of forearm rotation (50° of pronation and 50° of supination). However, greater motion may be required for personal hygiene, dressing, eating, holding the phone to the ear, and typing.



02

As a general rule, deficits of flexion and supination are harder to compensate for. For example, when reaching, grabbing, and manipulating an object, a pronation deficit can be partially compensated for with shoulder abduction and an extension deficit can be compensated for by bringing the object closer to the body. Without adequate flexion, however, it is difficult to bring the hand to the mouth or to perform grooming or toileting activities. Similarly, without supination, it is difficult to receive coins and to lift objects.

Etiology

A variety of elbow disorders can cause stiffness, with the most common being post-traumatic in origin; this category also includes burns, head injury, and elbow surgery. However, elbow stiffness also can be caused by atraumatic etiologies, such as osteoarthritis, inflammatory joint disease, infection, metabolic disease (e.g., hemophilia), and congenital conditions (arthrogryposis).

The typical etiology of joint stiffness involves an initial insult (such as trauma to the joint morphology¹), followed by a healing response (soft-tissue contracture of the capsule, ligaments, and muscles), and then by the development of secondary changes (avascular necrosis and degeneration), all of which will affect the severity of stiffness when the patient presents for treatment. In addition, heterotopic ossification (HO) can restrict the joint or compress the ulnar nerve. It is important to recognize the notion of time spanning the initial insult, the healing response, and the secondary changes. The final common pathway is to develop degenerative arthritis of the joint.

This entire process is well described in the ISAKOS article on “The Pathogenesis and Classification of Shoulder Stiffness.”¹ All of these factors affect the presentation of the patient, the likely natural history, and the outcome of surgical intervention.

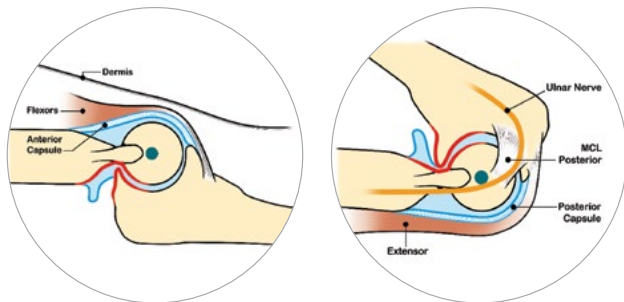
Imaging

Radiographs are used to evaluate joint congruency, joint space and articular degeneration, heterotopic ossification, osseous deformity and non-union, and the presence and location of internal fixation.

Computerized tomography (CT) provides a greater resolution of the osseous structures and therefore is very useful for surgical planning. In particular, 2D and 3D CT reconstructions are useful for evaluating mild joint incongruity, degeneration, loose bodies, the morphology of osteophytes (including their size, shape, location, and interaction with the fossae on the anterior and posterior aspects of the elbow), and the proximity of heterotopic ossification to vascular and nerve structures.

Classification

A number of classification systems have been developed for elbow stiffness. We will review some of these systems and highlight their clinical utility.



03

Plane of Motion

Stiffness can be classified according to whether it affects flexion-extension, pronation-supination, or both planes of motion. This classification system is practical for evaluating patient impairment and for planning surgery (Fig. 3).

Severity

In this system, the contracture is graded on the basis of the flexion-extension arc of motion as minimal ($>91^\circ$), moderate (61° to 90°), severe (31° to 60°), or very severe ($\leq 30^\circ$). This classification is simple and practical for assessment, prognosis, and surgical decision-making. It can also be used to evaluate impairment and improvement.

Etiology

Elbow stiffness can be classified on the basis of etiology as post-traumatic, micro-traumatic, degenerative or inflammatory, neurogenic, and other (congenital, tumor, burns, infection, etc.). This system is useful for evaluating treatment indications.

Prognosis

Jupiter et al. divided post-traumatic elbow stiffness into 2 categories: simple and complex². Simple stiffness is characterized by mild to moderate contracture (motion, $>80^\circ$), no prior surgery, minimal heterotopic ossification, and a well-preserved osseous anatomy.

Complex stiffness is associated with nerve dysfunction, prior nerve transposition, retained hardware, substantial heterotopic ossification, articular incongruity, and an arc of motion of $<80^\circ$. This system is useful for evaluating the risks and benefits of surgical treatment as the complex form is associated with a higher surgical complication rate and requires more expertise.

Anatomical Location

Morrey classified elbow stiffness into 3 categories on the basis of anatomical location and etiology: extrinsic, intrinsic, and mixed (Morrey, 2005). *Extrinsic factors* (i.e., extra-articular factors that spare the joint space) include capsular-ligament contracture, muscle-tendon retraction, ulnar nerve neuropathy, heterotopic ossification, and skin contracture. *Intrinsic factors* (i.e., intra-articular factors) include intra-articular adhesions and deformities, cartilage lesions, loose-bodies, and impinging osteophytes. *Mixed factors* are those that have both intrinsic and extrinsic elements. Until now, this system has been the most commonly used tool for the classification of joint stiffness.

In 2010, Watts and Bain³ recommended that the capsule be considered as a separate category as it is a separate anatomical structure with a different etiology, treatment, and prognosis. Isolated capsular contractures can be caused by immobilization or hemiarthrosis. Capsular contractures also are commonly noted in association with intra-articular pathologies. In cases of elbow stiffness, capsular contracture is often the main problem to be addressed as it is uniquely positioned to interact with both the intra-articular and extra-articular factors.

- 01 Diagram illustrating the concept of the “elbow machine,” which helps to understanding how the joint moves and highlights the 4 distinct anatomical areas where disorders may affect elbow motion. (Copyright Drs. G. Bain and A. Marinelli).
- 02 Diagrams illustrating why elbow stiffness is a disabling condition. The blue regions show the areas that are reachable by the hand with a full range of motion of the shoulder and elbow. The red regions represent the much smaller areas that are reachable by the hand with a normal shoulder but a 90° elbow flexion contracture.
- 03 Diagrams illustrating anatomical factors that can restrict extension (left) and flexion (right). With restricted extension, it may be necessary to release the contracted anterior soft tissues (anterior capsule, flexor muscles, dermis) and/or to excise any posterior osseous impingement. With restricted flexion, it may be necessary to release the contracted posterior soft tissues (the posterior band of the MCL, posterior capsule, triceps) and/or to excise any anterior osseous impingement. (Copyright Dr. A. Marinelli).

The Stiff Elbow: Classification and Treatment Algorithm

With the incorporation of the capsule as a separate category and the addition of neurological factors, a new all-inclusive classification can be proposed. The advantage of this classification is that is all-inclusive, including all causes of elbow stiffness, not only post-traumatic ones. Moreover, with the correct identification of the pathological process present in each area, this classification allows the surgeon to address each component, and tailor the appropriate treatment.

Intra-articular pathologies can be managed with joint arthroscopy (eg chondral flaps, loose bodies, impinging osteophytes or synovitis). In advanced cases, simple debridement is unlikely to be successful; in which case a joint arthroplasty is required.

TABLE I. All-Inclusive Pathoanatomical Classification of Elbow Stiffness

INTRA-ARTICULAR (Bearings)	CAPSULAR (Constraints)	EXTRA-ARTICULAR (Motor, Cable, Levers)	NEUROLOGICAL (Control, Electrics, Sensors)
Articular surface involvement (osteochondral defect, degeneration)	Ligament involvement (contracture, calcifications)	Muscle involvement (myopathy, fatty infiltration)	Central nervous system involvement (behavioral dystonia, spasticity)
Subchondral dysplasia, fractures, avascular necrosis, degeneration	Capsular involvement (contracture, calcifications)	Tendon and bursa involvement (tears, calcifications, degeneration, bursitis)	Peripheral nervous system involvement (ulnar, radial, medial nerve symptoms; cutaneous nerve neuritis or neuropathy)
Synovial inflammation, crystal arthroplasty	Congruity-related findings (subluxation, dislocation)	Other findings external to elbow (fracture, malignancy, heterotopic ossification, skin contracture)	Sensory and autonomic findings (Charcot joint, chronic regional pain syndrome)

Based on the ISAKOS shoulder stiffness classification¹, this all-inclusive pathoanatomical classification of elbow stiffness makes it possible to identify the 4 causes of elbow stiffness: intra-articular, capsular, extra-articular, and neurological (Table I). As Morrey noted, some cases have a mixed etiology.

The advantage of this classification system is that is all-inclusive and includes all causes of elbow stiffness, not just post-traumatic causes. Moreover, with the correct identification of the pathological process in each area, this classification system allows the surgeon to address each component and tailor the treatment appropriately.

- Intra-articular pathologies (e.g., chondral flaps, loose bodies, impinging osteophytes, or synovitis) can be treated with joint arthroscopy. In advanced cases, simple debridement is unlikely to be successful and a joint arthroplasty is required.
- Extra-articular pathologies (e.g., heterotopic ossification, ulnar nerve neuropathy, and muscle/tendon contractures) are usually treated with an open procedure with resection or release of the offending structures. Endoscopic treatment for these conditions is possible but is still evolving.
- Capsular contractures can be treated with open or arthroscopic release or resection, usually with a good outcome.
- Cases with mixed causes require each area be specifically addressed.

S.T.I.F. Classification

TABLE II. S.T.I.F. Classification System*

S.T.I.F. CLASSIFICATION STIFFNESS TYPES & INFLUENCING FACTORS	
PREVALENT TYPE OF STIFFNESS	TREATMENT and PROGNOSIS INFLUENCING FACTORS
1 SOFT TISSUE CONTRACTURE	a ULNAR NERVE SYMPTOMS
2 ARTHRITIS	b HARDWARE / PRIOR SURGERY
3 H. O.	c LCL / MCL CALCIFICATION
4 MALUNION / NON-UNION	d SKIN CONTRACTURE
5 CHRONIC SUBLUXATION	e ARTICULAR PAIN
	f LOOSE BODIES

*The S.T.I.F. system details the 5 common causes of stiffness and the 6 influencing factors. (Copyright Dr. A. Marinelli.)

In 1998, Kay⁴ proposed a practical classification for post-traumatic stiffness of the elbow that was based on the presence, severity, and combination of the 3 most common factors causing stiffness (capsular contracture, articular fractures, and heterotopic ossification), identifying 5 clinical situations.

More recently, in collaboration with Shawn O'Driscoll from the Mayo Clinic, members of our department (Roberto Rotini, Alessandro Marinelli, Enrico Guerra) developed the S.T.I.F. (Stiffness Types and Influencing Factors) classification system (Table II)⁵. This system, which was presented for the first time at the Rizzoli Elbow Course 2017 in Bologna, highlights the 5 common disorders causing stiffness as well as the 6 influencing factors that often effect the treatment and clinical outcome. The S.T.I.F. classification system also highlights the importance of the ulnar nerve, which can be entrapped in the cubital tunnel by scar tissue or heterotopic ossification and is at risk during the surgical treatment of elbow stiffness.

Treatment Algorithm

TABLE III. The S.T.I.F. Treatment Algorithm for Elbow Stiffness*

DECISIONAL TREATMENT ALGORITHM FOR ELBOW STIFFNESS RELEASE		
PREVALENT TYPE OF STIFFNESS	SURGERY	APPROACH
1 SOFT TISSUE CONTRACTURE	- Release - Release (column procedure)	SCOPE OPEN
2 ARTHRITIS	Mild or Moderate arthritis - Osteo-capsular arthroplasty	SCOPE OPEN COMBINED
	Severe arthritis - Biologic interposition / Distraction arthroplasty (External Fixators) - TEA (> 70ys)	OPEN
3 H. O.	- Removal	OPEN
4 MALUNION / NON-UNION	- ORIF / Osteotomy - TEA (> 70ys)	OPEN
5 CHRONIC SUBLUXATION	- Rad. Head / Coron. / Ligam. reconstr. / External Fixators - TEA (> 70ys or not possible reconstruction)	OPEN

*The type of stiffness, its severity, and the age of the patient are all factors that direct the preferred type of surgery. H.O. = heterotopic ossification, TEA = total elbow arthroplasty, and ORIF = open reduction and internal fixation. (Copyright Dr. A. Marinelli)

We propose a treatment algorithm, based the S.T.I.F. classification system, that includes the severity of the disorder as a guide to surgical treatment and the preferred operative approach (open or arthroscopic) (Table III).

Conclusion

Over the last 20 years, we have witnessed dramatic changes in the approach to elbow stiffness. Understanding the involved plane of movement as well as the severity and etiology of the stiffness is important. There have been advances in the methods of assessment of osseous disorders (including 2D and 3D CT scanning) and in the evolution of surgical techniques (open and arthroscopic). The elbow machine diagram is useful for identifying how the joint is mobilized and for understanding the causes of joint stiffness.

The new classification system highlights the etiology of the stiffness and provides a framework to better understand the natural history, direct the surgical management, and interpret the likely clinical outcome.

Other important factors that affect the decision-making process, dictate the preferred treatment, and likely affect the outcome include the ulnar nerve, existing implants, and prior surgery (Table IV).

TABLE IV. Elements to Consider When Assessing Elbow Stiffness*

PATIENT
Age, comorbidities, needs, expectations, compliance
ELBOW
Flexion/forearm rotation
Duration of stiffness/improvements
Stability/congruency
Pain
Neurological symptoms
Prior surgery/internal fixation
Skin condition
Prior surgery
ADJACENT JOINTS
Hand/shoulder/neck function

*Copyright Dr. A. Marinelli.

Reference

1. Bain GI, Clitherow HDS. The Pathogenesis and Classification of Shoulder Stiffness. In E. Itoi et al. (eds.), *Shoulder Stiffness: Current Concepts and Concerns*, ISAKOS 2015. 2. Jupiter JB, O'Driscoll SW and Cohen MS. The assessment and management of the stiff elbow. *Instr Course Lect* 2003;52:93-111. 3. Watts AC, Bain GI. New Techniques in Elbow Arthroscopy. In: AANA Advanced Arthroscopy: The elbow and wrist. Editors Savoie FH & Field LD, Philadelphia: Saunders-Elsevier; 2010:124-131. 4. Kay NR. Arthrolysis of the post-traumatic stiff elbow. In Stanley D, Kay NR, editors. *Surgery of the elbow*. London: Arnold; 1998. P 228-34 5. Marinelli A, Rotini R, Guerra E, O'Driscoll S. The S.T.I.F classification: a new classification for elbow stiffness, considering Stiffness Types and Influencing Factors. Presented at the Rizzoli Elbow Course, Bologna (Italy) 2017.

Trends in Total Knee Arthroplasty in South America



David Figueroa, MD
Santiago, CHILE



Francisco Figueroa, MD, Prof.
Santiago, CHILE

Orthopaedics Department, Knee Section Facultad de Medicina Clínica Alemana-Universidad del Desarrollo Santiago, CHILE

In the present article, we will discuss common controversies related to total knee arthroplasty (TKA), review different trends in our region (as indicated by a recent survey of 316 South American surgeons), compare these trends with those in other regions, and propose our preferred management.

Stabilization Method

Retention or sacrifice of the posterior cruciate ligament (PCL) remains controversial. Both strategies provide advantages and disadvantages, but there is no consensus regarding which approach provides superior outcomes. The PCL plays a crucial role in femoral rollback, allowing adequate flexion and granting efficiency to the extensor mechanism, and therefore efforts to preserve this structure during prosthetic surgery have been attempted. However, the current evidence is ambiguous: some studies have shown higher success rates in association with PCL sacrifice, whereas others have demonstrated proprioceptive and biomechanical benefits in association with PCL retention. Moreover, PCL retention is associated with lower cost (cheaper implants) and less bone loss, allowing future revision surgery with posterior-stabilized designs.

Our survey indicated that posterior-sacrificing (PS) implants are the most commonly used design in South America, with 73% of surgeons preferring them over cruciate-retaining (CR) implants (17.87%) and Medial Pivot implants (9.13%). This trend is contrary to those in other regions. For example, 7 of the top 10 most commonly used TKA prostheses in the Australian registry and almost 70% of those in the New Zealand joint registry are CR implants.

In the United Kingdom, the National Joint Registry (covering England, Wales, Northern Ireland, and the Isle of Man) shows the same tendency, with about two-thirds of primary TKAs being performed with CR implants. It is important to note that in all of these registries, CR implants perform better than PS implants in terms of the rate of revision.

Given the successful outcomes that have been reported in association with both techniques, and on the basis of expert recommendations, we reserve PCL-retention surgery for patients without substantial varus or valgus malalignment or flexion contracture. Consequently, we perform PCL-sacrificing surgery in patients with substantial malalignment or flexion contracture of the knee, as well as in those with inflammatory diseases, previous osteotomies, or patellectomy, because PCL sacrifice has been associated with better results in these groups.

Fixation Method

For the last 20 years, cement fixation has been the standard practice, with excellent implant survival rates (90% to 95% at 15 years of follow-up). Although cement fixation provides an immediate stable interface between the bone and the implant, it is well known that this method compromises bone stock. In the 1980s, manufacturers developed cementless implants, which hypothetically helped to preserve bone stock, for use in high-demand patients who were potential candidates for revision surgery in the future. However, studies revealed that cementless fixation was associated with increased micro-movement of the tibial component and early aseptic loosening of the implant. These findings led to a rapid decrease in the popularity of cementless implants and the development of hybrid implants (featuring cemented tibial and patellar components and uncemented femoral components), which demonstrated good intermediate-term results.

In our region, cemented fixation of the femoral and tibial components was preferred by 97.72% of the surgeons surveyed. This rate was similar to those in the New Zealand and United Kingdom registries, which indicate that cemented implants are used in approximately 100% and 85% of cases, respectively. On the other hand, the Australian registry shows that about one-third of procedures are performed with hybrid fixation (i.e., an uncemented femoral implant and a cemented tibial implant) and 20% are performed with cementless implants. It is important to note that, in the Australian registry, hybrid implants are associated with a lower rate of revision compared with cemented and cementless implants, whereas in the New Zealand and United Kingdom registries, cemented implants perform better.

Our standard practice today is to insert all components with cement as there are no substantial data to support changing this practice. However, we recognize that some series have demonstrated promising results in association with hybrid fixation and are expecting more evidence-based studies on this topic.

Patellar Resurfacing

The question of whether to resurface the patella or to leave the native patella unresurfaced continues to be debated among orthopaedic surgeons. Some of the traditional indications for patellar resurfacing include older age, anterior knee pain, patellofemoral symptoms, radiographic changes in patellofemoral joint, inflammatory arthropathy (e.g., rheumatoid arthritis), obesity, intraoperative maltracking, history of patellar dislocation, and a nonanatomical patellar trochlear groove on the femoral component. In contrast, the traditional recommendations for not resurfacing the patella have included a short, thin patella; younger age; osteoarthritis or non-inflammatory arthritis; well-preserved patellar cartilage; congruent patellar tracking intraoperatively; an inadequate patellar size or thickness for resurfacing; and a femoral component with an anatomic trochlear groove for the native patella.

Our survey revealed that almost half (49.8%) of South American surgeons prefer to resurface the patella in every case, 26.4% never resurface the patella, and 23.77% resurface the patella optionally. We believe patellar resurfacing may be increasing due to medicolegal implications.

In our group, surgeons favor resurfacing the patella; however, in some cases, we may decide not to resurface the patella on the basis of the intraoperative findings.

Computer Navigation

Computerized assistance to guide and aid in implantation (a technique known as *navigation*) was developed to increase the accuracy of prosthesis insertion. Considering that failures related to bone cuts and extremity alignment occur in up to 8% of patients, emerging efforts to reduce this rate are worthy. Navigation has demonstrated better results in terms of component positioning when compared with standard practice.

During the last few years, the emphasis has been on simplifying navigation systems, especially in terms of image capture. Thanks to newly developed optic systems, previous image capture is no longer needed, extending the use of navigation systems in clinical practice.

Despite the use of a guidance system, navigation presents the potential for errors resulting from software failures, inadequate instrument calibration, and incorrect landmark recognition. This last point is the most critical issue, because the surgeon is responsible for providing adequate anatomic references for an appropriate prosthesis insertion. Recent studies have shown that a 2-mm inaccuracy when recognizing femoral condyles produce a rotational error of 1° in the femoral component. Thus, although navigation may improve component alignment, errors can still occur during the process of making the bone cuts, leading to component malposition.

This limitation has led to the development of robotic-assisted TKA in an effort to facilitate the preparation of bone surfaces. The term *robot* refers to any mechanical device that is accurately controlled by a computer with the use of intelligent software.

Our survey revealed that only 4.5% of South American surgeons use computer navigation routinely in their practices. Even fewer (0.75%) use robotic surgery. On the other hand, almost 30% of Australian surgeons use computer navigation as an aid during TKA surgery, with a similar rate in Germany. However, only about 1% of surgeons in the United States use navigation.

While we do not currently use navigation/robotic surgery in our practice, we believe that it is an important component of the future of knee arthroplasty.

Conclusions

As there are no specific prosthesis registries for Latin America, we think that our survey provides valuable information regarding the preferences among surgeons in our region. We estimate that TKA procedures have doubled in our region in the last 5 years. This trend implies an enormous challenge for our region in terms of developing adequate health and economic policies to meet the increasing need for prosthetic knee surgery as well as the expected future increase in revisions.

19th INTERNATIONAL SPORTS MEDICINE FELLOWS CONFERENCE
January 18-20, 2019
Carlsbad, California

**2019 ISAKOS
ISMF Scholarship**

ISAKOS is pleased to offer the opportunity to three international sports medicine fellows to attend the International Sports Medicine Fellows Conference in Carlsbad, California. This scholarship is intended to promote better understanding and communication regarding injuries or conditions as related to sports medicine.

APPLY TODAY!
Deadline September 15
isakos.com/Awards/ISMFScholarship

Strategies to Minimize Blood Loss in TKR Surgery



Mihai Vioreanu, MD, FRCSI
Sports Surgery Clinic
Dublin, IRELAND

Introduction

Despite significant advances in implant design and fixation leading to improved survival and function following total knee replacement (TKR), the blood loss associated with this procedure remains a concern. Estimates of blood loss following TKR surgery have ranged from 800 to 1,700 mL. Most of this blood loss is “hidden” and occurs during the immediate postoperative period as the majority of procedures are performed under tourniquet control.

The aims of minimizing blood loss in TKR surgery are to reduce or eliminate the need for postoperative blood transfusion while optimizing postoperative hemoglobin (Hgb) and maximizing oxygen-carrying capacity. Decreasing will enhance patient recovery and improve the final clinical outcome. The average Hgb loss associated with primary TKR surgery has been calculated to be 3.8 mg/dL. The blood-transfusion trigger should be individualized on the basis of the risks and benefits for each patient. Previous studies have demonstrated allogenic blood transfusion rates of as high as 39% in association with TKR surgery. Several studies have highlighted the disadvantages of allogenic blood transfusions, including an increased rate of medical postoperative complications, an increased duration of hospitalization stay, and increased mortality.

Blood-management strategies should be individualized on the basis of patient-specific risk factors, the anticipated difficulty of the procedure, the expected blood loss, and associated medical comorbidities. A multimodal, evidence-based strategy is needed to reduce transfusion rates, postoperative complications, readmission rates, the length of stay, and mortality. Such a multimodal strategy should incorporate preoperative, intraoperative, and postoperative protocols (Table I).

TABLE I Summary of Strategies to Minimize Blood Loss in TKR Surgery

Preoperative	Intraoperative	Postoperative
<ul style="list-style-type: none"> Assessment and optimization of Hgb level <ul style="list-style-type: none"> Routine and timely measurement of Hgb Investigation of cause of low Hgb Administration of iron supplements Cessation of antiplatelet and anticoagulant medication 	<ul style="list-style-type: none"> Efficient surgical technique and meticulous hemostasis Use of tranexamic acid (TXA) <ul style="list-style-type: none"> Intravenous Topical 	<ul style="list-style-type: none"> No drain use Use of tranexamic acid (TXA) <ul style="list-style-type: none"> Intravenous Oral Immobilization in flexion

Preoperative Assessment and Optimization of Hgb Level

Several studies have demonstrated a relationship between the preoperative Hgb level and the need for blood transfusion after joint replacement surgery. The reported prevalence of anemia before arthroplasty surgery has ranged from 15% to 39%. Very few patients with a preoperative Hgb level of >15 g/dL require allogenic blood, whereas patients with a preoperative Hgb level of <11 g/dL have been reported to have a transfusion rate of 100%. Other factors that increase the risk for blood transfusion include increased weight (BMI >27 kg/cm²), an age of >75 years, male gender, and hypertension. In patients with multiple risk factors, optimizing the preoperative Hgb level is essential not only because doing so reduces the need for blood transfusion but also because it has a positive physiological impact on patient rehabilitation and functional recovery.

Ideally, all patients who are scheduled for elective TKR should undergo testing of the Hgb level within a timeframe that will allow for the treatment of a low Hgb level before surgery. At our institution, all patients are scheduled for an anesthetic consultation at least 4 weeks prior to the date of surgery. Any patient with anemia (Hgb <12 g/dL) is further investigated to determine the underlying cause and appropriate treatment. The most common reason for a low Hgb level in these patients is iron-deficiency anemia (low Hb and low ferritin). The options for optimizing the Hb level preoperatively include treatment with iron supplements and erythropoietin.

Iron supplements Can be administered orally or intravenously, but intravenous treatment appears to be more effective for raising Hb levels in a shorter period of time.

More specifically, it was also demonstrated superior efficiency and easier administration procedures with ferric carboxymaltose compared with iron sucrose. It should be noted that intravenous administration of ferric carboxymaltose may pose a rare but significant risk of anaphylaxis and therefore in-hospital administration and monitoring should be considered.

Erythropoietin is a powerful synthetic hormone that activates hematopoiesis, but it is expensive and we are not routinely using it at our institution for the treatment of preoperative anemia.

Another aspect of the preoperative assessment is managing the routine administration of **antiplatelet or anticoagulant medication** in order to reduce perioperative blood loss. The decision and timing of cessation of such medication before surgery must weigh the risk of bleeding against the risk of thrombosis. At our institution, patients receiving warfarin are asked to stop taking their anticoagulant medication 5 days prior to surgery. In order to minimize their thrombotic risk, those patients are managed with bridge therapy with low molecular-weight heparin during that time and with resumption of their previous anticoagulant medication immediately postoperatively. We also routinely stop antiplatelet medication, aspirin, and more modern anticoagulants (i.e., thrombin inhibitors and factor-Xa inhibitors) 5 to 7 days preoperatively and restart the medication immediately postoperatively. When a patient has undergone recent cardiac stenting (within 1 year previously), the opinion of the cardiologist is sought to evaluate the risk of thrombosis and the potential for a cardiac event if the anticoagulant medication is stopped.

Since we introduced this simple Hgb screening and optimization program at our institution, the blood transfusion rate has dropped significantly despite an increased volume of TKR surgery. An internal audit revealed that the rate of blood transfusion in our clinic decreased from 6.6% (21 of 317) in 2011 to 0.12% (1 of 812) in 2017 (unpublished data).

Intraoperative Blood-Management Protocol

Surgical factors such as the difficulty and duration of the procedure along with patient-related factors such as comorbidities, high BMI, and bleeding disorders have an impact on intraoperative blood loss. Employing an efficient surgical technique with careful dissection, soft-tissue handling, and meticulous hemostasis based on the detailed vascular anatomy around the knee joint is paramount for achieving good bleeding control and minimizing intraarticular blood loss. Additional factors that should be considered as part of the intraoperative blood-management strategy are briefly discussed below.

Use of Tranexamic Acid (TXA)

TXA is a synthetic form of lysine that prevents fibrinolysis by blocking the receptor site on plasminogen, thus preventing binding to fibrin and subsequent clot degradation.

The use of TXA in surgery in general and arthroplasty in particular has been reported widely; it is most commonly administered intravenously but also can be administered orally and topically. Multiple Level-I studies of patients undergoing TKR have shown that the perioperative administration of TXA has been associated with significant reductions in postoperative bleeding and the rate of blood transfusion, without an increase in the risk of venous thromboembolism. A recent meta-analysis of RCTs evaluating the effectiveness of TXA in primary TKR surgery showed that, when compared with placebo, TXA reduced blood loss by roughly 500 mL and resulted in 1.43 fewer units of blood being transfused per patient. There is, however, no clear consensus on the ideal dosage, timing, and route of administration for TXA in TKR surgery. The current recommendation for intravenous TXA is a single dose of 10 to 15 mg/kg. Both oral and topical administration of TXA have shown similar effectiveness to intravenous administration, and some authors have recommended a combined form of TXA administration. At our institution, we use a combination of single intravenous dose of TXA (15 mg/kg) before releasing the tourniquet and applying topical TXA (2 g) before skin closure.

Use of Tourniquet

Tourniquet usage in TKR surgery is still common practice among arthroplasty surgeons. A 2010 survey indicated that 95% of arthroplasty surgeons in North America use a tourniquet during TKR surgery, and the National Joint Registry in the United Kingdom reported that 93% of primary knee replacements in 2003 were performed under tourniquet control. The proposed advantages of routine tourniquet usage include improved visualization, decreased intraoperative blood loss, lower transfusion rates, and, possibly, superior cementation of components.

Recent awareness has been raised about the potential detrimental functional effects that result from routine tourniquet use. The use of a tourniquet may be a risk factor for postoperative thromboembolism, minor wound complications, and increased postoperative pain related to tissue hypoxia and reperfusion injury. Persistent lower postoperative quadriceps strength at 3 months of follow-up also has been reported in association with use of a tourniquet during TKR surgery. Some authors have recommended using a tourniquet during cementation of the components only. However, recent studies have suggested that TKR surgery that is performed without the use of tourniquet does not influence component fixation in the short term.

Strategies to Minimize Blood Loss in TKR Surgery

Currently, with improved perioperative blood-conservation methods such as spinal anesthesia and routine use of anti-fibrinolytic therapy with use of TXA, prolonged tourniquet use during TKR surgery does not appear to have a significant clinical impact on perioperative blood loss and transfusion requirements and may not be justified given its known association with higher rates of postoperative complications and slowed functional recovery.

Postoperative Blood-Management Protocol Use of Drains

Drains historically have been used in knee replacement surgery for the theoretical benefits of preventing wound hematoma, improving wound-healing, and preventing infection. However, drains have never been definitively shown to be of any benefit in THR or TKR surgery. Meta-analyses comparing drains and no drains consistently have shown that drains result in increased total blood loss and increased requirements for blood transfusion without any difference in terms of hematoma formation, surgical site infection, or reoperation for any reason. A 2007 Cochrane review of the available data indicated that there was insufficient evidence to support use of closed suction drainage in orthopaedic surgery.

Positioning the Knee in Flexion Immediately Postoperatively

Postoperative knee flexion is a simple and cost-effective intervention that can reduce postoperative blood loss and transfusion requirements. Positioning the knee in high flexion ($>90^\circ$) over a bent pillow for 6 hours immediately postoperatively has been shown to significantly reduce blood loss compared with positioning the knee either in flexion for 3 hours or in full extension, with no detrimental effect on the ultimate range of movement.

Conclusion

An effective blood-management strategy in TKR surgery focuses on minimizing perioperative blood loss, reducing the blood transfusion rate, and maximizing the Hgb level and oxygen-carrying capacity in the postoperative period. There is no single intervention that will reduce blood loss in TKR surgery. A multimodal blood-management strategy should include preoperative assessment and Hgb optimization, intraoperative use of TXA along with meticulous hemostasis, and immobilization in high flexion during the immediate postoperative period. A proactive approach to blood management will have a positive effect on early and long-term outcomes and will lead to greater success in the care of TKR patients.

Reference

1. Liu D, Dan M, Martinez Martos S, Beller E. Blood Management Strategies in Total Knee Arthroplasty. *Knee Surgery & Related Research*. 2016;28(3):179-187.
2. Su E, Su S. Strategies for reducing perioperative blood loss in total knee arthroplasty
3. Yang ZG, Chen WP, Wu LD. Effectiveness and safety of tranexamic acid in reducing blood loss in total knee arthroplasty: A meta-analysis. *J Bone Joint Surg Am*. 2012;94:1153-9.
4. Parker MJ, Livingstone V, Clifton R, McKee A. Closed suction surgical wound drainage after orthopaedic surgery. *Cochrane Database of Systematic Reviews* 2007, Issue 3. Art.
5. Napier RJ, Bennett D, McConway J, Wilson R, Sykes AM, Doran E, O'Brien S, Beverland DE. The influence of immediate knee flexion on blood loss and other parameters following total knee replacement *Bone Joint J* 2014;96-B:201-9.

2025 ISAKOS Congress Request For Proposal

We are pleased to announce the Request for Proposal for the 15th Biennial ISAKOS Congress. The ISAKOS Site Selection Committee asks all members to consider their region as a future Congress location. Please note, the rotation of locations indicates the 2025 Congress would most likely be in Europe.

2025 ISAKOS Congress – Europe

**Expression of Interest Forms Due:
January 1, 2019**

Members: RFP information and form can be found in your myISAKOS Dashboard

Log in at isakos.com/myISAKOS

Update on Meniscal Allograft Transplantation



Seth L. Sherman, MD
University of Missouri Department of
Orthopaedic Surgery
Columbia, MO UNITED STATES



Trevor R. Gulbrandsen, BS
University of Missouri School of Medicine
Columbia, MO UNITED STATES



Dimitri M. Thomas, MD
University of Missouri Department of
Orthopaedic Surgery
Columbia, MO UNITED STATES

Introduction

The knee meniscus contributes to shock absorption, joint lubrication, chondroprotection, proprioception, secondary stabilization, and load distribution. Given its critical role, surgeons should err on the side of meniscal preservation whenever possible. For symptomatic patients with meniscal deficiency, meniscal allograft transplantation (MAT) has evolved as a reliable surgical option for this challenging clinical problem.

The goal of MAT is to restore the biomechanical properties of the native damaged meniscus, thereby reducing pain, increasing overall knee function, and improving quality of life. Successful MAT requires careful management of patient expectations, appropriate patient selection, thorough preoperative planning, meticulous surgical technique, and adherence to postoperative rehabilitation guidelines. While some evidence-based recommendations exist, controversy remains regarding MAT indications, techniques, and outcomes.

Indications

MAT is indicated for patients with symptomatic post-meniscectomy syndrome following previous subtotal or functional meniscectomy. Patients often present with painful effusions and unicompartamental pain following previous injury or surgery. MAT may be considered when symptoms persist despite appropriate conservative management (e.g., unloader bracing, nonsteroidal anti-inflammatory drugs, biologic injections, rehabilitation programs). The role of prophylactic MAT remains highly controversial. While meniscal deficiency may progress toward radiographic evidence of joint-space narrowing over time, clinical symptoms do not accurately correlate. Additionally, there is no definitive evidence that MAT decreases the radiographic advancement of osteoarthritis (OA) or that the duration of allograft survival following MAT is >1 to 2 decades. Given these considerations, MAT is not routinely indicated for patients with asymptomatic meniscal deficiency, and for those who should be counseled effectively and monitored closely for signs and/or symptoms of post-meniscectomy syndrome.

MAT also may be indicated for patients with meniscal deficiency as a result of failed primary anterior cruciate ligament (ACL) reconstruction or chronic ACL insufficiency. It is well known that the medial meniscus plays a critical role as a secondary stabilizer to anterior tibial translation (i.e., brake stop mechanism) and that the lateral meniscus likely has a stabilizing effect during the pivot shift. MAT may be considered as an adjunct to ACL reconstruction in patients with functional instability and meniscal deficiency, particularly those with high-grade sagittal instability (grade IIIB on the Lachman test) and/or explosive pivot shift (Grade III on the pivot-shift test). Another important indication is the presence of meniscal deficiency in the setting of a symptomatic cartilage lesion. This scenario is most often encountered in the lateral compartment. In such cases, the addition of MAT can be considered as a means of optimizing the outcome of cartilage restoration.

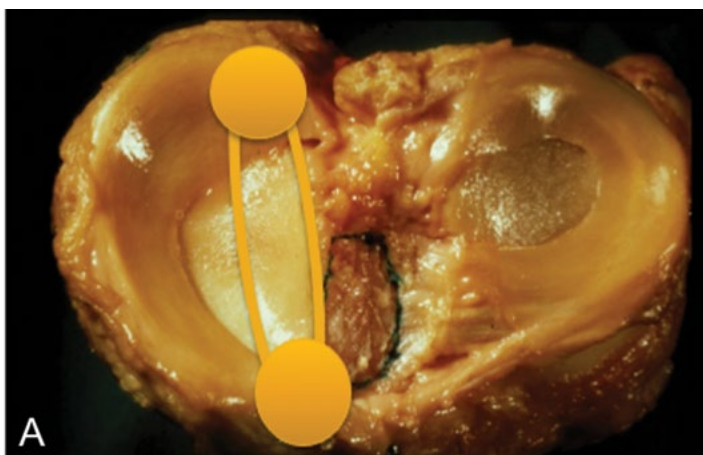
Applied Surgical Anatomy

Understanding the unique anatomical and biomechanical characteristics of the medial and lateral menisci is necessary when considering the addition of MAT in one's clinical practice. These striking differences influence the timing and frequency of MAT, the need for concomitant procedures, and, possibly, the selection of surgical technique.

The medial tibial plateau is concave, with the meniscus covering approximately 64% of the plateau and bearing an average of 50% of the load. As a result, medial meniscectomy is often well tolerated, with a delayed (or absent) or post-meniscectomy syndrome and decreased need for concomitant cartilage restoration with medial MAT. The medial meniscus is inherently more stable than the lateral meniscus through attachments of the meniscotibial (coronary) ligaments to the deep MCL. Reproducing these meniscotibial ligament insertions can be considered during medial MAT.

Update on Meniscal Allograft Transplantation

As previously discussed, the medial meniscus is a secondary stabilizer to anterior translation, and medial MAT combined with ACL reconstruction can be indicated for the treatment of instability. The medial meniscus has a wide spread between the root insertions; these insertions have an oblique orientation in the axial plane, and the anterior root inserts over the front of the tibia (Fig. 1A). These properties have implications for choice of MAT surgical technique. Many surgeons prefer soft tissue only or bone plug meniscus for medial MAT because of the advantages of maintained bone stock, ease of concomitant ACL reconstruction, and/or avoidance of the native ACL insertion.

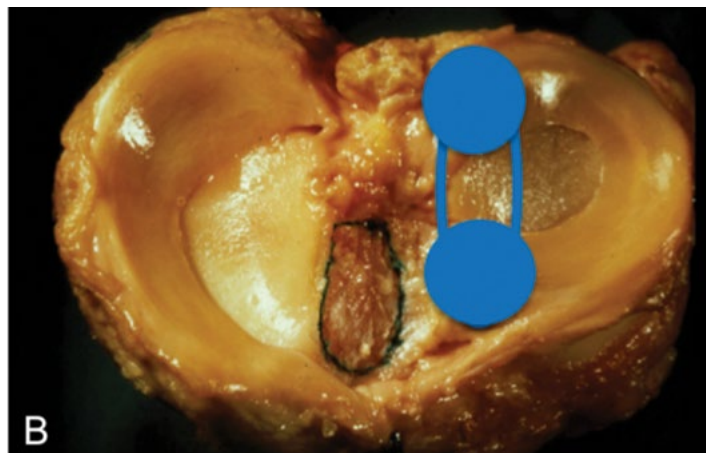


01 A

The lateral tibial plateau is convex, with the lateral meniscus covering 85% of the plateau and bearing 70% of the load. As a result, lateral meniscectomy is often poorly tolerated, with a higher incidence of symptomatic post-meniscectomy syndrome. In addition, there is a greater risk of chondral degeneration and earlier clinical symptoms following lateral meniscectomy as compared to medial meniscectomy. Therefore, in the setting of lateral meniscal deficiency, concomitant cartilage restoration is often required. The lateral meniscus is O-shaped, with a vertical orientation in the axial plane and a small spread between the meniscal roots (Fig. 1B). Given these findings, many surgeons prefer bone-block lateral MAT because of the advantages of a fixed distance between the meniscal roots and strong time-zero root fixation. The lateral meniscus is more mobile, with no attachments near the popliteal hiatus. Surgeons must be careful to avoid overconstraint of lateral MAT during fixation to avoid nonphysiological tension and early graft extrusion.

Treatment of Concomitant Pathology

When performing MAT, surgeons must recognize and address all associated pathologies, including high-grade cartilage defects, ligament insufficiency, and limb malalignment. Failure to correct concomitant pathology is a predictor of poor outcome and is associated with early transplant failure.



01 B

With increased understanding of and advancement in techniques, staged or simultaneous treatment of these comorbidities has resulted in comparable outcomes when compared with isolated MAT. In addition to careful history, physical examination, and radiographic evaluation, staging arthroscopy is often a useful tool in the surgeon's arsenal. This allows the surgeon to perform a careful examination with the patient under anesthesia, including stress radiography when indicated, to identify the exact size and location of any chondral lesions and to perform intra-articular lysis of scar adhesions resulting from prior surgery. In the setting of limb malalignment, extra-articular osteotomy also can be performed at the time of staging arthroscopy. Intra-articular procedures such as ligament reconstruction, cartilage restoration, and meniscal transplantation then can be performed during a second stage as needed. Alternatively, all comorbidities can be addressed in a single stage at the time of MAT.

Limb malalignment is evaluated clinically and with the use of a long-leg radiograph, which is a mandatory part of the preoperative work-up. The mechanical axis should be corrected to neutral if the patient has $>3^\circ$ of mechanical axis deviation, but it is critical to avoid overcorrection in these cases. Lateral opening-wedge or medial closing-wedge distal femoral osteotomy is often the treatment of choice for the correction of valgus malalignment, whereas opening-wedge proximal tibial osteotomy is used to correct varus malalignment. If alignment is corrected at the time of staging arthroscopy, the patient may be observed postoperatively and, if he or she is asymptomatic, MAT and other intra-articular procedures may be avoided.

Ligament insufficiency involving the ACL, the posterior cruciate ligament (PCL), the posterolateral corner, and/or the posteromedial corner is a known risk factor for the failure of meniscal repair and MAT. Ligament repair or reconstruction is usually performed in the same setting as MAT. Cartilage restoration and MAT are symbiotic and should be performed in the same setting.

As severe (grade III-IV) untreated chondral disease is a contraindication to MAT, meniscal deficiency is also a contraindication to cartilage restoration. Similarly, the combined procedures enhance the outcomes of each other. The treatment choice for cartilage restoration is lesion-specific and typically is performed through an open approach after arthroscopic or arthroscopic-assisted MAT. Additionally, surgeons can complete the anterior horn MAT fixation during the open portion of the procedure (Fig. 2).

Graft Sizing

Preoperative MAT graft sizing is critical. Errors can result in improper biomechanics, meniscal extrusion, and failure. Grafts should be within 10% of the size of the native meniscus. If necessary, it is always preferable to use an undersized graft rather than an oversized one because of the increased risk of meniscal extrusion and early failure associated with oversized grafts. Additionally, proper mediolateral sizing is more important than anteroposterior sizing. For medial MAT, the Pollard x-ray method may be used for the determination of length and width. For lateral MAT, the Yoon equation for length and the arthropometric method for width may be preferred. If cost is not a concern, contralateral magnetic resonance imaging is accurate and useful for sizing.

Surgical Options for Meniscal Transplantation

TABLE I Meniscal Allograft Transplant Technique

	Soft Tissue	Bone Plug	Bone Bridge
Technical Difficulty	Least difficult	Somewhat	Most difficult
Clinical Outcomes	Similar	Similar	Similar
Graft Survival	Similar	Similar	Similar
Graft Extrusion	Higher risk	Lower risk	Lower risk
Bone Stock	Most preserved	Preserved	Least preserved
Accommodate for Graft Mismatch	Not difficult	Not difficult	Most difficult
Violates ACL Insertion for Medial MAT	No	No	Yes
Difficulty "Flipping" Meniscus	No	No	Yes

The ideal MAT technique is minimally invasive and reproducible, preserves bone stock, provides the surgeon with the ability to handle graft mismatch, and provides anatomical footprint restoration with secure time-zero fixation. Three standard surgical techniques are used for root fixation: soft-tissue only, double bone plug, and bone in slot (bone bridge/trough) (Table I).

02 Soft tissue-only fixation is commonly performed worldwide. It is technically the easiest option, with similar clinical and functional outcomes as the osseous procedures. However, there remains concern regarding increased risk of graft extrusion.

- 01 Photographs of a left knee, showing (A) the wide spread and oblique root insertions of the medial meniscus (orange) and (B) the narrow, linear root insertions of the lateral meniscus (blue). The anterior cruciate ligament footprint is outlined in black.
- 02 Arthroscopic photograph made during lateral MAT with concomitant treatment of a focal ICRS grade-III chondral lesion of the lateral femoral condyle.

There are two common osseous root-fixation techniques: the bone bridge technique and the bone plug technique. The bone bridge MAT technique has strong time-zero fixation as the relationship between the anterior and posterior meniscal roots is maintained. This technique has some disadvantages, including the loss of bone stock, the difficulty of dealing with graft-size mismatch, and the technical challenge of “flipping” the meniscus into place.

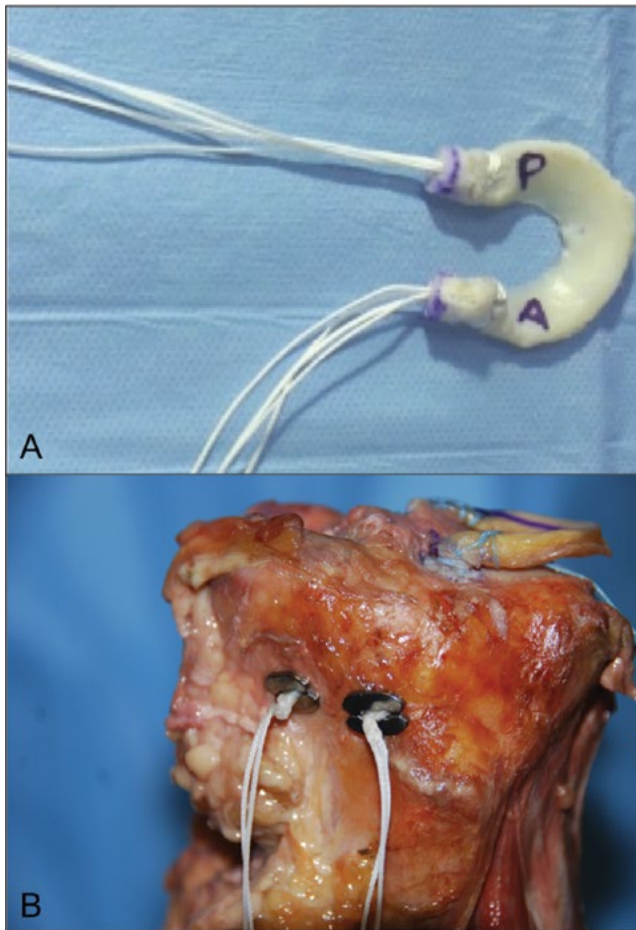
Update on Meniscal Allograft Transplantation

The traditional bone plug MAT technique is bone stock-preserving. It also is easier to accommodate graft-size mismatch. There is no required “flipping” of the meniscal transplant as there is with the bone bridge technique. Nevertheless, this technique is associated with several challenges and disadvantages, including a lack time-zero fixation strength, the challenge of seating plugs with a depth of 8 mm to 10 mm, and a difficulty in the lateral compartment due to close proximity of the lateral meniscal root insertions and the risk of tunnel overlap.

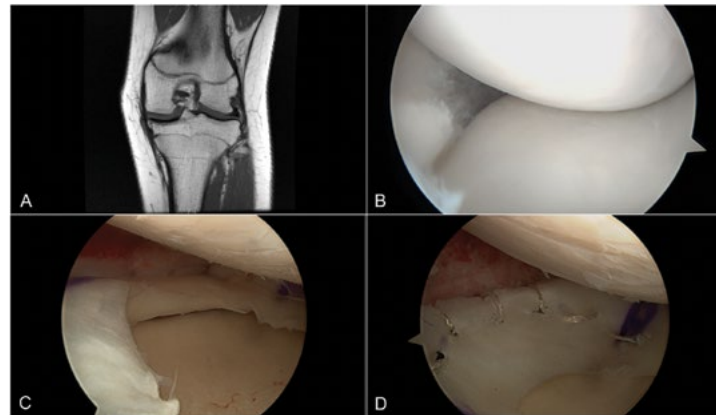
Evolving techniques seek to combine the most favorable aspects of the three standard root-fixation strategies.

Our preferred technique for arthroscopic MAT is to use anatomic bone sockets and adjustable suspensory cortical fixation with wide (9-mm) but short (3-mm) bone plugs (Fig. 3). The advantages of this technique include the ability to perform medial and lateral MAT during the same procedure, strong independent time-zero root fixation, the ability to adjust for graft mismatch in real time, and the preservation of bone stock with less concern about “burning bridges” in the case of future revision.

The native meniscus should be meticulously prepared to a 2-mm to 3-mm rim of healthy remaining tissue if possible. A shaver and/or manual rasp can be used to create a healthy healing surface. The meniscal graft is typically fixed with use of a hybrid repair strategy that involves strong root fixation, all-inside sutures posteriorly, inside-out sutures for the mid-body, and an outside-in technique anteriorly. In total, at least eight fixation points are usually sufficient for meniscal healing (Fig. 4). For medial MAT, additional meniscotibial fixation may be considered. Native capsular plication to the tibia also may be considered to reduce the risk of early graft extrusion.



03



04

Regardless of the chosen technique, access to the medial or lateral compartment is critical for the technical execution of MAT. In the medial compartment, access may be improved by a combination of deep MCL trephination and reverse notchplasty beneath the PCL. Valgus force and foot external rotation over a lateral post can help to improve visualization. In the lateral compartment, the figure-4 position with the application of a varus force is often sufficient.

Selected Literature Review

In general, MAT results in patient satisfaction rates of around 80%, a decrease in the visual analogue scale score for pain from 6 (of 10) to 2, and a significant improvement in patient-reported outcomes in comparison with the preoperative state. The rate of graft survival has been reported to be 95% at 5 years (Cole et al., AJSM, 2014), 70% at 10 years (Verdonk et al., JBJS, 2005), and 52% at 16 years (Wal et al., AJSM, 2009).

With regard to clinical outcomes, no differences have been found between medial MAT and lateral MAT, between isolated MAT and MAT with concomitant procedures, between soft-tissue and osseous fixation, or between procedures performed with a bone plug technique and those performed with a bone bridge technique. No technique is associated with better outcomes. Soft tissue fixation is associated with a higher rate of extension. There is no consensus with regard to the rehabilitation protocol or the use of a brace following MAT. Most authors advocate partial weight-bearing and restricted ROM at first, followed by full weight-bearing and full ROM by 6 weeks. Return to sports following MAT remains controversial. There is a paucity of literature on this topic, with only a few small case series in the literature. Limited low-quality evidence suggests that return to the pre-injury level of play is possible after MAT; however, the durability of the transplant in terms of its ability to resist repetitive supraphysiological loads is unknown. The chondroprotective effects of MAT remain controversial. Animal models have demonstrated some protective effects, but human studies have shown mixed results as a result of small sample sizes and lack of standardized outcomes. Level-IV evidence suggests that MAT may prevent the progression of cartilage degeneration, with slight or no progressive loss of joint space in most patients. MAT has not been shown to prevent the development of OA in patients with normal cartilage at the time of the index procedure.

Conclusion

Meniscal allograft transplantation has been shown to be to be a safe procedure with good to excellent clinical outcomes and high rates of patient satisfaction. Careful patient selection and appropriate patient counseling are critical. In general, MAT should be approached as a salvage intervention intended to improve quality of life. Sports-related goals are secondary and may not be achievable. It is important to emphasize that the results of this procedure will not last forever and that the patient will require further surgery.

- 03 Photographs illustrating the technique used for arthroscopic MAT involving anatomical bone sockets and suspensory cortical fixation. A: Graft preparation. P = posterior, and A = anterior. B: Cadaveric model demonstrating suspensory cortical root fixation with use of a 4-point knotless locking system to provide strong cortical fixation.
- 04 Images of the knee of a patient who underwent medial MAT. A: Preoperative MRI demonstrating medial meniscal deficiency. B, C, and D: Arthroscopic images made before (B) and after (C, D) medial MAT.

Recommended Literature

1. Sherman S, Nuelle C, Latterman C. AAOS Let's Discuss Series: Meniscal Allograft Transplantation. May 2015.
2. Hergan D, Thut D, Sherman O, Day MS. Meniscal allograft transplantation. *Arthroscopy*. 2011;27(1):101-112.
3. Rosso F, Bisicchia S, Bonasia DE, Amendola A. Meniscal allograft transplantation: a systematic review. *Am J Sports Med*. 2015;43(4):998-1007.
4. Lee BS, Kim HJ, Lee CR, Bin SI, Lee DH, Kim NJ, Kim CW. Clinical outcomes of meniscal allograft transplantation with or without other procedures: a systematic review and meta-analysis. *Am J Sports Med*. 2017 [Epub ahead of print] PMID: 28945482.
5. Getgood A, LaPrade RF, Verdonk P, Gersoff W, Cole B, Spalding T; IMREF Group. International Meniscus Reconstruction Experts Forum (IMREF) 2015 consensus statement on the practice of meniscal allograft transplantation. *Am J Sports Med*. 2016 [Epub ahead of print] PMID: 27562342.



THE INTERACTIVE AGENDA HAS A NEW LOOK!

Save the ISAKOS Congress Web App for Access on the Go!

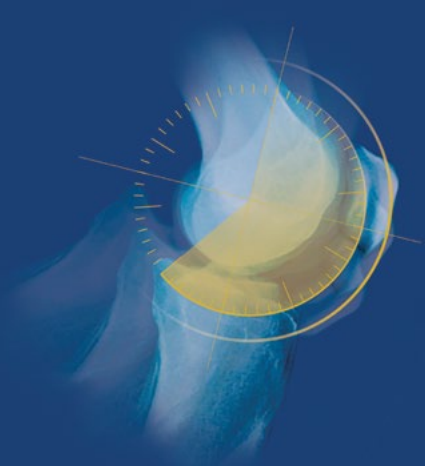
Now more mobile, tablet and computer friendly! The Interactive web app includes:

- LIVE agendas by day, room, or session type
- Faculty Profiles
- Linked Abstracts, Outlines & Presentations
- Search and Sort Filters
- Collapsible and Expandable Viewing
- Save Favorites to mySchedule
- 5-Star Rating System
- Electronic Question Queue (On-Site)
- Interactive Exhibits Floorplan & Directory
- Congress PDF Programs & Downloads
- And More!

isakos.com/interactiveagenda

JOURNAL OF ISAKOS

Joint Disorders & Orthopaedic Sports Medicine



An Official Publication of the
International Society of Arthroscopy,
Knee Surgery and Orthopaedic Sports Medicine

BMJ

isakos.bmj.com



ISAKOS PUBLICATIONS

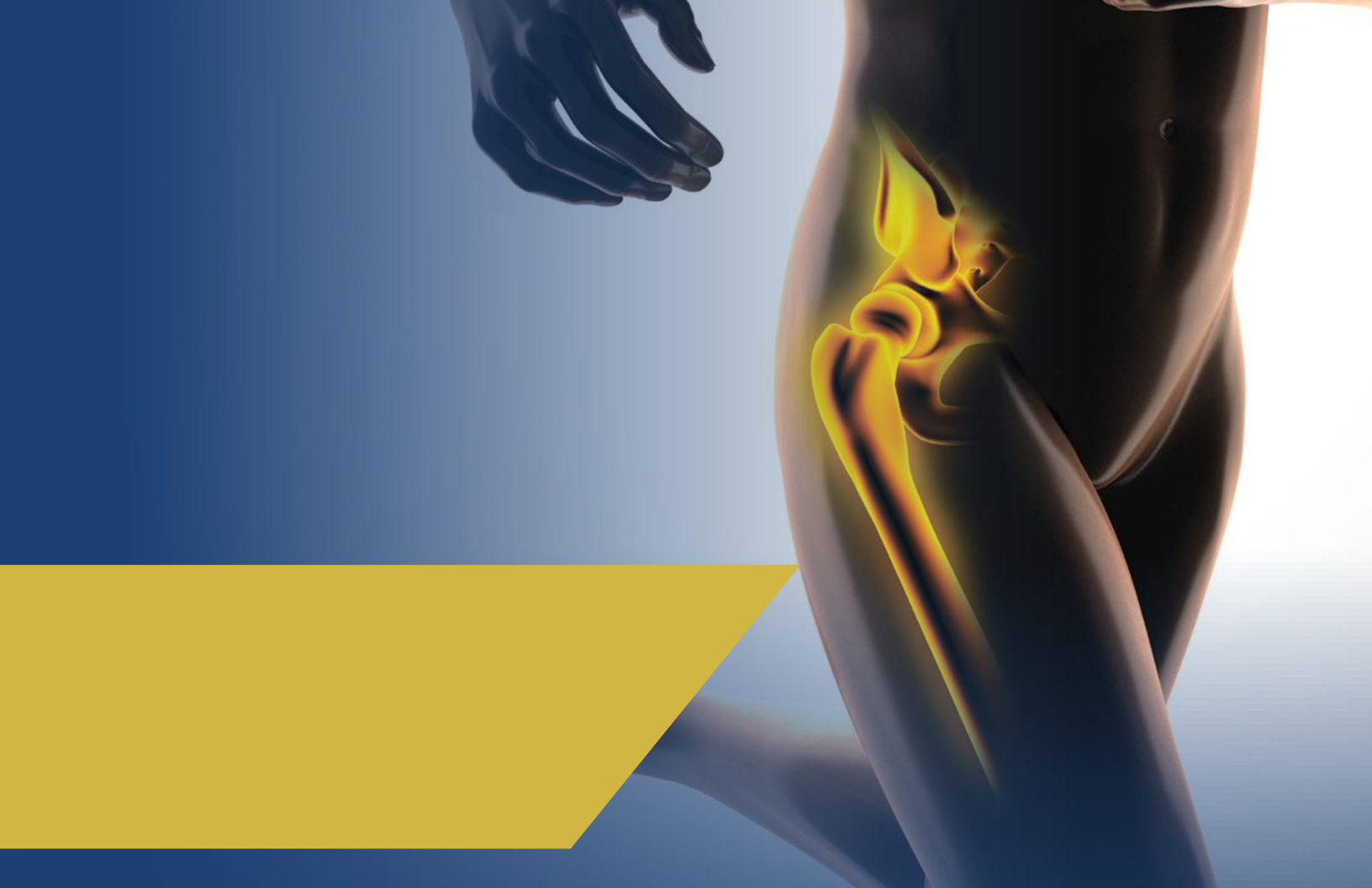

Full Access in myISAKOS

ISAKOS Members can access all official ISAKOS Publications through myPublications in myISAKOS—including *Journal of ISAKOS*!

isakos.com/books





*Management of Knee
Osteoarthritis*

The Menisci

*Shoulder Instability Across the
Life Span*

Muscle and Tendon Injuries

Elbow Arthroscopy

*Shoulder Concepts 2013:
Consensus and Concerns*

Meniscal Transplantation

Surgery of Shoulder Instability

*Controversies: Technical Aspects
of ACL Reconstruction*

*Soft Tissue Balancing in Total
Knee Arthroplasty*

*Injuries and Health Problems in
Football*





Bio-orthopaedics

Cartilage Lesions of the Ankle

*Normal and Pathological Anatomy
of the Shoulder*

*Shoulder Stiffness—Current
Concepts and Concerns*

The Patellofemoral Joint



Justification of the Concept of Microinstability to Explain Anterolateral Impingement Syndrome



Joao Teixeira, MD
Porto, PORTUGAL



Haruki Odagiri MD
Kumamoto, JAPAN



Thomas Bauer MD, PhD
Boulogne, FRANCE



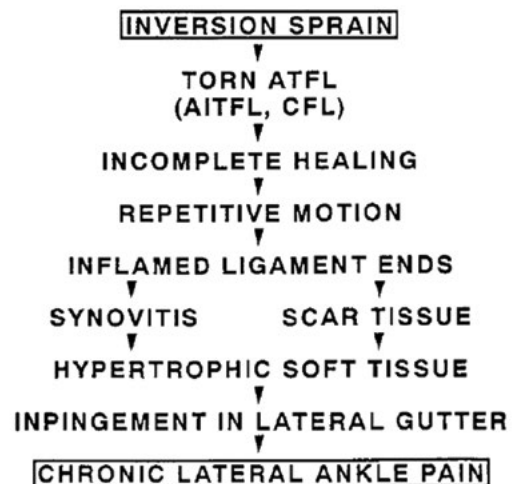Stéphane Guillo MD,
Bordeaux-Mérignac, FRANCE

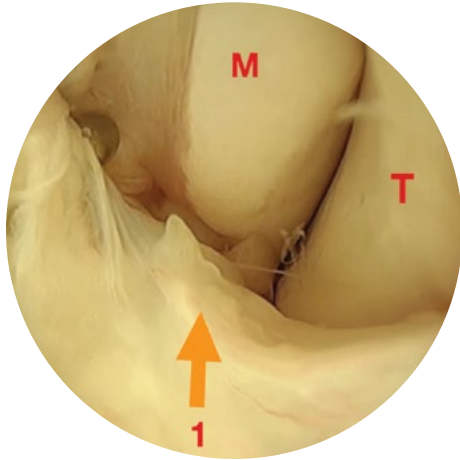
The concept of microinstability in the shoulder was described several decades ago, and since then numerous reports have focused on this theme. Microinstability of the shoulder is characterized by shoulder pain or apprehension, secondary to one or more episodes of instability, along with arthroscopic findings showing lesions of the glenohumeral ligament or labrum.

In terms of the ankle, when no mechanical instability is observed following a sprain, we speak of functional instability or anterolateral impingement. Several theories have been proposed on the role of the neurosensitive motor elements in the development of functional instability, but the most recent meta-analysis on this topic demonstrated inconsistencies among these theories¹. As in the shoulder, arthroscopic findings naturally led to a search for intra-articular lesions in these patients. Two studies have specifically investigated this topic.

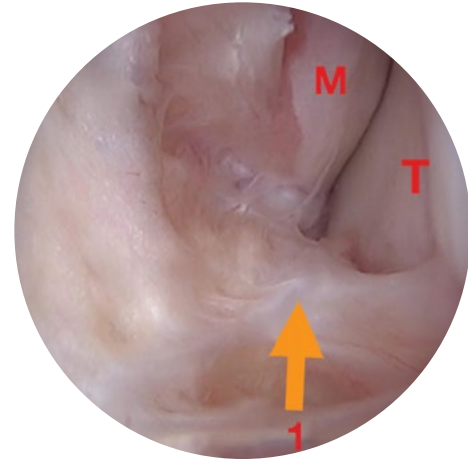
In 2008, Takao et al.² reported on 14 patients with functional instability; of these, 9 had partial fibrosis of the anterior talofibular ligament (ATFL), 3 had total fibrosis, and 2 had an avulsion. In 2016, Vega et al.³ reported on 36 patients with functional instability and anterolateral pain secondary to an ankle sprain. Those authors found synovitis in only one patient out of two, a proximal detachment of the ligament in 60% of the cases and a fibrosis of the ATFL in 50% of the cases.

Wollin first described anterolateral ankle impingement in 1950, proposing that this condition was the result of a “mass of connective tissue associated to the ATFL that invades the articular joint space.” The most contemporary description of anterolateral impingement was proposed in 1991 by Ferkel et al.⁴ (Fig. 1). According to those authors, the initial traumatic event in the development of ankle impingement is an ankle sprain with involvement of the ATFL. Incomplete ligament scarring following the initial event will lead, to either synovitis, or fibrosis, resulting in hypertrophic tissue. This hypertrophic tissue is responsible for the impingement and lateral gutter pain. It appears that history has only retained hypertrophy of the synovium from that description, as subsequent studies (including those by Liu [1994], with 87% good results; Branca [1997], with 63% good results; Kim [2000], with 94% good results, Rasmussen [2002], with 90% good results, Urguden [2005], with 90% good results; and Brennan [2012], with 83% good results) demonstrated very optimistic results without ever focusing on what Ferkel et al. considered to be the initial trauma mechanism, the ATFL lesion. Moreover, none of those articles included an arthroscopic image of the external gutter with relief of the ATFL (Fig. 2), with published images typically showing only the superolateral corner and distal part of the anterior tibiofibular ligament. In addition, it is often very difficult to tell what was really done during a procedure. For example, in the recent review article by Ross et al.⁵ on the treatment of anterior impingement, soft-tissue management was not described well, in our opinion.





02



03

The clinical picture is that the ankle sprain is the triggering factor. It is therefore logical to focus on the ATFL. We believe that it is highly probable that ligament-healing problems lead to pain and/or apprehension, even if the clinical examination does not demonstrate pathological laxity. The Molloy sign can be negative⁵ when there is no synovitis in the external gutter. In contrast, it is more common to find pain with palpation of the ATFL, particularly on its malleolar insertion. Unlike in the shoulder, imaging (especially ultrasound and magnetic resonance imaging [MRI]) is very useful in the ankle. Specifically, imaging studies should be used to assess for ATFL injury, especially avulsion of the ligament at its malleolar insertion. Arthroscopic inspection should be thorough and should include a complete view of the ATFL (including its malleolar and talar insertions) and the anterior tibiofibular ligament. The degree of fibrosis and synovitis should also be assessed. These lesions can be classified as distal or proximal ligament injuries with partial or total fibrosis (Fig. 3).

In conclusion, there is reason to believe that patients suffering from functional instability and/or anterolateral impingement following an ankle sprain likely have clinically undetectable instability. In these situations, it is important to look for a ligamentous lesion with use of ultrasound or MRI and to propose appropriate arthroscopic or open surgical repair as indicated.

References

1. Munn J, Sullivan SJ, Schneiders AG. Evidence of sensorimotor deficits in functional ankle instability: a systematic review with meta-analysis. *J Sci Med Sport* 2010; 13(1): 2-12.
2. Takao M, Innami K, Matsushita T, Uchio Y, Ochi M. Arthroscopic and magnetic resonance image appearance and reconstruction of the anterior talofibular ligament in cases of apparent functional ankle instability. *The American journal of sports medicine* 2008; 36(8): 1542-7.
3. Vega J, Pena F, Golano P. Minor or occult ankle instability as a cause of anterolateral pain after ankle sprain. *Knee surgery, sports traumatology, arthroscopy : official journal of the ESSKA* 2016; 24(4): 1116-23.
4. Ferkel RD, Karzel RP, Del Pizzo W, Friedman MJ, Fischer SP. Arthroscopic treatment of anterolateral impingement of the ankle. *The American journal of sports medicine* 1991; 19(5): 440-6.
5. Ross KA, Murawski CD, Smyth NA, et al. Current concepts review: Arthroscopic treatment of anterior ankle impingement. *Foot and ankle surgery : official journal of the European Society of Foot and Ankle Surgeons* 2017; 23(1): 1-8.

01 Diagram illustrating the description of anterolateral impingement as proposed by Ferkel et al.⁴

02 Arthroscopic view showing the ATFL (1, arrow), the malleolus (M), and the lateral side of the talus (T).

03 Arthroscopic view showing the lateral gutter with extensive fibrosis starting from the ATFL (1, arrow), the malleolus (M), and the lateral side of the talus (T).

ACL Evaluation with Slice Imaging: Applicability of the Porto-Knee Testing Device



Rogério Pereira, BHKin
Porto, PORTUGAL



Renato Andrade, BSc
Porto, PORTUGAL



Ricardo Bastos, MD, PhD
Porto, PORTUGAL



João Espregueira-Mendes, MD, PhD
Porto, PORTUGAL

Clínica do Dragão, Espregueira-Mendes Sports Centre—FIFA
Medical Centre of Excellence, Porto, PORTUGAL

Background

Multiplanar knee laxity beyond the physiological range of motion seems to be a hazard in several contexts. Pathological laxity often leads to comorbidities such as early osteoarthritis as well as meniscal and capsuloligamentous injuries, which may decrease the ability to perform athletic or work-related activities.

The aims of operative treatment of an anterior cruciate ligament (ACL) rupture are to restore the native arthrokinematics of the knee and to prevent comorbidities associated with the abnormal laxity.

It has been reported that ACL-reconstructed knees, even those in which the procedure is considered to have been successful, demonstrate altered kinematics, which may, under certain scenarios, impose potentially harmful amounts of stress to the ACL¹. In the last few decades, however, important advances in surgical technique have led to an improvement in postoperative knee kinematics, particularly with regard to the reestablishment of knee stability in the transverse plane. Thus, it is crucial to assess multiplanar knee laxity in order to correctly classify ACL-deficient and ACL-ruptured knees in terms of their laxity profile and refine treatment indications accordingly.

Notwithstanding all of the research on objective clinical measures of joint laxity, the scientific and medical communities still maintain that there is a need for a simple and clinically applicable tool for measuring sagittal and rotatory laxity of the knee. While the Lachman test is recognized as the most sensitive and most commonly used, other clinical maneuvers, such as the anterior drawer test, are also often performed for the manual evaluation of sagittal laxity. In addition, the pivot-shift test remains the most accepted method for assessing rotatory laxity and is believed to correlate with episodes of giving way in individuals with ACL-deficient knees. However, manual examinations are subjective, lack standardization, and may be influenced by a number of variables (e.g., the extent of injury, muscle guarding, and the technique and experience of the examiner), all of which may lead to variable arthrokinematics and, as a result, limited accuracy. In light of the shortcomings and the need for a tool that will provide consistent, reproducible, and comprehensive multiplanar assessments, instrumented laxity devices continue to evolve.

Stress MRI/CT Assessment

The instrumented assessment of laxity with use of magnetic resonance imaging (MRI) or computed tomography (CT) offers new possibilities and is already a reality in daily clinical practice. This method provides insight into the anatomical structures and their association with biomechanical behavior, thereby providing an enhanced and more sensitive diagnostic workflow. As reported previously^{2,3}, the Porto-Knee Testing Device (PKTD; Soplast, Valongo, Portugal) is a noninvasive and CT and MRI-compatible device that provides objective measurements of sagittal and rotatory laxity (Fig. 1).

Evaluation Procedures

The PKTD evaluation procedure starts by laying the patient supine on the MRI/CT table, with the lower limb placed on the PKTD. The knee is flexed to 30° and is aligned with the mechanical axis of the device. The foot rests in neutral flexion and rotation, contributing to the locking effect of the talus in the ankle mortise. The patient is instructed to remain calm and to avoid muscle guarding.



01

The first MRI or CT scan is performed without any stress applied in order to record the rest position. A second sequence is performed with posteroanterior stress applied to the proximal part of the calf by means of an ascending platform that is activated by a plunger under a 4-bar pressure. Then, the rotatory stresses (i.e., maximum internal rotation and maximum external rotation of the tibia) are tested independently by applying pressure through a rotatory footplate. Stress is gradually increased to comply with the viscoelastic mechanical characteristics of human tissues in order to ensure patient safety. Whenever possible, this procedure is performed bilaterally for side-to-side comparison.

Measurement Procedures

The MRI or CT scans are recorded with 1 to 5 mm slices. The laxity measurements (in mm) are made in both the medial and lateral tibiofemoral compartments. The slice selection is made independently for the medial and lateral tibial plateaus. The reference for the medial compartment is the first appearance of the medial portion of the proximal origin of the gastrocnemius muscle, and for the lateral compartment, the most medial sagittal aspect of the fibula. The measurements are made by calculating the distance between a line (oriented perpendicular to the tibial slope) crossing the most posterior point of the tibial plateau and a second line (oriented parallel to the first line) crossing the most posterior point of the femoral condyle⁴. Measurements are made with the knee at rest (non-stressed condition), as well as with the application of posteroanterior and rotatory stresses, for both the medial and lateral knee compartments. The difference between the rest and stressed conditions determines the amount of tibial displacement. Moreover, with the PKTD method, it is possible to calculate 2 combined measures in order to enhance the sensitivity and specificity of complete ACL ruptures. Global anterior translation (that is, the sum of the anterior tibial displacement of the medial and lateral tibial plateaus) provides high specificity (93%) with a cut-off of 15.1 mm. Global rotation (that is, the sum of the internal and external rotation of the lateral tibial plateau) has a high sensitivity (94%) with a cut-off of 11.1 mm³.

Clinical Relevance

The PKTD evaluation allows for the correlation of ligamentous “anatomy” and “function” within the same examination, which makes the PKTD a useful tool for the objective assessment of knee ligament injuries. The PKTD method can be used to assess differential diagnoses, to refine surgical indications, to assist with preoperative planning, to evaluate follow-up treatment outcomes, and to provide an additional criterion for return-to-sports decision-making. Additionally, it is possible to use this method to develop rotatory and sagittal laxity profiling of total ACL tears (Fig. 2), partial ACL tears (Fig. 3), combined ACL and posterolateral corner injuries (Fig. 4), and isolated posteromedial corner injuries (Fig. 5).

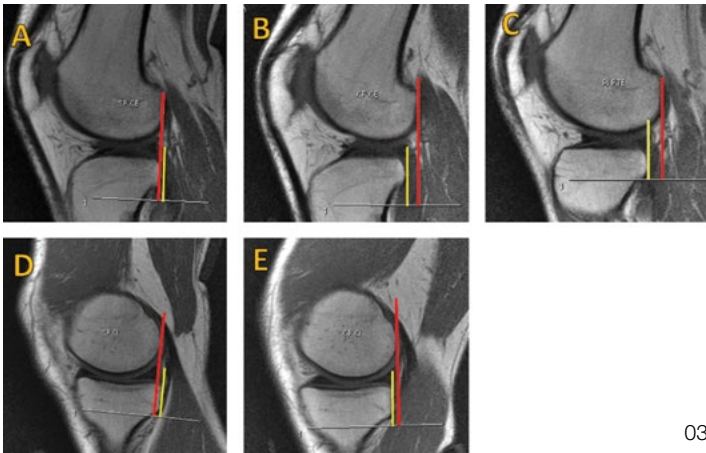
02

This method also can be used to demonstrate a “chewing-gum” effect (a situation in which a complete ACL rupture initially appears to be a partial rupture on MRI scans but, when stressed is applied by pushing the tibia anteriorly, a clear separation or an elongation of the ACL is seen). This effect may reveal that a ligament that would otherwise be considered intact and functional is actually non-functional.

01 Photograph of the Porto Knee Testing Device (PKTD; Soplast, Valongo, Portugal).

02 **Panels A through F:** MRI scans showing PKTD measurements in the medial plateau (Panels A, B and C) and in the lateral plateau (Panels D, E and F) in a patient with a total ACL rupture. **Panels A, B, and C:** The measurements in the medial plateau were -1 mm with no stress (Panel A), 9 mm with posteroanterior stress (Panel B), and 13 mm with maximum external rotation of the tibia (Panel C). **Panels D, E, and F:** The measurements in the lateral plateau were 1 mm with no stress (Panel D), 11 mm with posteroanterior stress (Panel E), and 12 mm with maximum internal rotation of the tibia (Panel F).

ACL Laxity Evaluation with Slice Imaging: Applicability of the Porto-Knee Testing Device



03

References

1. Tashman, S., Collon, D., Anderson, K., Kolowich, P., & Anderst, W. (2004). Abnormal rotatory knee motion during running after anterior cruciate ligament reconstruction. *Am J Sports Med*, 32(4), 975-983.
2. Espregueira-Mendes, J., Pereira, H., Sevivas, N., Passos, C., Vasconcelos, J. C., Monteiro, A., Oliveira, J. M., & Reis, R. L. (2012). Assessment of rotatory laxity in anterior cruciate ligament-deficient knees using magnetic resonance imaging with Porto-knee testing device. *Knee Surg Sports Traumatol Arthrosc*, 20(4), 671-678.
3. Espregueira-Mendes, J., Andrade, R., Leal, A., Pereira, H., Skaf, A., Rodrigues-Gomes, S., Oliveira, J. M., Reis, R. L. & Pereira, R. (2017). Global rotation has high sensitivity in ACL lesions within stress MRI. *Knee Surg Sports Traumatol Arthrosc*, 25(10), 2993-3003.
4. Tashiro Y, Okazaki K, Miura H, Matsuda S, Yasunaga T, Hashizume M, Nakanishi Y, Iwamoto Y (2009) Quantitative assessment of rotatory instability after anterior cruciate ligament reconstruction. *Am J Sports Med* 37:909-916

S.T.I.F. CLASSIFICATION STIFFNESS TYPES & INFLUENCING FACTORS

PREVALENT TYPE OF STIFFNESS	TREATMENT and PROGNOSIS INFLUENCING FACTORS
1 SOFT TISSUE CONTRACTURE	a ULNAR NERVE SYMPTOMS

04

DECISIONAL TREATMENT ALGORITHM FOR ELBOW STIFFNESS RELEASE	
PREVALENT TYPE OF STIFFNESS	SURGERY
1 SOFT TISSUE CONTRACTURE	- Release - Release (column procedure)
2 ARTHRITIS	Mild or Moderate arthritis - Osteocapsular arthroplasty
	Severe arthritis - Biologic interposition / Distraction arthroplasty (External Fixators) - TEA (>70ys)

05

Take-Home Message

Instrumented laxity measurements made with use of MRI or CT scans during the application of stress with use of the PKTD provide a clear picture of both the structural and functional status of the knee. Thus, a knee with a structural lesion may be found to be functionally competent, which may support a conservative approach. Alternatively, a knee with a structurally continuous ligament may be found to be non-functional (or even to exhibit a chewing-gum effect), which may require surgery.

- 03 **Panels A through E:** MRI scans showing the PKTD measurements in the lateral plateau (Panels A, B and C) and medial plateau (Panels D and E) for a patient with a partial ACL rupture. PKTD assessment showed important internal rotation (+9 mm) following a rupture of the posterolateral bundle of the ACL. **Panels A, B, and C:** The measurements in the lateral plateau were -2 mm with no stress (Panel A), 6 mm with posteroanterior stress (Panel B), 7 mm with maximum internal rotation of the tibia (panel C). **Panels D and E:** The measurements in the medial plateau were -4 mm with no stress (Panel D) and 3 mm with posteroanterior stress (Panel E).
- 04 **Panels A, B, and C:** MRI scans showing PKTD measurements in the lateral plateau for a patient with a combined ACL and posterolateral corner injury. The measurements were -1 mm with no stress (Panel A), 14 mm with posteroanterior stress (Panel B), and -6 mm with maximum external rotation of the tibia (Panel C).
- 05 MRI scans showing PKTD measurements in the medial plateau for a patient with a posteromedial corner injury. The measurements were -2 mm with no stress (Panel A) and -6 mm with posteroanterior stress (Panel B).

Critical Shoulder Angle and Impact on RTC Repair

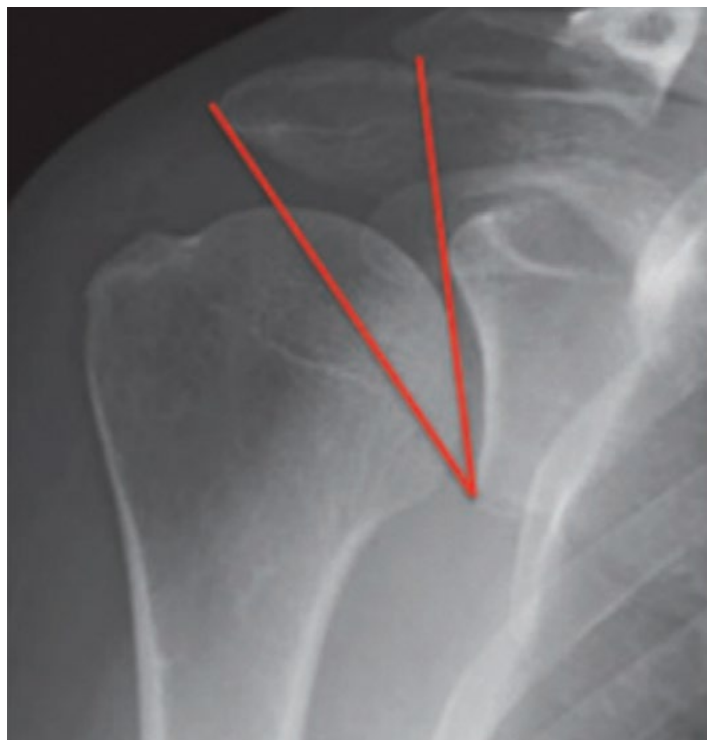

Francesco Franceschi, MD, PhD
Campus Biomedico University of Rome
Rome, ITALY

The purpose of rotator cuff repair is to facilitate healing of the tendon within the native site. In many studies, surgical repair has been associated with success rates of 85% to 90%, with good clinical results. However, retears may occur, especially in older patients with large tears. Several studies have shown that rotator cuff re-tears after surgery depend on biomechanical, biochemical, and physiological factors that, together with additional unknown local factors, regulate the tendon-regeneration process. The process of connective-tissue repair seems to resemble that of wound-healing, although the details of the regulatory mechanisms remain unclear.

The rate of recurrence following surgical treatment ranges from 13% to 94% and is related to the quantity and quality of tendon tissue, age, and other factors. To decrease this rate, surgeons have sought to improve the surgical techniques and materials used. Biological factors (e.g., platelet-rich plasma [PRP]) and increasingly personalized rehabilitation programs, either delayed or accelerated, also have been used in an attempt to promote healing of the area, but the results have been poor.

It is possible that lesions of the rotator cuff and their recurrence could be related to the anatomy of the shoulder. The critical shoulder angle (CSA) is formed between a line extending from the superior to the inferior aspect of the glenoid and a second line extending from the inferior aspect of the glenoid to the inferolateral aspect of the acromion on a true anteroposterior radiograph with the arm in neutral position (Fig. 1). The CSA is a measurement that combines lateral acromial offset and glenoid inclination. A more lateral acromial offset creates a more lateral deltoid origin and, in theory, results in greater shear and less compressive vector of the deltoid across the glenohumeral joint. Glenoid inclination also may play a role in the development of rotator cuff disease. Superior glenoid inclination increases shear forces and decreases compression forces across the glenohumeral joint and may encourage proximal humeral migration and increase loads placed on the articular margin of the supraspinatus to resist the deltoid.



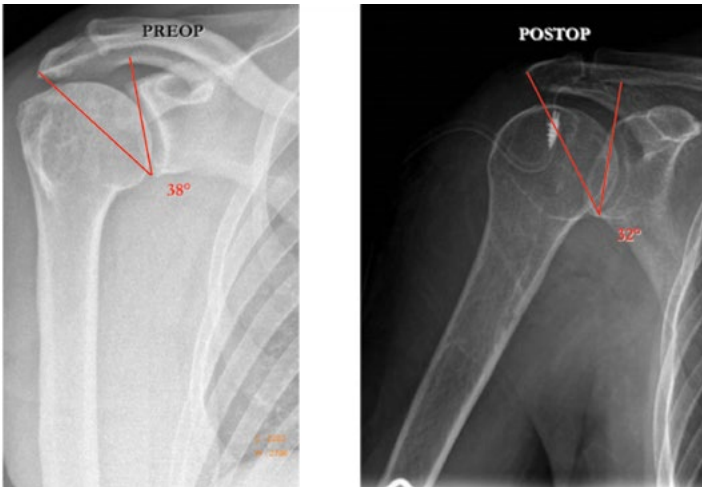
01

In a recent study, Moor and colleagues¹ evaluated several radiographic parameters and concluded that the CSA is a predictor of rotator cuff injury. In particular, angles of $>35^\circ$ were found to be predictive of a rotator cuff tear and angles of $<30^\circ$ were predictive of early osteoarthritis of the shoulder. Furthermore, a recent study by Garcia et al.² showed that the risk of re-tear after arthroscopic rotator cuff repair was 15 times higher if the CSA was $>38^\circ$. In contrast, Chalmers et al.³, in a retrospective study, found that the CSA is unlikely to be related to rotator cuff disease and described concerns regarding the radiographic measurement of the CSA. These concerns have good foundations, although Bouaicha et al. noted that the execution of good-quality radiographs that respect the classification of Suter-Henninger allows the CSA to be calculated correctly⁴.

Reduction of the CSA to $<35^\circ$ could be useful for preventing progression of a rotator cuff tear or for protecting a cuff repair from re-tear. Lateral acromioplasty is an effective procedure that can be used to reduce the CSA without violating the acromial deltoid origin (Fig. 2)⁵. Further research in this area is needed to determine if lateral acromioplasty can improve outcomes.

01 Radiograph illustrating the orientation of the lines forming the CSA.

Critical Shoulder Angle and Impact on RTC Repair



02

Reference

1. Moor B.K., Bouaicha S., Rothenfluh D.A., Sukthankar A., Gerber C. Is there an association between the individual anatomy of the scapula and the development of rotator cuff tears or osteoarthritis of the glenohumeral joint? A radiological study of the critical shoulder angle. *Bone Joint J.* 2013;95-B(7):935-941. 2. Garcia GH, Liu JN, Degen RM, Johnson CC, Wong AC, Dines DM, Gulotta LV, Dines JS Higher critical shoulder angle increases the risk of retear after rotator cuff repair. *J Shoulder Elbow Surg.* 2017 Feb;26(2):241-245. doi: 10.1016/j.jse.2016.07.009. Epub 2016 Sep 1. Erratum in: *J Shoulder Elbow Surg.* 2017 Apr;26(4):732 3. Chalmers PN, Salazar D, Steger-May K, Chamberlain AM, Yamaguchi K, Keener JD. Does the Critical Shoulder Angle Correlate With Rotator Cuff Tear Progression? *Clin Orthop Relat Res.* 2017 Jun;475(6):1608-1617. doi: 10.1007/s11999-017-5249-1. Epub 2017 Jan 24. 4. Bouaicha S., Ehrmann C., Slankamenac K., Regan W.D., Moor B.K. Comparison of the critical shoulder angle in radiographs and computed tomography. *Skeletal Radiol.* 2014;43(8):1053-1056. 5. Gerber C, Catanzaro S, Betz M, Ernstbrunner L. Arthroscopic Correction of the Critical Shoulder Angle Through Lateral Acromioplasty: A Safe Adjunct to Rotator Cuff Repair. *Arthroscopy.* 2017 Oct 31. pii: S0749-8063(17)31067-8. doi: 10.1016/j.arthro.2017.08.255

02 Radiographs illustrating the CSA before and after lateral acromioplasty.

ISAKOS Members Receive Full Access to OrthoEvidence

OrthoEvidence's database has thousands of evidence-based summaries from more than 360 journals of the highest-quality research in orthopaedics.

1

Log in to myISAKOS at isakos.com/myISAKOS

myISAKOS

2

Click on myPublications



3

Click "Access" the ISAKOS/ OrthoEvidence Portal

Access

OE ORTHOEVIDENCE⁺

in partnership with



Shorter Stems and Stemless Implants in Shoulder Replacement Surgery



Stephen C. Weber, MD
The Johns Hopkins University
School of Medicine
Silver Spring, UNITED STATES



Jorge Rojas Lievano, MD
Division of Shoulder and Elbow
Fundacion Santa Fe de Bogotá
Bogotá, COLOMBIA



Edward G. McFarland, MD
The Johns Hopkins University
School of Medicine
Lutherville, UNITED STATES



Uma Srikumaran, MD
The Johns Hopkins University
School of Medicine
Columbia, UNITED STATES

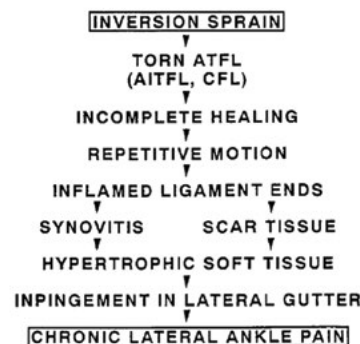History Of Stem Length

Shoulder arthroplasty was developed during the middle part of the last century by Dr. Charles Neer. The Neer humeral prosthesis, introduced in 1953, was designed to replace the humeral head in cases of fracture. Neer noted that the stem length was chosen so that the stem would diffuse strain over a 15-cm span; this length was most likely chosen on the basis of the concomitant implant length in the hip. Although the standard prosthesis length has remained the same this day, Neer recognized that the anatomical features of some patients might require the use of a shorter stem. The original Neer device therefore included a short stem option that was “designed for use in small or deformed bones, as in patients with juvenile rheumatoid arthritis or chondrodystrophy.” These short stems were not intended for routine use; in Neer’s original series (n = 356), a short stem was used in only 2 patients, both of whom had epiphyseal dysplasia multiplex.

Recognizing many of the disadvantages of stemmed shoulder arthroplasty, Copeland pioneered the concept of surface replacement arthroplasty. While glenoid resurfacing is technically possible with use of resurfacing implants, it can be difficult because of persistence of the humeral head, which makes direct access to the glenoid difficult. Stemless and short-stemmed arthroplasty have shown advantages over surface replacement in that they may decrease the tendency to overstuff the joint and may offer better exposure to the glenoid for glenoid resurfacing.

The Concept

The use of shorter stems is associated with several potential advantages, including (1) preservation of bone stock in revision situations, (2) the fact that humeral head position is not constrained by the stem (thereby allowing placement of the component independent of alignment with the medullary canal, which can be advantageous in cases of proximal humeral deformity), (3) easier stem removal in the event of revision, (4) less blood loss and shorter operating time, (5) less stress resorption in the proximal part of the humerus, and (6) a requirement for less inventory than is the case with third-generation prostheses (because with shorter stems, and especially, with stemless devices, it is not necessary to reproduce neck angles or offsets with multiple implants or modular implants). In theory, short-stem and stemless devices should be associated with fewer periprosthetic fractures because of avoidance of the diaphyseal stress riser, although clinical data to support this concept are lacking. Fractures around short-stem prostheses can still occur (Fig. 1).

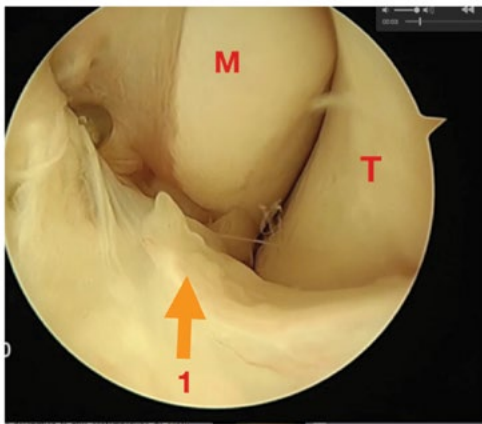


01

01 Radiograph showing a fracture through the metaphysis six-months following a short-stem reverse total shoulder replacement.

Shorter Stems and Stemless Implants in Shoulder Replacement Surgery

In addition, these fractures are more commonly metaphyseal and often can be treated either nonoperatively or with cerclage fixation without the use of a long stem. Radiographically evident stress resorption occurs in association with a substantial number of stemmed implants, and Razfar et al.¹, using finite image analysis, showed that this finding might be avoided with use of short-stem implants. Those authors also proposed a classification system for stem lengths on the basis of their work (Fig. 2). The advantages noted above may offer significant improvements in the outcomes of shoulder arthroplasty.

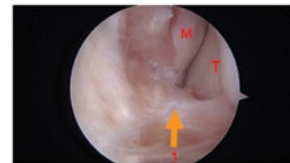

02

Limitations

Perhaps the greatest limitation of shorter stems is the excellent long-term results associated with standard-length stems. Long-term loosening rates for traditional devices have been widely reported as <1%, and the success that has been achieved with these devices may be difficult to duplicate. Both short-stem and stemless devices share several limitations. Polyethylene debris resulting from glenoid wear increases the risk of loosening of all humeral components, and migration of this debris into an implant interface with only metaphyseal fixation potentially could increase long-term loosening rates. As there is no diaphyseal fixation, metaphyseal bone quality is critical. It must be understood that as many as 30% of patients will not have adequate bone quality to support these devices, and often the decision about which implant to use must be made at the time of surgery on the basis of fairly arbitrary criteria such as the “thumb test.” The excellent results associated with short-stem implants have been achieved because of strict adherence to the requirement for high-quality metaphyseal bone. Patients with rheumatoid arthritis may be at higher risk of fracture.

Similarly, short-stem implants are inappropriate for the treatment of the majority of proximal humeral fractures because of the presence of concomitant metaphyseal comminution. For this reason, a “bail out” option (i.e., the availability of a stemmed prosthesis system in the operating room) is absolutely necessary in cases of planned short-stem arthroplasty. Failure to respect this precaution will increase the risk of implant failure (Fig. 2). Surgeons who support the use of a lesser tuberosity osteotomy to manage the subscapularis need to understand that this procedure can also possibly compromise implant fixation. Also while positioning of the implant has the advantage of being independent of the humeral diaphysis, both short-stem and stemless implants have been noted to be malpositioned in a substantial number of cases².



03

Short-stem designs offer several advantages over stemless components in terms of metaphyseal fixation. First, the rate of loosening of short-stem components approaches 0%, and the larger surface area available for fixation may prove beneficial. Second, most short-stem systems on the market offer a range of humeral inclination angles and therefore can compensate for a variety of proximal humeral geometries. Third, the fixed geometry of a stem corrects for excessive varus or valgus humeral osteotomy, an error commonly seen in association with stemless implants. Fourth, many currently available stemless designs are not convertible secondary to the implant collar. As platform systems offer many of the same advantages as short-stem or stemless implants in terms of revision, many of the advantages reported in association with these implants may in fact be imaginary.

Results

Between 2004 and 2013, approximately 10,000 short-stem and stemless shoulder prostheses were implanted worldwide¹. Premature loosening has been virtually unreported, and short-stem and stemless implants have been discussed in several comprehensive reviews³⁻⁵. The only 2 publications that raised concerns regarding loosening of short-stem implants noted the potential need for a porous coating on implants with metaphyseal fixation.

In nearly all series, the clinical outcomes associated with short-stem and stemless implants have been equivalent to those associated with traditional stemmed implants. Malpositioning of the implant secondary to loss of constraint remains the most common complication². Intraoperative fractures generally have been more common in association with short-stem and stemless implants than with standard stems, and improvement in the rate of postoperative fractures to date has not been established. Despite the purported advantage of the lack of diaphyseal constraint, the restoration of humeral-sided anatomical parameters has been reported to occur significantly less frequently in association with stemless implants as compared with short-stem and standard-stem implants². The clinical importance of this malalignment remains unclear.

Conclusion

The early published results associated with short-stem and stemless components have been encouraging. The rates of loosening and revision have been consistent with the long-term results associated with traditional stemmed components. We agree with the conclusion of Keener et al.⁴, who stated that “Longer-term follow-up will be necessary before the potential clinical advantages and disadvantages of stemless and short-stemmed implants are fully understood. Stemmed implants continue to have the best available evidence and thus remain the preferred design.”

Reference

1. Razfar N, Reeves JM, Langohr DG, Willing R, Athwal GS, Johnson JA. Comparison of proximal humeral bone stresses between stemless, short stem, and standard stem length: a finite element analysis. *J Shoulder Elbow Surg.* 2016;25(7):1076-83. 2. Sholder D HJ, Abboud JA, Cox RM, Lazarus MD, Ramsey ML, Stoll LE, Williams GR. Humeral Head Anatomic Restoration after Total Shoulder Arthroplasty: Does the Stem make a Difference? *Proceedings of the American Academy of Orthopedic Surgeons.* 2018. 3. Hawi N, Tauber M, Messina MJ, Habermeyer P, Martetschlager F. Anatomic stemless shoulder arthroplasty and related outcomes: a systematic review. *BMC Musculoskelet Disord.* 2016;17(1):376. 4. Keener JD, Chalmers PN, Yamaguchi K. The Humeral Implant in Shoulder Arthroplasty. *J Am Acad Orthop Surg.* 2017;25(6):427-38. 5. Budeyri A, Garofalo R, Krishnan SG. Glenohumeral osteoarthritis in young patients: Stemless total shoulder arthroplasty trumps resurfacing arthroplasty—Affirms. *Seminars in Arthroplasty.* 2017;28(3):113-20.

02 Diagram illustrating stemless, short-stem, and standard humeral components. (Reprinted, with permission, from: Razfar et al.¹)

03 Radiograph showing a loose short stem at the site of a malunited proximal humeral fracture.



ISAKOS GLOBAL CONNECTION

Education, Research and Collaboration

DONATE TO ISAKOS

Donations to ISAKOS directly support initiatives that ensure the growth of our specialty, the professional development of our members and enhanced patient care. Your generosity will enable the Society to implement programs in education and research for its members around the globe.

Ways to Give:

- ISAKOS Annual Fund
- ISAKOS Godfather Initiative
- Corporate Giving

Donate Today at
isakos.com/GlobalConnection

NOW ACCEPTING!

ORIGINAL RESEARCH IN *JISAKOS*

ISAKOS is pleased to announce
that the Journal of ISAKOS is now
publishing original research



SUBMIT AT JISAKOS.BMJ.COM



Follow @J_ISAKOS on Twitter!



BMJ

10th Annual International Meeting of the Peruvian Arthroscopic Chapter

The 10th Annual International Meeting of the Peruvian Arthroscopic Chapter had 430 registered attendees, apart from the 20 speakers and members of the Organizing Committee. The faculty was comprised by world-class lecturers from the Americas and Europe. For another consecutive year, the meeting had faculty support from AANA and was joined by AANA President, Dr. Louis McIntyre. No missed talks were observed, and the program was fulfilled in its entirety. General and attendee satisfaction were high. Social activities included the inauguration and closure ceremonies, the President's Dinner—with great attendance from the Faculty, and the broadcast of the Peru-France World Cup match, which was enjoyed by all. The meeting had excellent support from industry as well. Overall, the meeting was a success and everyone is looking forward to repeating this great experience in 2019.

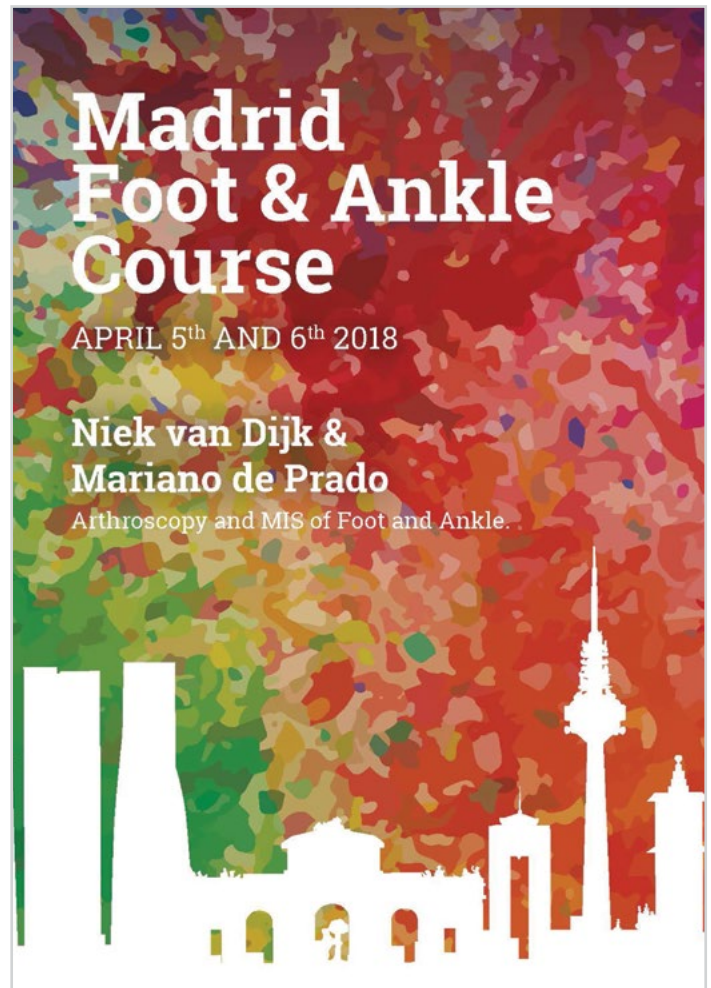


Madrid Foot & Ankle Course

5–6 April, 2018
Madrid, SPAIN

The Madrid Foot and Ankle Course, which took place on April 5–6, 2018, is a new initiative bringing together two world experts in their field; C. Niek van Dijk and Mariano de Prado. During the two-day course, they presented a unique combination of the strengths of Ankle Arthroscopy and Minimal Invasive Surgery in a mix of live surgical demonstrations, lectures, case discussions, and tips and tricks. Both techniques have their place in the spectrum of surgical solutions in ankle and hind foot problems. Both have their specific application and indication. C. Niek van Dijk and Mariano DePrado share the same vision “WHY to do it is as important as HOW to do it”. The course was both for advanced and beginners who are interested in these new techniques and solutions. The number of participants was limited to 200 and had ample time for exchange and discussion. Participants came from all continents and 44 countries. Participants cited that the lectures and live surgical demonstrations were “useful for [my] professional activity” and were given an average score of 4.7 out of 5.

The Madrid Foot and Ankle Course was hosted by Prof. Forriol, the head of the Anatomy Department of Central European University in Madrid and organized in cooperation between the Amsterdam Foot and Ankle Course ‘on tour’ and Ripoll y de Prado Van Dijk Clinic in Madrid, Spain.



1st FAST (Foot and ankle Arthroscopy Sports Traumatology)

The first FAST (Foot and ankle Arthroscopy Sports Traumatology) course was held this year in Amsterdam in de Academic Medical Center 2018. This course aimed for a more structured course on ankle arthroscopy with content individualized per year, based on participants' preferences. Participants from all over the world were invited to share their and our vision, learn from our techniques and experience working as a team.

With the (professional) athlete at the base, different physiological and pathological mechanisms were explained in lectures and solutions in terms of minimal invasive surgical techniques were explained—linking the lectures to the lab sessions. For some extra in-depth knowledge a new e-learning system was developed to assist in explaining anatomical and radiological findings that could be found during the diagnostic process and surgical procedures.

The course program was filled with lectures, discussions, quizzes, lab sessions on anterior & posterior ankle arthroscopy and tendoscopy, e-learning, and clinical demonstrations in terms of live surgery and innovation on the lab (i.e. new techniques and devices). During the lab sessions techniques were introduced by means of an instruction video before practice on cadavers. National faculty, one per two participants, was present to assist in procedures where needed, matched based on participants interest. The course had a limited number of participants, allowing each participant ample opportunity to practice during the cadaver lab sessions and to interact with their matched faculty.

The Thursday night program was on voluntary basis and was localized in the old center of Amsterdam, in the restaurant Nacarat, which provides an amazing view over Amsterdam in the direction of Dam Square.

The 1st Foot and Ankle Arthroscopy Sports Traumatology course was successfully completed with an average score of 4.2 out of 5 on the event survey.



**Surgical Demo
Video Courses**

**Available on
Global Link**

Access archived
Congress presentations,
surgical demonstrations and
courses, committee projects,
current concept articles...
and more!

ISAKOS
global link

isakos.com/GlobalLink

4th ISAKOS Knee Course & 8th Pune Knee Course Report

The 4th ISAKOS Knee Course and 8th Pune Knee Course was held from April 19–21, 2018 at the JW Marriott in Pune, India. The event was graced by the participation of about 1000 orthopaedic surgeons — delegates from India, South-East Asia and the Middle East; 13 International Faculty and 19 National Faculty. Dr. Charles Brown from the International Knee and Joint Center, Abu Dhabi was the Scientific Chairman while Dr. Sachin Tapasvi, Dr. Parag Sancheti and Dr. Nilesh Kamat were the Course Chairmen. This academic extravaganza was organized for the eighth year in a row and the popularity keeps growing every year. Since 2017, the format has been changed to have more focus on dedicated issues and this year’s event was focused on PCL, MCL, PLC and Patellofemoral joint injuries. This course provided an excellent opportunity for the delegates to learn the nuances of arthroscopy and interact with masters in the field from all across the globe. The course was approved and supported by ISAKOS, APOA and other various regional academic groups in India.

International Faculty:

Charles Brown	Abu Dhabi
Prof. Elizabeth Arendt	USA
Alan Getgood	Canada
James Robinson	United Kingdom
Ronald van Heerwaarden	The Netherlands
Martin Lind	Denmark
Julian Feller	Australia
Hayden Morris	Australia
Bancha Chernchujit	Thailand
Rik Kundra	United Kingdom
Neil Jain	United Kingdom
Amit Joshi	Nepal
Luke O’Brien	USA

The course was divided into five sessions and commenced on Thursday April 19th with the first session “Posterior Cruciate Ligament”. The other sessions were “Posterolateral Corner Injuries”, “The Medial Side” and “Multiligament Injuries” on Friday, April 20th and “Patellofemoral Joint” on Saturday, April 21st. The main program began with a LIVE surgical demonstration of Single Bundle PCL Reconstruction with hamstring autograft by James Robinson and Dinshaw Pardiwala. This was relayed to the auditorium via fiber-optic cables and created direct interaction between the surgeon in the OR and the onsite delegates.

Join the ISAKOS Global Conversation!

[Facebook.com/ISAKOSSociety](https://www.facebook.com/ISAKOSSociety)

@ISAKOS

Join the ISAKOS Group on LinkedIn



Tweeting About The Congress?

Include hashtag #ISAKOS2019 in your Tweets to join the global conversation!

This feature remains the highlight of Pune Knee Course and nine such surgeries were performed including; All Inside PCL Reconstruction; Revision ACL Reconstruction with Modified Larson PLC Reconstruction; Arthroscopic Popliteus Reconstruction with PCL Reconstruction; Anatomic LaPrade PLC Reconstruction + ACL Reconstruction + PLC Reconstruction; Danish MCL Reconstruction with PCL Reconstruction; Osteotomy for Chronic PCL Laxity; Quadriceps Tendon MPFL Reconstruction and MPFL Reconstruction with Tibial Tubercle Osteotomy.

Other hallmark features of this course are the Breakfast Instructional Course Lectures or Master Class—which are didactic in nature but allow close interaction between the delegates and faculty. There were five such sessions conducted this year and five different meeting rooms were packed with groups of about 50 delegates. The topics covered were “All You Need to Know About Posterolateral Corner Injuries”; “How to Perform MPFL Reconstruction”; “PCL Reconstruction: Step by Step”; “Management of Medial Knee Instability”; and “How to Perform Trochleoplasty and TTO”. These sessions were conducted in the morning of the 20th and 21st, prior to commencement of the main program, and very well received by the delegates.

There were two segments of live clinical examination in the Multiligament Injuries and Patellofemoral Joint sessions. In this, patients with a particular condition were examined and presented to an expert panel followed by discussion of management. In addition to this, two case-based panel discussions were also done in Multiligament Injuries and Patellofemoral Joint sessions, which were followed by a discussion on their management.

The other course highlight is the PKC Oration, where a stalwart of knee arthroscopy shares his/her journey of learning and teaching, followed by felicitation by the organizing team. This year, Prof. Elizabeth Arendt from the University of Minnesota, USA was honored for her contribution towards Patellofemoral surgery. She presented her experience on this subject during the Oration titled “A la Carte Management of Patellofemoral Instability—Evolution of My Philosophy”. She was presented a puneri pagadi and a citation recognizing her achievements.

The special ‘Fire-Side Chats’ session was held at the end of the first and second days, open to a limited number of invited delegates in five different meeting rooms.

The course was highly appreciated for its scientific content, format, presentation and conduct by the delegates and the faculty. The Pune Knee course believes that close interaction between the fraternities across the globe opens up new avenues of research, innovation and also opens flood gates for ideas to flow.

PKC™

ISAKOS

TAPASVI
CHANDRASEKHAR & MURTHY
CENTRE

An educational initiative by IJCC

In association with:
International Knee & Joint Centre

Supported by:

4
MMC
Points

COMBINED
4TH ISAKOS KNEE COURSE &
8TH PUNE KNEE
COURSE
2018

FOCUS MEETING ON
PCL, MCL, PLC AND PF JOINT

19TH, 20TH & 21ST APRIL, 2018
VENUE: HOTEL J. W. MARRIOTT, PUNE

www.punekneecourse.com

27th Severance Arthroscopy Symposium: Knee

Prof. Sung-Jae Kim MD, PhD
Symposium Chairman

The 27th Severance Arthroscopy Symposium, which is ISAKOS and Asian Arthroscopy Congress (AAC) Approved, was successfully held on June 17, 2018.

The Symposium has been held at Yonsei University Health System, in Seoul, Korea, 27 times since 1995 and has been an ISAKOS Approved Course since the 13th symposium on May 22, 2004.

On behalf of the entire Symposium Program Committee, Prof. Sung-Jae Kim (Education Committee Member) would like to thank all the attendees and members of the Severance Arthroscopy Society (ISAKOS Approved Teaching Center) for their great contributions.

The 27th Severance Arthroscopy Symposium had 170 participants (141 registrants) and 29 distinguished speakers from all around the country who delivered lectures in their areas of expertise.

The program was unique in that topics concerning knee arthroscopy were addressed within a single symposium—to help time-constrained surgeons quickly grasp the recent advances in the rapidly evolving field of Arthroscopy.

Various topics ranging from multiple ligaments and meniscus injuries to osteotomy were covered in sufficient depth to help the audience practice with more confidence.

In particular, the Symposium covered new topics not previously covered in past symposiums or symposiums of other institutions. It became an educational platform, allowing for sufficient discussions on subjects without clear solutions.

Many registrants stated that they attend the Symposium every year. Attendees indicated that the Severance Arthroscopy Symposium was “the best knee symposium in Korea” and well worth attending.

After the Symposium, the members of the Severance Arthroscopy Society and the speakers networked and mingled at the Symposium banquet.

The Severance Arthroscopy Symposium will continue to strive to enhance the opportunity for the exchange and dissemination of knowledge that the Severance Arthroscopy Society is famous for.



01



02



03



04

- 01 Opening remarks speech by Prof. Chong-Hyuk Choi
- 02 Photo of full shot taken at the back of auditorium
- 03 Closing remarks speech by Prof. Sung-Jae Kim
- 04 Faculty group photo taken at the auditorium

XV Congreso Internacional de la Asociación Argentina de Artroscopia—III Congreso Conjunto con la AOSSM

Hilton Buenos Aires Hotel
Buenos Aires, ARGENTINA

September 4–7, 2018

Chair(s): Dr. Rodrigo Maestu
Executive Committee: Drs. R. Maestu, J. Batista,
JP Previgliano, D. Slullitel

For further information, please contact:

Tel: +5411 4811 2089

Fax: +5411 4811 2389

www.artroscopia.com.ar

The 6th Biennial Meeting ASSA Combined with the 6th Annual Meeting IOSSMA “New Challenges in Management of ACL & Sports Injury”

Crowne Plaza Hotel
Semarang, INDONESIA

September 5–8, 2018

Chair: Dr. Isa An Nagib, SpOT

For further information, please contact:

Tel: +62 082125396333; +62 0811902664;

+62 0818920664

Fax: +62 21 7396261

www.assa-iOSSMA2018.org

Patras International Sports Medicine Fellowship
University Hospital of Patras

Patras, GREECE

September 12–14, 2018

Chair: Andreas Panagopoulos

For further information, please contact:

Tel: +30 6944363624

Fax: +30 2610-994657

www.patrasfellowship2018.com

1st Global Update in Joint Imaging & Orthopaedic Surgery Congress for Healthcare Practitioners
University Malaya Medical Centre

Kuala Lumpur, MALAYSIA

September 15–17, 2018

Chair: Professor Dr. John George

For further information, please contact:

Tel: +6012-277 3799

Fax: +603-2690 1301

www.penangmskrad.com

18th Journées Lyonnaises de Chirurgie du Genou—Advanced Course:

Revision Knee Arthroplasty

Lyon Convention Centre

Lyon, FRANCE

September 20–22, 2018

Chair(s): Dr. Roger Badet & Prof. Sebastien Lustig

For further information, please contact:

Tel: 33 472 07 62 22

www.lyon-knee-congress.com

XIV Turkish Sports Traumatology, Arthroscopy and Knee Surgery Congress
Gloria Convention Center

Antalya, TURKEY

October 2–6, 2018

Chair(s): Prof. A. Merter Ozenci

For further information, please contact:

Tel: 00902123814637

Fax: 00902122586078

tusyad2018.org/en.html

7th SIGASCOT National Congress

Bologna Fiere Congress Center

Bologna, ITALY

October 3–5, 2018

Chair(s): Stefano Zaffagnini, Maurizio Marcacci,

Pietro Randelli

For further information, please contact:

Tel: 003933838337991

Fax: 0039055 4641490

www.sigascot.com

ISHA 2018

Melbourne Exhibition and Convention Centre

Melbourne, AUSTRALIA

October 4–6, 2018

Chair: Dr. Nicolas Bonin

For further information, please contact:

Tel: +41787101726

www.ishaconference.com

V OrthoTrauma Update Course:

Trauma & Sports Medicine

Hotel Sol de Oro

Lima, PERU

October 19–20, 2018

Chair(s): Dr. Christian Lozano

For further information, please contact:

Tel: 51 1 2642230 / Cel 51 955207421

Fax: 51 1 2643623

www.maeventosycongresos.com/eventos-2018/v-ortho-trauma-update-course-trauma-and-sports-medicina.html

Amsterdam Foot and Ankle Course in Shanghai

Huashan Hospital, Shanghai—China Department

of Sports Medicine

Shanghai, CHINA

October 24–26, 2018

Chair: Prof. Niek Van Dijk

For further information, please contact:

Tel: +34963734690

Fax: +34963734690

shanghaifootandankle.com

4th Symposium on Hip Preservation

Treatments: Arthroscopy, Minimally-Invasive

Surgery, Physiotherapy

Fabryka Welny Hotel

Pabianice, POLAND

October 26–27, 2018

Chair(s): Dr. Konrad Malinowski,

Dr. Krzysztof Hermanowicz

For further information, please contact:

Tel: +48 22 826 30 82

Fax: +48 22 826 30 82

biodro.org/?lang=en

Patellofemoral Masterclass

Scarman Conference Centre, Coventry UK

Coventry, UNITED KINGDOM

November 1–3, 2018

Chair(s): Tanweer Ashraf & Sameh ElKawy

For further information, please contact:

Tel: +44 (0) 1476 860759

Fax: +44 (0) 1476 860759

www.patfemmasterclass.co.uk

10th Congress of Asia-Pacific Knee Society (APKS 2018)

Kimdaejung Convention Center

Gwangju, REPUBLIC OF KOREA

November 8–10, 2018

Chair(s): Eun-Kyoo, Song

For further information, please contact:

Tel: +82-70-8676-8921

Fax: +82-62-670-9589

www.apks2018.org

3rd Annual Cartilage Symposium

Parc 55 Hotel

San Francisco, UNITED STATES

November 8–10, 2018

Chair: Dr. Kenneth Akizuki

For further information, please contact:

Tel: 510-333-4860

Fax: 510-333-4860

SFCartilage.com

13th Hanover Arthroscopy & Arthroplasty Course

Fairground Hanover (NORD/LB Forum)

Hanover, GERMANY

November 9–10, 2018

Chair(s): PD Dr. Jens D. Agneskirchner, Prof.

Dr. Helmut Lill, Prof. Dr. Philipp Lobenhoffer

For further information, please contact:

Tel: +49 76169699 246

Fax: +49 76169699 11

arthroskopiekurs-hannover.de/en/

Is your Course an...

ISAKOS
Approved-Course

www.isakos.com/meetings

UPCOMING ISAKOS APPROVED COURSES

International Combined Meeting ESMA-SIGASCOT Masterclass in Sports Trauma: Traumatic Lesions in Professional Soccer Players (New)
Palazzo Ducale
Genoa, ITALY

November 16–17, 2018

Chair(s): Claudio Mazzola, Francesco Giron, Giacomo Zanon, Gian Luigi Canata

For further information, please contact:

Tel: 003933838337991
Fax: 0039055 4641490
www.sigascot.com

ICRS Focus Meeting—I Am Not Ready for Metal
Humanitas University
Milan, ITALY

December 13–14, 2018

Chair(s): Elizaveta Kon, Maurilio Marcacci, Alberto Gobbi

For further information, please contact:

Tel: 0041445037373
Fax: 0041445037372
www.cartilage.org/icrs-focus-meeting-milan/

3rd Course of Osteotomy
Universita' Federico II Congress Center
Naples, ITALY

December 15, 2018

Chair(s): Donato Rosa, Bruno Violante

For further information, please contact:

Tel: 003933838337991
Fax: 0039055 4641490
www.sigascot.com

Update in Elbow Surgery
Ospedale di Sassuolo
Sassuolo, Modena, ITALY

January 17–18, 2019

Chair: Luigi Adriano Pederzini

For further information, please contact:

Tel: +39 0575 19 48 501
Fax: +39 0575 19 48 500
www.iclo.eu

II No Consensus Lisbon Knee Meeting
CUF Hospital Descobertas
Lisbon, PORTUGAL

January 18, 2019

Chair(s): Ricardo Varatojo MD

For further information, please contact:

Tel: +351 965806690
Fax: 210 060 279
www.saudecuf.pt

The Meniscus 2019
Royal Hotel Carlton
Bologna, ITALY

January 31–February 2, 2019

Chair: Professor Stefano Zaffagnini

For further information, please contact:

Tel: 00 33 4 95 09 38 00
Fax: 00 33 4 95 09 38 01
www.the-meniscus.org

EGAA 7th Annual Conference
Sheraton Heliopolis
Cairo, EGYPT

February 19–21, 2019

Chair: Adel Hamed

For further information, please contact:

Tel: +201222360955
Fax: +20226845085
www.egaaonline.com

10th Global Musculoskeletal Ultrasound with
Basic MRI Correlation Conference & Workshop
for Physicians & General Practitioners
Holiday Inn Resort

Penang Island, MALAYSIA

March 17–18, 2019

Chair(s): Professor Dr. John George

For further information, please contact:

Tel: +6012-277 3799
Fax: +603 2690 1301
www.penangmskrad.com

aossmTM
SURGICAL SKILLS

AOSSM & ISAKOS Surgical Skills Course

Osteotomies Around the Knee:
From Ligament Insufficiency to Cartilage/Meniscus Pathologies and Arthritis

Learn more and register
today at sportsmed.org

EARLY BIRD PRICES END
MARCH 12, 2019
**REGISTER AT
SPORTSMED.ORG**

April 12–13, 2019

OLC Education and Conference Center
Rosemont, IL

Course Co-Chairs

Elizabeth A. Arendt MD
Alan M. Getgood MD, FRCS (Tr&Orth)
Robert F. LaPrade MD, PhD

DEMYSTIFY OSTEOTOMY TECHNIQUES

Gain a greater understanding of lower limb alignment and how it may be altered to improve patient function for a variety of knee conditions; from cartilage and meniscal injury, to ligament deficiency to osteoarthritis.

Attendees will learn techniques for realignment osteotomy that provide a clear rationale and practical treatment applications to implement into every day practice.

aossmTM
American Orthopaedic Society
for Sports Medicine



ACTIVE DEPLOYMENT UP TO 6X LESS DISPLACEMENT¹

Compared to other all-suture anchors



References 1. Douglass NP, Behn AW, Safran MR. Cyclic and Load to Failure Properties of All-Suture Anchors in Synthetic Acetabular and Glenoid Cancellous Bone. *Arthroscopy*. 2017 May;33(5):977-985.e5. doi: 10.1016/j.arthro.2016.11.022. Epub 2017 Jan 26. 2. Data on file. Report P/N 49190-01 Rev. B. 3. Erickson J, Chiarappa F, Haskel J, Rice J, Hyatt A, Monica J, Dhawan A. Biomechanical Comparison of a First- and a Second-Generation All-Soft Suture Glenoid Anchor. *The Orthopaedic Journal of Sports Medicine*, 5(7) 1-7, 2017. 4. Data on file. Report 15002117 Rev. A. 5. Data on file. Report P/N 49193-02 Rev. A. 6. Data on file. Report P/N 51963-01 Rev. A. 7. Barber FA, Herbert MA. All-Suture Anchors: Biomechanical Analysis of Pullout Strength, Displacement, and Failure Mode. *Arthroscopy*. 2017 Jun;33 (6):1113-1121. doi: 10.1016/j.arthro.2016.09.031. Epub 2016 Dec 22.

Active deployment



High fixation strength^{5,6,7}



Curved drill guides



Available in multiple sizes



Double-loaded options



SUTUREFIX and Q-FIX[®] All-Suture Anchors

Active Deployment delivery systems confirm successful deployment with audible and tactile cues.^{3,4} They also provide the least displacement,¹⁻³ compared to other all-suture anchors. [Learn more at all-suture.com](http://all-suture.com).

Perform without compromise



Supporting healthcare professionals for over 150 years



International Society of Arthroscopy,
Knee Surgery and Orthopaedic Sports Medicine
2410 Camino Ramon, Suite 215
San Ramon, CA 94583-4318 USA

Telephone: +1 925 807-1197
Fax: +1 925 807-1199
isakos@isakos.com
www.isakos.com



12TH Biennial
ISAKOS
CONGRESS 2019

Cancun, Mexico • May 12-16, 2019

REGISTRATION
NOW OPEN!

A comprehensive educational experience, providing the latest research from around the world—in one place. From basic to advanced topics and surgical techniques, the ISAKOS Congress allows for networking with international peers and experts.

- Six Half-Day Pre-Courses Saturday, May 11, 2019
- Sports Rehabilitation Concurrent Course
- 300+ Scientific Papers
- Panel Discussions & Debates
- Symposia
- Lunchtime Lectures & Workshops
- Surgical Demonstrations
- Instructional Course Lectures
- Paper & ePoster Presentations
- Technical Exhibits
- CME Certification
- Spouse & Guest Program
- Welcome Reception

isakos.com/2019congress

#ISAKOS2019