

ISAKOS

ISAKOS NEWSLETTER 2017 • VOLUME I

Current Concepts on Arthroscopy, Knee Surgery & Orthopaedic Sports Medicine



11TH BIENNIAL
ISAKOS CONGRESS
JUNE 4-8, 2017 | SHANGHAI, CHINA
PRESIDENTIAL GUEST SPEAKER

**YAO
MING**



INSIDE 2

A MESSAGE FROM ISAKOS PRESIDENT, PHILIPPE NEYRET

14

CASE CORNER: COMPLEX PATELLOFEMORAL INSTABILITY

18

CURRENT TRENDS AND COMPLICATIONS ASSOCIATED WITH MUSCULOSKELETAL INJECTIONS

21

SECONDARY RESTRAINTS TO INTERNAL ROTATION: THE ROLES OF THE ANTEROLATERAL LIGAMENT, ILIOTIBIAL BAND, AND LATERAL MENISCUS

24

SCAPHOLUNATE LIGAMENT INJURIES

in this issue

ISAKOS Key Values	1
President's Message	2
2017 Congress, Shanghai, China.....	4
Presidential Guest Speaker	11
Case Corner.....	14
Current Concepts.....	18
Research Reports	28
Fellowship Reports	34
Approved Course Reports.....	42
Upcoming Approved Courses.....	44

EDITOR

Robert G. Marx, MD, MSc, FRCSC UNITED STATES

EDITORIAL BOARD

Stephen L. Lyman, PhD UNITED STATES
David Sadigursky, MD, MSc BRAZIL
Luis Alberto Vargas, MD, PhD UNITED STATES
Omer Mei-Dan, MD UNITED STATES, Past Editor
Benno Ejnisman, MD BRAZIL
Iftach Hetsroni, MD ISRAEL
Christophe H. Hulet, MD, Prof. FRANCE
Bruce A. Levy, MD UNITED STATES
Tatsuo Mae, MD, PhD JAPAN
Daniel Whelan, MD, MSc, FRCSC CANADA



**International Society of
Arthroscopy, Knee Surgery and
Orthopaedic Sports Medicine**

2410 Camino Ramon, Suite 215
San Ramon, CA 94583 – 4318 USA
Telephone: +1 925 807 – 1197
Fax: +1 925 807 – 1199
Email: isakos@isakos.com

EDITOR'S MESSAGE



Shanghai will be HUGE!

The 11th Biennial ISAKOS Congress in Shanghai will be HUGE! Perhaps most impressively, there will be sixty-four countries represented on the program. A total of 90 countries will be in attendance, and will learn and return home with knowledge to improve the care of their patients in their country. In this way, ISAKOS has a truly global reach, as patients around the world will benefit from ISAKOS' dedication to education, and the dissemination of advanced treatment information.

11th Biennial ISAKOS Congress by the numbers:

- 755 ePosters
- 250+ papers
- 31 Instructional Course Lectures
- 40 Symposia
- 15 Live Surgical Demonstrations
- 5 Partner Society Lectures from AANA, AOSSM, APKASS, ESSKA and SLARD

As well, there will be six pre-courses, three in the morning and three more in the afternoon, covering topics related to the Knee, Hip, Shoulder, and practice of Sports Medicine. Truly, the ISAKOS Congress has something for everyone!

To take full advantage of the scientific offerings, I encourage all registrants to visit the ISAKOS Congress Interactive Agenda www.isakos.com/2017/InteractiveAgenda. The Interactive Agenda includes a current list of all Congress events (including handouts and abstracts!), faculty profiles, Lunch Time Session offerings, and the option to build your own schedule.

In addition to teaching and learning, our members will gather to meet other surgeons and health care providers from other countries and learn more about their cultures, languages and health care systems in more informal settings such as meals and receptions.

Have you traveled to Shanghai? The city has something for all attendees, whether you are interested in incredible food, inspiring art and architecture, or great shopping! Optional post-Congress tours are also available for those interested in enjoying Shanghai and the surrounding areas as a tourist outside of the Congress dates. For more information on travel and tours, please visit www.isakos.com/2017/Travel.

The 11th Biennial ISAKOS Congress looks like it will be the best yet—we hope to see you in China for this HUGE event!

Robert G. Marx, MD

ISAKOS Newsletter Editor 2015–2017

海内存知己，天涯若比邻。

“The world is but a little place, after all”

–Chinese Proverb

The International Society of Arthroscopy, Knee Surgery and Orthopaedic Sports Medicine was founded on the basis of a desire of our founding members to “advance the worldwide exchange and dissemination of education, research and patient care in Arthroscopy, Knee Surgery and Orthopaedic Sports Medicine.” Throughout our history, ISAKOS has sought to embrace four key values:

- Global Perspective–We respect diversity and international viewpoints.
- Excellence–We take pride in ensuring quality.
- Integrity–We advocate high ethical conduct in all we do.
- Dedication–We believe in the ISAKOS Mission, its teachings and collaboration with others.

These four values as well as the Chinese proverb referenced above are alive and well in the day to day operations of ISAKOS, as well as evident in our hallmark event, the upcoming ISAKOS Congress.

GLOBAL PERSPECTIVE

ISAKOS’ global perspective is evident in the more than 20 different countries represented in this Newsletter. It is evident in the Journal of ISAKOS, which in just one short year has published 41 papers and 6 editorials from 23 different countries. It is evident in the 81 countries currently represented in the registration for the 11th Biennial ISAKOS Congress in Shanghai.

EXCELLENCE

ISAKOS strives to ensure quality in everything we produce. ISAKOS Committees have produced more than ten different high quality publications on a variety of topics. These books have quickly become known for addressing state of the art and emerging issues on a wide variety of topics, while embracing an international authorship.

INTEGRITY

ISAKOS seeks to embody ethical behavior in all that we do, and will instituting an Ethics Committee to address issues as they arise in any organization of our size.

DEDICATION

ISAKOS is dedicated to our mission and disseminating education around the world. In 2016 alone, ISAKOS participated in more than five different international meetings with financial and faculty support, as well as supporting more than 40 ISAKOS Approved Courses. ISAKOS will bring our unique brand of education to Poland in 2017 with the second event in the ISAKOS Symposium & Workshop Series. Finally, our committees and leadership are dedicated to our mission and spend many, many volunteer hours every week working to accomplish various initiatives for our diverse membership.

The diversity of ISAKOS will be on full display in Shanghai, China in June 2017 for the ISAKOS Congress. All corners of the world will come together to address a wide variety of topics ranging from treatment of the elite FIFA or Olympic Athlete, to pathology and indications related to the shoulder, elbow, wrist, hip, knee, and ankle. Our international faculty will bring a true worldly perspective to these topics, and they look forward to sharing their knowledge with a globally diverse audience.

We hope you enjoy this issue of the ISAKOS Newsletter, and hope to see you at the 11th Biennial ISAKOS Congress in Shanghai!



Greetings from ISAKOS

There are far better things ahead than any we leave behind

–C.S. Lewis

It has been said that “all great things must end”... this is true as I come to the end of my tenure as ISAKOS President. It has been my immense pleasure to serve the membership of ISAKOS as your president for the 2015–2017 Term.

ISAKOS has accomplished great things in the last two years! I began my presidency with the immensely successful ISAKOS Congress in my hometown of Lyon, France. It was a personal pleasure to welcome the ISAKOS Family to a city so close to my heart. The ISAKOS Executive Committee and other leaders gathered in Clearwater, Florida in March 2016 to clarify our vision for the future, and how to solidify ISAKOS' role as a leader in international education. Then we were able to bring that vision and strategic initiative to life in Doha, Qatar with the first **ISAKOS Symposium and Workshop Series Event**. The Symposium and Workshop Series brought ISAKOS' high caliber of education to the Middle East, including a cadaveric skills component not frequently seen in the area.



Perhaps the greatest achievement of ISAKOS over the last year was the successful launch of the Journal of ISAKOS. Under the leadership of Editor-in-Chief C. Niek van Dijk, the *Journal of ISAKOS (JISAKOS)* synthesizes the latest research and evidence-based guidelines in orthopaedic sports medicine to provide busy specialists a thorough reference for diagnosing and treating patients. I have greatly enjoyed reading through the Classics articles and systematic reviews, as well as Niek's insightful editorials. I would also like to thank John Bartlett and the ISAKOS Past Presidents, particularly Masahiro Kurosaka (ISAKOS President 2013–2015) for their guidance and wisdom in bringing the Journal project to fruition.

On a personal note, I must thank the ISAKOS Committees, most specifically the Committee Chairs for their diligence and efforts over the last two years. We reorganized the committee structure in 2015, and the committees have thrived in the work they have accomplished in a short period of time. They have answered the call of ISAKOS, and have performed immense feats. We cannot wait to share the fruits of their labors with you at the ISAKOS Congress in Shanghai, China through the newly released **ISAKOS Publications (www.isakos.com/myISAKOS/myPublications)**. Through their leadership, the ISAKOS Committees have held Current Concept Meetings, completed surveys, updated the ISAKOS website, and more. I hope you will join me in thanking the Committees for their hard work.

The Committees will continue their diligent efforts in the coming months on additional publications, and the reorganization of the **ISAKOS Global Link**. Under the guidance of Luigi Pederzini, the Global Link will be undergoing a review and renovation to become a premier resource for orthopaedic and sports medicine practitioners.

One of the largest labors of love for any ISAKOS President is the **Biennial Congress**. We look forward to welcoming our ISAKOS Family to Shanghai, China for the 11th Biennial Congress. Julian Feller and Stefano Zaffagnini have crafted an impressive program that we think will serve the diverse needs of our international population.

As I conclude my presidency in Shanghai, ISAKOS' future remains bright! We look forward to the second in the ISAKOS Symposium & Workshop Series—the **Master Class in Lodz, Poland**, new committee projects, and more fantastic publications, including at least three more text books! I leave ISAKOS in the capable hands of Marc Safran, ISAKOS President 2017–2019, and I know he will serve you well.

On a personal note, I would like to thank the ISAKOS Executive Committee and the ISAKOS Office for their diligent efforts, and incredible support throughout these last two years. The success of ISAKOS depends greatly on our leadership and the support of the Office, and we have wonderful collaboration.

Finally, I must thank my wonderful wife, Isabelle (pictured below) for her love and support during this busy presidential term.



ISAKOS has much to look forward to in the future, and I look forward to continuing the journey!

Philippe Neyret, MD, PhD, FRANCE

ISAKOS President 2015–2017



THE YEAR OF THE CONFERENCE!

In 1995, The ISAKOS family was founded in Hong Kong by the merger of the International Arthroscopy Association (IAA) and the International Society of the Knee (ISK). Now over 20 years later, Asia will be another ISAKOS Conference Host, this

time in the remarkable city of Shanghai.

For me, ISAKOS looks with pride and gratefulness to the past: to our masters that – thanks to their revolutionary work – make a bright future possible for millions of patients and show us the right direction towards new developments and collaborations. Like a Chinese Proverb said: “The grass doesn’t grow by pulling on its blades, but by watering its roots.”

This future will follow that ISAKOS Legacy but – as we know that the only constant in life is CHANGE – it will be different. Since every ISAKOS Meeting highlights the latest technical improvements in a spirit of mutual understanding, friendship and enriching humanism, why don’t we start preparing together at Shanghai?

When looking at the recent history of China, somewhat 100 years ago, the QING Dynasty was overthrown and the Republic of China was born. In Sports Surgery, we also need to prepare for constant change since I believe that our future – like all challenges in Medicine – will be directed by what is called “the BING REVOLUTION”:

B for Biotechnology
I for Informatics and Artificial Intelligence
N for Nanotechnology and
G for Cognitive Sciences

Future technologies are growing at a fast pace and communication access is all over. I believe it will be a challenge for all us to navigate through these changes to the benefit of our patients and the next orthopaedic generation. Like our honorable President recently said: “Education is the wine cellar of our future orthopaedic surgeons.”

Exactly ten years ago, I got in contact with ISAKOS during my final fellowship weeks. The absolute highlight that year was the Florence conference in Italy. I just started up my private practice and became curious about this international society that aligned with my medical field of interest. Now 10 years later, I reflect gratefully on how ISAKOS can change your life. After Florence came Osaka, Rio, Toronto, Lyon and suddenly you realize you’ve met the world and learned from the best. That’s what ISAKOS’ mission is about but it’s also time to “give back” in line with this adopted ISAKOS’ spirit. Like Franklin Roosevelt said, “If you want to make a friend, be one.”

As Chair of the ISAKOS Leg, Ankle and Foot Committee (LAF), I have the privilege of collaborating with our enthusiastic LAF Committee, the Board and Program Committee towards Shanghai 2017. Exciting months ahead for us all to deliver in the Scientific Paper Sessions, Discussions and Debates, Symposia, Live Surgical Demonstrations, Electronic Posters, Technical Exhibits, Instructional Course Lectures, Lunch Time Lectures, Hands on Workshops and Social Programs. My ten years of membership have been a rollercoaster of Science, Education, Management and Friendship so far. I’m convinced that the Shanghai ISAKOS Meeting will show us again that $1 + 1 = 3$. Meaning that if you put together each one of our individual qualities, the final result is much more important than the mathematical one. Thank you ISAKOS!

“...suddenly you realize you’ve met
the world and learned from
the best”

Consequently, ISAKOS becomes a way of life rather than being an addition of techniques, becomes a lesson of life rather than just another arthroscopic lecture and finally becomes a “rendez-vous” of collegial support rather than just another medical conference. This is why ISAKOS has a bright future ahead and that’s why it is such a great platform for “young surgeons” like us. Looking forward to Shanghai, the next step in the realization of these exciting challenges!

Pieter D’Hooghe

On behalf of the ISAKOS Leg,
Ankle and Foot Committee (LAF)

欢迎来到上海 • WELCOME TO SHANGHAI

11TH BIENNIAL

ISAKOS CONGRESS

JUNE 4-8, 2017 | SHANGHAI, CHINA

On behalf of the community of ISAKOS, we welcome you to the 11th Biennial ISAKOS Congress! The ISAKOS Congress embodies the fraternity, and international exchange of ideas that ISAKOS is known for.

The city of Shanghai is known as a showpiece of modern China. A popular tourist destination, Shanghai features such historical landmarks as The Bund, City God Temple and Yu Garden. Other cultural highlights include the Shanghai Museum and the China Art Museum. Shanghai is well recognized for its extensive Lujiazui skyline featuring many skyscrapers.

The five-day ISAKOS Congress will include a myriad of educational opportunities. The meeting provides a variety of new and cutting edge surgical techniques and approaches to clinical management, combined with overviews of current controversies in orthopaedic practice.

ISAKOS' international perspective is evident in our more than

280

unique faculty members

REPRESENTING

37 different countries

AN ADDITIONAL

550 will present Papers and E-Posters, representing

participants

64 different countries.

The ISAKOS Congress will begin with a full day of pre-courses on Saturday, June 3rd. The pre-course day will include six half-day pre-courses on a variety of topics ranging from sports medicine, to the knee, hip and shoulder. We encourage you to consider attending the pre-courses, and have included a description of each course in this Newsletter on page 12.

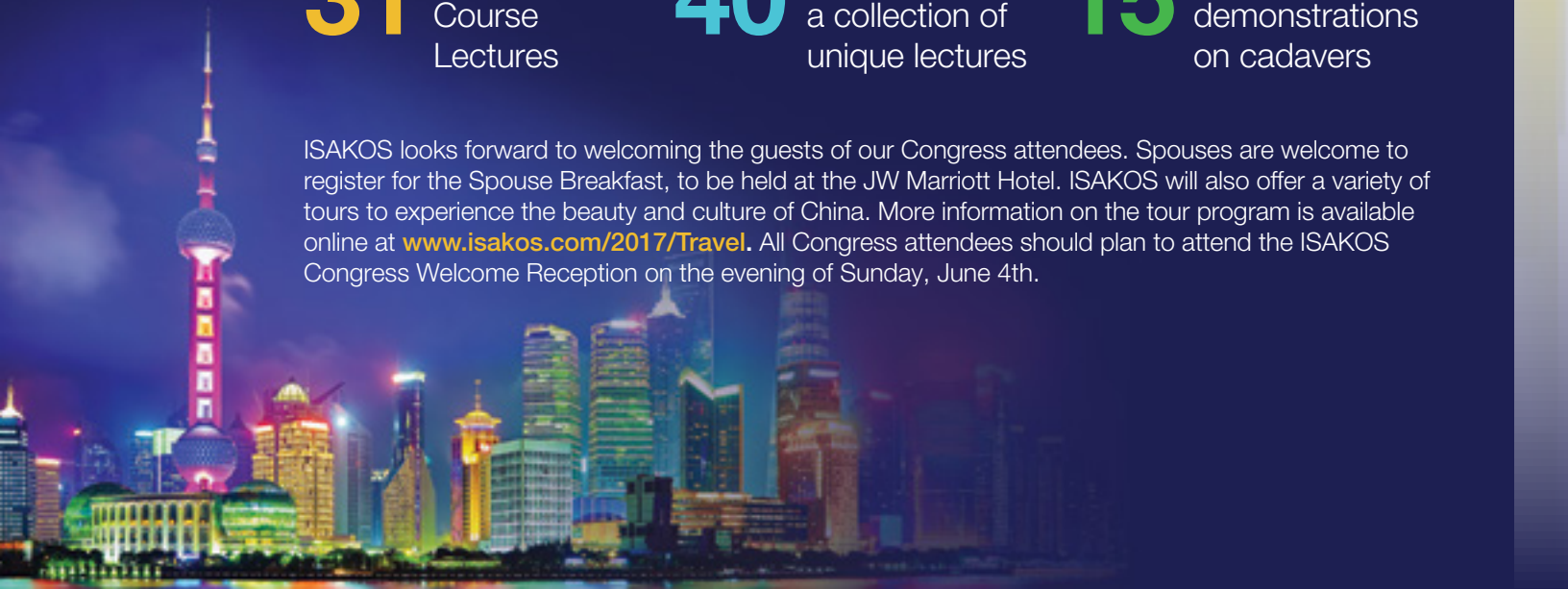The ISAKOS Congress will officially begin on Sunday, June 4th. The Congress will include a wide variety of topics and educational opportunities ranging from

31 Instructional Course Lectures

40 symposia, and a collection of unique lectures

15 live surgical demonstrations on cadavers

ISAKOS looks forward to welcoming the guests of our Congress attendees. Spouses are welcome to register for the Spouse Breakfast, to be held at the JW Marriott Hotel. ISAKOS will also offer a variety of tours to experience the beauty and culture of China. More information on the tour program is available online at www.isakos.com/2017/Travel. All Congress attendees should plan to attend the ISAKOS Congress Welcome Reception on the evening of Sunday, June 4th.



SURGICAL DEMONSTRATIONS

SUNDAY, JUNE 4 – WEDNESDAY, JUNE 7

SUNDAY, JUNE 4

- 09:00–10:00 **KNEE**
Single Anteromedial Bundle Biological Augmentation
LSD Presenter: Bertrand Sonnery-Cottet, MD FRANCE
Moderator: Moises Cohen, MD, PhD, Prof. BRAZIL
- 10:15–10:45 **HIP**
Labral Repair
LSD Presenter: Marc J. Philippon, MD UNITES STATES
Moderator: J.W. Thomas Byrd, MD UNITED STATES
- 11:15–12:00 **TOTAL KNEE REPLACEMENT**
Tibia First Balanced Femur Total Knee Arthroplasty
 Mark Clatworthy, FRACS NEW ZEALAND
Moderator: Nicolaas Cyrillus Budhiparama, MD, FICS INDONESIA
- 13:30–14:30 **SHOULDER–INSTABILITY**
Arthroscopic Bone Block for the Treatment of Glenoid Bone Loss
LSD Presenter: Ettore Taverna, MD ITALY
- 15:30–16:15 **KNEE–ACL**
Anatomical ACL Reconstruction
LSD Presenter: Freddie H. Fu, MD UNITED STATES
Moderator: Charles H. Brown, Jr., MD UNITED ARAB EMIRATES
- 16:30–17:30 **KNEE–ARTHROPLASTY**
Robotic-Assisted Bi-Cruciate Substituting Total Knee Replacement
LSD Presenter: David Mayman, MD UNITED STATES
Moderator: Sebastien Lustig, MD, PhD, Prof. FRANCE

MONDAY, JUNE 5

- 14:00–14:45 **SHOULDER**
Rotator Cuff Repair
LSD Presenter: Ian King Yeung Lo, MD CANADA
Moderator: Geoffrey D. Abrams, MD UNITED STATES
- 15:30–16:15 **SHOULDER**
Posterior Instability Repair
LSD Presenter: Felix Henry Savoie III, MD UNITED STATES
Moderators: Philippe Landreau, MD QATAR
 Ian King Yeung Lo, MD CANADA

MONDAY, JUNE 5

- 16:30–17:30 **Knee–Meniscus**
Meniscal Root Repair
LSD Presenters: Robert F. LaPrade, MD, PhD UNITED STATES
 Hua Feng, MD CHINA
Moderator: James Robinson, MBBS, MRCS, FRCS(orth), MS UNITED KINGDOM

TUESDAY, JUNE 6

- 10:45–11:30 **SHOULDER–ROTATOR CUFF**
Complex Rotator Cuff Tear
LSD Presenter: Yong-Girl Rhee, MD REPUBLIC OF KOREA
Moderator: Jeffrey S. Abrams, MD UNITED STATES
- 13:30–14:15 **KNEE**
Lateral Extra-Articular Tenodesis Lateral Extra-Articular Tenodesis
LSD Presenter: Andy Williams, MBBS, FRCS, FRCS (Orth), FFSEM(UK) UNITED KINGDOM
Moderator: Andrew A. Amis, FREng, PhD, DSc UNITED KINGDOM
- 14:15–15:00 **PATELLAR JOINT**
Patellar Stabilization
LSD Presenters: David Henri Dejour, MD FRANCE
 Sachin Ramchandra Tapasvi, MBBS, MS, DNB, FRCS INDIA
Moderator: Elizabeth A. Arendt, MD UNITED STATES

WEDNESDAY, JUNE 7

- 11:00–12:00 **SHOULDER–ROTATOR CUFF**
Massive Rotator Cuff Repair
LSD Presenter: John Tokish, MD UNITED STATES
Moderator: Emilio Calvo, MD, PhD, MBA SPAIN
- 13:30–14:15 **HIP**
Gluteus Medius Repair
LSD Presenter: J.W. Thomas Byrd, MD UNITED STATES
Moderator: Marc R. Safran, MD UNITED STATES
- 15:30–16:30 **KNEE–ARTHROPLASTY**
Kinematic Total Knee Replacement
LSD Presenter: Stephen M. Howell, MD UNITED STATES
Moderator: Myles Raphael James Coolican, FRACS AUSTRALIA

SHANGHAI TOURS

OPTION 1

Suzhou (Humble Administrator Garden, The Master-of-Nets Garden)

\$99/CNY653

June 3–9, Every Day

08:00 to 18:00

Number of participants: min.10/max.30

Humble Administrator Garden

The beautiful waterside City of Suzhou in Jiangsu Province in South China is most famous for its elegant classical gardens. Among these, the Humble Administrator's Garden, covering about 52,000 sq. meters (12.85 acres), is the largest and most renowned. Due to its unique designs and ethereal beauty, it is listed as a World Cultural Heritage site and has also been designated as one of the Cultural Relics of National Importance under the Protection of the State as well as a Special Tourist Attraction of China.

The Humble Administrator's Garden was originally built in 1509 during the Ming Dynasty (1368–1644). It was initially a private garden of a former government servant named Wang Xianchen.

The garden was created upon the old relics of a residence and a Taoist temple. Water feature is the main background and its natural landscape includes small forests, hills and rock formations. It also has man-made pavilions, halls and parlors.



The Master-of-Nets Garden

It is the smallest of the Suzhou residential gardens, yet it is the most impressive because of its use of space which creates the illusion of an area that is much greater than its actual size. Even more than the architectural achievement is the mood of tranquility and harmony that it embodies.

The garden is divided into three sections: a residential section, the central main garden and an inner garden.

As you walk about the gardens and along the walkways, you can often see beautiful flowers or plants through delicate windows which frames the scenery from a distance and draw you to a single sight, a moment of peaceful natural beauty.

Shantang Old Street

Shantang Street, an ancient riverside pedestrian road in northwest Suzhou, Jiangsu, is very popular with tourists. From Changmen Gate (the west gate of the ancient city) in the downtown, it winds northwest on the northern bank of the Shantang River, and ends at scenic Tiger Hill. It extends about 2.2 miles (7 li), hence the name 'Seven-Li Shantang'.



The old street sector is about 395 yards (360 meters) long. Although it fills only one tenth of the length, it has the essence of the Shantang block and is called the 'miniature of the old Suzhou' and the 'window of Jiangsu culture'. It was a commodities hub, where merchants conducted business and community staged folk activities. It was one of the most eventful streets in Ming (1368–1644) and Qing (1644–1911) Dynasties.

ISAKOS ENCOURAGES CONGRESS ATTENDEES AND THEIR GUESTS TO EXPLORE THE RICH CULTURE AND SITES OF SHANGHAI!

OPTION 2

Panda House

\$43/CNY284

Saturday, June 3; Thursday, June 8

09:00 to 12:00

Number of participants: min.10/max.30

More than 100,000 trees flourish here. A wide variety of flowers are also displayed. There is also a Scientific Building, the first of its kind established in China, situated in the zoo.

Shanghai Zoo is a large-scale state-level zoo. Shanghai Zoo is divided into five exhibition areas.



OPTION 3

Tianzifang & Shanghai World Financial Center

\$65/CNY429

Saturday, June 3; Monday, June 5; Thursday, June 8

13:00 to 16:00

Number of participants: min.10/max.30

Tianzifang

Tianzifang is an arts and crafts enclave that has developed from a renovated residential area in the French Concession area of Shanghai, China. It is now home to boutique shops, bars and restaurants.

Shanghai World Financial Center

Shanghai World Financial Center is the second tallest skyscraper in mainland China. While wandering on the floor made of transparent glass, you can see the top of the Oriental Pearl Tower just in front and feel as if you are walking in the air above the roof of the Jinmao Building.



ISAKOS encourages attendees of the 11th Biennial ISAKOS Congress to supplement your Congress experience with tours exploring the rich culture and history of China!
www.isakos2017congresstour.com/

OPTION 4**Shanghai Museum****\$40/CNY264**

Saturday, June 3; Tuesday, June 6

14:00 to 17:00

Friday, June 9

13:00 to 16:00

Number of participants: min.10/max.30

Shanghai Museum has a mind-boggling collection of 120,000 precious exhibits including bronze, pottery, porcelain, calligraphy, Jade, furniture, coins, the collection of the minority group people painting.

**OPTION 5****Zhu Jia Jiao****\$55/CNY363**

Sunday, June 4; Wednesday, June 7

09:00 to 12:00

Number of participants: min.10/max.30

Zhu Jia Jiao, where market had already formed during the Song and Yuan Dynasty. The town is crisscrossed by rivers and canals, with 9 long streets running along the rivers and thousands of buildings of Ming and Qing Dynasty architecture flanking both sides.

The antiquity of the bridges, the rareness of the streets and the seclusion of the alleyways all present you a scene of boats sailing on the water and people touring in painting.

OPTION 6**Yu Garden & Jade Buddha Temple****\$50/CNY330**

Sunday, June 4; Wednesday, June 7

13:00 to 16:00

Tuesday, June 6

09:00 to 12:00

Number of participants: min.10/max.30

Yu Garden

Yu Garden is a famous classical garden located in Anren Jie, Shanghai. It was finished in 1577 by a government officer of the Ming Dynasty (1368 – 1644) Yu in Chinese means pleasing and satisfying.

Recognized as a significant national heritage site, the Garden is a remarkable representation of a southern Chinese-style garden.

Jade Buddha Temple

Jade Buddha Temple, constructed in 1918, ranks as one of Shanghai's top tourist draws.

The interior is heavy in the wow-factor with its classic Chinese architecture and is highlighted by a massive jade statue of Buddha. But what makes this so wildly popular is the ability to witness the temple's resident monks perform their daily ceremonies throughout its four halls.

These daily "events" provide amazing first-hand insight to China's ancient religious culture.



OPTION 7

French Concession

\$40/CNY264

Sunday, June 4; Thursday, June 8

14:00 to 17:00

Number of participants: min.10/max.30

The Shanghai French Concession was a foreign concession in Shanghai, China from 1849 until 1943, which progressively expanded in the late 19th and early 20th centuries. The concession came to an end in 1943.

For much of the 20th century, the area was one of the centers of Catholicism in China.

Furthermore, the area retains a distinct character, and is a popular tourist destination. The most famous attractions is Xintiandi and Shikumen Residence.



OPTION 8

Local Community and Dumpling Cooking

\$85/CNY561

Monday, June 5; Friday, June 9

10:00 to 12:30

Number of participants: min.10/max.30

If you want to experience the life of an ordinary Shanghai resident, please come to Caoyang New Village and spend some time with a local family. You could learn to prepare a few Shanghai dishes and taste your own cooking at the same table with your host family, which may have three generations under the same roof.



OPTION 9

Cruise + Bund

\$57/CNY376

Monday, June 5; Wednesday, June 7; Friday, June 9

14:00 to 17:00

Tuesday, June 6

13:00 to 16:00

Number of participants: min.10/max.30

The Bund is a famous waterfront and regarded as the symbol of Shanghai for hundreds of years. The most famous and attractive sight which is at the west side of the Bund are the 26 various buildings of different architectural styles. It is now acclaimed as an outdoor museum of international architecture and worth a visit to see the florid night view of the Bund.

www.isakos.com/2017/travel

2017 11TH BIENNIAL
ISAKOS CONGRESS
JUNE 4-8, 2017 | SHANGHAI, CHINA



YAO MING

PRESIDENTIAL GUEST SPEAKER

The Way to Improve Psychological Rehabilitation –
Trust Between Therapist and Injured Athlete

General Session – Room 301

Tuesday, June 6

09:35 – 10:10

Born in Shanghai, Yao Ming is one of China's best-known athletes. A retired professional basketball player, Ming played for the Shanghai Sharks of the Chinese Basketball Association (CBA) and the Houston Rockets of the National Basketball Association (NBA). At the time of his final season, he was the tallest active player in the NBA, at 7 feet 6 inches. Ming ranks sixth among franchise leaders in total points and total rebounds, and second in total blocks.

isakos.com/2017congress

   #ISAKOS2017

ISAKOS CONGRESS PRE-COURSES

SATURDAY, JUNE 3, 2017

ISAKOS Congress Pre-Courses are to be held on Saturday, June 3, 2017. Pre-Course Day Registration includes admission to one morning and one afternoon Pre-Course.

Program information, agendas and faculty details are subject to change. Please check the Interactive Agenda for the most up-to-date information – www.isakos.com/2017/PreCourses

MORNING COURSES

The Knee: Maximizing Surgical Procedures in the Active & Athletic Patient

Elizabeth A. Arendt, MD UNITED STATES

Mark Clatworthy, FRACS NEW ZEALAND

Christopher John Vertullo, MBBS, FRACS (Orth), FAOrthA AUSTRALIA

This pre-course is targeted to the orthopaedic surgeon whose practice centers on the young and the aging sports knee. It will present the latest knowledge and surgical techniques relevant to the management of knee pathology, focusing on surgical knowledge and technique. The course will be suitable for the subspecialist knee surgeon as well as the general orthopaedic surgeon desiring an update on controversies and techniques within the athletic and the aging knee.

The half-day course will consist of a series of expert and evidence based lectures combined with case examples querying the experts on difficult problems with diverse and at times controversial solutions. Key cadaveric surgical demonstrations are embedded within each topic. An interactive audience response system has enhanced audience participation and has augmented audience education. Following this course, the participant will be well-versed in the approach to the injured athletic knee, with improved knowledge in its management.

CME Certification*

The American Academy of Orthopaedic Surgeons designates this live activity for a maximum of **4.5 AMA PRA Category 1 Credits™**.

The IOC Prevention of Injuries & Illnesses in High Level Athletes

Lars Engebretsen, MD, PhD NORWAY

Gino M.M.J. Kerkhoffs, MD, PhD, Prof. NETHERLANDS

Upon completion of this pre-course, participants will be able to understand the principles of injury and illness prevention. Practical examples will translate the principles into practical programs on Olympic athletes.

CME Certification*

The American Academy of Orthopaedic Surgeons is accredited by the ACCME to provide continuing medical education for physicians. The American Academy of Orthopaedic Surgeons designates this live activity for a maximum of **3.75 AMA PRA Category 1 Credits™**.

Current Concepts in Shoulder Surgeries: New Insights into Instability, Rotator Cuff Repair and Minimal Invasive Humeral Fracture Fixation

Andreas B. Imhoff, MD, Prof. GERMANY

Felix Henry Savoie III, MD UNITED STATES

This course will present the latest techniques in shoulder stabilization like Latarjet – the French and US experience, and also new insights into rotator cuff repair (tendon to bone healing and superior capsule reconstruction) and minimally invasive humeral fracture fixation. Each presentation will be moderated separately as a cross-fire to involve the attending members.

CME Certification*

The American Academy of Orthopaedic Surgeons designates this live activity for a maximum of **4.0 AMA PRA Category 1 Credits™**.

*These activities have been planned and implemented in accordance with the accreditation requirements and policies of the Accreditation Council for Continuing Medical Education (ACCME) through the joint providership of the American Academy of Orthopaedic Surgeons and the International Society of Arthroscopy, Knee Surgery and Sports Medicine. The American Academy of Orthopaedic Surgeons is accredited by the ACCME to provide continuing medical education for physicians.

AFTERNOON COURSES

Advanced Course on Knee Arthroplasty

Sebastien Lustig, MD, PhD, Prof. FRANCE
 Shuichi Matsuda, MD, PhD JAPAN
 Willem Mare van der Merwe, MBChB, FCS, SA Ortho
 SOUTH AFRICA

This pre-course will provide a comprehensive update and overview of the latest knowledge and techniques relevant to knee arthroplasty for the orthopaedic surgeon. The topics will include basic concepts and surgical technique of cruciate retaining and cruciate-sacrificed total knee arthroplasty, as well as unicompartmental knee arthroplasty. Focusing on management for severe varus or valgus deformity, instability, contracture, bone defect, and intraoperative trouble shooting. We have assembled an international faculty, including experts from around the world, presenting on their areas of expertise.

This half-day course will consist of a series of expert and evidence-based lectures. In addition to the lectures there will be panel discussions, particularly on controversial topics such as kinematic alignment. This pre-course will present a variety of surgical techniques, involving video demonstrations, as well as pearls and pitfalls, and discussions for each topic. Following this course, participants will be able to understand how to treat more difficult cases such as severe varus or valgus deformity by total knee arthroplasty.

CME Certification*

The American Academy of Orthopaedic Surgeons designates this live activity for a maximum of **4.0 AMA PRA Category 1 Credits™**.



The Use of Biologics to Treat Sports Medicine Pathology

Johnny Huard, PhD UNITED STATES
 Robert F. LaPrade, MD, PhD UNITED STATES
 Nicola Maffulli, MD, PhD, MS, FRCS(Orth)
 UNITED KINGDOM

The course aims to provide a clinical-based overview on the scientific basis for the use of biologics to treat orthopaedic sports medicine pathology. The various treatment options available, including growth factors, platelet rich plasma, and stem cells will be presented, and the basic science rationale behind their use clarified. Their clinical use will be presented, the regulatory issues related to their use, and the evidence on their effectiveness and efficacy will be discussed.

CME Certification*

The American Academy of Orthopaedic Surgeons designates this live activity for a maximum of **3.75 AMA PRA Category 1 Credits™**.

Evaluating Athletes with Hip and Groin Problems: From Symptoms to Diagnosis and Treatment

Per Hölmich, Prof., DMSc DENMARK
 Nick Mohtadi, MD, MSc, FRCS(C) CANADA
 Allston J. Stubbs, MD UNITED STATES

At the completion of this course, participants will be able to understand the presenting complaints, symptoms and patient reported outcome information. Participants will be able to confirm the common diagnoses in athletes presenting with a hip and groin problem. Participants will be able to understand the role of non-surgical and surgical treatment of common groin and hip conditions.

CME Certification*

The American Academy of Orthopaedic Surgeons designates this live activity for a maximum of **3.5 AMA PRA Category 1 Credits™**.

*These activities have been planned and implemented in accordance with the accreditation requirements and policies of the Accreditation Council for Continuing Medical Education (ACCME) through the joint providership of the American Academy of Orthopaedic Surgeons and the International Society of Arthroscopy, Knee Surgery and Sports Medicine. The American Academy of Orthopaedic Surgeons is accredited by the ACCME to provide continuing medical education for physicians.

Complex Patellofemoral Instability 2 Cases: Adult & Skeletally Immature



Case Presenter:
Petri Sillanpää, MD, PhD
*Dextra Hospital
Tampere, FINLAND*

Panel:

Elizabeth Arendt, MD *UNITED STATES*
Christopher John Vertullo, MBBS, FRACS (Orth), FAOrthA
AUSTRALIA
Ryosuke Kuroda, MD, PhD *JAPAN*

Case 1

A 17-year-old girl sustained a lateral patellar dislocation at school at the age of 12.5 years, just before skeletal maturity. The left patella dislocated first, followed by the right patella six months later. The patient underwent initial nonoperative management for both knees, including physiotherapy.

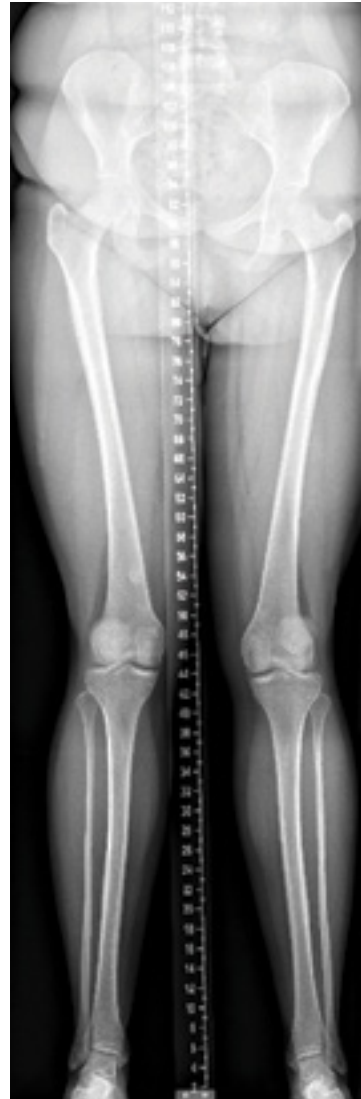During the next two to three years, the patient sustained multiple patellar dislocations and reported occasional pain. By the age of 16 years, she no longer participated in any running activities or any physical activities at school. She was referred to me for consideration of surgery.

The clinical examination demonstrated multiple abnormal findings. Both lower limbs were in substantial valgus alignment. Patellar tracking revealed an obvious J-sign, with the patella relocating by 30° of active knee flexion. Both patellae were laterally translated in full extension, with the patient complaining of knee discomfort in full extension with active quadriceps contraction; the symptoms were greater on the left side than on the right.

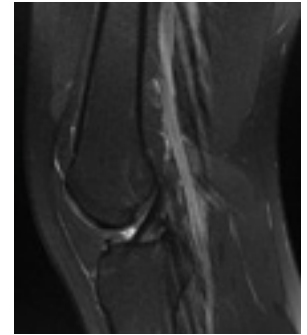Imaging studies included standard radiographs, axial weight-bearing radiographs, routine MRI scans of both knees, and additional rotational MRI scans for axial alignment.

What are the major factors predisposing to recurrent patellar instability?

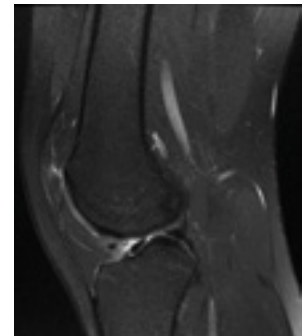Vertullo: PFJ instability in these complex cases is of course multifactorial and a combination of a number of factors including MPFL laxity, trochlear morphology, patellar tendon length and tibial tubercle–trochlear morphology. It is important to regard the anatomy, but we must understand we cannot make it “normal.”



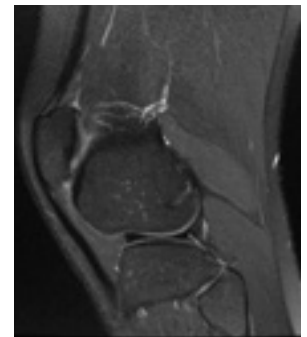01



02



03



04

Kuroda: She has a flat trochlea and patellar dysplasia with patella alta. The most important factors influencing this patient might be lower-limb alignment.

Arendt: It is accepted that complex PJI is multifactorial. Patella alta is a major factor, a flat trochlea and a deficient MPFL. Other factors include a lateral patella with (likely) tight lateral structures and valgus knee alignment.

What radiographic imaging findings most concern you and factor into your surgical algorithm?

Vertullo: The failed MPFL, patella alta, trochlear morphology.

Kuroda: Valgus knee alignment, patellar alta, trochlea dysplasia.

Arendt: Patella alta, flat trochlea, valgus knee. I don't think limb version, tibial in her case, plays a major role in PJI as she does not have pain as a major complaint. Of course, all factors play some role.

Which anatomic imaging factors would you surgically correct? Which technique would you use?

Vertullo: In these complex multifactorial situations, the key is not to try and correct all of the abnormalities but rather to avoid further patellofemoral instability events without producing unintended consequences. Hence, I have a pragmatic functional approach rather than attempting to achieve anatomic “normalization.” Often, these patients have the same pathology on the opposite side, frequently without any functional instability.

In this case, given the radiographic findings, I would consider an MPFL reconstruction with tibial tubercle distalization in order to engage the patella in the trochlea earlier in flexion than currently is occurring. I reserve trochleoplasty for habitual dislocation or revision cases given the lack of high-level data directly comparing MPFLR in isolation to MPFLR with trochleoplasty. MPFL reconstruction is the cornerstone of PFJ stabilization in my practice, and I add tibial tubercle distalization as required.

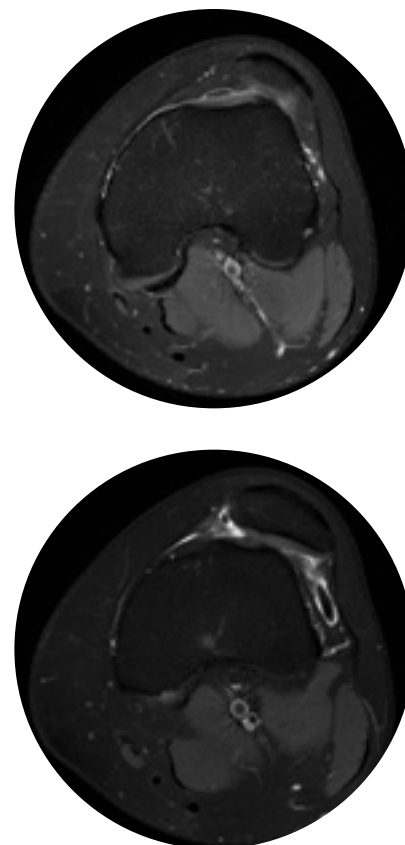
Another clinical problem is the lack of validity and reliability of trochlear morphology classification systems. The role of derotational and coronal plane alignment in corrective osteotomies remains uncertain.

Kuroda: Closing distal femoral osteotomy to correct valgus alignment might be the first step.

After correcting the alignment, MPFL reconstruction or anterior-medialization of tuberosity will be chosen up to the patellar tracking and TT-TG.

Additional trochleoplasty might be considered.

Arendt: I would address the PF instability first, which to me would involve MPFL reconstruction with LRL/LRR as needed. I would perform distal TTO, with medialization if necessary, to achieve a tubercle-sulcus angle of 0°. I would perform these procedures in a single setting, with the contralateral limb addressed during a second-stage procedure. I would not address the valgus angulation at this age (as the growth plates are closed) unless the patient had lateral tibiofemoral issues. I would not perform a trochleoplasty as the patient has no substantial trochlear prominence, and distalizing the patella would engage the patella in a deeper portion of the groove, helping to correct the J-sign.



- 01 Limb alignment : ° right/° left Mechanical Axis 8/9 mLDA 82/83 mMPTA 89/90
- 02 MRI: TT-TG: not measurable, because of B dysplasia
- 03 TT-PCL 20/21mm Trochlear depth: 0mm, B dysplasia Patellar alta: C-D 1.4/1.4
- 04 Rotational study: (in degrees) Anteversion L 22, R 26 External tibial torsion L 34, R 30

Complex Patellofemoral Instability 2 Cases: Adult & Skeletally Immature

Case 2

A skeletally immature patient with unilateral recurrent patellar instability was first seen by me at the age of 10 years. She had had four redislocations of the right knee, each of which had become less painful over time. She was able to run and to participate in school activities, but activities became more difficult over the next two years.

She returned to me for further evaluation at the age of 12 years, at which time she remained pre-menarchal. Clinical examination revealed a J-sign, which had become more prominent over the preceding two years. The limb was in valgus alignment, the J-sign was obvious, and apprehension positive.

Imaging studies included radiographs and MRI scans.

What are the major factors predisposing to recurrent patellar instability?

Vertullo: The failed MPFL, the patella alta, and the trochlear morphology.

Kuroda: She also has shallow trochlea and valgus knee alignment. The major factor is insufficiency of the MPFL.

Arendt: Shallow trochlea and MPFL insufficiency, followed by valgus knee alignment.

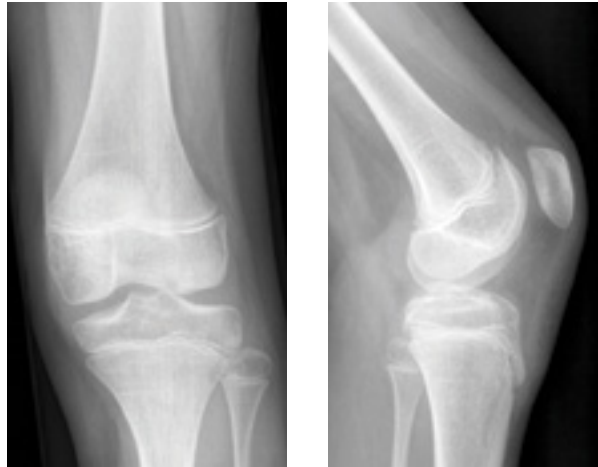
Though her C/D measures high, her patellar trochlea engagement on sagittal MRI looks sufficient, so I do not think patella alta is a major factor.

What radiographic imaging findings most concern you and factor into your surgical algorithm?

Vertullo: The patient's skeletal immaturity.

Kuroda: Shallow trochlea, patellar alta, open epiphysis.

Arendt: Open physis with a valgus knee alignment.



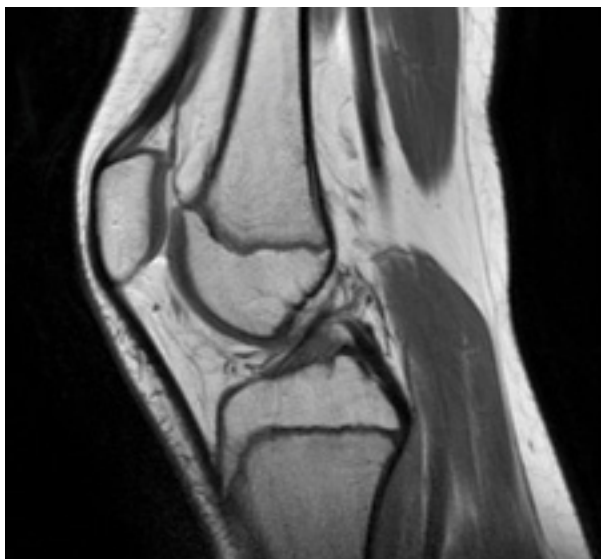05

Which anatomic imaging factors will you surgically correct? Which technique would you use?

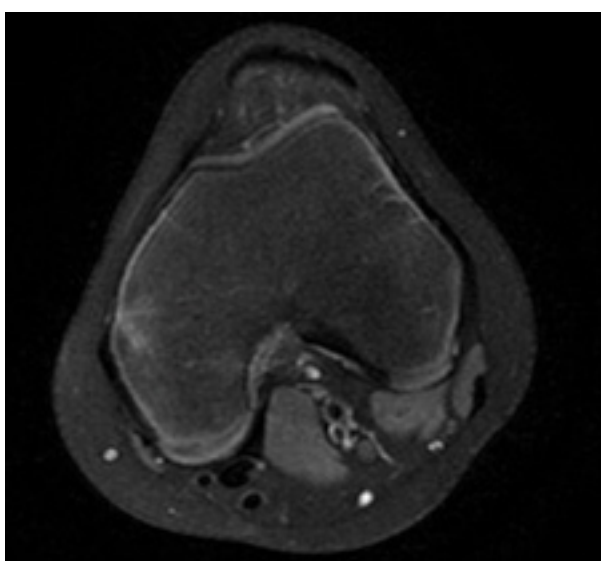
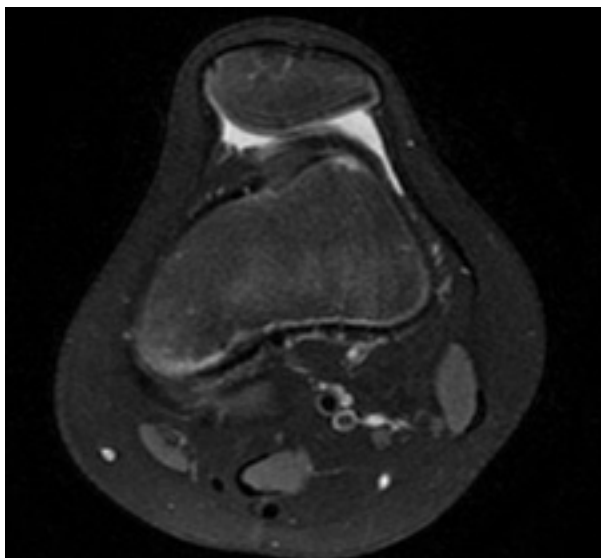
Vertullo: I would perform MPFL reconstruction, with attention to the MFPL femoral insertion and its relationship to the physis, placing the graft distal to the femoral physis.

Kuroda: MPFL reconstruction is the first choice during open epiphysis periods. After the growth plate has closed, distal femoral osteotomy and/or tibial tubercle transfer would be chosen, depending on the patellar tracking.

Arendt: I would consider guided growth surgery if better clarity could be achieved with regard to the degree of limb valgus and if at least two years of growth remains. An MPFL reconstruction with avoidance of the physis could be performed at the same time. The patient likely has tight lateral structures, which will be addressed by LRL/LRR. A mild J-sign may still be present postoperatively, and this possibility needs to be discussed.



06



07

Tips for Clinicians

- 1 Limb Alignment:
 - a Both axial and rotational alignment can be a factor in complex patellar instability.
 - b When excessive alignment is diagnosed on physical exam, use axis radiographs (AP weight bearing long leg alignment) and rotational MRI/CT studies (rotational alignment) for objective evaluation to best evaluate their potential role PFI
- 2 In the skeletally immature patient: axis alignment should always be evaluated and potentially treated, as it is easier to correct mild to major deformities by guided growth than in the adult population with closed physes.
- 3 Remember to consider all factors before planning surgery. However, in these complex multifactorial situations, the key is to not attempt anatomic “normalization” (i.e., correcting all abnormalities). The goal is to avoid further patellofemoral instability events and to improve quality of life while minimizing potential unintended consequences.
- 4 Although global guidelines can be elucidated, every patient needs an individualized surgical plan based on anatomic factors, age, psycho-social factors, and patient-specific surgical expectations.

05 Limb alignment: right/left (in degrees)
 MAD 9/8
 mL DFA 82/84
 mMP TA 88/90

06 Lateral: patellar height (Right/Left) C-D 1.5/1.4

07 MRI: (Right/Left)
 TT-TG: 15/13mm
 Trochlear depth: 2/1mm
 Patellar alta: C-D 1.5/1.4

Current Trends and Complications Associated with Musculoskeletal Injections

Scott Caterine, Masters Candidate

London, ON, CANADA

Alan Getgood, MPhil, MD, FRCS (Tr&Orth)

London, ON, CANADA

Robert LaPrade, MD, PhD

Vail, CO, UNITED STATES

Daniel Slullitel, MD

Rosario, ARGENTINA

On behalf of the ISAKOS Sports Medicine Committee

Corresponding Author: Dr. Daniel Slullitel

Introduction

Intra- and extra-articular joint injections play a major role in the diagnosis and treatment of musculoskeletal injuries and disease. Generally, intra-articular injections are used to treat degenerative conditions such as osteoarthritis and inflammatory diseases such as rheumatoid arthritis. Extra-articular injections are used to treat a variety of medical and traumatic pathologies around multiple joints and connective tissues throughout the body. With the multitude of injection types, injection sites, and different disease indications, it is difficult to ascertain injection patterns commonly utilized in clinical practice. Furthermore, due to a lack of documentation in the literature, it is hard to determine patterns of complications associated with these injections.

The purpose of this short report is to present the results of a recently conducted survey of the ISAKOS membership, administered by the ISAKOS Sports Medicine committee. Two hundred and twenty-two clinicians who specialize in sports medicine, sports trauma, and orthopaedics responded to a survey that was designed to provide an understanding of injection trends and associated complications.

Survey Results

Type and frequency of injection

Joint injections are commonplace in an orthopaedic clinical practice. Hill et al., in a survey of 233 clinicians, reported that, on average, orthopaedic surgeons perform 150 intra-articular injections and 193 extra-articular injections annually. Our survey of 222 clinicians indicated a large range in the number of injections given per year (Table 1). These results highlight how common injections are in current medical treatment, indicating the importance of post-injection complication rates.

The majority of the current literature focuses on the use of corticosteroid injections due to their popularity and lower cost compared to other injection types. However, our survey revealed that a variety of injections are popular in orthopaedic practice, with 60% of respondents using hyaluronic acid, 47% using platelet-rich plasma (PRP), and 46% using corticosteroids (although this only reflects the percentage of respondents that use these types of injections, not the frequency at which each type is used). These findings are different from those reported by Hill et al., who found in 1989 that 90% of respondents used corticosteroid injections in their clinics. This demonstrates a trend away from corticosteroid injections and the introduction of more biologic treatments. This difference also may be due to the fact that although corticosteroids have demonstrated good results in the short term, there is a question with regard to their effectiveness over the intermediate to long term.

Other types of injections reported in our survey were dextrose (prolotherapy), stem cells (including bone-marrow-derived, adipose-derived, and allogeneic stem cells), polidocanol (sclerotherapy), and Botox. It is important to note that with the current regulatory issues surrounding autologous and allogeneic stem-cell injections, there are no clear data on how often they should be used and there is also a need for more rigorous adverse-event recording following injection to ensure an adequate safety and efficacy profile.

Injections per Month	Clinician Response
1–5	56
6–10	57
10–30	67
>30	42
Total	222

Table 01

Injection site

In our survey, the most popular injection site was the knee joint (89% of clinicians), followed by the glenohumeral joint (65%), acromioclavicular joint (45%), and ankle (40%). The hip (27%), as well as a variety of muscles (18%) and ligaments/tendons (27%), were also common injection sites.

The most commonly reported uses for injections included the treatment of OA (80%), subacromial impingement (62%), and tendinopathies (61%) as well as the differentiation of intra- and extra-articular abnormalities (45%). Injections were also used to treat trigger points (33%), ligament and muscle tears (14%), pubalgia (14%), and pain after joint arthroplasty (11%). These findings correspond with the current literature, although injections also have been used for nerve compression, bursitis, ganglion cyst, bone cysts, carpal tunnel, and a variety of musculoskeletal disorders.

Complications

In addition to current injection trends, our survey also asked about the different types of injection complications that clinicians have encountered. Although adverse events following injections have been reported as rare, it is important to be aware of the common complications caused by injections. In the survey conducted by Hill et al., 89% of 233 orthopaedists reported that their patients had experienced some sort of complication following injection. This is similar to our survey, with the vast majority of respondents also reporting post-injection complications. The most common complication was post-injection pain. A list of complications in order of frequency is shown in Table 2, in addition to other common complications reported in the literature.

ISAKOS Survey (listed in order of frequency)
Pain
Tissue atrophy
Fever
Tissue retraction
Joint infection
Aseptic necrosis
Tendon ruptures
Abscess
Other: Allergic reactions, flushing, hydrarthrosis, stiffness
Other common complications in the literature
Skin irritation, ecchymosis, sterile abscess, hypopigmentation, cellulitis, septic bursitis, necrotizing fasciitis, protothecosis, menstrual disturbances, sepsis, skin depigmentation, cartilage damage

Table 02

Corticosteroid injections caused the majority of post-injection complications. In a placebo-controlled study, 51% of patients in the treatment group reported post-injection pain, compared with 31% of those in the placebo group. In another study looking at athletic injuries treated with corticosteroid injections, the most common complications included post-injection pain (9.7%), followed by skin atrophy (2.4%) and skin depigmentation (0.8%).

Gaujoux-Viala et al., in an analysis of 19 studies evaluating post-injection complications associated with corticosteroids, reported that 10.7% of patients experienced pain and that 4% experienced skin atrophy/depigmentation. In a large systematic review of 87 studies, the reported complications following extra-articular injections included pain (3.4% to 81%), skin atrophy (1.5% to 40%), skin depigmentation or discoloration (1.3% to 11.2%), and numbness and tingling (5%). Additionally, in a large systematic review of intra-articular knee injections, it was found that 13% of those treated with corticosteroids experienced side effects, compared with 15% of those who received a placebo injection. These findings lead to the question as to whether complications are a result of the type of injection or the injection itself.

Most of the complications described above are considered minor, with serious adverse events being much more rare. The reported rates of serious complications have ranged from 0% to 5.8%, with many studies not reporting any serious events at all. Very few tendon/ligament ruptures have been reported following corticosteroid injections, although whether such ruptures are due to the injection or disease process is still unknown. Additionally, there have been case reports of necrotizing fasciitis, aseptic and septic arthritis, and nerve damage.

Our survey indicated that hyaluronic acid (HA) injections were second to corticosteroid injections in terms of the frequency of complications. One advantage of HA compared to corticosteroid injection is that the former is believed to have a longer lasting effect of up to several months. In a large systematic review on the use of HA injections for the treatment of joint disease, serious adverse events were small in both number and magnitude of risk, with many studies reporting no serious events at all. In this review of four large cohort studies of 6,000 participants, only one serious event (severe swelling and synovial fluid accumulation) was reported. Additionally, a review of 18 case reports revealed only nine serious adverse events: five cases of sepsis and one case each of saphenous nerve injury, eosinophiluria, erythema, and herpes zoster. With respect to minor complications, pain and swelling were the most common, with reported rates ranging from 1.3% to 47%. Overall it was found that minor adverse events will occur following 1.48% to 2.7% of injections; it should be kept in mind that the risk of complications increases if multiple injections are given to the same patient. One also should note the increasing popularity of hylans, which are a concentrated form of HA. These types of injections have effects similar to those of HA, although they tend to be associated with more local events and have been found to be associated with increased flare ups.

Table 01 Total monthly injections of survey respondents
Table 02 Post-injection complications listed by frequency

Current Trends and Complications Associated with Musculoskeletal Injections

Another popular treatment that was found to be responsible for complications in our survey was platelet-rich plasma (PRP) injections. Compared to corticosteroids and HA, the data on these injections are limited due to small sample size. Patients should be made aware that there is possibility of temporary worsening of symptoms following injection because PRP is likely to stimulate the body's natural inflammatory mediators. Krogh et al. found that PRP injections were associated with significantly more post-injection pain compared with placebo and glucocorticoid injections. However, other studies demonstrated no adverse effects of PRP injections, or very low instances, with 1% of patients reporting post-injection pain.

Practices to reduce post-injection complications are still being investigated. However, it is generally understood that adverse events can be minimized by having well-trained practitioners using appropriate injection procedures. In addition, further comprehensive studies describing injection patterns and adverse event rates are needed. Currently, there is a great interest in using imaging to help guide injections, with 40% of respondents in our survey reporting that they use image guidance. Ultrasound-guided injections have been shown to significantly increase accuracy compared to clinically guided injections. Of imaging techniques, ultrasound seems most practical because it is quick, safe, portable, and gives real-time information. In a systematic review of 13 studies, ultrasound increased the accuracy of intra-articular knee injections from 81% to 96.7% and that of intra-articular shoulder injections from 77.8% to 95.8%. Additionally, ultrasound was associated with a 43% reduction in procedural pain and a 52% reduction in absolute pain at two weeks. However, there is still debate whether these techniques should be adopted due to increased time and cost as well as conflicting clinical data.

Discussion

The purpose of this report was to describe current injection trends as indicated by the findings of a recent survey of ISAKOS members that was administered by the ISAKOS Sports Medicine Committee. Our survey demonstrated that a wide variety of injection types are being utilized within the practice of sport medicine and that these injections are being used for the treatment of a range of pathological conditions involving multiple joints and soft tissues. The most commonly performed injections involve the use of corticosteroids, which also likely reflects the higher complication rates that have been reported in the literature.

An emerging trend towards more biologic injections such as PRP and stem-cell preparations are noted. However, the side-effect profiles of these treatment options are less well documented, and therefore it is important to counsel patients appropriately. Image guidance is also being utilized commonly.

This study was not designed to investigate the effectiveness of current injection treatments in orthopaedics. Furthermore, the nature of the survey design does not provide a robust determination of the incidence of complications associated with each injection type, hence the need to compare our findings with published data. However, it is important that the ISAKOS membership have a general understanding of the different types of post-injection complications seen in orthopaedic practice today. Even though the risks associated with orthopaedic injections are minor, we need to be mindful of the multitude of complications that can arise and be aware of the more serious adverse events that injections may cause. By having an awareness of these issues, we can administer these injections with more confidence and with the hope of achieving better short- and long-term outcomes.

ISAKOS archives

Contribute a piece of History!

isakos.com/Archives

From the history of the International Society of the Knee (ISK) and International Arthroscopy Association (IAA), to the creation and future of ISAKOS—learn more about us through our ISAKOS Archives online!



Brought to you by the ISAKOS Archives Committee

Have something you would like to contribute to the archives?

- Photos
- Videos
- Programs
- Publications
- Antiques (instruments, etc.)

Please send to the ISAKOS Office along with your contact information and submission description.

isakos@isakos.com

2410 Camino Ramon Suite 215

San Ramon, CA 94583 USA

Secondary Restraints to Internal Rotation: The Roles of the Anterolateral Ligament, Iliotibial Band, and Lateral Meniscus



Tim Lording, MBBS, FRACS
Melbourne Orthopaedic Group
Malvern, Victoria, AUSTRALIA

Introduction

Anterior cruciate ligament (ACL) reconstruction is a commonly performed procedure, but isolated intra-articular reconstruction may fail to restore rotational stability to the joint. Residual rotational laxity, which may manifest as the pivot shift, is associated with inferior subjective outcomes.

Recent interest in the anterolateral ligament has refocused attention on the secondary restraints to rotation. In addition to the ACL, the anterolateral ligament (ALL), iliotibial band (ITB), and lateral meniscus all have been shown to restrain internal rotation at the knee.

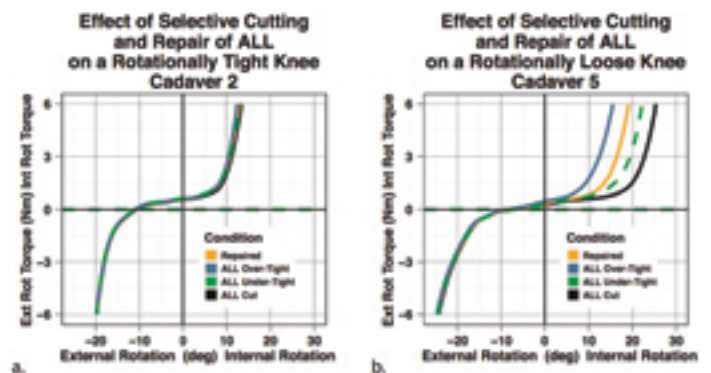
The Anterolateral Ligament

Anatomical and radiological studies over more than a century have described structures connecting the lateral femoral condyle, the lateral meniscus, and the lateral tibial plateau on the anterolateral aspect of the knee. These structures have been described as capsular thickenings, as components of the iliotibial tract, as part of the lateral collateral ligament (LCL), or as ligaments in their own right, and have been variously referred to as the “middle one-third of the lateral capsular ligament,” the “anterolateral femorotibial ligament,” the “capsulo-osseous layer of the iliotibial tract,” the “retrograde tract fibers,” the “anterior oblique band,” and the “lateral femorotibial ligament.” This non-standardized nomenclature, coupled with vague anatomical descriptions, has contributed to ongoing confusion regarding the anatomy of the anterolateral aspect of the knee.

In 2013, Claes and colleagues described the ALL as an extra-capsular structure originating just anterior to the LCL and inserting onto the proximal aspect of the tibia, midway between Gerdy’s tubercle and the fibula head. The structure, which had a strong connection to the body of the lateral meniscus but lacked attachments to the ITB, was identified in 40 of 41 embalmed specimens.

Since that time, additional anatomical studies have furthered our understanding of this structure. While the tibial attachment appears relatively constant, variation has been reported in the femoral attachment. Some authors have described this attachment as being proximal and posterior to the LCL, while others have described an anterior and distal attachment.

A number of authors have now investigated the role of the ALL in rotational control of the knee, with conflicting results. Lording and Branch performed a cadaveric experiment investigating the effect of cutting the ALL and ITB at 30° of flexion. They used a custom robot to replicate the clinical internal-external rotation or dial test while tracking the free-floating tibia in six degrees of freedom. The investigators found that division of the ALL in the ACL-intact knee increased internal rotation at 30° of knee flexion by 2.4°. However, there was wide variation among specimens, with ALL sectioning having no significant effect in one specimen but causing an increase in internal rotation approaching 40% in another specimen (Fig. 1).



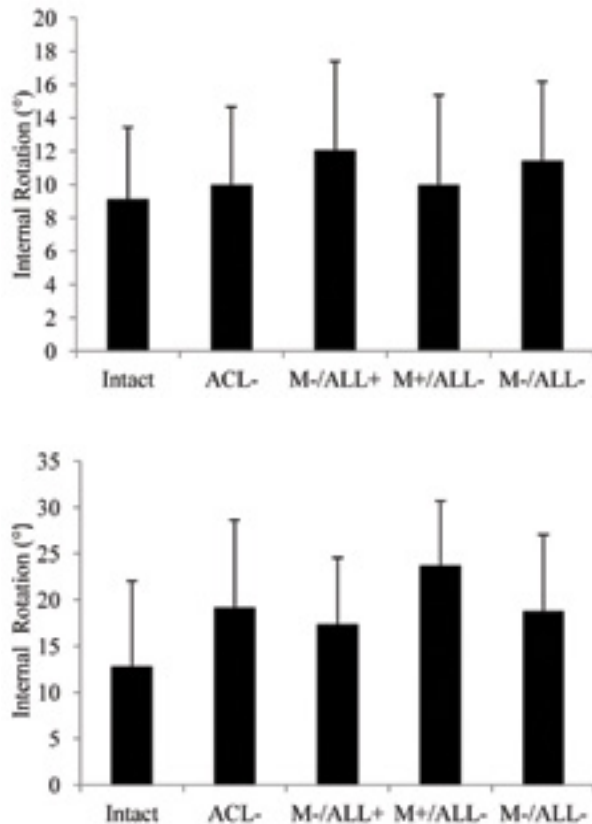
01

Sonnery-Cottet, in a navigation-based study, demonstrated increased internal rotation after division of the ALL in the ACL-deficient knee at 20° and 90°, as well as increased coupled axial rotation during the pivot shift. Parsons, using a six-degrees-of-freedom robotic system, found the ALL to be the primary restraint to internal rotation only at knee flexion angles of greater than 35°, with the ACL providing the greatest restraint closer to extension. Importantly, the ITB was removed from all specimens in this study prior to testing. Consistent with this finding, Lording and Getgood, in a navigation-based study with manually applied forces, found the ALL to play a significant role in internal rotational control only at knee-flexion angles of greater than 30° (Fig. 2).

In contrast, Kittl et al. found that the ALL played no significant role in rotational control. In a robotic experiment involving a six-degrees-of-freedom system, they determined the superficial and deep components of the ITB to be the primary restraints to internal rotation from 30° to 90°.

01 Variation in impact of ALL sectioning on rotation between specimens, with little effect in cadaver 2 (left) and pronounced effect in cadaver 5 (right). Ext rot, External rotation; Int Rot, Internal rotation.

Secondary Restraints to Internal Rotation: The Roles of the Anterolateral Ligament, Iliotibial Band, and Lateral Meniscus The Iliotibial Band



02

The idea that the ITB contributes to rotational control of the knee is not new. In fact, the term “anterolateral ligament” was probably first used by Kaplan in his 1958 morphological study of the iliotibial tract.

Anatomically, the insertion of the ITB onto the lateral aspect of the distal part of the femur, known as Kaplan’s fibres, has been shown to be a true tendon enthesis. This could be considered to divide the ITB into a proximal, tendinous part, and a distal, ligamentous part that could provide a static restraint to internal rotation.

A number of biomechanical studies have supported a role for the ITB in the control of internal rotation. Lording and Branch measured an increase in internal rotation of 2.6° in the ACL-intact knee at 30° after division of the ITB at Gerdy’s tubercle (Fig. 3). This increase was similar in magnitude to that noted after division of the ALL (2.4°), but with less variability between specimens.

As previously mentioned, Kittl et al. found the superficial and deeper layers of the ITB to be the most important stabilizers of internal rotation, with the superficial layer more important at deeper flexion angles and the deep layer especially important between extension and 30° of flexion in the ACL-deficient knee. In that study, the superficial and deeper layers of the ITB were also the primary restraints to the pivot shift. In Sonnery-Cottet’s study, division of the ITB in the ACL-intact knee caused a significant increase in internal rotation at 20° of flexion and of coupled axial rotation during the pivot shift. Sectioning of the ITB after the ACL and ALL also caused increased internal rotation at 20°, 90°, and during the pivot shift. In addition to these biomechanical findings, there is evidence of ITB injury occurring in association with ACL injury and contributing to the reported spectrum of instability. Intraoperatively, injury to the deep and capsulo-osseous layers has been observed in association with in 84% and 71% of ACL ruptures, respectively, with injury to these structures correlating with the pivot-shift findings. Most of these injuries occurred at the femoral insertion.

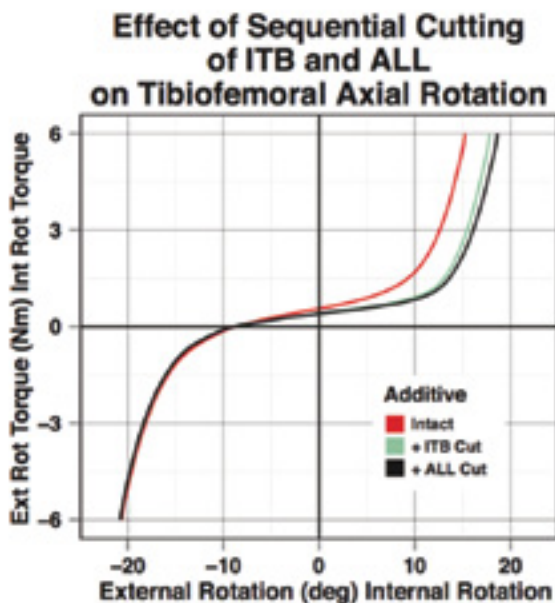
The Menisci

The role of the medial meniscus as a secondary stabilizer to anterior translation is well documented. More recently, the lateral meniscus has been implicated in the control of rotation.

Musahl examined the effect of medial and lateral meniscectomy in the ACL-deficient knee using navigation and a mechanized “pivot shifter.” Medial meniscectomy significantly increased anterior tibial translation during the Lachman test but did not increase lateral-compartment translation during the pivot-shift test. Lateral meniscectomy, on the other hand, caused a significant increase in lateral-compartment translation during the pivot-shift test but had no effect during the Lachman test.

Injuries to the posterior root of the lateral meniscus have a similar effect on rotational stability. Shybut investigated the impact of tears of the posterior root of the lateral meniscus on stability in the ACL- deficient knee. Using an infrared motion-analysis system, loss of the meniscal root was shown to increase lateral-compartment translation during the pivot-shift test. Lording and Getgood examined the role of the ALL and posterior lateral meniscal root on internal rotation in the ACL-deficient knee. Loss of the meniscal root increased internal rotation in extension and at knee flexion angles under 30° (Fig. 3).

02 Internal rotation in extension (top) and at 45° of flexion (bottom). In extension loss of the lateral meniscal posterior root causes an increase in internal rotation, while at 45° loss of the ALL is more important. ACL-, ACL deficient state; M-/ALL+, meniscal root sectioned with ALL intact; M+/ALL-, meniscal root intact, ALL sectioned; M-/ALL-, both meniscal root and ALL sectioned.



03

Discussion

The ALL, ITB, and lateral meniscus all contribute to the restraint of anterolateral rotatory instability at the knee. Biomechanical studies have suggested that the contributions of these structures are dependent on the knee-flexion angle, with the lateral meniscus being more important near extension and the ALL exerting greater control at deeper flexion angles.

The indications for surgical management for the anterolateral extra-articular structures have yet to be fully determined. The results of intra-articular reconstruction are satisfactory for most patients, and, as such, extra-articular reconstruction should be reserved for those most likely to benefit from the additional intervention. This group may include those at higher risk of failure, such as younger patients, those returning to pivoting sports, and those undergoing revision procedures. The degree of clinical laxity also has been proposed as an indication; however, it seems likely that the severity of this laxity reflects the pattern and degree of injury to the secondary stabilizers.

The ideal lateral extra-articular procedure is unclear. ALL reconstruction is an attractive option due to its anatomical nature. However, biomechanical studies suggest the native ALL is important only at deeper flexion angles, and, as such, anatomical ALL reconstruction may not control the pivot shift. More traditional ITB-based reconstructions, such as a modified Lemaire procedure, may be more isometric and superior in terms of functional rotational control.

Tears involving the posterior root of the lateral meniscus have been reported in up to 12% of knees with ACL injuries. In addition to their effect on stability, injuries to the meniscal roots have biomechanical consequences similar to total meniscectomy and may lead to meniscal extrusion and progressive chondral degeneration. These effects may be mitigated to a degree in the lateral compartment by the presence of intact meniscofemoral ligaments. Biomechanical studies of transosseous repair techniques for lateral root tears have shown a reduction in contact pressures to near-normal levels compared to the injured state, and clinical studies have shown encouraging results.

The lateral meniscal root should be carefully inspected for injury during ACL reconstruction, with repair of these lesions being performed when possible. Such a repair has two potential benefits: improved rotational control and long-term maintenance of the chondroprotective function of the meniscus.

Conclusion

The ALL, ITB, and lateral meniscus all contribute to the restraint of anterolateral rotatory instability at the knee. Injury to these secondary stabilizers contribute to the spectrum of instability seen with ACL injury, and surgery should aim to address these lesions where appropriate. While the indications and ideal technique for anterolateral extra-articular procedures are yet to be fully determined, repair of lateral meniscal root injuries has potential benefits for both knee stability and chondral protection and should be undertaken when possible.

03 Sequential cutting of the ITB and ALL at 30° of knee flexion increased internal rotation by 2.6° and 3.4°, respectively.

Scapholunate Ligament Injuries

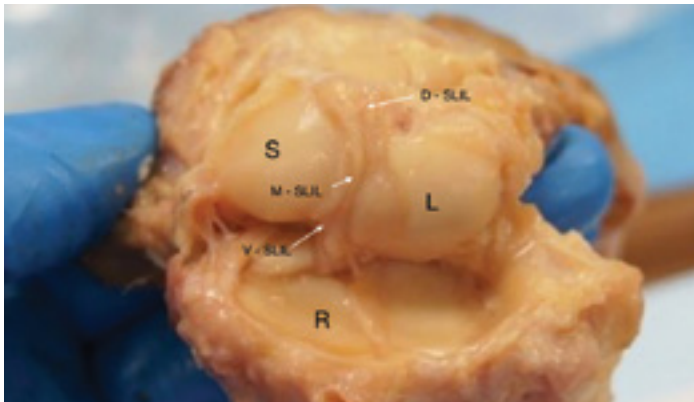


Margaret Woon Man Fok,
FRCS(ortho), MBChB (Otago)
Queen Mary Hospital,
The University of Hong Kong,
HONG KONG

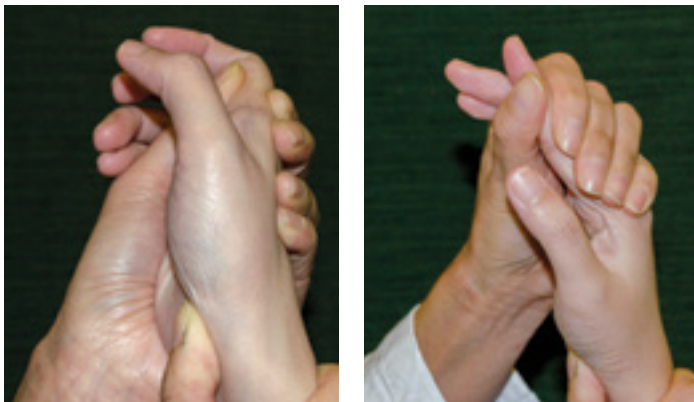Additional Author:
Gregory Bain, Flinders University and Flinders Medical
Centre, Adelaide, AUSTRALIA

Elbow Wrist and Hand Committee, ISAKOS

Scapholunate (SL) dissociation is the most common wrist ligament injury that occurs during sporting activities. It is a result of an injury of the scapholunate interosseous ligament (SLIL) and usually is caused by a fall onto an outstretched hand. It can occur as an isolated injury or as a part of a perilunate injury, a carpal dislocation, or a distal radial fracture.



01

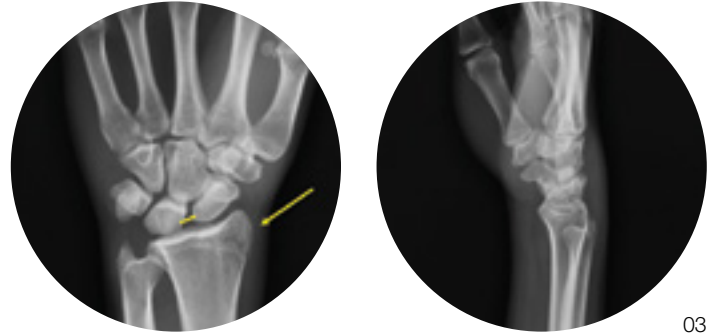


02

Anatomy (Fig. 1)

The SLIL is made up of three distinct parts. The dorsal ligament is thick and prevents diastasis of the scapholunate interval. The palmar ligament is thinner and maintains rotational stability. The membrane part is fibrocartilaginous but does not contribute significantly to stability.

There are secondary stabilizers, which include the STT, scaphocapitate, and dorsal intercarpal ligaments. An injury to the SLIL and the secondary stabilizers will lead to clinical instability.

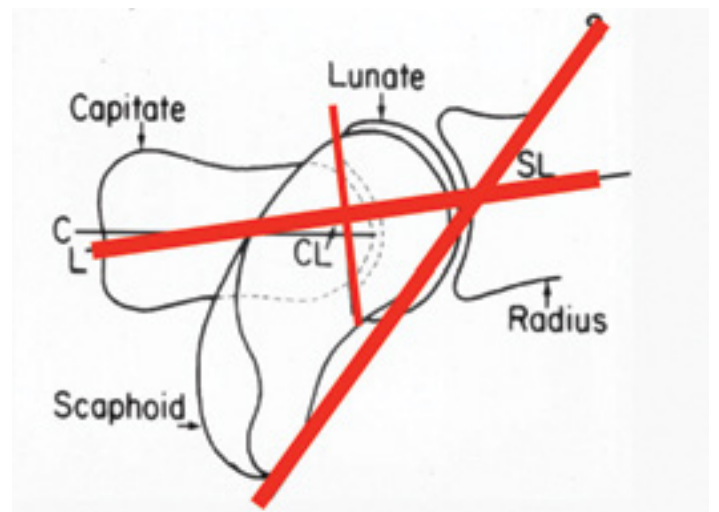


03

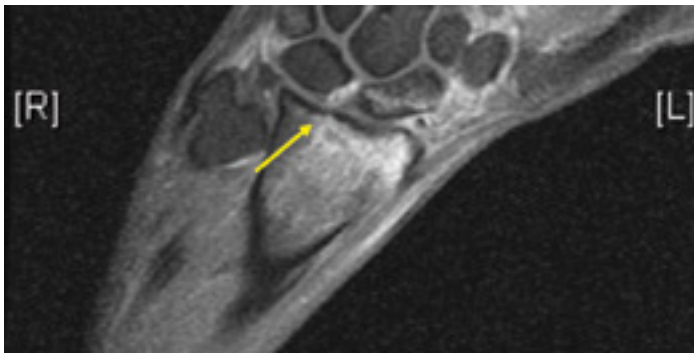
Clinical Presentations

The patient usually will present with a history of a fall onto an outstretched hand, with localized pain and swelling on the dorsal aspect of the wrist. The patient may describe weakness with activities and mechanical symptoms such as clicking or locking of the wrist.

An isolated SLIL injury is associated with swelling and tenderness over the SL interval just distal to the Lister tubercle. There is usually pain with loading the wrist and a positive SL ballottement or Watson scaphoid shift test (Fig. 2).



04



05

Imaging

Plain radiographs

A wrist injury should initially be evaluated with standard PA and lateral radiographs. A scapholunate gap of >3 mm is usually indicative of SL instability.

For the younger individual, it is worth evaluating a comparative radiograph of the contralateral wrist as it may reveal normal findings. It is important to identify any associated injuries such as a perilunate dislocation, scaphoid fracture, or distal radial fracture (Fig. 3).

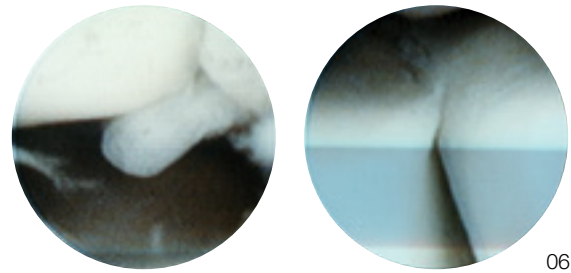
Carpal alignment can be assessed on a true lateral radiograph (Fig. 4). The scapholunate angle (SLA) is measured between a line drawn perpendicular to the distal cusps of the lunate and a line drawn along the volar aspect of the scaphoid. SL dissociation should be suspected if the scapholunate angle is greater than the normal value of 45° to 60° .

The radiolunate angle (RLA) is measured between a line drawn along the radius and a line drawn perpendicular to the distal cusps of the lunate. Dorsal intercalated segment instability (DISI deformity) is present if the RLA is $>15^\circ$.

If the radiographic findings are unremarkable but SL instability is still suspected, stress views may unmask dynamic SL instability. A clenched-fist PA radiograph demonstrating an SL gap of >3 mm will indicate dynamic SL instability.

Magnetic resonance imaging (MRI) (Fig. 5)

MRI is used to assess the SLIL and to identify diastasis and associated chondral changes. However, it may not provide added information if SL dissociation can be diagnosed on plain radiographs, especially in the acute setting. With the advances of modern technology, including using dedicated wrist coils with a 3T magnet, the sensitivity of diagnosing SL dissociation has been reported to be up to 89%. With these new methods plain MRI is comparable to magnetic resonance arthrography (MRA).

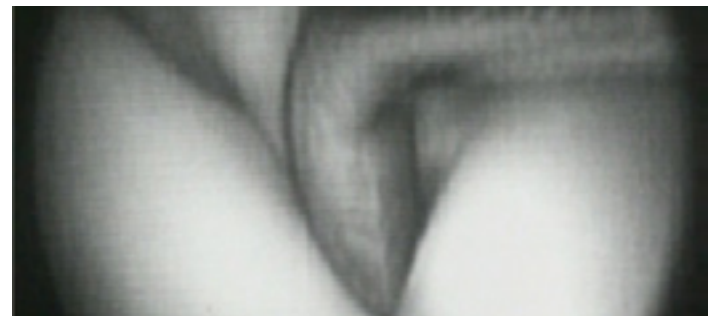

06

Arthroscopy

Wrist arthroscopy is regarded as the gold standard for diagnosis of SL dissociation. It provides direct visualization of the ligament and can be used to assess the extent of the ligament injury and whether the ligamentous stump is repairable. In addition, provocation of the scapholunate instability can be created by the surgeon's thumb pushing on the volar scaphoid tubercle while visualizing the SL ligament. This stresses the SLIL, which can unmask a SLIL tear and/or produce to abnormal widening of the SL interval. The associated articular degenerative changes that occur on the radial styloid can also be identified (Fig. 6).

From the midcarpal joint, the degree of laxity between the SL interval can be assessed. Geissler et al., described a classification for assessment of SL instability, based on the ability of the SL joint to admit the probe (Fig. 7) (Table 1). This reflects the functional significance of the ligament injury as we can determine the presence of a tear with or without associated significant instability.



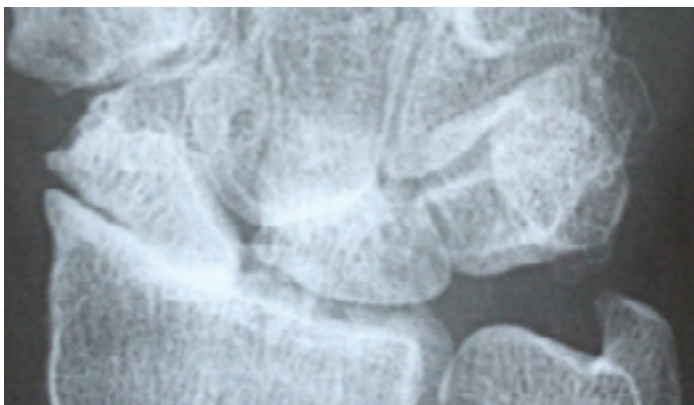
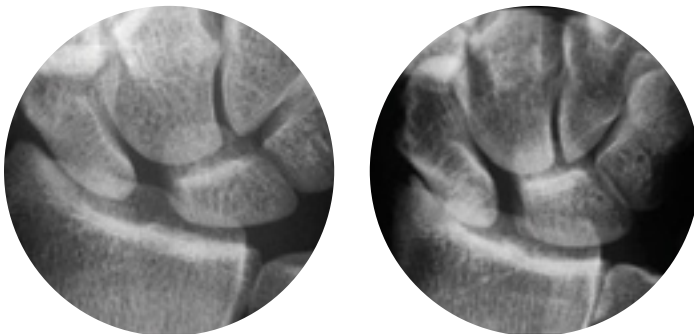07

- 01 Anatomy of scapholunate ligament. S = scaphoid, L = lunate, R = radius, D-SLIL = dorsal SLIL, M-SLIL = membranous SLIL, V-SLIL = palmar SLIL
- 02 Watson shift test.
Firm pressure is applied to the palmar tuberosity of the scaphoid with wrist in ulnar deviation (top). When the wrist is moved in radial deviation in a patient with SL dissociation, the scaphoid will more dorsally under the posterior margin of the radius, inducing pain (bottom).
- 03 PA radiograph of the wrist, showing an increase in SL gap and an associated radial styloid fracture.
- 04 Lateral radiograph of the wrist, showing how the scapholunate angle (SLA) and the radiolunate angle (RLA) are measured.
- 05 MRI scan showing an SL tear.
- 06 Wrist arthroscopy showing SL tear via the radiocarpal joint (top) and via the midcarpal joint (bottom).
- 07 Wrist arthroscopy illustrating the admittance of a probe into the SL joint.

Scapholunate Ligament Injuries

Grade	Description
I	Attenuation/haemorrhage of SLIL (viewed from radiocarpal space). No midcarpal malalignment
II	Attenuation/haemorrhage of SLIL (viewed from radiocarpal space) AND step off/incongruity of carpal alignment. Slight gap between carpals (less than width of 5-mm probe)
III	Step off/incongruity of carpal alignment (viewed from both radiocarpal and midcarpal space) AND SL gap large enough to pass probe between carpals
IV	Step off/incongruity of carpal alignment (viewed from both radiocarpal and midcarpal space), gross instability, AND 2.7-mm arthroscope can pass through the gap between the scaphoid and lunate (positive “drive-through sign”)

Table 01



08

Principles of Management

The current literature includes a wide variety of proposed treatment options for SL dissociation. Garcia-Elias proposed a set of six questions as a useful framework for developing stage-based treatment algorithms.

- 1 Is the dorsal part of SLIL intact?
- 2 Is SLIL repairable? Does it have a good chance of healing if being repaired?
- 3 Is the radioscapoid angle normal?
- 4 Is the lunate uncovering index normal?
- 5 Is the malalignment easily reducible?
- 6 Is the cartilage around the wrist intact?

This in turn generates seven stages of SLIL injury, a scale that indicate the severity of SL dissociation.

- I Partial rupture of SLIL
- II Complete rupture of SLIL with repairable ligament
- III Complete rupture of SLIL with irreparable ligament but normal alignment
- IV Complete rupture of SLIL with irreparable ligament, reducible rotatory subluxation of the scaphoid, and normal lunate alignment
- V Complete rupture of SLIL with reducible rotatory subluxation of the scaphoid and reducible ulnar translocation of lunate
- VI Complete SLIL with irreducible malalignment but intact cartilage
- VII The presence of scapholunate-advanced collapse (SLAC)

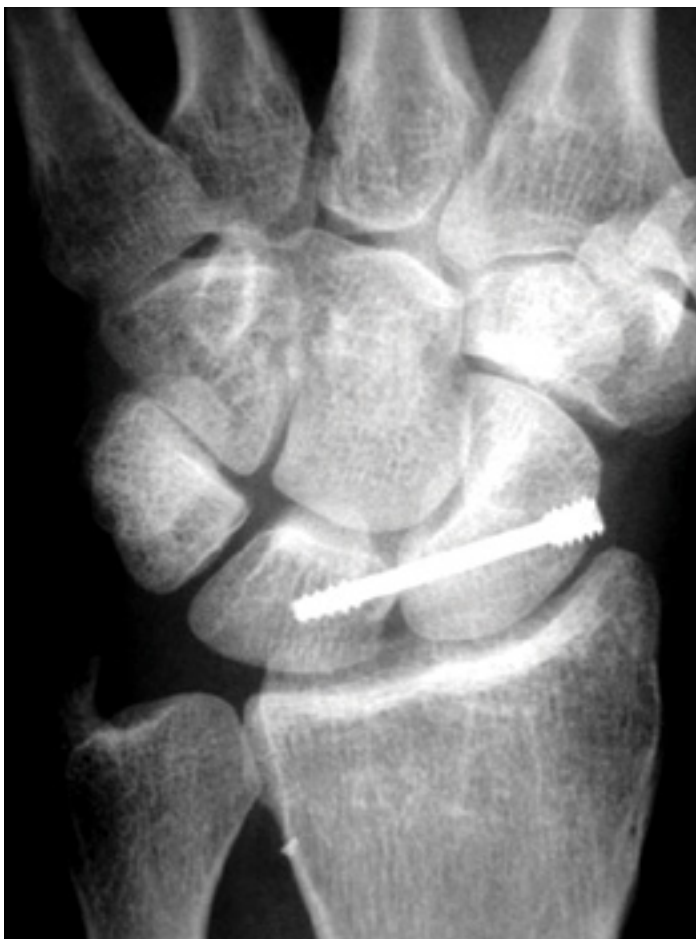While we can determine the treatment options based on the stages of the SL dissociation, it is important to note that we need to take into account demographic characteristics such as the patient’s age, occupation, recreational demands, and level of symptoms. Further research is required to obtain a better understanding of the natural history of SL dissociation (Fig. 8).

Mildly symptomatic patients – a wrist splint, activity modification and wrist exercise can be offered (Fig. 9).

For symptomatic and high-demand patients, surgical treatment can be considered. This usually involves an arthroscopic assessment and proceeding to definite care depending upon the finding as outlined above.



09

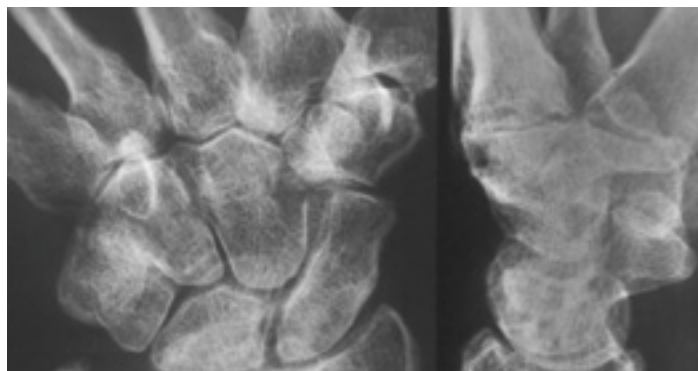


10

Partial SLIL injuries (Stage I). Arthroscopic debridement is the treatment of choice for partial SLIL injuries, in which the dorsal aspect of the SLIL remains intact. Debridement may be augmented by K-wire fixation or splint immobilization. Once the wrist is stabilized, proprioception exercises for the extensor carpi radialis longus (ECRL), abductor pollicis longus (APL), and flexor carpi radialis (FCR) muscles should be commenced to provide dynamic support to the SLIL.

Complete but repairable SLIL tears (Stage II). Either open or arthroscopic repair is recommended for complete but repairable SLIL tears. The repair should be augmented with percutaneous SL joint fixation in order to off-load the ligament while it heals. Percutaneous fixation can be achieved with either K wires or temporary SL screws, as advocated by Herbert.

Irreparable SLIL tears in patients with intact or reducible radiocarpal alignment (Stages III, IV, and IV). Carpal instability must be reduced before reconstruction of the SLIL is performed. Many different techniques have been proposed, including bone-ligament-bone reconstruction and tenodesis involving the extensor carpi radialis brevis (ECRB), FCR, and ECRL. While each technique has its advocates, it is not uncommon to observe a loss of reduction at follow-up.



11

Therefore, a temporary SL screw instead of percutaneous K-wires is proposed (Fig. 10). The SL screw should be removed once loosening is observed on radiographs (Fig. 11) as the screw may pull out or break.

Irreducible malalignment without the arthritis (Stage VI). In this situation, there is scarring and contracture of the SLIL and secondary stabilizers, so the results of a ligament repair and tenodesis are poor. Therefore, a motion-preserving salvage procedure is required, such as a limited wrist fusion (midcarpal or radioscapholunate [RSL] fusion or proximal row carpectomy) (Fig. 12).

Scapholunate-advanced collapse (SLAC) wrist (Stage VII). This injury requires a midcarpal fusion.

Conclusion

There have been advances in the understanding of anatomy, biomechanics, and imaging of the wrist in recent years. With a greater awareness of the common wrist injuries, early diagnosis, and appropriate treatment, good clinical outcomes can be achieved.



12

Table 01	Geissler arthroscopic grading system.
08	Radiographs demonstrating the natural progression of SLAC wrist, with degeneration over the radial styloid (top left) and then the midcarpal joint (top right and bottom)
09	Wrist splint.
10	Radiograph showing the scapholunate screw in place after debridement.
11	Radiographs, made four years after repair, following removal of the SL screw.
12	Radiograph showing midcarpal fusion involving the lunate, capitate, and hamate.

The ISAKOS Young Investigator's Research Mentoring Fellowship Report



Deepak N. Bhatia,
MS(Orth), DNB(Orth)
*Seth GS Medical College,
and King Edward VII
Memorial Hospital
Mumbai, INDIA*

The ISAKOS Young Investigator's Scholarship and Research Mentoring Program was initiated in 2015. I was awarded the first part of the fellowship to attend the ISAKOS conference in Lyon, France. The ISAKOS Scientific Committee provided valuable research mentoring at the ISAKOS conference, and the fellows were subsequently invited to submit a research proposal for further mentoring. In April 2016, I was delighted to hear that I had been selected to receive a research grant to support a two-week research fellowship with a mentor of my choice. Professor Gregory Bain (Flinders University, Adelaide, Australia) had earlier expressed his interest in my ongoing research on an "all-endoscopic distal biceps repair" technique, and I instantly opted to do my research fellowship with him.

I visited Professor Greg Bain for a two-week period in November 2016. I reached Adelaide on a weekend and was looking forward to beginning the fellowship the following week. Greg, on the other hand, was keen to begin right away; we arranged a meeting over the weekend to plan the course of the fellowship, and the work that had to be done was charted. Thereafter, Greg invited me to attend a tour of the Adelaide Oval, an iconic cricket stadium, and I was impressed with Greg's in-depth knowledge of the game and its rich history.

The following week, I attended the outpatient clinics and operating sessions with Greg at the various hospitals in Adelaide. We discussed the clinical aspects of a wide range of shoulder and elbow problems, and Greg demonstrated his innovative surgical techniques in upper-limb surgery. I was introduced to the concept of "dry arthroscopy," and it was interesting to watch Greg perform reconstructive shoulder surgery using only air as an insufflation medium.

Other interesting surgeries were the "cable-augmented, quad ligament tenodesis" for scapholunate reconstruction and a reconstructive procedure for chronic extensor tendon subluxation. Toward the end of the week, Greg arranged a visit to a cadaver and biomechanics lab at Flinders University, and we spent time discussing research methodology to further evolve and test newer techniques.

The following week was spent completing a collaborative project on endoscopic distal biceps repair techniques. We discussed and compared our respective techniques of distal biceps repair: Greg's technique of endoscopic-assisted footprint repair of distal biceps ruptures was advantageous from a biomechanical point of view, whereas my technique of all-endoscopic repair was performed entirely endoscopically via new portals. The discussions led to completion of a review paper on distal biceps repair techniques, and the review will be included as a chapter in an upcoming ISAKOS book on cutting-edge elbow surgery.

Overall, the ISAKOS Young Investigator's fellowship provided me with a rare opportunity to be mentored by an exceptional researcher and surgeon. I am thankful to Professor Gregory Bain, not only for the mentorship, but also for being a wonderful host and friend. I am grateful to Professor Volker Musahl, (Chair, ISAKOS Scientific Committee) for guiding me throughout this process, and I thank ISAKOS for the support towards this exceptional experience.



01

01 Prof. Greg Bain (right) and Dr. Deepak Bhatia (left) at the cadaveric lab at Flinders University.

ISAKOS Young Investigator's Scholarship and Research Mentoring Program – 2016

Tiago Lazzaretti Fernandes, MD, MSc, PhD
*Department of Orthopaedics and Traumatology,
 University of São Paulo Medical School
 São Paulo, BRAZIL*

Introduction

The ISAKOS Young Investigator's Scholarship and Research Mentoring Program gave me the opportunity to improve my arthroscopic and knee surgery knowledge related to ACL reconstruction as well as cartilage and meniscal treatment. The ISAKOS Young Investigator's Scholarship and Research Mentoring Program gave me the opportunity to improve my arthroscopic and knee surgery knowledge related to ACL reconstruction as well as cartilage and meniscal treatment. It also has provided a unique opportunity to share my new knowledge and experiences with colleagues, orthopaedic residents, and sports medicine fellows in my own country as well.

At the first part of ISAKOS Young Investigator's Scholarship and Research Mentoring Program, at the Biennial ISAKOS Congress in Lyon, France, I had the chance to present my work and research proposal to the selection committee of the ISAKOS Scientific Board and listen to some suggestions on how to increase the quality of my research proposal.

During the second part of the program, I was able to accomplish all of my personal, professional, and institutional objectives and achieved substantial improvements in both my surgical and research skills.

I'd like to thank the ISAKOS Scientific Committee for the honor of being selected as one of the finalists of the Young Investigator's Scholarship as well as being selected for the Research Mentoring Program. In the next pages, I describe my academic daily activities, including clinical case discussions, operating room activities, and laboratory research, and various conferences and meetings.

Personal Background

I serve as orthopaedic assistant at the Sports Medicine Group in the Institute of Orthopedics and Traumatology at the University of São Paulo Medical School. The Sports Medicine Group is also an ISAKOS Teaching Center and FIFA Medical Centre of Excellence.



In 2015, I finished my PhD fellowship in the Bioengineering Laboratory of the Department of Orthopaedic Surgery at Massachusetts General Hospital-Harvard Medical School, Boston, coordinated by Dr. Guoan Li.

Osaka University

My main activities during the program took place at the University of Osaka, which has assistance, translational, and basic research facilities.

Chairman

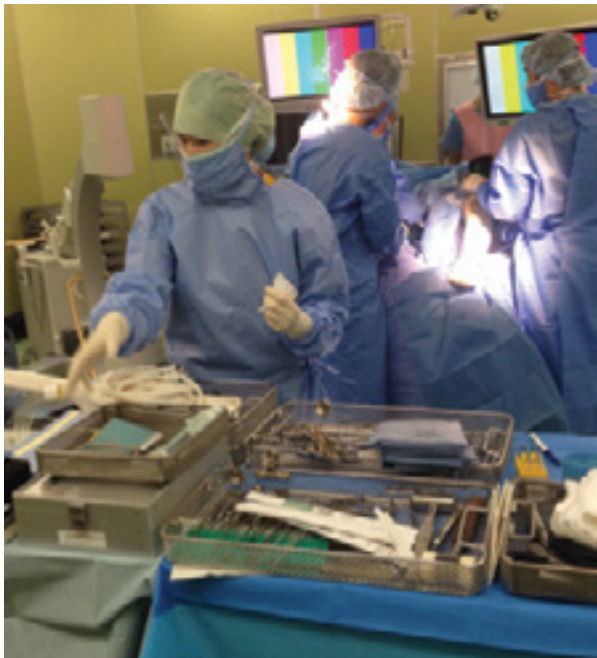Professor Norimasa Nakamura, Invited Professor of the Department of Orthopaedic Surgery and Professor of the Center for the Advanced Medical Engineering and Informatics at Osaka University, was responsible for my activities during this fellowship and mentoring program in Osaka University from August 22 to September 13, 2016.



ISAKOS Young Investigator's Scholarship and Research Mentoring Program – 2016

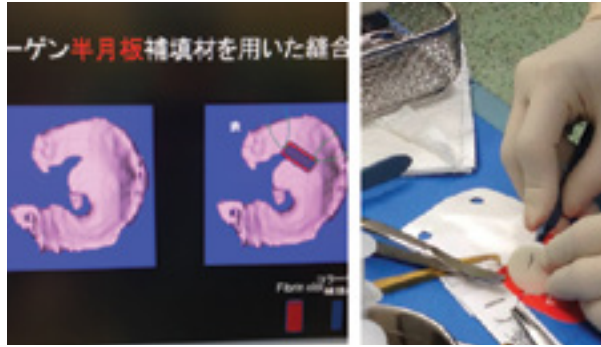
Tiago Lazzaretti Fernandes, MD, MSc, PhD

Every Monday morning during the program, I participated in a discussion of past and present surgical procedures at the Orthopaedic Department of Osaka University. Inpatient visits were conducted after the surgical meeting. Rehabilitation protocols for ACL reconstruction, MPFL reconstruction, and cartilage and meniscal treatments were discussed as well.



On Thursdays, I visited the translational research facilities Osaka University, including the new building housing the Center of Medical Innovation and Translational Research, next to Osaka University Hospital. Surgical procedures at Osaka University occurred throughout the entire day on Thursdays as well as during some extra periods during the week.

Tuesdays, Wednesdays, and Fridays were dedicated to research activities, including literature review, hands-on laboratory work, design of a research protocol, and manuscript writing. Wednesday evenings were dedicated to scientific discussions between Dr. Norimasa Nakamura's fellows and me about each week's research progress.



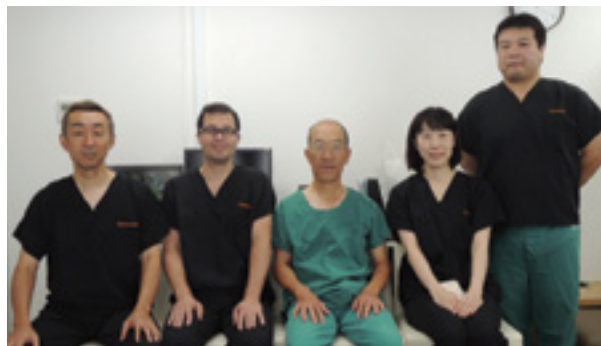Surgical procedures

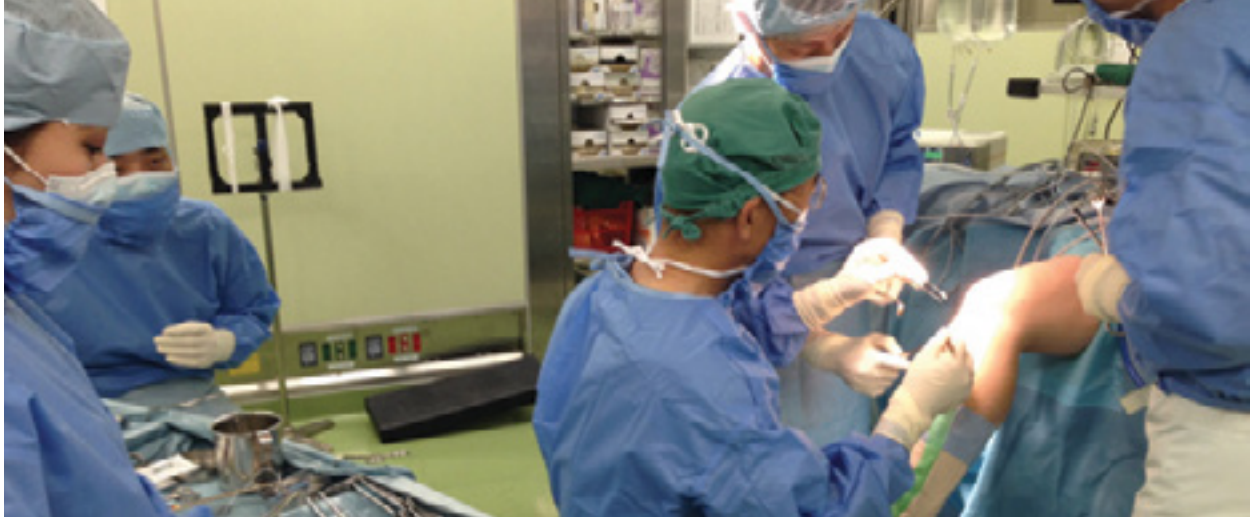I had the opportunity to be observe surgical procedures performed by many professors and doctors from Osaka University, including Professor Norimasa Nakamura, Professor Ken Nakata, and Dr. Kazunori Shimomura.

Dr. Nakamura performed an anatomic double-bundle ACL reconstruction with semitendinosus graft in a female soccer player; a double-bundle reconstruction was chosen over triple-bundle reconstruction because of the short height of the patient and the size of the intercondylar notch. Anteromedial and posterolateral anatomic tunnel positions were defined after meticulous debridement of the ACL footprint in the femur and tibia. After adequate tensioning, the ACL graft was fixed with 20 N of tension as measured with a dynamometer for each tunnel.

At Osaka University Hospital, Prof. Ken Nakata, as part of a clinical trial, performed meniscal repair with use of a bioengineered collagen scaffold involved with fibrin clot. He also executed a posterior root repair with a transosseous fixation.

Another week, Dr. Kazunori Shimomura, orthopaedic assistant at Osaka University Hospital, performed a triple-bundle ACL reconstruction along with meniscal suture repair in a basketball player.





For the anatomic triple-bundle ACL reconstruction, three tunnels were drilled into the tibial ACL footprint, representing the anteromedial, intermediate, and posterolateral bundles. Two tunnels were drilled in the femur: the intermediate and anteromedial bundles had their origins in the anteromedial tunnel, whereas the posterolateral bundle had its origin in the corresponding posterolateral tunnel.

The meniscal suturing procedure was performed with a new outside-in meniscal kit developed at Osaka University. This kit consists of five separate stitches with two 6-cm needles that can be easily pulled out from the outside of the capsule, permitting an accurate selection of meniscal portion to be sutured.

At Yukioka Hospital, I had the opportunity to observe surgical procedures performed by the ISAKOS past-president Professor Konsei Shino, who is admired among all Japanese orthopaedic surgeons. Professor Shino performed two ACL reconstructions with rectangular bone-patellar tendon-bone (BPTB) graft (which he advocates as the gold standard), a procedure that he recently described in the literature.

Professor Shino explained that tunnel dilators or expanders with rectangular shape should be inserted gently so as to not fracture posterior cortical bone. After graft fixation with a metallic interference screw in the femur, Professor Shino uses a metallic boot with a dynamometer attached to apply 20 N tension to the graft.

Meetings and conferences

I had the opportunity to participate in two scientific conferences in Japan. Due to my attendance, speakers were advised to write presentations in English so that I could understand.

The first meeting, held on September 2 at Osaka University Nakanoshima Center, was the 17th Locomotor Science Meeting. Classes were related to basic science as applied to cartilage, bone, tendon, and muscles injuries. One of the classes on cartilage repair was taught by Dr. Yausutoshi Ikeda, a student of Professor Nakamura. This class focused on new knowledge related to recombinant IGF-1 gene overexpression on mesenchymal stem-cell (MSC) scaffold-free constructs, showing better results of cartilage repair on IGF-1 overexpression group.

The second conference that I attended was The 37th Osaka Sports, Arthroscopy, Knee Surgery Study Meeting (OSAK), held on September 3 in Kobe, Japan. There, I listened to talks on the latest research and literature reviews related to pathological conditions involving the knee. Medial patellofemoral ligament reconstruction, ACL reconstruction, and meniscal and cartilage treatments were also discussed. At this meeting, I also had the opportunity to present the ISAKOS Young Investigator's Scholarship and Research Mentoring Program Award to the selected audience.

Interaction with other colleagues in Japan

Dr. Wataru Ando, from the Department of Orthopaedic Surgery at Kansai Rosai Hospital, is an orthopaedic researcher who completed a fellowship program with Professor David A. Hart at McCaig Institute for Bone and Joint Health in Calgary, Canada. I had the chance to listen to Dr. Ando describe his research experience related to MSCs and cartilage and about new advances in cartilage repair.

ISAKOS Young Investigator's Scholarship and Research Mentoring Program – 2016

Tiago Lazzaretti Fernandes, MD, MSc, PhD

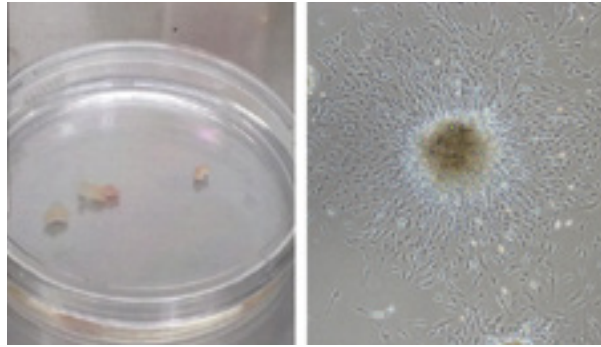
Prof. Fujie, who works at Tokyo Metropolitan University, was one of the first engineers to specialize in knee biomechanics at the University of Pittsburg with Dr. Freddie Fu. Actually, he was at Pittsburg before Dr. Guoan Li, who is the chief of the Bioengineering Laboratory at Mass General Hospital, where I did the analysis for my PhD program.

Translational research

Professor Norimasa Nakamura and his fellows gave me full support to learn and reproduce laboratory techniques of harvesting and expanding MSCs. I'd like to thank all fellows who helped me in the Osaka University research laboratory, including Dr. Kazunori Shimomura, Dr. Shoichi Shimomura, Dr. Shuichi Hamamoto, and Dr. Yausutoshi Ikeda. Despite the fact that we could count on technicians to perform the laboratory procedures, I was interested in learning these techniques myself in order to be able to replicate them and teach them to other students during collaborative research.

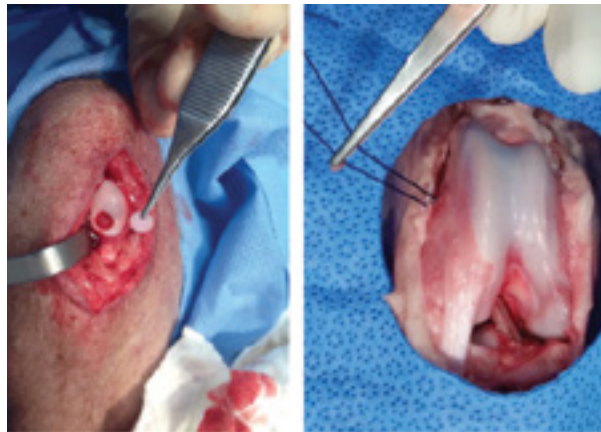


Human MSCs were harvested from synovial membrane following an arthroscopic procedure. After harvesting some synovial fragments, extracellular matrix was digested and MSCs were separated. Many human MSCs could be identified after a few weeks in a well dish with synovial remnants.



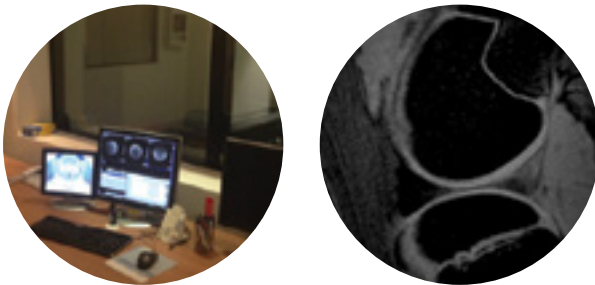
I also had the chance to learn about Tissue Engineered Construct (TEC), which is a three-dimensional (3D) scaffold-free tissue composed of MSCs and type-I and III collagen that is being investigated for the treatment of cartilage defects in translational research. After medium exchange for 15 days, we had a sufficient number of cells to prepare TEC. TEC also needed 10 to 15 days to get ready to be detached to form the 3D construct, that has adhesive properties to the well dish and also biological materials.

In addition, Professor Nakamura and Dr. Kazunori Shimomura provided me with an orientation regarding macroscopic, microscopic, and biomechanical cartilage evaluation in translational large-animal models. Their assistance contributed to write a manuscript about a Brazilian miniature pig model for the investigation of stem-cell treatment of cartilage lesions after ACL reconstruction.



Research Proposal

Going forward, it is hoped that this collaborative program will contribute to in vitro and in vivo studies to confirm the chondrogenic properties and paracrine effects of dental pulp stem cells (DPSCs) in cartilage repair. Biomechanical cartilage tests and investigations of some microscopic markers will be performed in collaboration with Osaka University Hospital. The paracrine effects of DPSCs will be studied in the large-animal facility (miniature-pig) and analyzed with 7 Tesla MRI. In addition, a clinical trial involving patients has been proposed to investigate cartilage treatment with the most suitable MSC construct.



Social Program

I'm thankful for the kindness of all of my Japanese friends, with whom I shared great moments to be remembered and cherished. During the weekend at



the end of my fellowship, a visit to some Japanese cities and sites (including Osaka Station in the Umeda neighborhood and Osaka Castle) allowed me to learn a bit about their ancient history culture, with its mixture of tradition and modernity.

Acknowledgements

I would like to thank the ISAKOS Scientific Committee for this great proposal of sharing knowledge and continuing the improvement of knee, sports, and arthroscopic research, in which I may collaborate in future. I cannot forget to thank all of the staff at my Orthopedic Department in the University of São Paulo Medical School. In addition, I would like to say a special thank you to Professor Norimasa Nakamura and his fellows, all of whom are outstanding friends, physicians, and researchers. Finally, I would like to thank my family (my wife Sabrina and my sons João and Antonio) for all of their support and understanding during my participation this important fellowship.

ISAKOS PUBLICATIONS

Full Access in myISAKOS

ISAKOS Members can access all official ISAKOS Publications through myPublications in myISAKOS—including *Journal of ISAKOS*!



www.isakos.com/myISAKOS

ISAKOS Teaching Centre Scholar Report

**Manit Arora, MBBS, MSOrtho, MSportsMed
Chandigarh, INDIA**


Professor Greg Bain

*Flinders University and Flinders Medical Center
Adelaide, AUSTRALIA*

First, I would like to thank ISAKOS for giving me this wonderful opportunity to attend a teaching center of excellence. I also would like to thank Prof. Greg Bain, who is a wonderful human being and a gracious host. I visited Prof. Bain to learn more about upper-limb surgery at Flinders University and Flinders Medical Center, Adelaide, Australia.

It was an amazing experience to see a master at work. During my visit, I learned about many new things to which I had not had been previously exposed, including arthroscopic-assisted distal radial fixation, arthroscopic scapholunate pinning, and reverse shoulder arthroplasty. It was excellent to see the setup of the OR, to observe dissections, and to learn some pearls of wisdom.

Prof. Bain also showed me the many books and chapters he had written, and it was good to see his book on upper-limb surgical anatomy, which includes some neat information (such as the exact insertion points of the coracoclavicular ligaments on the clavicle) that will come in useful as I plan my own upper-limb procedures.



01

Apart from the academic stimulation, Adelaide is a very nice small city. I stayed at the tourist hub of Glenelg, which was quite close to Flinders Medical Center. It has a long beach and many cafes and restaurants, which are usually bustling with people.

Overall, this fellowship was a great experience, and I highly recommend it to any young surgeon for all the wonderful things it has to offer.

01 View from hotel of Glenelg Pier

ISAKOS Members Receive Full Access to OrthoEvidence

ISAKOS / OrthoEvidence Portal

OrthoEvidence's database has more than 3,400 evidence-based summaries from more than 360 journals of the highest-quality research in orthopaedics.

1

Log in to myISAKOS at
www.isakos.com/myISAKOS

myISAKOS

2

Click on
myPublications in the
myISAKOS Dashboard



3

Click "Access"
the ISAKOS/
OrthoEvidence Portal

Access

OE ORTHOEVIDENCE⁺

in partnership with



Stefan Mogos, MD
Bucharest, ROMANIA

*Steadman Clinic,
 Vail, CO UNITED STATES*

The present article provides a short report of my activity during the ISAKOS Teaching Center Scholarship at Steadman Clinic in Vail, Colorado, under the coordination of Dr. Robert LaPrade, from January 3 through 27 2017.

First, I would like to thank everybody who made possible these Fellowships, which represent a great opportunity to get in touch with leading orthopaedic centers all over the world and thus improve the management of our patients.

I received the letter of acceptance for the ISAKOS Teaching Center Scholarship in July 2016. This letter was welcome news as I was searching for an opportunity to continue my medical education outside of Europe after having had great experiences during my previous fellowships in Lyon, Geneva, and Barcelona. At the same time, it was like feedback for my efforts and an acknowledgement of my work during the last years. I was offered the opportunity to visit an important medical center and, even more, to visit a hospital doing very important work in the field of the knee pathology, which is my main focus as an orthopaedic surgeon.

After receiving the letter, I contacted Dr. Robert LaPrade, who agreed to host me in his clinic for the ISAKOS Teaching Center Scholarship. After an exchange of e-mails, we agreed that my visit to the Steadman Clinic in Vail, Colorado, would take place from January 3 to 27, 2017. Dr. LaPrade and his team were very helpful in establishing the other details of my visit, especially concerning accommodations and daily meals.

I arrived in Denver on January 2, 2016, and a shuttle bus took me from the airport to the apartment where I stayed during my visit. On January 3, I met Dr. LaPrade and his team at the Steadman Clinic, a very modern medical facility in Vail, Colorado. Thus began my “orthopaedic adventure.”

The progress that I made during this period was enormous. I was exposed to the latest technical developments and came into contact with some of the greatest orthopaedic surgeons in the United States. I had the chance to observe the modern surgical treatment of complex knee injuries (including multiligamentous knee injuries) as well as advanced techniques of meniscal and cartilage repair. The preoperative, operative, and postoperative management of these patients were all of great interest to me. In the field of shoulder surgery, I observed surgical procedures performed by Dr. Millett, the expert at the clinic in this area of activity. In the afternoons and evenings, I had the time to review the literature on the newly seen procedures. I also had the opportunity to go in the lab to practice all the procedures on cadaveric specimens. Early every Monday morning, I took part in the weekly scientific meetings at Steadman Clinic.

During the weekends, I took advantage of the opportunity to explore Vail and the neighbouring areas, including Denver and Beaver Creek. I am very grateful to Dr. Robert LaPrade for accepting me as a scholar in his clinic. I am very proud to have had the opportunity to observe Dr. LaPrade and his team.

**The ISAKOS
 Online Education Portal**

Available on
 Global Link

Access archived Congress presentations, surgical demonstrations/courses, committee projects and current concept articles... and more!

ISAKOS
 global link

isakos.com/GlobalLink

Dr. Ghislain Nietiayurk Aminake, MBBS, MS Shanghai, CHINA

Linksfeld Park Medical Center,
Johannesburg, SOUTH AFRICA



I was very grateful to be selected for the ISAKOS Teaching Center Scholarship in 2016. After going through the ISAKOS directory of teaching centers multiple times, I decided to spend this wonderful opportunity at the knee unit at Linksfeld Park Medical Center in Johannesburg, South-Africa.

After initiating contact with the teaching center and going through the visa application procedures, I finally arrived in Johannesburg on November 7, 2016, around noon. I spent the rest of the day settling in, and by the next morning I was ready to make the best of this great opportunity.

Upon stepping into Suite 303 at the hospital, I was introduced to the entire staff of the knee unit, lead by Dr. Ponky Firer and his associate Dr. Bradley Gelbart. I received a warm welcome and immediately became part of the team. By the end of the first week, I was already introduced to Dr. Firer's philosophy regarding total knee arthroplasty, consisting of maintaining soft-tissue balance by focusing on bone osteotomy instead of soft-tissue release. There was an ongoing study on the topic, and the clinical and statistical results looked very promising.

Our weekly work schedule was as follows. On Mondays, Tuesdays, and Thursdays, we had a surgery list in the morning and clinic in the afternoon; on Wednesday mornings, we had clinic at Charlotte Maxeke Johannesburg Academic Hospital (formerly known as Johannesburg General Hospital); and on Fridays, we had a surgery list at that same hospital.

I quickly became an active member of the team, observing and learning consultations tips from Drs. Ponky and Gelbart, and actively assisting during surgical procedures. Our surgery lists included procedures such as TKA, partial knee replacement, arthroscopic ACL reconstruction with or without extra-articular tenodesis, PCL reconstruction, PLC reconstruction, partial meniscectomy, all-inside meniscal repair, inside-out meniscal repair, microfracture, and articular cartilage repair. The biggest highlight of my visit was definitely the basic knee arthroscopy cadaveric workshop hosted at the KZN Orthopaedic Training Centre, during which I had the privilege of gaining hands-on practice under the supervision of Dr. Gelbart.



For a young surgeon like me, this experience has boosted my confidence and what I have learned is going to influence my practice, going forward.

Last but not least, I would like to thank ISAKOS for this eye-opening opportunity, for which I will forever be grateful. I would like to extend special thanks to Dr. Ponky for his assistance throughout the planning of this visit and for the tutoring during the visit; to Dr. Gelbart for making me part of the team and for his constant concern and highly productive tutoring; and to all of the staff at the Linksfeld Park Medical Center knee clinic for a wonderful experience.

Journal of ISAKOS



Joint Disorders &
Orthopaedic
Sports Medicine

JISAKOS synthesizes current research in orthopaedic sports medicine to provide an expert guide to treating and managing patients.

Visit the journal website today!
jisakos.bmj.com



BMJ

ISAKOS Upper Limb Travelling Fellowship

Peter Domos MD, FRCS (Tr&Orth)
Cambridge, UNITED KINGDOM

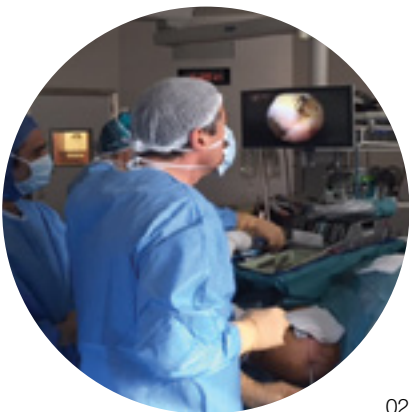Being awarded the Upper Limb Travelling Fellowship by ISAKOS afforded me an amazing opportunity to travel within Europe and to spend time with leading shoulder and elbow surgeons.

I spent two weeks during the fellowship program in Nice, France, following Professor Pascal Boileau in his busy practice at a brand new university hospital. I spent five sessions per week in the operating room (OR), where I was involved in more than 20 cases.



01

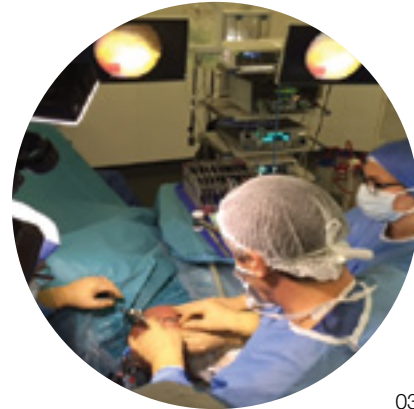During this time, I was able to observe Dr. Boileau perform his unique arthroscopic Latarjet-Bankart technique with button fixation as well as the bony increased offset (BIO) reverse shoulder arthroplasty (RSA) with or without the L'Episcopo procedure to improve patient satisfaction and external rotation (as indicated with the ADLER score).



02

I also was able to watch him perform his unique subscapularis tendon repair using the Nice knot following arthroplasty (a technique that I have managed to incorporate into my own practice).

In addition, I followed him and his two fellows in the outpatient department for 3 sessions per week, where he personally reviewed all of his patients (approximately 50 patients per day).



03

Professor Boileau has also set up a successful day-case surgery system, which even covers shoulder arthroplasties. He shared with me his self-designed orthopaedic PC program to collect outcomes and scores. We had an interesting discussion about his concept of the RSA inclination angle, the unstable painful shoulder, the arthroscopic Trillat procedure, and the double-layer rotator cuff repair or arthroscopic transosseus cuff repair (Fig. 3).

When not spending time with Dr. Boileau, I took the opportunity to explore the beautiful seacoast and Nice.

Dr. Laurent Lafosse

*ALPS Surgery Institute (ASI),
Clinique Generale d'Annecy, ANNECY, FRANCE*

The second visit was to the wonderful town of Annecy to meet Dr. Laurent Lafosse and his two fellow, for one week.

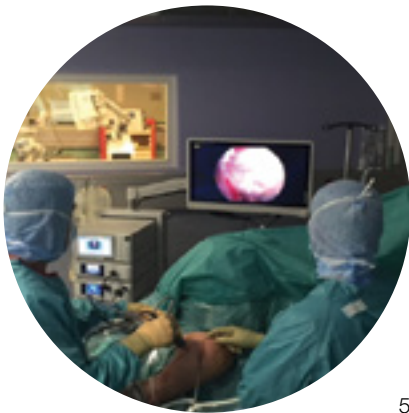

04

- 01 OR session with Prof. Boileau
- 02 Prof. Boileau performing his arthroscopic Latarjet technique
- 03 New technique of arthroscopic transosseus cuff repair
- 04 Outpatient clinics with Dr. Lafosse

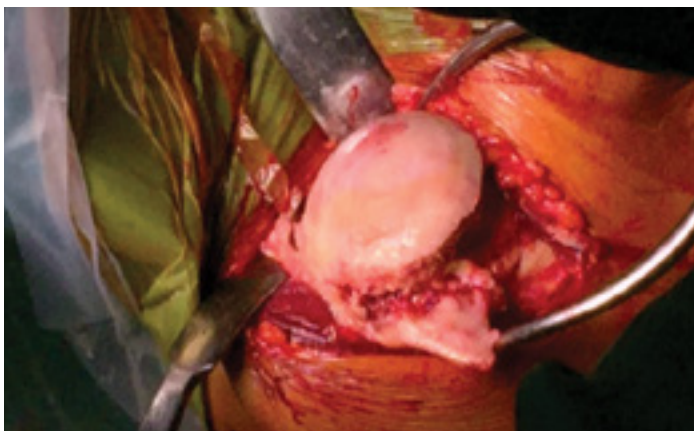ISAKOS Upper Limb Travelling Fellowship Report 2016 (cont.)

Dr. Lafosse has hosted more than 100 fellows, from all over the world, who typically spend at least three months with him. In addition, he has hosted a number of visitors for shorter periods. I followed him in the outpatient clinics for two days, where he personally reviewed all of his patients (45 patients per ay). We discussed in detail the suprascapular nerve compression test and the new hyperextension-internal rotation (HERI) test, for anterior instability. He used his innovative 4D Code system for a comprehensive description of shoulder pathologies and procedures. I was able to spend 2 full days in the OR (6 or 7 cases per day), during which I was able to see Dr. Lafosse perform see his arthroscopic Latarjet technique (Fig. 5), arthroscopic posterior bone-block procedure, arthroscopic suprascapular nerve release and, subacromial spacer-protected arthroscopic rotator cuff repair.



5

I also observed his unique V-shape subscapularis tenotomy and repair for anatomic total shoulder arthroplasty (Fig. 6).



06

Professor Christian Gerber

Balgrist University Hospital, ZÜRICH, SWITZERLAND

During my third visit, I spent a week in Zürich observing Professor Christian Gerber, Professor Dominik Meyer, and the rest of their team (2 other consultants, one fellow, and four residents).

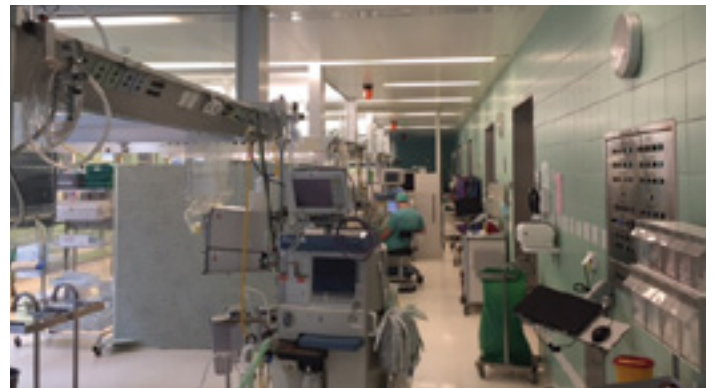

07



08

The team spent approximately 20% of their time treating elbow problems as well as some shoulder and elbow trauma cases. I spent three full days in the OR, which has a unique set up as all rooms are separated only by movable walls. This arrangement allows the more senior experienced surgeons to easily advise their younger colleagues intraoperatively, even if they are scrubbed in a different room (Fig. 9).




09

I scrubbed in for almost all cases and received great exposure to their approaches to primary and revision instability and arthroplasty procedures. We discussed the use of metal-backed glenoid components and single medial-row repair for the treatment of massive cuff tears. During my time spent in the outpatient clinics, I developed my understanding of the critical shoulder angle (CSA) in clinical practice and their conservative treatment of frozen shoulder (oral or intra-articular administration of steroid along with NSAID, vitamin C, and calcitonin) and also managed to clarify the best indications for tendon transfers. I was also invited to their monthly lunchtime research meeting, where they discuss the progress of ongoing projects as well as other new ideas. I spent my free time exploring the beautiful city of Zürich.

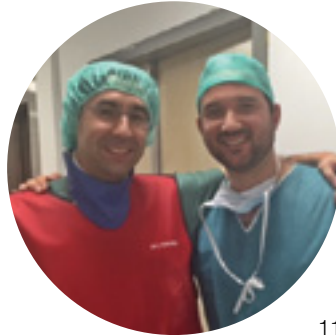
Professor Emilio Calvo

Universidad Autónoma, MADRID, SPAIN

I then travelled from Switzerland to Madrid for my one week visit with Professor Emilio Calvo and Dr. Antonio Foruria.

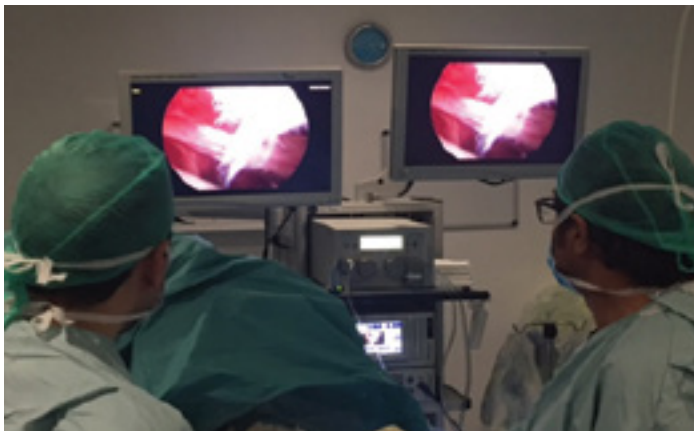


10



11

During that week, I was exposed to a good mixture of shoulder and elbow cases, including complex trauma cases, in the outpatient clinics and OR. I managed to see some great procedures, including an arthroscopic Latarjet procedure (Fig. 12), osteosuture fixation of proximal humeral fractures, and various treatments for complex elbow injuries.



12

We had interesting discussions surrounding the up-to-date management of isolated coronoid fractures and shoulder instability following failed Latarjet procedures. The former are treated with unique arthroscopic extracapsular reinforcement to re-create a sling effect when there are no bone-block complications. I also picked up useful tips and tricks for ideal radial head arthroplasty. In my down time, I visited some attractions of the capital city of Madrid and enjoyed the great food that it had to offer.

Dr. Alexandre Lädermann

Shoulder Surgery Centre, Clinique La Colline, GENEVA, SWITZERLAND

My next trip involved spending a week with Dr. Alexandre Lädermann and his fellow in Geneva.



13

Dr. Lädermann has a busy practice, and I had the opportunity to observe him in both the outpatient clinic and the OR. I scrubbed in for all cases, the first of which was an arthroscopic partial scapulectomy and debridement for the treatment of snapping scapula. I was interested to learn about his subscapularis-sparing reverse shoulder arthroplasty technique and approach, which allows immediate full mobility. Between cases, we had a great discussion about his approach to ACJ injuries with the modified Mazzocca technique, the recently described Fosbury flop cuff tears, and his independent double-row cuff repair. He also explained his preoperative CT and patient-activity-based PC program, which helps to plan custom subacromial decompressions.

- 05 Dr. Lafosse performing his arthroscopic Latarjet technique
- 06 V-shape subscapularis tenotomy
- 07 OR session with Prof. Gerber
- 08 OR session with Prof Meyer
- 09 OR in Balgrist
- 10 OR session with Prof. Calvo
- 11 OR session with Dr. Foruria
- 12 Prof. Calvo performing arthroscopic Latarjet procedure
- 13 Outpatient clinics with Dr. Lädermann

ISAKOS Upper Limb Travelling Fellowship Report 2016 (cont.)

Dr. Roger Van Riet

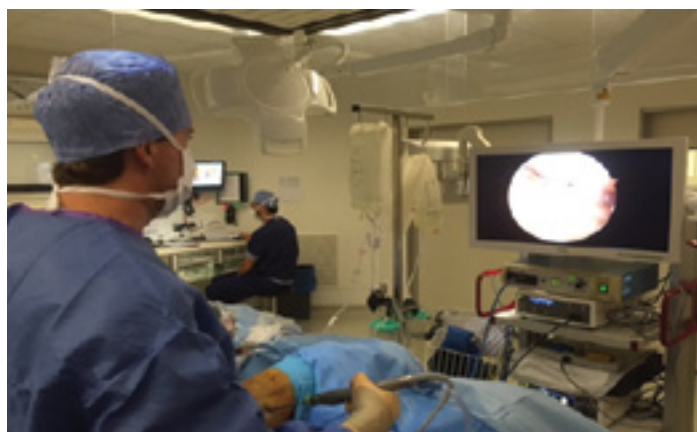AZ Monica/Orthopedic Center Antwerp, BELGIUM

My last visit was to Antwerp, to see Dr. Roger Van Riet, who is one of the founders (and current president) of the Belgian Elbow and Shoulder Society. I followed him for more than a week. Dr. Van Riet deals with elbow problems 80% to 90% of the time, with almost 500 cases a year, including approximately 200 elbow arthroscopies and multiple trauma cases. He has tremendous experience, as reflected in the number of short surgical videos that he has prepared for different courses and meetings, which he showed to me on his personal laptop. I spent three sessions at outpatient clinics, where he saw up to 50 patients per session.



14

I was amazed by the very efficient “traffic light system” that informs him, his fellows, and the nurses which consultation room to enter next (Fig. 14).



15

During this trip, I gained a greater understanding about the PIN test, endoscopic partial distal biceps tear procedures, and complex ligament reconstruction. I spent 5 sessions observing Dr. Van Riet in OR, where he treats 12 to 15 patients per day. I saw him perform several elbow arthroscopy procedures (Fig. 15) as well as his unique percutaneous tennis elbow release and PIN decompression via an open anterior approach.

Dr. Van Riet and I had an in-depth discussion about his arthroscopic LUCL repair and EHL allograft reconstruction for the treatment of chronic ligament insufficiencies. At the end of the week, we also enjoyed few pints of famous Belgian beer together and explored Antwerp (Fig. 16).



16

Gains from this fellowship

This fellowship allowed me to develop a much greater understanding of different controversial shoulder and elbow pathologies. These visits provided a great balance between elective and trauma cases, outpatient clinics, and OR sessions, which maximized my learning opportunities.

I hope to apply the acquired knowledge and skills to my future clinical practice as well as share my experiences with colleagues. I also took for the opportunity to compare and contrast different healthcare systems in Europe and to build an international network between different orthopaedic societies. Moreover, the fellowship allowed me to learn about new cultures, make new friends, and visit amazing places.

Overall, this fellowship was an amazing experience, and I encourage other colleagues to travel. I would like to thank all of my hosts and ISAKOS for this unique and truly educational experience.

14 “Traffic light system”

15 Elbow arthroscopy performed by Dr. Van Riet

16 Sampling Belgian beer in Antwerp

The Journal of Rheumatology

First Release Articles
Current Issue
Archives
Authors/Reviewers



What you get

- ↖ Current
- ↖ Clinical
- ↖ Definitive

Where you get it **THE JOURNAL**

To subscribe: visit jrheum.org online or send in your completed coupon below

Rates for 2017 calendar year USA/INTERNATIONAL

	Print + Online	Online Only
INDIVIDUALS:	\$350 US	\$285 US
INSTITUTIONAL:		
- Multisite*	On request	On request
- Multisite (IP ranges)	\$1025 US	\$975 US
- Basic-Plus (IP ranges)	\$750 US	\$700 US
- Basic (up to 4 users)	\$550 US	\$500 US
TRAINEES†	\$215 US	\$150 US+
AIRMAIL (ADD)	\$120 US	

For terms of access visit jrheum.org
*Supervisor certification required below.

NAME OF SUPERVISOR: _____

SUPERVISOR SIGNATURE: _____

SUPERVISOR TELEPHONE: _____

Please enter my 2017 subscription to The Journal of Rheumatology

Name (please print) _____

Address _____

City _____ State/Province _____

Country _____ Zip/Postal Code _____

Contact E-mail _____

Amount Enclosed \$ _____ Bill Me _____

Telephone Number _____ Fax Number _____

VISA/MasterCard Number _____ Expiration Date _____

Signature _____ CVV _____

Mail completed form to: **The Journal of Rheumatology**
365 Bloor Street East, Suite 901 Phone: (416) 967-5155
Toronto, Ontario Canada M4W 3L4 Fax: (416) 967-7556
E-mail: subscriptions@jrheum.com

All subscriptions are for the calendar year. Renewals for print subscriptions received after May 31, 2017 will be charged an additional \$10 per back issue. Back issues: 3 years including current year are available if in stock. Single copies are available at \$30 each. Claims: US 2 months, elsewhere 4 months from issue date, e.g., March 1 and May 1, respectively, for the January Issue. **PRIVACY POLICY:** For details of our privacy policy, visit our website at www.jrheum.org.

CCAP-AANA 8th Annual International Meeting

26–30 September, 2016

Lima, PERU

The 8th Annual International Meeting of the Peruvian Arthroscopic Chapter of the AANA Course had 296 registered attendees in addition to the 20 speakers and members of the Organizing Committee. No missed talks were observed, and the program was entirely filled. The level of attendee satisfaction was high. Social activities included the inauguration and closure ceremonies and the President's Dinner, with great attendance from the faculty, including Dr. Neyret, President of ISAKOS, Dr. Abrams, president of AANA, and Dr. Espregueira, President of ESSKA. Overall, the meeting had great attendance, offered a high academic level, and provided great attendee satisfaction.



LKS 2017 Symposium

2–3 March, 2017

Camara de Comercio del Peru

In the 21st century, orthopaedic surgery is changing and developing every day. As a result, specialists must be exposed to new skills and methods so that they can evaluate, judge, and apply this knowledge to their patients and achieve the best medical results. The LKS 2017 Symposium offered a great deal of new knowledge to orthopaedic surgeons who wish to improve their skills in the management of knee diseases.

Under the accurate vision and management of Dr. Rolando Suarez Peña, an orthopaedic surgeon with a private and public practice dedicate to the research and vanguard treatments of knee diseases, followed by the Knee Unit of the Edgardo Rebagliati Martins hospital from Lima, Peru, this conference attracted knee surgeons from Peru, Latin America, USA, and Europe.

This Symposium, which was sponsored by national and international institutions such as ISAKOS and the Arthroscopy Chapter from Peru, had 448 attendees. Topics included capsular ligamentous injuries, knee osteoarthritis, knee instability, primary knee replacement, osteotomies around the knee, meniscal injuries, knee revisions, ACL injuries, and various other procedures. The sessions included 55 expert conferences as well as two plenary sessions with Dr. Philippe Neyret and Dr. René Verdonk.

This symposium also provided a great opportunity to develop friendships, enjoy down-time activities such as a beach day, and enjoy exclusive dinners around Lima. Overall, the symposium was a great success.

Join the ISAKOS Global Conversation!

 **Tweeting About The Congress?**
Include #ISAKOS2017 in your Tweets!

facebook.com/ISAKOSSociety

@ISAKOS



Join the ISAKOS Group on LinkedIn



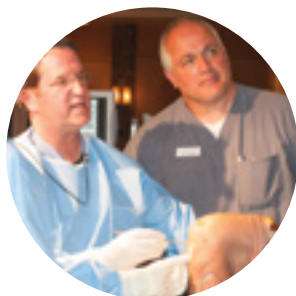Vail International Knee Symposium

9–11 June, 2016

Vail, Colorado

The third annual Vail International Knee Symposium (VIKS 3) was co-chaired by Rob LaPrade, MD, PhD and Lars Engebretsen, MD, PhD, and was sponsored by Smith and Nephew. The course was attended by 160 physicians and scientists from all six inhabited continents. The faculty were from North and South America, Europe, and Africa. The course format was a combination of interactive lectures combined with 17 live surgical demonstrations to enhance the lecture content on the anatomical treatment of complex knee injuries.

Topics covered included anatomic-based reconstructions of the medial and posterolateral aspects of the knee, double-bundle PCL and revision ACL reconstructions, osteotomies, and trochleoplasty. In addition, all surgeons were able to attend a cadaveric surgical skills lab to practice the techniques with faculty. Overall, the course was a huge success, and VICKS 4 is scheduled to be held on June 22 to 24, 2017.



ANNOUNCEMENT ABOUT JOSKAS 2017

Dear Colleagues,

We are pleased to inform you that the 9th Annual Meeting of Japanese Orthopaedic Society of Knee, Arthroscopy and Sports Medicine (JOSKAS 2017) is going to be held in Sapporo, Japan, on June 22 to 24, 2017.

We welcome you to submit abstract for oral and E-poster presentation.

The meeting outline is as follows:

Meeting Name The 9th Annual Meeting of Japanese Orthopaedic Society of Knee, Arthroscopy and Sports Medicine (JOSKAS 2017)

Date June 22–24, 2017

Venue Sapporo Convention Center
0-0-1 Higashi-Sapporo 6-jo,
Shiroishi-ku, Sapporo, 003-0006,
JAPAN
TEL: +81-11-817-1010

President Yasuhito Tanaka, MD, PhD
Professor and Chairman of
Orthopaedic Surgery,
Nara Medical University

Website www.c-linkage.co.jp/joskas2017/en/index.html

We look forward to your abstract submission.

Sincerely yours,

Organizing Committees of JOSKAS 2017

SECRETARIAT OF JOSKAS 2017 CONVENTION LINKAGE, INC.

PIAS TOWER 11F,
3-19-3 Toyosaki,
Kita-ku, Osaka 531-0072
JAPAN

Phone: +81-6-6377-2188

Fax: +81-6-6377-2075

E-mail: joskas2017@c-linkage.co.jp

UPCOMING ISAKOS APPROVED COURSES

Samsung Medical Center 10th Live Surgery and Symposium
Samsung Medical Center
Seoul, REPUBLIC OF KOREA

May 13–14, 2017

Chair(s): Jae Chul Yoo

For further information, please contact:

Kwon YH
Tel: +821099333501
Fax: +82234100061

San Diego Shoulder 34th Annual Course:
Arthroscopy, Arthroplasty, and Fractures
Hilton San Diego Bayfront
San Diego, CA UNITED STATES

June 14–17, 2017

Chair(s): James C. Esch, MD
Jon J.P. Warner, MD

For further information, please contact:

Larky Blunck
Tel: 760-940-2066
Fax: 951-695-6801
www.shoulder.com

9th Meeting of the Peruvian Arthroscopic Chapter
Lima Chamber of Commerce Convention Center
Lima, PERU

June 22–23, 2017

Chair(s): Dr. Jose Luis Guzman, MD

For further information, please contact:

Dr. Jose Luis Guzman Vargas, MD
Tel: (+51)999451077; (+51)12641747
Fax: (+51)12643623
www.maeventosycongresos.com

Vail International Complex Knee Symposium (VICKS) IV
Marriott Hotel
Vail, CO UNITED STATES

June 22–24, 2017

Chair(s): Robert F. LaPrade MD, PhD; Lars Engebretsen MD, PhD

For further information, please contact:

Robert F. LaPrade MD, PhD
Tel: 970-479-5881
Fax: 9704795813
drlaprade.com

ICRS Heritage Summit
Gothia Towers
Gothenburg, SWEDEN

June 29–July 1, 2017

Chair(s): Mats Brittberg, Gothenburg,
Ken Zaslav, Richmond

For further information, please contact:

Melanie
Tel: 0041445037373
Fax: 0041445037372
<http://cartilage.org/icrs-heritage-summit-gothenburg/organisation/>

Arthroscopy & Arthroplasty Courses Utrecht 2017
University Medical Center Utrecht
Utrecht, NETHERLANDS

July 3–7, 2017

Chair(s): Rob PA Janssen, MD, PhD

For further information, please contact:

Florence Hanselaar
Tel: +3130 276 9174
Fax: +3130 276 9251
<https://www.shoulder-elbow-knee.nl>

17th Amsterdam Foot and Ankle Course
Academic Medical Center Amsterdam
Amsterdam, NETHERLANDS

July 12–13, 2017

Chair(s): Prof. C.N. van Dijk

For further information, please contact:

Gwendolyn Vuurberg
Tel: +31(0)205662474
Fax: +31(0)205669117
www.ankleplatform.com

3rd Advanced Amsterdam Foot and Ankle Course
Academic Medical Center Amsterdam
Amsterdam, NETHERLANDS

July 13–14, 2017

Chair(s): Prof. C.N. van Dijk

For further information, please contact:

Gwendolyn Vuurberg
Tel: +31(0)205662474
Fax: +31(0)205669117
www.ankleplatform.com

Combined 5th Scientific Meeting of IHKS with ICJR Symposium
Shangri-La Hotel
Central Jakarta City, INDONESIA

August 23–27, 2017

Chair(s): Andito Wibisono, MD

For further information, please contact:

EMILDA KARLINA
Tel: +6221-52920303
Fax: +6221-52920303
www.ihks.org

VIII Jornada Lyonesa no Brasil–ACL
Centro de Convenções de Goiania-GO
Goiania, BRAZIL

August 31–September 2, 2017

Chair(s): Guilherme Zuppi

For further information, please contact:

Vitor Padua
Tel: 55 14 991239932
Fax: 55 14 34549326
<http://rventos.net>

4th Saúde Atlântica & ISAKOS & ESSKA International Meeting–Challenges in Football Injuries

Porto Palácio Congress Hotel

Porto, PORTUGAL

September 22–23, 2017

Chair(s): João Espregueira-Mendes

For further information, please contact:

Vânia Teixeira
Tel: +351220100117
Fax: +351220100122
<http://jornadassaudeatlantica.com/>

ICRS Focus Meeting–Osteoarthritis in Athletes

Schulthess Clinic

Zurich, SWITZERLAND

September 28 - 29, 2017

Chair(s): Gian Salzmann

For further information, please contact:

Melanie
Tel: 0041445037373
Fax: 0041445037373
<http://cartilage.org/icrs-focus-meeting-osteoarthritis-in-athletes/>

icSPORTS 2017–5th International Congress on Sport Sciences Research and Technology Support

Funchal, PORTUGAL

October 30–31, 2017

Chair(s): Pedro Pezarat

For further information, please contact:

Ana Guerreiro
Tel: +351 265 520 185
Fax: +351 265 520 186
<http://www.icSPORTS.org/>

International Consensus Meeting on Cartilage Repair of the Ankle
Pittsburgh, PA UNITED STATES

November 17–18, 2017

Chair(s): John G. Kennedy, MD

For further information, please contact:

Christopher Murawski
Tel: +1 570 236 4628

Athens Shoulder Course
Conference Center “N. Louros” Mitera
Hospital & Laboratory of Anatomy of the
Medical School of the University of Athens
Athens, GREECE

February 1–3, 2018

Chair(s): Antonogiannakis Emmanouel

For further information, please contact:

Despina Nikolopoulou
Tel: +302109609400
Fax: +302104190905
www.athens-shoulder-course.com

Is your Course an...

ISAKOS
Approved-Course

www.isakos.com/meetings

The all-in-one visualization solution – designed for performance, efficiency and value

Clarity and confidence at your fingertips

Illumination, visualization, image capture and image management are all here, in one system, and for one cost. The Camera captures in high definition, the Camera Head is autoclavable, durable and ergonomic, and a proprietary iPad[®] application takes media management and versatility to a whole new level.

Performance

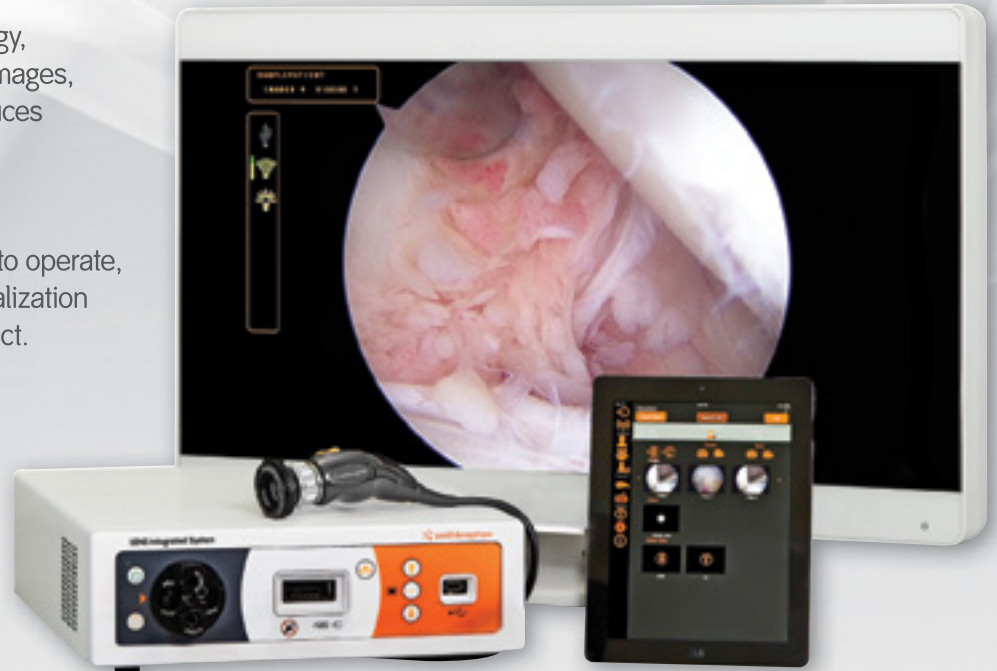Employing the latest in CMOS chip technology, the LENS System captures quality, true HD images, features excellent depth of focus* and produces clear live video.

Efficiency

Designed to be durable, intuitive and easy to operate, the LENS System provides all the core visualization features necessary for the results you expect.

Value

By combining three products into one, the LENS Surgical Imaging System can potentially minimize capital investment. Also, the system is designed for scalability, meaning that future camera options and software upgrades may be added on as they become available.



**Based on limited commercial release feedback. Data on file at Smith & Nephew, 2016.*

For more information, or to schedule an evaluation, please contact your local sales representative or call Smith & Nephew Customer Service at +1 800 343 5717.

Supporting healthcare professionals for over 150 years



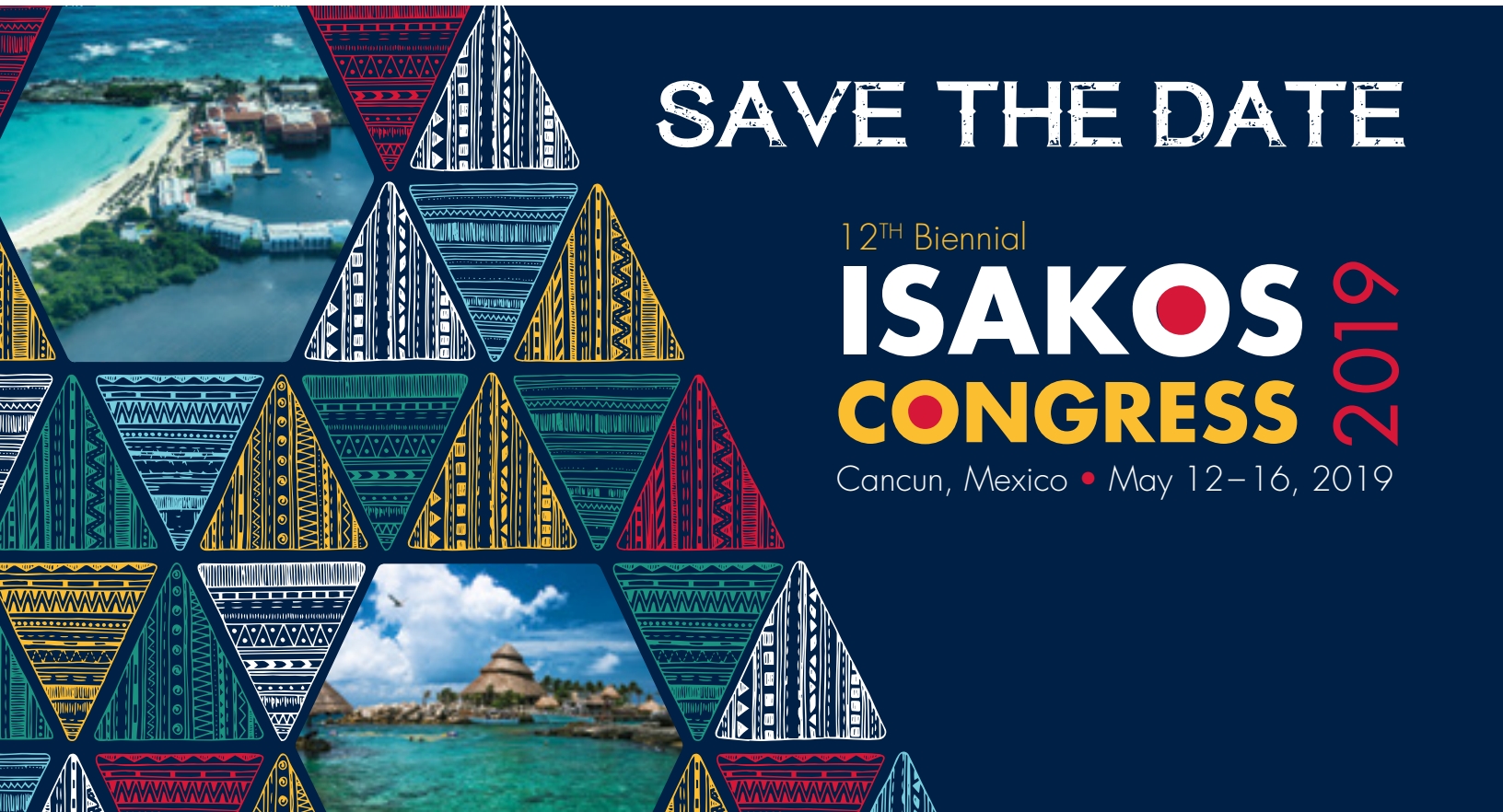International Society of Arthroscopy,
Knee Surgery and Orthopaedic Sports Medicine
2410 Camino Ramon, Suite 215
San Ramon, CA 94583-4318 USA

Telephone: +1 925 807-1197
Fax: +1 925 807-1199
isakos@isakos.com
www.isakos.com



2017
11TH BIENNIAL
ISAKOS
CONGRESS
JUNE 4-8, 2017
SHANGHAI, CHINA

JOIN US
IN SHANGHAI



SAVE THE DATE

12TH Biennial
ISAKOS
CONGRESS 2019

Cancun, Mexico • May 12-16, 2019