

ISAKOS

ISAKOS NEWSLETTER 2016 • VOLUME II

Current Concepts on Arthroscopy, Knee Surgery & Orthopaedic Sports Medicine



- INSIDE 2** A LETTER FROM ISAKOS PRESIDENT, PHILIPPE NEYRET
- 4** ISAKOS CONGRESS 2017 – SHANGHAI
- 12** STEM CELL UPDATES IN SPORTS MEDICINE
- 30** POINT / COUNTERPOINT ON POSTEROLATERAL PORTAL DURING HIP ARTHROSCOPY

in this issue

Editor's Message	1
President's Message	2
2017 Congress, Shanghai, China	4
Communication Committee Update	10
Current Concepts	12
Members in Memoriam	43
Approved Course Reports	44
Upcoming Approved Courses	51

EDITOR

Robert G. Marx, MD, MSc, FRCSC UNITED STATES

EDITORIAL BOARD

Benno Ejnisman, MD BRAZIL
Iftach Hetsroni, MD ISRAEL
Christophe H. Hulet, MD, Prof. FRANCE
Bruce A. Levy, MD UNITED STATES
Stephen L. Lyman, PhD UNITED STATES
Tatsuo Mae, MD, PhD JAPAN
David Sadigursky, MD, MSc BRAZIL
Luis Alberto Vargas, MD, PhD UNITED STATES
Daniel Whelan, MD, MSc, FRCSC CANADA
Omer Mei-Dan, MD UNITED STATES, Past Editor



**International Society of
Arthroscopy, Knee Surgery and
Orthopaedic Sports Medicine**

2410 Camino Ramon, Suite 215
San Ramon, CA 94583 – 4318 USA
Telephone: +1 925 807 – 1197
Fax: +1 925 807 – 1199
Email: isakos@isakos.com

Educating the mind without educating the heart is no education at all.

– Aristotle

When asked in a recent survey, nearly 80% of ISAKOS members said that they joined ISAKOS to expand their expertise to be a better professional. Nearly 60% said they hoped to gain global scientific knowledge, and 35% felt ISAKOS offered unique international networking opportunities. What better way to gain advantage of all three than to attend the ISAKOS Congress?

ISAKOS prides ourselves on the education of the whole surgeon. Attendees at the ISAKOS Congress can look forward to unprecedented access to international leaders on the hottest, cutting edge topics in arthroscopy, knee surgery and orthopaedic sports medicine. Fellowship between surgeons of varying backgrounds and ethnicities is also a hallmark of the ISAKOS Biennial Congress. ISAKOS members look forward to the opportunity to engage with colleagues they don't get to see often due to geographical distance and busy schedules. Few other meetings provide the opportunity to watch a surgical demonstration on a cutting edge topic with an international leader, then walk down the hall and watch more international experts passionately debate a topic such as anatomic ACL reconstruction or shoulder instability repair.

The ISAKOS Congress is evolving on a daily basis as more surgical demonstrations, lectures and debates are added. Have you visited the ISAKOS Congress Interactive Agenda – www.isakos.com/InteractiveAgenda? The Interactive Agenda is a live reflection of the Congress Scientific Program—start building your schedule now using MySchedule!

The ISAKOS Committees are currently undergoing the immense task of reviewing the more than 2,000 scientific abstracts submitted for consideration for the ISAKOS Congress! Each abstract must be reviewed three times, using a 12-point scale. We greatly appreciate our committee members participating in this process to ensure the very best scientific quality for the Congress.

The beautiful city of Shanghai is a renowned international metropolis, perfect for an ISAKOS Congress. Situated on the estuary of Yangtze River, it serves as the most influential economic, financial, international trade, cultural, science and technology center in East China. Shanghai is afforded a unique glamour and blend of cultures as modern meets traditional, and western meshes with oriental. New skyscrapers and Shikumen (traditional Shanghai architecture) combine to shape a unique skyline, reflecting the Western customs and Chinese traditions that intertwine to make a visitor's stay truly memorable.

To learn more about the 11th Biennial ISAKOS Congress, please see page 4 of this Newsletter, or visit the ISAKOS website at www.isakos.com/2017.



Shanghai is NEAR!

Shanghai is near, very near! In just a few months the 11th biennial ISAKOS Congress will be held in Shanghai, China. The program looks spectacular and the meeting promises to be more educational and exciting than ever before. The range of topics is very wide and there will also be pre-courses focusing on surgery for active and athletic patients, injury prevention for high-level athletes, current concepts in shoulder surgery, advanced techniques for knee arthroplasty, biologics in sports medicine and also a course on hip problems in athletes.

A record number of papers were submitted, and of these 2050+ abstracts, nearly 800 will be selected for presentation in podium or poster format. There will also be 32 Instructional Course Lectures and 41 Symposia with the topics ranging from elbow arthroscopy to complex knee surgery and foot and ankle arthroscopy. There will indeed be something for everyone—I encourage you to look at the Congress Interactive Agenda and start building your schedule so you don't miss anything!

As always, the faculty and attendees will represent the entire globe. Every continent will be represented and we expect to have attendees from over ninety countries.

Shanghai is closer than you think. It is a major transportation hub with direct flights from around the world, including North and South America and Europe. Shanghai has two commercial airports—Hongqiao International, which services primarily domestic and Asia-based flights, and Pudong International, which serves more than 17 million passengers annually. Depending on your country of origin, a visa is likely needed to visit China. I encourage you to contact your local embassy as soon as possible, and download your complimentary visa invitation letter via the ISAKOS registrations system. More information on Hotels and Tours is also available through the Congress website—book early!

I strongly encourage you not to miss the ISAKOS Congress in Shanghai!

Robert G. Marx, MD, MSc, FRCSC UNITED STATES

ISAKOS Newsletter Editor 2015–2017





Greetings from ISAKOS

It has been my immense pleasure to serve as ISAKOS President for the past year.

MISSION

As I enter the second half of my ISAKOS Presidency, I have the occasion to reflect on the wonderful opportunities I have had to spread ISAKOS' mission of worldwide exchange and dissemination of education, research and patient care in Arthroscopy, Knee Surgery and Orthopaedic Sports Medicine.

As promised in my previous editorial, I would like to take this opportunity to expand on the results of the ISAKOS Strategic Retreat, held in late February, 2016 prior to the American Academy of Orthopaedic Surgeons meeting in Florida.

During this retreat, ISAKOS leaders, including the ISAKOS Executive Committee, members of the ISAKOS Committees and other key strategic leaders, gathered to reflect on the great strides ISAKOS has made in our first 20 years, as well as look forward to the great work we are sure to accomplish in our next twenty years.

VISION

We agreed that our ISAKOS Vision Statement should remain that ISAKOS strives to be a dynamic international organization that attracts and nurtures outstanding members who are dedicated to our mission of worldwide exchange and dissemination of information.

With that in mind, we identified our four key values:

- 1 Global Perspective**—We respect diversity and international viewpoints.
- 2 Excellence**—We take pride in ensuring quality.
- 3 Integrity**—We advocate high ethical conduct in all we do.
- 4 Dedication**—We believe in the ISAKOS Mission, its teachings and collaboration with others.

With our memories refreshed of the past, we looked forward to the key goals ISAKOS would like to accomplish before 2020. Our resulting Strategic Goals are as follows:

Membership: Provide value to current and future members through shared knowledge, experience and expertise.

Education: Serve as the premier educational resource for orthopaedic learning through continual enhancement of educational resources.

Research: Advance arthroscopy, knee surgery and orthopaedic sports medicine research and scholarship opportunities through funding-support and partnerships.

Collaboration: Further develop and enhance relationships with national, regional, and partner societies to support the ISAKOS mission and vision.

Infrastructure & Accountability: Maintain an efficient governance and operational organization to support the ISAKOS mission and vision.

These five guiding Strategic Goals will shape our ISAKOS initiatives, including committee projects, for the coming years.

As we considered these five strategic goals, it became clear that ISAKOS needed to increase our educational outreach outside of the ISAKOS Congress. Therefore, the ISAKOS Symposium & Workshop Series was born! The ISAKOS Symposium & Workshop Series will be an ongoing series of courses in targeted regions of the world, that either have never hosted an ISAKOS Congress, or where an ISAKOS Congress will not return for several years.

The first ISAKOS Symposium & Workshop Series event was held on October 13–15, 2016. The “Orthopaedic and Sports Medicine Master Class” was held at Aspetar in Doha, Qatar in collaboration with ESSKA, the new Middle East and Africa Knee, Arthroscopy and Sports Medicine Society (MAKASS), and Aspetar. The Master Class uniquely allowed ISAKOS to provide structured and comprehensive surgical skill instruction for 100 surgeons from the Middle East and surrounding regions. Attendees had the opportunity to interact with international experts in both knee and shoulder arthroscopy during hands on cadaveric Knee and Shoulder labs, and didactic sessions. More information on the course can be found on the ISAKOS website at www.isakos.com/doha2016. Further related to the Strategic Goals, ISAKOS will undergo our Committee on Committees process in the coming months. We ask all Active members to watch your email for information about applying to serve on ISAKOS Committees. The Committees are the backbone of our society, and we depend on them to continue our great work of advancing education and related patient care!

We hope you are making plans to join ISAKOS at an upcoming Collaborative Course, as well as the 11th Biennial ISAKOS Congress! Plans are well underway for the Congress in Shanghai, and we look forward to welcoming you for a busy and education-packed meeting.

As we approach the holiday season, I wish you all the best and a happy and healthy New Year!

All the Best,

Philippe Neyret, MD, FRANCE

ISAKOS President 2015–2017



HAVE YOU MADE PLANS TO ATTEND THE 11TH BIENNIAL ISAKOS CONGRESS?

ISAKOS looks forward to welcoming the ISAKOS Family to the 11th Biennial ISAKOS Congress in Shanghai, China! The 11th Biennial ISAKOS Congress represents a unique opportunity to learn from nearly 300 international leaders in the fields of Arthroscopy, Knee Surgery and Orthopaedic Sports Medicine. Drawing from the best and brightest of the international community, the ISAKOS Congress is your opportunity to interact with the leaders in the field, and our faculty look forward to meeting you!

The ISAKOS Congress is unique in the diversity of faculty and topics presented. Instructional Course Lectures, Symposia, Debates, lectures, scientific papers and live surgical demonstrations will address topics ranging from injuries of elite and civilian athletes, operative complications, use of biologics, osteoarthritis and total joint replacement.

The variety of topics available at the ISAKOS Congress can be seen in the variety of topics offered as Pre-Courses on Saturday, June 3. For one low registration price, registrants have the option to attend SIX different half-day pre-courses on *The Use of Biologics to Treat Sports Medicine Pathology*; *Evaluating Athletes with Hip and Groin Problems: From Symptoms to Diagnosis and Treatment*; *The IOC Prevention of Injuries & Illnesses in High Level Athletes*; *Advanced Course on Knee Arthroplasty*; *The Knee: Maximizing Surgical Procedures in the Active & Athletic Patient*; and *Current Concepts in Shoulder Surgeries: New Insights into Instability, Rotator Cuff Repair and Minimal Invasive Humeral Fracture Fixation*.

Can't wait for Shanghai? Start building your personal course schedule now through the ISAKOS Congress Interactive Agenda! www.isakos.com/InteractiveAgenda. Interested in hearing a particular faculty member? View their full presentation schedule through the Congress faculty list. The Interactive Agenda is being updated weekly.

The enormous metropolis of Shanghai is a city of changes. Melding old with new, Shanghai is the most populous city in China, with more than 23 million residents. Shanghai is a wonderful host city for ISAKOS, as more than 9 million of the 23 million residents of the city are from outside of China!

Particular points of cultural interest include Yuyuan Gardens (豫园) (in Old City), which is full of classical Chinese architecture. For a taste of 1920's Shanghai, head for the stately old buildings of the The Bund or the French Concession—this area is becoming known for boutique shopping and fantastic restaurants! For art aficionados—the Shanghai Museum (上海博物馆) has an impressive Ancient Bronze exhibit, as well as other traditional art offerings. Zhujiajiao Water Town (朱家角镇) is known as the Venice of Asia. This more than 400-year-old classic, water village is home to a five-arch bridge spanning the Cao Gang River. The city is located about 40 minutes from downtown Shanghai, but is home to quaint shops and restaurants serving local favorites. Visitors can stroll the maze of paths and bridges, and take a boat ride to view the residences of this nicely-preserved water village.

The Program Committee would like to thank all who have submitted abstracts for consideration for the 11th Biennial ISAKOS Congress. Abstracts are currently under review by our ISAKOS Committees, and decisions will be sent out by December 31, 2016.

We look forward to welcoming you to Shanghai and the unparalleled educational experience that is the ISAKOS Congress!

Julian A. Feller, FRACS AUSTRALIA
ISAKOS Congress Program Chair, 2017

Stefano Zaffagnini, MD, Prof. ITALY
ISAKOS Congress Program Deputy Chair, 2017

ISAKOS CONGRESS SURGICAL DEMONSTRATIONS

SUNDAY, JUNE 4 – THURSDAY, JUNE 8, 2017

The ISAKOS Congress Scientific Program will feature cutting edge Live Surgical Demonstrations with an internationally renowned faculty. Each demonstration will feature an international expert demonstrating on a cadaveric specimen. Questions will be relayed to the faculty by an expert moderator. These sessions are a highlight of the ISAKOS Congress, and one of our more unique educational experiences.

For a full schedule of the ISAKOS Congress Scientific Program events, please visit www.isakos.com/InteractiveAgenda

HIP

Hip Arthroscopy

Faculty to be confirmed

Gluteus Medius Repair

J. W. Thomas Byrd, MD USA

SHOULDER

Arthroscopic Latarjet

Pascal Boileau, MD, Prof FRANCE

Complex Rotator Cuff Tear

Yong Girl Rhee, MD SOUTH KOREA

Massive Rotator Cuff Repair

Anthony Romeo, MD USA

Posterior Instability Repair

Nikhil Verma, MD USA

Rotator Cuff Repair

Ian Lo, MD CANADA



KNEE

All Inside ACL Reconstruction

Faculty to be confirmed

Anatomic Single Bundle ACL Reconstruction

Freddie Fu, MD USA

Dinshaw Pardiwala, MS(Orth), DNB(Orth), FCPS, INDIA

Lateral Extra-Articular Tenodesis

Andy Williams, MBBS, FRCS, FRCS (Orth), FFSEM(UK)
UNITED KINGDOM

Meniscal Root Repair

Robert LaPrade, MD, PhD USA

Hua Feng, MD CHINA

Patellar Instability

David Dejour, MD FRANCE

Sachin Tapasvi, MBBS, MS, DNB, INDIA

KNEE ARTHROPLASTY

Robotic-Assisted Bi-Cruciate Substituting Total Knee Replacement

David Mayman, MD USA

Kinematic TKR

Stephen Howell, MD USA

*faculty pending confirmation

2017 11TH BIENNIAL
ISAKOS CONGRESS
JUNE 4-8, 2017 | SHANGHAI, CHINA

ISAKOS CONGRESS: PRE-COURSE PREVIEW

ISAKOS is pleased to offer six half-day pre-courses on Saturday, June 3, 2017. These courses will immediately precede the 11th Biennial ISAKOS Congress. Pre-Course registration includes admission to one morning and one afternoon pre-course. Three concurrent courses will be held in the morning, and three in the afternoon.

Full agendas for each pre-course can be found online in the ISAKOS Congress Interactive Agenda—
www.isakos.com/2017/PreCourses

MORNING

THE KNEE: MAXIMIZING SURGICAL PROCEDURES IN THE ACTIVE & ATHLETIC PATIENT

Chairs:

Elizabeth A. Arendt, MD UNITED STATES

Mark Clatworthy, FRACS NEW ZEALAND

Christopher John Vertullo, MBBS, FRACS (Orth),
FAOrthA AUSTRALIA

This pre-course is targeted to the orthopaedic surgeon whose practice centers on the young and the aging sports knee. It will present the latest knowledge and surgical techniques relevant to the management of knee pathology, focusing on surgical knowledge and technique. The course will be suitable for the subspecialist knee surgeon as well as the general orthopaedic surgeon desiring an update on controversies and techniques within the athletic and the aging knee.

The half-day course will consist of a series of expert and evidence based lectures combined with case examples querying the experts on difficult problems with diverse and at times controversial solutions. Key cadaveric surgical demonstrations are embedded within each topic. An interactive audience response system has enhanced audience participation and has augmented audience education. Following this course, the participant will be well-versed in the approach to the injured athletic knee, with improved knowledge in its management.




THE IOC PREVENTION OF INJURIES & ILLNESSES IN HIGH LEVEL ATHLETES

Chairs:

Lars Engebretsen, MD, PhD NORWAY

Gino M.M.J. Kerkhoffs, MD, PhD, Prof.
NETHERLANDS

Upon completion of this pre-course, participants will be able to understand the principles of injury and illness prevention. Practical examples will translate the principles into practical programs on Olympic athletes. Presentations will include case discussions from the recent Summer Olympic Games in Rio de Janeiro, ensuring healthy athletes, knee-related injuries, and how the IOC is working to prevent injuries in Olympic athletes.



CURRENT CONCEPTS IN SHOULDER SURGERIES: NEW INSIGHTS INTO INSTABILITY, ROTATOR CUFF REPAIR AND MINIMALLY INVASIVE HUMERAL FRACTURE FIXATION

Chairs:

Andreas B. Imhoff, MD, Prof. GERMANY

Felix Henry Savoie III, MD UNITED STATES

This course will present the latest techniques in shoulder stabilization like Latarjet—the French and US experience, and also new insights into rotator cuff repair (tendon to bone healing and superior capsule reconstruction) and minimally invasive humeral fracture fixation. Each presentation will be moderated separately as a cross-fire to involve the attending members.

AFTERNOON

ADVANCED COURSE ON KNEE ARTHROPLASTY

Chairs:

Sebastien Lustig, MD, PhD, Prof. FRANCE

Shuichi Matsuda, MD, PhD JAPAN

Willem Mare van der Merwe, MBChB, FCS,
SA Ortho SOUTH AFRICA

This pre-course will provide a comprehensive update and overview of the latest knowledge and techniques relevant to knee arthroplasty for the orthopaedic surgeon. The topics will include basic concepts and surgical technique of cruciate retaining and cruciate-sacrificed total knee arthroplasty, as well as unicompartmental knee arthroplasty. Focusing on management for severe varus or valgus deformity, instability, contracture, bone defect, and intraoperative trouble shooting. We have assembled an international faculty, including experts from around the world, presenting on their areas of expertise.

This half-day course will consist of a series of expert and evidence-based lectures. In addition to the lectures there will be panel discussions, particularly on controversial topics such as kinematic alignment. This pre-course will present a variety of surgical techniques, involving video demonstrations, as well as pearls and pitfalls, and discussions for each topic. Following this course, participants will be able to understand how to treat more difficult cases such as severe varus or valgus deformity by total knee arthroplasty.

**THE USE OF BIOLOGICS TO TREAT SPORTS MEDICINE PATHOLOGY**

Chairs:

Johnny Huard, PhD UNITED STATES

Robert F. LaPrade, MD, PhD UNITED STATES

Nicola Maffulli, MD, PhD, MS, FRCS(Orth)
UNITED KINGDOM

The course aims to provide a clinical-based overview on the scientific basis for the use of biologics to treat orthopaedic sports medicine pathology. The various treatment options available, including growth factors, platelet rich plasma, and stem cells will be presented, and the basic science rationale behind their use clarified. Their clinical use will be presented, the regulatory issues related to their use, and the evidence on their effectiveness and efficacy will be discussed.

**EVALUATING ATHLETES WITH HIP AND GROIN PROBLEMS: FROM SYMPTOMS TO DIAGNOSIS AND TREATMENT**

Chairs:

Per Hölmich, Prof., DMSc DENMARK

Nick Mohtadi, MD, MSc, FRCSC CANADA

Allston J. Stubbs, MD UNITED STATES

At the completion of this course, participants will be able to understand the presenting complaints, symptoms and patient reported outcome information. Participants will be able to confirm the common diagnoses in athletes presenting with a hip and groin problem. Participants will be able to understand the role of non-surgical and surgical treatment of common groin and hip conditions

ISAKOS CONGRESS HOTELS & TOURS ARE NOW AVAILABLE!

JW MARRIOTT SHANGHAI CHANGFENG PARK


ISAKOS Headquarters Hotel

Located in the Changfeng Ecological Commercial District in west Shanghai, the JW Marriott Hotel Shanghai Changfeng Park is adjacent to the Shanghai Convention & Exhibition Center of International Sourcing. It offers 501 guestrooms, six world-class restaurants and more than 1,500 square meters of multi-function event space featuring the state-of-the-art technologies and facilities. The hotel is poised to become the benchmark of luxury service as well as convention center in the fast growing, west Shanghai



GUOMAN HOTEL

As the flagship property of Guoman Hotels in Asia, Guoman Hotel Shanghai is a luxurious hotel in downtown Shanghai which is located in the Grand Hongqiao Area. 26 floors with sweeping views of Shanghai's stunning skyline and tranquil Changfeng Park's lake a stone's throw away, Guoman Hotels have created a hotel in green surroundings, seldom seen within the densely developed city of Shanghai. The hotel is closely located to the Shanghai Convention & Exhibition Center of International Sourcing (5-minute walk). Close to two shopping malls with a wide range of shops, restaurants and supermarkets. The hotel has abundant recreational facilities nearby, such as the Jackie Chan Film Gallery (2-minute walk), Shanghai Marina Club (5-minute walk), Shanghai Changfeng Ocean World (5-minute walk), Diskart Indoor Karting (15-minute walk).



RENAISSANCE SHANGHAI ZHONGSHAN PARK HOTEL

Renaissance Shanghai Zhongshan Park Hotel - A Marriott Luxury & Lifestyle Hotel. They have the proud distinction of being the tallest Renaissance hotel in the world, and their building is integrated with offices and a large shopping complex, offering guests easy access to many recreation opportunities. They're also ideally situated in the downtown district of Shanghai. With a unique location over the Zhongshan Park Metro Station Lines 2, 3, and 4; Shanghai Hongqiao International Airport is 18 minutes away via train. Settle in to one of the 667 deluxe hotel rooms and suites, which offer warm decor and helpful amenities; some also offer awe-inspiring views of downtown Shanghai. Sample flavorful dining at one of their on-site restaurants, or enjoy room service in the privacy of your accommodations.

RENAISSANCE SHANGHAI YANGTZE HOTEL

Located in the heart of Hongqiao, Renaissance Shanghai Yangtze Hotel, a Marriott Luxury & Lifestyle Hotel, is your home away from home. Merely a walk away from top exhibition centers and close to major national and international corporations, it is strictly business blended with pleasure in the most convenient of ways. With 5 award-winning restaurants and 2 lounges, indulge yourself with gastronomic temptations ranging from classical Chinese cuisine to modern Western fusion. The Renaissance Yangtze Shanghai Hotel delightfully indulges every business and leisure guest in unparalleled stay experience by combining savvy service with a home away from home feel.

www.isakos.com/2017/travel

ISAKOS ENCOURAGES CONGRESS ATTENDEES AND THEIR GUESTS TO EXPLORE THE RICH CULTURE AND SITES OF SHANGHAI!

Options include exploring the beautiful waterside City of Suzhou in Jiangsu Province in South China, made famous by its elegant classical gardens. Among these, the Humble Administrator's Garden, covering about 52,000 sq. meters (12.85 acres), is the largest and most renowned. Due to its unique designs and ethereal beauty, it is listed as a World Cultural Heritage site and has also been designated as one of the Cultural Relics of National Importance under the Protection of the State as well as a Special Tourist Attraction of China.



Take a cooking class and learn to make traditional soup dumplings with a Shanghainese family!

Explore the Shanghai Museum's mind-boggling collection of 120,000 precious exhibits including bronze, pottery, porcelain, calligraphy, Jade, furniture, coins, the collection of the minority group people painting.



ISAKOS encourages attendees of the 11th Biennial ISAKOS Congress to supplement your Congress experience with tours exploring the rich culture and history of China!

www.isakos2017congresstour.com/

Visit the giant panda at the Shanghai Zoo! Covering an area of 885,000 square, the Shanghai Zoo is home to more than 6,000 animals, including up to 600 rare animals. There are not only animals from China, such as giant pandas, golden monkeys, South China tigers, Manchurian tigers, Yangtze alligators, and elks, but also animals from all over the world, such as giraffe, kangaroo, penguin, hippopotamus, sea lion, ostrich, and cougar.



Experience China's ancient religious culture at the Jade Buddha Temple, constructed in 1918. The beautiful interior features classic Chinese architecture and is highlighted by a massive jade statue of Buddha. But what makes this so wildly popular is the ability to witness the temple's resident monks perform their daily ceremonies throughout its four halls.





Maintaining communication between such a diverse group of individuals such as ISAKOS members is a challenging task. We are disparate in our geography, languages, cultures, practices and time zones. We are united in our desire to learn and pass on knowledge relating to the health, well-being and recovery of our active patients. To achieve that goal and to continue that resolve at an international level we need efficient communication channels. This is the purpose of the ISAKOS Communications Committee. We build on the excellent work of earlier Committees and report to the Board through the efficient secretarial staff.

There are many levels of Communication already functioning very well within ISAKOS, but nothing is ever truly perfect and such issues can often be improved and should frequently be reviewed. New Committee members also offer different viewpoints and progressive improvements are the result.

Communication between members is already possible via the web site and at meetings, but is limited. An innovation which you will see very soon will be member profiling. When you renew your membership you will be asked to indicate your Practice Type, Area of Focus and Subspecialty / Anatomical area. This information along with your Geographical region will allow you to search through the ISAKOS web site for other members with like interests, either in your own region or internationally. Hopefully this will lead to better collaboration between members in dealing with difficult clinical cases or even establishing multicentre research projects.

Communication between members and the various Committees or the Board is currently challenging unless one knows personally the members on the particular Committee of interest. We encourage individual members who have an interest, an idea or a possible project to make contact with the Chairman of the relevant Committee directly by email or through the Secretariat.

On the other hand, Communication from the Board and Committees to the members is possible through many means. The ISAKOS web site is a great resource for members and a communication channel for all information related to ISAKOS. Improvements to the web site are ongoing but a major challenge at present is to make the Global Link section of the web site more user friendly. There is a wealth of information contained in Global Link and this needs to be more accessible to the membership. This is currently underway. Hopefully some items will be available for general access to 'advertise' one of the benefits of membership.

This Newsletter is very widely read among members and provides much information along with academic articles of interest. It is also available on the web site. Emails from the office staff regularly advertise local meetings, Congress information and other items. Social media is also being used increasingly as members become more comfortable with this 'new' form of information sharing.

Communication between Committees has always been difficult within ISAKOS, made even more so with the recent addition of new Committees. However the creation of a Committee Liaison officer has helped to improve duplication of effort between the Committees. This has also resulted in improved communication channels between Committees and the Board.

The Communication Committee is also working to produce an ISAKOS page on Wikipedia and expects to have that on line before Christmas. This will hopefully result in raising the awareness of ISAKOS in the general Orthopaedic community and possibly lead to new memberships.

Finally we would like to recognise those ISAKOS members who have passed away – not only the great innovators and contributors but also members who have contributed to the goals and fraternity of ISAKOS by being members, attending meetings and by simply being involved. There is a changed 'In Memoria' page on the web site and I invite you to visit it. Also if you know of any past or recent ISAKOS member in your region who has passed away, I ask you, please, to notify either the ISAKOS office or myself so that appropriate recognition can be made both in this Newsletter and on the Web page.

Peter Myers, MBBS, FRACS, FAOrthA AUSTRALIA
Chair, ISAKOS Communication Committee 2015-2017

Join the ISAKOS Global Conversation!

facebook.com/ISAKOSSociety

@ISAKOS



Join the ISAKOS
Group on LinkedIn

 **Tweeting About The Congress?**
Starting now, and during the Congress,
include hashtag #ISAKOS2017 in your Tweets
& join the global conversation!

Stem Cell Updates in Sports Medicine



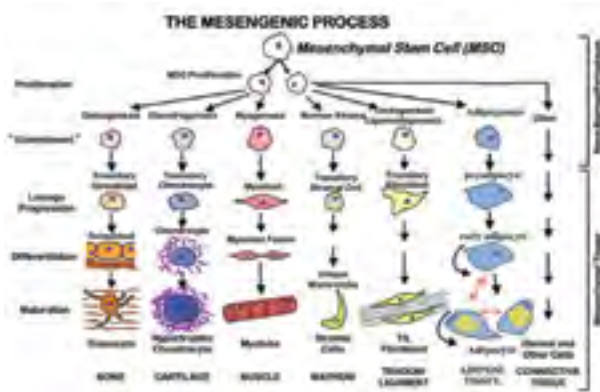
Adam Anz, MD
Andrews Institute
Gulf Breeze, FL, USA

“The first great advancement in sports medicine was the arthroscope; the second is going to be this!”

–James R. Andrews, MD USA

Introduction

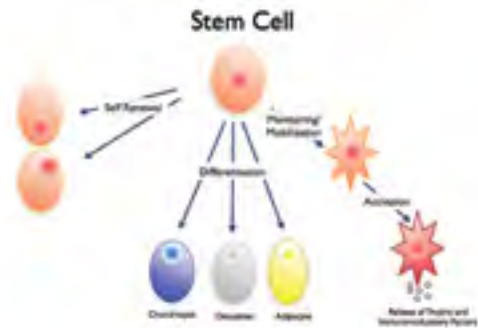
As the orthopaedic sports medicine profession was excited about the arthroscope in the 1970’s and 1980’s, today excitement has centered and remained upon biologic therapies, mainly stem cell treatments. While the arthroscope developed in the hands of clinical pioneers, biologics have developed at the hands of basic scientists, beginning with bench-top laboratory studies and pre-clinical animal trials. These studies have clearly illustrated the promise of biologic treatments and guided us as clinicians to pursue clinical implementation in sports medicine. However, the translational step from bench to bedside has proven an enormous hurdle, and for the majority of clinicians progress has stalled at this step. While government regulation had little involvement in the development of the arthroscope, it will continue to control and mold the progress of stem cell technologies. The impetus to prove safety and efficacy of stem cell therapies prior to clinical implementation is a current, necessary roadblock, which the orthopaedic community must overcome.



01

What Are Stem Cells

The two cardinal properties of stem cells are the ability to self-renew and the ability to differentiate into distinctive end-stage cell types. The work of Caplan and colleagues captured our early attention, with mesenchymal stem cell differentiation into a number of different cell types of orthopaedic interest i.e. cultured cells from bone marrow can be differentiated into chondrocytes, adipocytes, or osteocytes (Fig. 1). Our latest attention has been captured by the additional abilities of these cells to mobilize, monitor, and interact with their surrounding environment (Fig. 2). In response to their environment, stem cells are able to release a broad spectrum of macromolecules with trophic, chemotactic, and immunomodulatory potential, which allows them to participate in injury response, tissue healing, and tissue regeneration (Fig. 3). These cells are innate to the body’s maintenance, repair, and stress response systems. Basic science and animal study has illustrated the potential of cells with stem potential regardless of their environment / source of harvest, and the interplay of cells based upon the environment in which they reside is not fully understood.

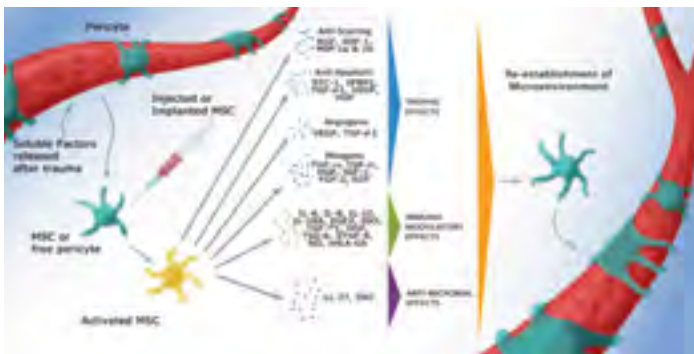


02

Where Can We Get Stem Cells

Cells with stem properties are present in many environmental niches, including the bone marrow, circulatory system, adipose tissue, synovial tissue, muscle tissue, and tendon tissue. From bone marrow two cell types with stem properties, the hematopoietic stem cell (HSC) and the perivascular stromal cell (PSC) can be aspirated from their natural niche. The interplay, interaction, and superiority between these two cell types, is complex and incompletely understood (Fig. 4). When bone marrow is aspirated for culturing purposes, it is unclear which cell line produces the plastic-adherent multi-potential cells grown in culture, which are often referred to as mesenchymal stem cells (MSC). Some researches propose that PSC and MSC are derived from HSC, and that HSC may support innate regeneration of the majority of cells in our bodies. All three of these cells have stem properties and have been shown to differentiate to tissues of orthopaedic interest.

Current clinical utilization of these cell types by the orthopaedic community primarily utilizes point of care bone marrow aspiration and concentration, while the hematology oncology community mobilizes these cells from the bone marrow to the blood stream with pharmaceutical agents and harvests HSC via apheresis. Bone marrow aspiration produces variable numbers of stem cells, with studies ranging from one stem cell per mL of tissue collected to 300 thousand stem cells per mL of tissue collected. Mobilization and apheresis can produce large volumes of peripheral blood derived cells with 600 thousand HSC per mL and 2.32 million PSC per mL of tissue collected.



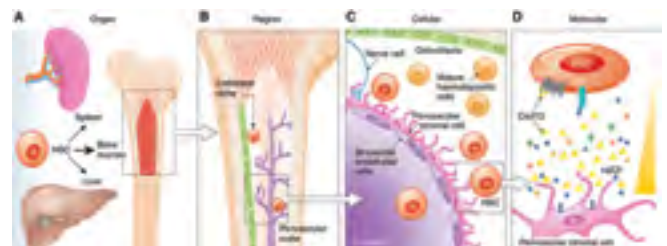
03

In adipose tissue, cells adherent to the abluminal side of blood vessels known as pericytes also carry stem qualities. Aspiration and processing of adipose tissue can access these stem cells, producing a product often referred to as stromal vascular fraction (SVF). Processing of lipoaspirate to create stromal vascular fraction requires mechanical or enzymatic processing. This produces variable numbers of stem cells, with quantitative studies ranging from 5 thousand to 1.5 million stem cells per mL of tissue collected. Similar to adipose derived stem cells, synovial derived and muscle derived stem cells also require mechanical or enzymatic processing. For applications where it is believed that a large numbers of cells is necessary, investigators often utilize culturing techniques for all sources with the exception of mobilization and apheresis harvest. As clinicians, three challenges have proven more important than which cell type to utilize:

1. patient-care logistics regarding collection and application
2. the undefined dose-response curve regarding stem cell treatments
3. government/community regulation.

Regulation of Stem Cell Therapies

Regulation of stem cell technologies is important for clinicians interested in the translation step into clinical practice. Regulation presents a double edge sword for developing technologies. While loose regulation encourages clinical application and experimentation, patient safety and efficacy concerns are raised. Tight regulation temporarily hampers clinical progress yet ensures the proof of safety and efficacy prior to widespread implementation. The two benefits of patient protection and proof of value are worthwhile to appropriately advance stem cell technology to established clinical techniques. Within the United States, the Food and Drug Administration has intervened in the ability of clinicians to utilize stem cell therapies in humans, including warning letters to multiple clinics. The basis for intervention has been the interpretation of stem cell therapies as high-risk biologic treatments. The US FDA dichotomizes biologic therapies into low-risk and high-risk therapies based primarily on the principles of minimal manipulation and autologous use. It also considers whether the product represents a tissue combined with another product and whether the tissue is utilized in a fashion homologous with its original function. If a biologic does not meet these criteria, then the FDA requires that a treatment proceed through a developmental process outlined/observed by the FDA, which is similar to a the developmental process for a pharmaceutical. The developmental process involves pre-clinical animal trials and phases of clinical study prior to offering the treatment in the normal scope of clinical practice (Fig. 5). The FDA has recognized little no stem cell treatments as low risk products which has set a significant hurdle for stem cell technologies in the United States. The FDA has not moved to regulate the point of care use of bone marrow aspirate or platelet rich plasma.




04

- 01 The differentiation process outlining the progression of multiple tissues from one stem cell source. (figure from Caplan. J Orthop Res. 1991)
- 02 Stem cells carry the cardinal properties of self renewal and multipotentiality but also have the ability to mobilize, monitor their environment, and affect their environment upon activation.
- 03 Stem cells have the potential to release a broad spectrum of macromolecules, allowing them to participate in injury/stress response and tissue maintenance/repair/healing. (figure from Murphy. Exp Mol Med. 2013)
- 04 The hematopoietic stem cell predominantly resides in the perivascular and endosteal niches of the bone marrow but also can be found in the peripheral circulation, liver, and spleen. Within the bone marrow, molecular interaction between the hematopoietic stem cell and perivascular stromal cell is important for tissue maintenance and stem cell mobilization. (figure from Ugarte. EMBO J. 2013)

Stem Cell Updates in Sports Medicine

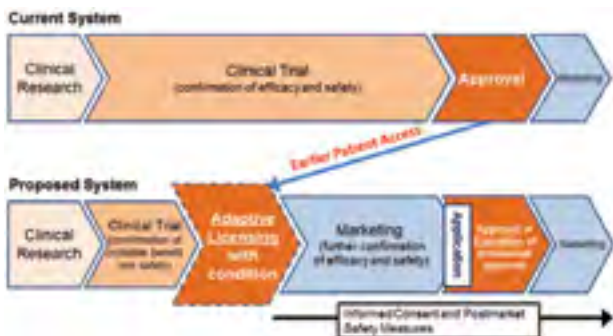Some countries have mirrored the FDA with tight regulatory mechanisms, some countries have no established regulation, and a few countries have established modern regulatory mechanisms aimed at the promotion of conscientious development. The governments of South Korea and Japan are examples which have taken a proactive stance on stem cell therapy regulation. While Japan has a similar pharmaceutical drug pathway as the United States, they recently have labeled stem cell technologies as “regenerative medicine products,” setting them apart from pharmaceuticals. A newly proposed approval system for these products allows early observed commercialization with further approval contingent upon studies confirming safety and efficacy (Fig. 6).



05

Bone Marrow Aspiration

While the regulation of the majority of stem cell technologies has hampered their clinical application, bone marrow aspiration has remained unregulated and a growing body of evidence supports clinical application. The stem cell concentration of bone marrow aspirate is technique dependent, declines with age, and has been found to be an important factor for clinical benefit. While it is possible to aspirate from multiple sites, posterior iliac crest harvest produces the highest stem cell yield. Philippe Hernigou has outlined safe zones for trocar placement and illustrated that strong aspiration with small volume syringes, 10-mL syringes, optimizes stem cell harvest. Additionally, his studies involving tibial non-union, avascular necrosis of the femur, and augmentation of rotator cuff repair are guideposts to clinicians utilizing bone marrow aspirate. We utilize bone marrow aspirate in cases where there is concern regarding the healing potential or time of recovery (Fig. 7).



06

Update in Cartilage

The study of stem cell technologies within the realms of cartilage repair and the symptomatic treatment of cartilage degeneration is vast. In-vitro, bench-top studies and in-vivo animal studies have guided progress. In one of the earliest animal studies, bone marrow derived cultured stem cells embedded in a collagen I gel differentiated into chondrocytes by the 2-week time point. Animal models involving scaffolds and scaffold-less models have both illustrated promise and have led to competing theories. Carboxyfluorescein labeling studies suggest that stem cells have natural homing mechanisms when injected in the setting of cartilage injury. Cell differentiation toward the chondrocyte lineage prior to application is not necessary.

A number of cartilage repair techniques involving stem cells are in the early phases of clinical development. A scaffold-less model involving the augmentation of arthroscopic subchondral drilling with multiple stem cell injections has histology supporting a high quality of repair tissue and Level II data suggesting superiority to subchondral drilling alone. This technique utilizes mobilized hematopoietic stem cells harvested by apheresis and cryopreserved for multiple injection time points. The time point can be spread over the entire cartilage maturation timeline, out to 18 months. Further, randomized controlled study is underway. Another cartilage repair technique utilizing adipose stem cells in a fibrin glue scaffold to augment microfracture, recently reported a comparative study to microfracture alone. The stem cell group illustrated superiority in certain KOOS subsets and MRI evaluation; similar structural repair tissue was seen upon histologic evaluation. A model involving cultured bone marrow derived stem cells has also been developed and compared to first generation autologous chondrocyte implantation (ACI). Authors first studied an open method with a periosteal patch for implantation with similarity to ACI upon study. A second follow-up study compared a scaffold-less model involving arthroscopic microfracture and one postoperative injection illustrated superiority to the open method. Removing a deforming force, such as varus, with high tibial osteotomy has shown powerful in combination with these stem cell technologies. Tissue engineering of cartilage utilizing synovial mesenchymal stem cells has also progressed with pilot human clinical trials currently underway.

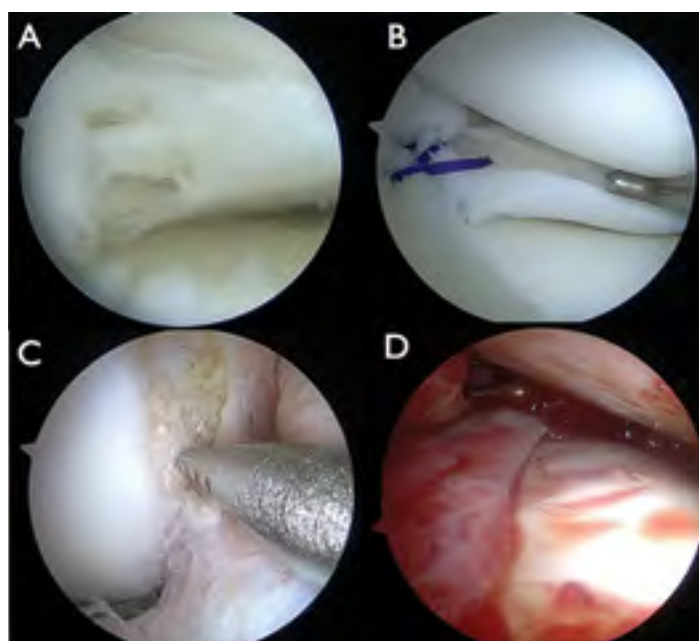
Update in Ligament Reconstruction

While evaluation of stem cells to augment cartilage repair has progressed to clinical study, evaluation regarding the augmentation of ligament reconstruction, repair, and healing remains predominantly in pre-clinical animal evaluation. Animal studies evaluating the stump tissue left after ACL injury has revealed the presence of vascular derived stem cells. Incorporating the stump tissue itself into soft tissue ACL grafts in animal study has illustrated higher strength and enhanced vascularization of reconstruction.

Cells isolated from the graft, cultured, and applied with a carrier sheet to a graft have illustrated the ability to enhance incorporation in animal study. A carrier sheet has become the interest of bio-enhancing repair and reconstruction, with pilot studies underway in humans. Studies utilizing a carrier sheet loaded with whole blood, cultured adipose stem cells, and cultured lymphocytes/monocytes suggested that whole blood may be sufficient to load such a scaffold. Animal study in MCL healing has illustrated that mobilized hematopoietic stem cells augment neovascularization and the strength of healing tissue. Mobilized hematopoietic stem cells provide a unique opportunity for multiple injection options (Fig. 8).

Update in Meniscus Repair

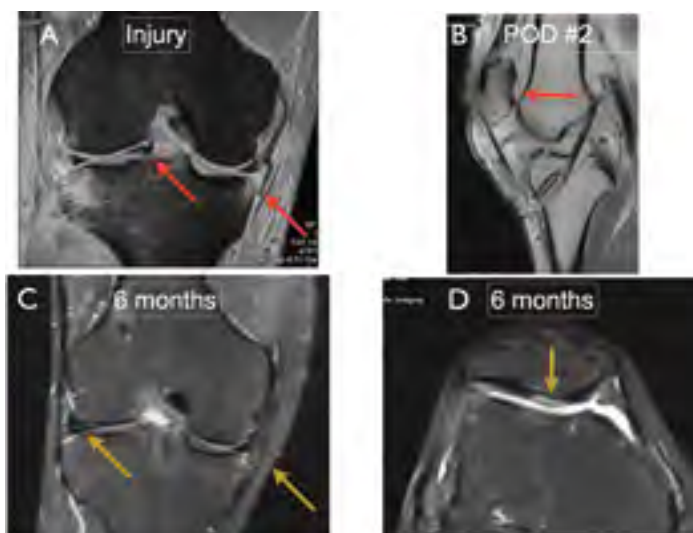The healing potential of the meniscus is limited by the articular environment and its peripheral-based vasculature. Biologic augmentation of meniscus repair has been investigated in animal study: the creation of vascular access channels, synovial abrasion, and marrow stimulation of the intercondylar notch improve healing potential. Pre-clinical animal studies involving stem cell technologies have also illustrated their potential to improve the quality of tissue regeneration and repair tissue integration. Similar to cartilage studies, labeling studies involving the meniscus and stem cells have also suggested an innate homing mechanism of cells and that undifferentiated cells may be best in the setting of meniscus repair. These animal studies have involved cultured cells, and translation to human clinical practice has not been achieved. One randomized trial has supported the use of an allograft, stem cell injection to improve clinical outcomes after partial meniscectomy. This trial illustrated improvement in knee pain and meniscal tissue integrity in the stem cell group.



07

Conclusion

The future of stem cell treatments hinges upon the creation of new favorable regulatory mechanisms which will promote clinical application, while ensuring that safety and efficacy milestones are reached. Clinical researchers require freedom to develop these technologies while protecting patients and ensuring the validity of treatments. The coordination of research and regulatory affairs on a global level is necessary focusing on the harmonization of guidelines, regulations, and mechanisms for simultaneous adoption in different countries. The global orthopaedic community has made strides regarding the science of stem cell technologies; it is time for us to initiate progressive change regarding regulation so that we can determine what is effective clinically.



08

- 05 The US FDA dichotomizes stem cell therapies into high risk and low risk therapies based upon the principles of minimal manipulation, autologous, non-combination product, and homologous use.
- 06 A new pathway has been proposed in Japan creating earlier access to stem cell technologies while confirming safety and efficacy. (figure from Stem Cell Therapies: Opportunities for Ensuring the Quality and Safety of Clinical Offerings. National Academies Press (US); 2014)
- 07 A. A complete radial lateral meniscus tear in a 19 year old with lateral joint pain upon activity and sport.
B. The meniscus was repaired in an outside-in fashion
C. Marrow stimulation at the intercondylar notch to augment repair was performed.
D. The joint was dried, and a bone marrow aspirate concentrate laden fibrin clot placed at the repair site.
- 08 A. 21 year old with complete tears of anterior cruciate ligament (ACL) and medial collateral ligament (MCL) as well as a bucket handle lateral meniscus tear (red arrows) and cartilage defect of the central patella.
B. Surgically, he was treated with ACL reconstruction, medial meniscus repair, and arthroscopic marrow stimulation of the cartilage defect (red arrow). Over the following 18 months after surgery, he received 20 injections of mobilized, cryopreserved hematopoietic stem cells intra-articularly for cartilage repair and 3 injections percutaneously to the MCL.
C/D. Postoperative MRI at 6 months, yellow arrows highlight the remodeling MCL, the meniscus repair site, and the cartilage repair site. (Case courtesy of Dr. Khay Yong Saw)

Injection Therapy for Tennis Elbow



Renée Keijsers, MD
Amphia Hospital Breda
Utrecht, NETHERLANDS

Additional Author:
Denise Eygendaal, Prof., MD, PhD NETHERLANDS

Introduction

Tennis elbow (TE) or lateral epicondylitis is a condition that causes pain on the lateral side of the elbow involving the Extensor Carpi Radialis Brevis (ECRB) in 95% of all cases. It is a common condition with an estimated prevalence of 1–3% and the incidence rate is estimated to be 4–7 per 1000 patients per year. The incidence of LE seems independent of sex and ethnical background and only age influences the incidence with the highest incidence between 40–50 years. Patients experience many limitations in their daily lives and because LE is a disease that is associated with patients in working age, it often results in absenteeism with prolonged sickness absence in 5% and a median sickness absence of 29 days. It's therefore not only a disturbing condition, wherein the dominant arm is affected in 75% of the cases, but it also involves high costs. The golfer elbow, or medial epicondylitis, is 8 times less common than Tennis elbow.

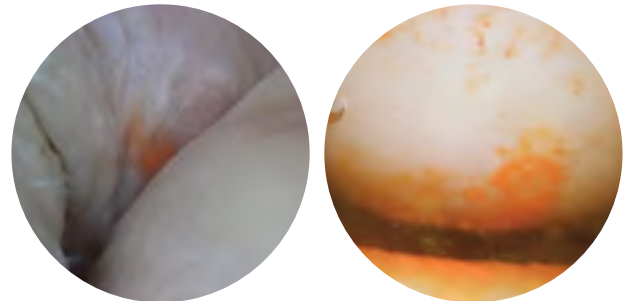
Etiology and Pathophysiology

The name Tennis elbow incorrectly suggests that it is a sports related injury instead of a work related injury. During their sports careers 50% of all tennis players will get a tennis elbow but only 5% of all TE patients play tennis. The actual pathophysiology of tennis elbow is still not completely understood but high physical demands, smoking, and obesity are strong determinants of lateral elbow pain. The current consensus is that repetitive trauma results in lesions and an abnormal vascular reaction in the common extensor tendon. The tendinous origin of the extensor carpi radialis brevis is universally involved, although the tendinous origins of the extensor carpi radialis longus and the extensor digitorum communis can also show pathologic changes. Microscopic evaluation of involved tissue shows proliferation of fibroblasts and ingrowth of new blood vessels. Although the suffix –itis suggests inflammation, inflammatory cells are absent in most studies. Therefore, the term lateral epicondylitis is also debatable.

That is probably the reason that Tennis elbow is known by many other synonyms, such as epicondylalgia, tendinopathy or tendinosis and these terms might therefore be more appropriate. Because Tennis Elbow is well known, we have decided to continue to use this term.

Disease Course

It is important to realize that in most cases TE is a self-limiting condition; with 80% resolving in 6 months and 90% resolves after 1 year with a wait-and-see policy and avoidance of aggravating activities. Therefore, it is not necessary to intervene directly. But despite this self-limiting character an effective treatment is needed in order to shorten the duration of symptoms and to reduce limitations in daily life and absenteeism from work. And there is also a group of patients with persistent symptoms after 1 year. These long term complaints have a poorer prognosis especially when the dominant arm is involved or when there is severe pain. It's also less favorable when the complaints recur or when it's accompanied by neck pain. Other negative predictors are work related stress (both physical and mental) and mental health status. There is also some evidence that suggest that patients with more positive attitudes toward their condition show more improvement in their coping status and use less medical resources.



01

Treatment Options

There is still no consensus on the optimal treatment of TE despite numerous randomized trials and systematic reviews. Several non-surgical treatment options are available such as physiotherapy, electroshock therapy, orthotic devices, acupuncture and injection therapy with different kinds of injectables. Because of the mostly self limiting character it is hard to compare the different options and large samples are required in order to demonstrate any difference.

Injection Therapy

What to inject?

Injection therapy is very common in the treatment of TE. Currently, different injectables are used without proper scientific evidence; RCTs on injectables in LE are inconclusive and sometimes conflicting. A meta-analysis by Krogh et al found a paucity of evidence from unbiased trials on which to base treatment recommendations for LE.

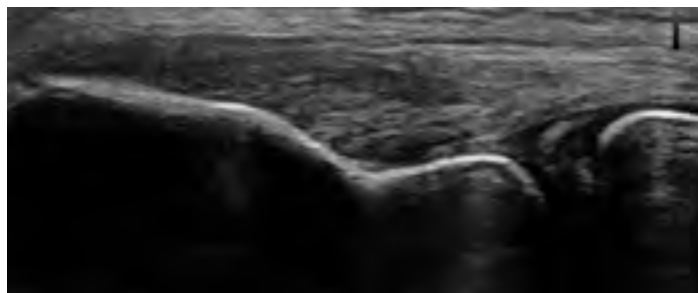
However, this meta-analysis showed that perforation with application of autologous blood and prolotherapy (injection with dextrose) were all more efficacious than placebo. Also, these injectables seemed to be more effective after six weeks than corticosteroids.

Since the 1950's glucocorticoids are being used. Nowadays several studies have shown that there is no long-term benefit. It is also known that on the long term steroid injections could even worsen symptoms compared to wait and see and therefore its use should be reduced to a minimum. Despite this knowledge, steroid injections are still frequently used in daily practice, particularly in general practice. And even in the scientific field several studies are still being conducted comparing the effect of treatment with steroid injections, in the view of the current literature this is very remarkable. Use is only conceivable, when a quick relief of pain is required, for example, in athletes just before an important game. The poorer prognosis in the long term should be taken into account.

New injectables have become available in the past 10 years. Very popular are the ones focusing on the use of growth factors such as autologous blood and Platelet Rich Plasma (PRP). PRP is an autologous blood product in which the platelets have been concentrated. These injectables contain platelets with growth factors that may help in the healing process of chronic injuries. The hypothesis is that these growth factors could enhance tendon healing and tissue regeneration by stimulating angiogenesis and cell proliferation. There are different types of PRP available with a lot of variation in platelet concentrations, other blood components and preparation methods and the optimal preparation has yet to be determined. Given the variety it is difficult to compare them, and varying results are seen. Studies suggest that autologous blood and PRP may be of benefit, but the current evidence is limited. There is need for standardization of PRP preparation methods and standardization injection technique.

Injection therapy with application of dextrose is a common treatment in chronic musculoskeletal pain including TE. Animal model studies suggest that the treatment by perforation with application of dextrose may enlarge and strengthen ligament and tendon insertions. However, the precise mechanism is unclear. Hyaluronic acid is a biological polysaccharide and is a major component of synovial fluid. Its therapeutic effect and safety have been reported for soft tissue use in acute ankle sprain and it might be effective in the treatment of TE as well.

The effect of botulinum toxin injections have been assessed by a few randomized controlled trials, with conflicting results. The mechanism for relief of pain is paralysis of extensor muscles, preventing further micro trauma to the tendon origins and allowing healing to occur. All trials reported temporary side effects with transient paresis or weakness in the wrist or in finger extension. With the current literature, there is not enough evidence to justify the use for the treatment of TE.



02

How to Inject?

The current debate on any study related to injectables for LE is that in most studies the perforations are performed manually and 'blindly' without ultrasound guidance and it is therefore difficult to determine the exact location of the injections. Moreover the number of perforations in the tendon as well as the amount of fluid released with each infiltration is not described in most studies. Proper comparison of injectables for LE is therefore questionable. Since in more than 95% of all cases of LE the Extensor Carpi Radialis Brevis (ECRB) is involved, the injections should be directed to the humeral insertion of this tendon. This debate is supported by a recent study on injection accuracy; 10 orthopedic surgeons and residents were asked to perform an injection on a cadaver arm as they would do in the treatment of LE. The study reported that 70% of the participants missed the ECRB tendon while two-thirds of the injections were (at least partial) located intra-articular. These results support the notion that studies that compare the effectiveness of injectables should be performed in a standardized way by ultrasound guidance. This overcomes bias due to manually performed injection therapy (Fig. 1).

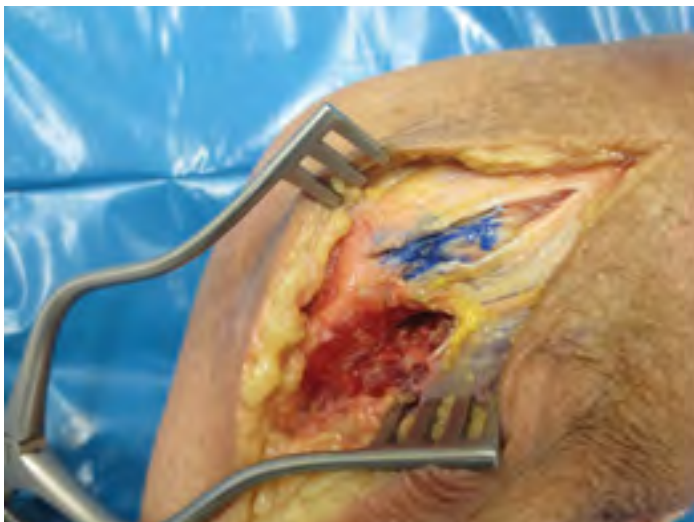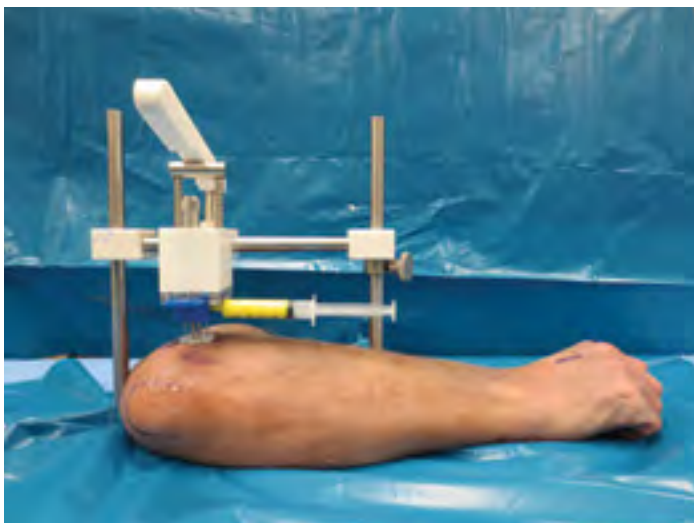
Recently, a device (ITEC; Instant Tennis Elbow Cure. ITEC Medical, Enschede the Netherlands) has been developed to standardize the injection technique for TE. This device can perform percutaneous and reproducible perforations with application of an exact amount of fluid and is equipped with a set of 12 (3x4) disposable needles, which are positioned based on anatomic landmarks of the elbow. Before perforation an ultrasound-guided localization and depth measurement of the affected ECRB tendon should be performed (Fig. 2).

- 01 Arthroscopic images of the intra-articular dye. On the left: a little, on the right: a lot
- 02 Left: ultrasound image of the ECRB tendon. Right: schematic view ECRB tendon and depth M1. ULTRASOUND ECRB TENDON

Injection Therapy for Tennis Elbow

A cadaveric study on the accuracy of this ITEC device reported that injections with the ITEC device are accurate, with all injections localised at the ECRB tendon. For this study 10 cadaveric arms were infiltrated with acrylic paint by both a junior resident and a senior orthopaedic surgeon. Afterwards, an arthrotomy and dissection of the elbow was performed. The accuracy of the injections was not altered by experience (Fig. 3).

A pilot study of 25 patients with TE demonstrated no side effects or complications after standardized perforation of the ECRB by the ITEC-device. Therefore, ITEC appears to be suitable to use in future studies to compare different injection therapies in a standardized manner.



03

Another point of discussion is the number of perforations. Besides the potential effectiveness of the injectables, it is hypothesized that by multiple perforations of the tendon the needle is used to either break up scars or poke holes in the injured tendon so that bleeding occurs. The blood cells carry precursors, which eventually develop into collagen to replace the damaged tendon. This was first described as “peppering technique” in the 60’s, whereby multiple perforations of the tendon were delivered by one perforation of the skin (by withdrawing without exiting the skin, repositioning, and perforating again). Several studies on this peppering technique suggest that injection technique might be more important than the substance injected.

In addition, it’s also questionable how much fluid needs to be injected. It is conceivable that injections should ideally be enough to infiltrate throughout the whole affected tendon and thereby to infiltrate as little as possible of the non-affected tissues. To answer this question we experimented on cadaveric tendon tissue and perforated the tendon with a set of 12 (3x4 needles) and infiltrated with different solutions and amounts of acrylic dye. It appeared that only 0.4cc of fluid was needed to infiltrate the whole tendon. This effect is likely to be influenced by the viscosity of the injected fluid and the characteristics of the tissue. However this is not a controlled trial, it suggests that not much fluid is needed to obtain adequate tissue perfusion. By taking this into consideration when injecting patients, unnecessary damage to surrounding tissue might be avoided.

Another issue is the timing of the injections. Ideally, the treatment should take place in the initial stage in order to prevent aggravation of symptoms. But given the self-limiting character of TE it is hard to find the most beneficial timing for treatment. Early injection therapy also results in overtreatment of the condition. As long as there is no more knowledge on this subject, it seems logical that this decision should be made by the health care professional. The aim should be to treat as minimally invasive as possible whereby the severity of the complaints and consequences for the patient should be taken into account.

Conclusion

It is still not known which injection therapy is most effective in the treatment of Tennis Elbow. To solve this problem, future studies on the effectiveness of injectables should be conducted in a standardized manner in order to be able to compare results. Some injectables are potential beneficial, but more research is needed. Also the injections technique seems to be relevant. For an accurate injection at the origin of the ECRB tendon it is recommended to use ultrasound guidance because manually performed injections lacks accuracy.

03 Study setup and dissection of the elbow and arthrotomy.

Journal of ISAKOS

Joint Disorders & Orthopaedic Sports Medicine



Authoritative. High quality. Evidence based.

Clinical developments in orthopaedic sports medicine have accelerated in recent years. *Journal of ISAKOS (JISAKOS)* helps orthopaedic surgeons, and relevant specialists, stay current on the latest research and evidence-based guidelines, including understanding the different approaches to diagnosis and intervention around the world.

State of the Art and systematic review articles provide the best evidence for diagnosis and treatment, the pros and cons of various alternatives and future perspectives of the field. *JISAKOS* not only covers how patients respond to treatments, but how findings translate into practical application.

***JISAKOS* synthesizes current research in orthopaedic sports medicine to provide an expert guide to treating and managing patients.**

Features include:

- **Expert reviews:** Authors are invited and papers are peer-reviewed
- **Timely updates:** The latest content publishes continuously online
- **Global representation:** International editorial board members, authors and peer reviewers reflect diverse patient populations, healthcare systems and clinical preferences
- **Historical perspective:** Invited papers called "The Classic" provide a historical approach to major concepts or ideas, with abundant references to literature
- **Outcome measures:** Validated outcome measures (including PROMs) and classifications, presented in easy-to-read tables
- **Practical application:** Clinically-relevant reviews assist readers in their daily clinical practice

Visit the journal website today!
jisakos.bmj.com



BMJ

Bone Defects in Revision Total Knee Arthroplasty



Marco Kawamura Demange,
MD, PhD
BRAZIL

Introduction

As the number of primary total knee arthroplasty (TKA) procedures performed annually increases, it is expected that the revision TKA burden will also increase. Handling bone loss at the time of revision surgery is a major challenge, and a systematic approach is required for effective treatment and obtaining reproducible clinical outcomes.

Before Surgery

Pre-operative evaluation begins with a comprehensive history and physical examination. Specific questions regarding difficulty negotiating stairs, standing from a seated position, or feeling of the knee “giving out” can assist in the diagnosis of mid-flexion or flexion instability. The lack of a pain free interval following the index procedure, persistent wound drainage, or the presence of constitutional symptoms increases the suspicion for peri-prosthetic infection

Painful knee replacements should have laboratory tests, which include a serum erythrocyte sedimentation rate and C-reactive protein. Elevated serum inflammatory markers should prompt a pre-operative knee aspiration. Equivocal patient scenarios may benefit from synovial fluid analysis for Alpha Defensin, which has been reported to demonstrate 98% sensitivity and 100% specificity for the diagnosis of peri-prosthetic infection.

Routine weight-bearing anteroposterior (AP) and lateral view radiographs as well as a merchant view should be obtained. The AP and lateral views allow for evaluation of component fixation, size, and degree of bone loss. The merchant view demonstrates component fixation and patellar tracking. Full-length extremity AP radiographs are helpful in determining the presence of diaphyseal deformities, the status of the ipsilateral hip joint, the presence of peri-articular hardware, and the overall limb alignment. Oblique radiographs can enhance visualization of early osteolytic lesions, especially in posterior stabilized implants. These lesions are difficult to identify due to metallic artifact, and typically underestimate the degree of bone loss encountered intra-operatively.

Pre-reconstructive Surgical Steps

Component Extraction Techniques

Femoral component is removed first to facilitate tibial component removal. It is imperative to spend adequate time making sure the implant is loose prior to removal. Premature removal of the component can result in iatrogenic bone loss, making the reconstruction more difficult.

Similar principles are used for removal of the tibial component. A combination of an oscillating and reciprocating saw blade, as well flat osteotomes, can be used to disrupt the cement-implant interface. An adequate medial release allows knee flexion and tibial external rotation, rendering access to the posterolateral portion of the component, the most common location in which iatrogenic bone loss occurs during removal.

A well-fixed, well-functioning patellar component can be retained. However, in the setting of a peri-prosthetic infection, the patellar component must be removed.

Knee Bone Loss Classification

Currently the most widely used classification is the Anderson Orthopedic Research Institute (AORI) classification, which categorizes bone defects into three principle types (Table 1).

Type 1 has intact metaphyseal bone with cavitory cancellous defects without affecting the cortical bone. Most of type 1 defects can be treated with cement or metal augmentation. Type 2 defects have significant metaphyseal bone loss and are subdivided into two categories: 2A defects affect only one of the femoral condyles or tibial plateaus and 2B defects involve both condyles or plateaus. Typically, type 2 defects require the use of metal augments, morcelized or structural allograft reconstruction. Type 3 defects have severe bone loss that compromises a major portion of the condyle or plateau, occasionally affecting ligaments or tendon insertions. Management of these defects typically requires the use of metal augmentation in conjunction with structural allograft, cones/sleeves or a modular oncology prosthesis.

Intra-operative Evaluation of Bone Loss and a Systematic Approach to Reconstruction

Bone loss encountered intra-operatively is often greater than expected based on pre-operative radiographic analysis. Assessment of iatrogenic bone loss can be quantified by examining the components that have been removed; ideally, minimal additional bone loss should occur during the removal process. Following component removal, a systematic approach is important for properly identifying bone loss patterns.

Start assessing the integrity of the femoral epicondyles. If the epicondyles are not present or significantly affected, a higher constrained device is indicated (rotating hinge or modular segment replacement), as the integrity of the collateral ligaments has often been compromised. Following epicondylar evaluation, next assess the amount of residual distal bone stock. Distal bone loss can be estimated considering the distance from the epicondyles to the joint line - 25mm and 30mm from the lateral and medial epicondyle, respectively.

Bone loss between 10 mm and 25/30 mm typically require the use of a more robust construct such as tantalum cones, metaphyseal sleeves or bulk structural allografts. Distal defects less than 10 mm with mild associated metaphyseal bone loss can be treated with cement +/- screws, morcelized graft and/or metal augments.

Estimation of tibial bone loss begins with evaluation of the integrity of the tibial tuberosity. The involvement of tuberosity bone loss may result in a non-functioning extensor mechanism, which requires maximal constraint (e.g. rotating hinge or proximal tibial replacement). Using the fibular head as a reference (typically 15 mm distal to the joint line), the depth of bone loss can be assessed. Defects greater than 10 mm with significant metaphyseal loss may require tantalum cones or structural allografts. For defects less than 10 mm with mild metaphyseal bone loss can be treated with cement +/- screws, morcelized impaction grafting and/or metal augments.

Implant Selection

Implant selection in revision TKA should be based on the reliability of the collateral ligaments, degree of bone loss, and the integrity of the residual host bone stock. Revision implant designs are generally categorized as posterior stabilized, unlinked constrained, rotating-hinge, and modular segment replacement. Posterior stabilized prostheses are indicated for patients with intact collateral ligaments without varus-valgus instability. This system necessitates that host soft-tissues are able to provide coronal stability.

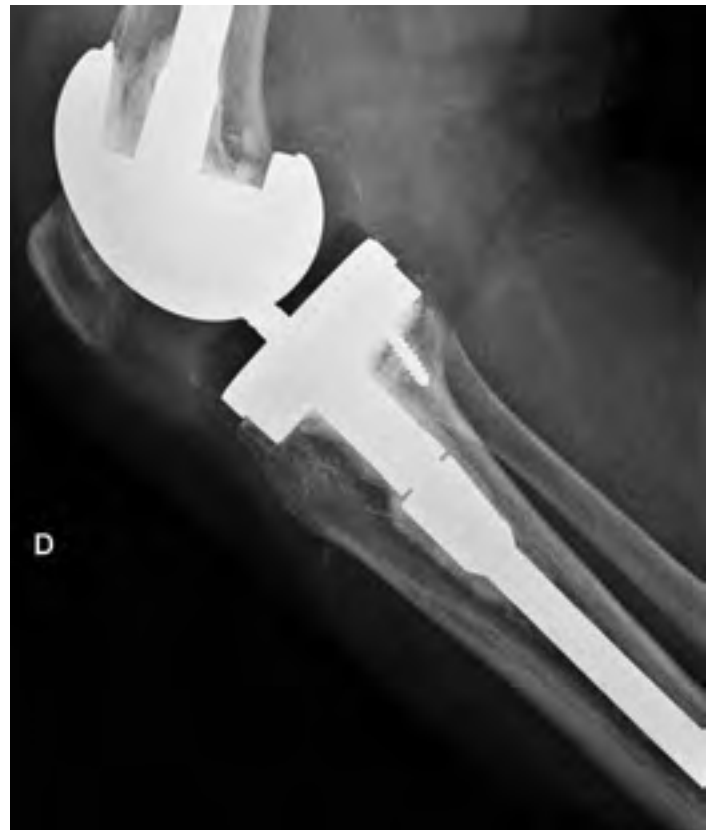In the presence of mild to moderate varus-valgus instability, a higher degree of constraint should be used. The unlinked constrained designs constitute a taller and thicker polyethylene intercondylar post (TC3, Depuy, Warsaw, IN, USA and CCK, Zimmer, Warsaw, IN, USA), which limit rotation, medial-lateral translation and varus-valgus angulation. Advantages of this design are the possibility to change the center of rotation during flexion and theoretically result in less tangential anterior-posterior stress across the prosthetic-bone interface. Additionally, the design allows the soft tissues to absorb hyperextension forces. Alternatively, it experiences a greater degree of torsional stress at the fixation interface.

Rotating-hinge prostheses are indicated in cases of severe bone loss with compromise of the collateral ligament insertions, an incompetent extensor mechanism, or severe flexion-extension mismatch. When bone loss becomes too severe, and standard reconstruction is not feasible, the use of a modular segment replacement device is indicated. Both of these highly constrained devices are attractive options for sick, elderly patients that exhibit lower demand and can benefit from rapid rehabilitation.

Reconstructive Techniques - Available Options for Treatment of Bone Loss

Cement and Screws

The use of cement for bone loss is reserved for defects that are typically less than 5 mm and less than 50% of the bone surface area. Cement can be used in conjunction with cancellous screws (4.5 mm), for defects between 5 mm and 10 mm, to enhance load transfer from the prosthesis to the underlying bone (Fig. 1). The screws should be inserted ensuring that the screws heads are slightly below the level of the implant.



01

Bone Defects in Revision Total Knee Arthroplasty

Morcelized Allograft

The use of impaction grafting of morcelized allograft was first described and well established in revision total hip arthroplasty. This technique has been modified for use in revision TKA theoretically enabling restoration of bone stock, especially in young patients in whom future surgeries should be anticipated. Other advantages are cost-effectiveness and ability to accommodate the defect shape. Disadvantages associated with the procedure are the technical difficulty, risk for intra-operative fracture, disease transmission, infection, and graft resorption.

The surgical technique requires careful debridement of the defect. Contained defects can be treated immediately, while uncontained defects require wire mesh augmentation prior to grafting. A trial stem should be positioned in the femoral or tibial medullary canal, prior to firmly impacting cancellous graft with a mallet and tamps into the defect. The trial stem is removed and the final component is cemented in place.

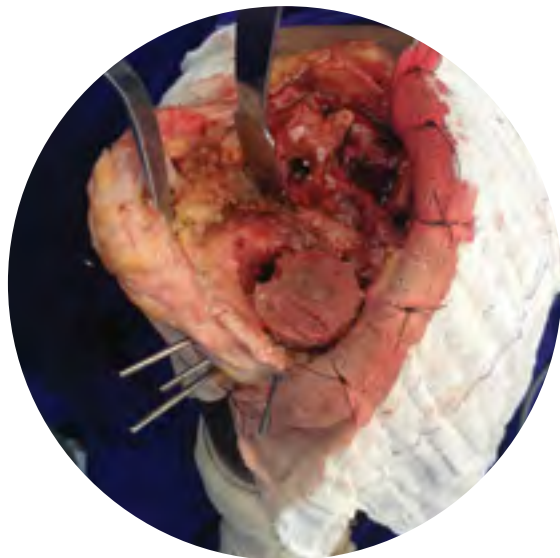Bulk Structural Allograft

Structural allografts have been used for a long time in revision TKA. The use of bulk allograft allows for accommodation of different shapes and sizes of bone defects. Advantages of this technique yield good initial support of the prosthesis and theoretically the possibility of restoring bone stock assuming incorporation of the graft. However, the disadvantages are prolonged operative time, non-union, delay union, graft resorption, graft infection and disease transmission.

Femoral head allograft is most commonly used in this setting. All cartilage must be removed prior to use, and an acetabular reamer can be used to prepare the host bone to receive the femoral head graft, while taking care to avoid reaming away cortical bone. The graft is provisionally fixed with kirschner wires inserted parallel to the joint line. Once the graft is stabilized an oscillating saw is used to roughly remove the part of the graft that protrudes above the borders of the defect (Fig. 2). The graft is definitely fixed with cancellous bone screws, and the definitive bone cuts are made. Additional cuts can be made for proper fit of the stems and components. Then the final components can be positioned.

Modular Wedges and Block Augments

Metal augments in different shapes and sizes are available for reconstruction of the femur and/or the tibia. These augments are typically indicated for uncontained defects between 5-10 mm. The use of augments is recommended when 40% or more of the bone-implant interface is unsupported by host bone, resulting in instability of the trial, or the periphery of the defect involves 25% or more of the adjacent cortex. The size of the augment corresponds to the size of the defect and the size of the implant. Angled wedge augments result in greater shear force at the implant-bone interface and are thus more susceptible to mechanical failure. Block augments may require further resection of host bone for accommodation, but exhibit better load transfer to the underlying host bone. Blocks have the advantage of immediate support without the need of consolidation or maturation, shorter surgery time and non-susceptible to absorption. Metal augments do not restore, but replace bone stock (Fig. 3).

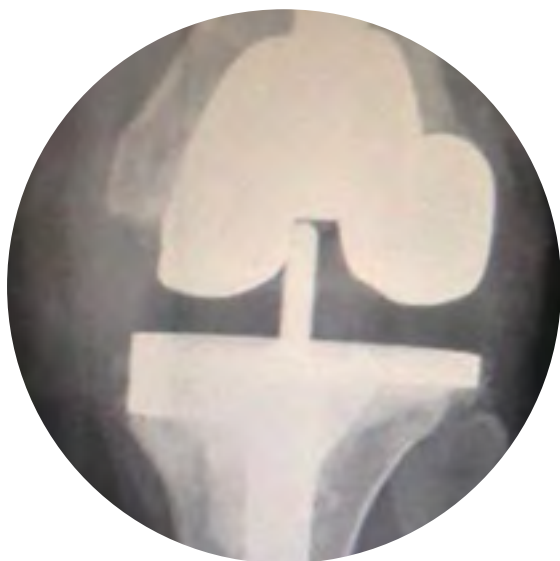

02

- 01 Radiograph in a lateral view of a revision TKA with screw for support, in the posteromedial tibial defect.
- 02 Intra-operative image of a reconstruction using bulk allograft. Femoral head allograft has been secured in place for reconstruction of the tibial plateau.

Porous Metal Metaphyseal Cones

Porous metaphyseal cones are a more modern option for the treatment of bone defects, addressing some of the problems associated with other techniques outlined above. This material does not only possess the potential for biological fixation, but can also fill large defects and provide immediately additional structural support. The use of porous metal cones obviates the concerns regarding disease transmission, graft resorption and graft fracture. The modular design of cones allows for defects of different sizes and shapes to be treated. The drawbacks associated with cones are that restoration of bone stock doesn't occur, additional native bone is typically removed to accommodate the cone and removal of these devices in the setting of peri-prosthetic infection can be challenging due to biologic fixation of the cone.



03

Mega-Prostheses

Mega-prostheses are systems that replace the entire distal femur or proximal tibia. These prostheses are indicated in cases of severe bone loss, typically encountered following chronic infection or multiple surgeries. The literature supports the routine use of this type of prosthesis for patients that are undergoing resection of a malignant tumor.

There are few studies that have evaluated the outcomes of mega-prostheses in the setting of revision TKA. When compared to cases of malignant tumor resection, clinical outcomes are comparable. However, the reported rate of infection in revision cases was 29.5% compared to 9.1% in the patients treated for a malignant tumor.

Summary

Addressing bone loss at the time of revision TKA is a challenging problem. Cautious removal of implants intra-operatively is critical to avoid further iatrogenic bone loss. A systematic approach, with a thorough understanding of the available reconstruction options, allows for the surgeon to adequately treat the defects and achieve reproducible clinical outcomes.

Table 1

Type	Description
1	Minor and contained cancellous bony defects
2	Damage to metaphyseal bone, loss of cancellous bone in the metaphyseal segment A. One femoral condyle or tibial plateau B. Both femoral condyle or tibial plateau
3	Deficient metaphyseal segment, bone loss that comprises a major portion of the condyle or plateau

03 Radiograph of a metal block augment for the treatment of a medial tibial defect.

Technical Pearls for Open Wedge High Tibial Osteotomy



Betina B. Hinckel, MD
Universidade de São Paulo
São Paulo, SP, BRAZIL

Additional Author:
Annunziato Amendola, MD USA
Andreas H. Gomoll, MD USA

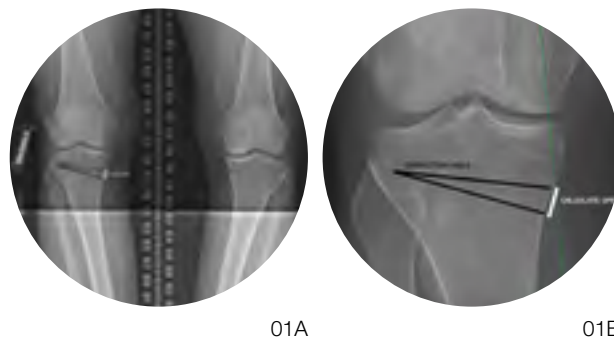
High tibial osteotomy (HTO) is an established, effective method of altering the biomechanical axis of the lower extremity. It is considered when lower extremity malalignment greater than 3 to 5 degrees is associated with a focal chondral defect requiring cartilage repair, unicompartmental osteoarthritis (OA), meniscal deficiency, posterolateral corner injury with symptomatic varus thrust, or cruciate ligament injury (with failed primary ligament reconstruction). Contraindications include degenerative changes and/or meniscal deficiency in the contralateral compartment, inflammatory arthritis, limited motion (<90 degrees flexion, >15 degrees flexion contracture), tibial subluxation >1cm, obesity, smoking and osteoporosis.

Patellofemoral OA is a relative contra-indication and no strict guidelines exist. However, persistent anterior knee pain unresponsive to intensive patellofemoral strengthening, as well as the presence of extensive erosive changes in the patellofemoral joint, particularly when associated with significant subchondral edema, should caution against HTO.

Surgical Planning

Hip-to-ankle long leg weight-bearing radiographs are utilized for surgical planning. The patient should be standing comfortably with equal weight on both limbs to reproduce normal weight-bearing. The required correction angle is the angle between two separate lines drawn from the centers of the hip and ankle joints to the location on the tibial plateau that the mechanical axis is to be shifted to. The indication for osteotomy dictates the specific amount to shift the mechanical axis. For medial compartment osteoarthritis, it is recommended to shift the mechanical axis into the lateral compartment (62% of tibial width, Fujisawa point). For cartilage repair or ligamentous reconstruction, more active patients, however, neutralization (neutral or mild valgus, 0 to 3° valgus) rather than over-correction is preferred.

A practical way to plan is to overlay the correction angle onto the radiograph at the level of the osteotomy and the opening in mm can be measured after magnification correction (Fig. 1).

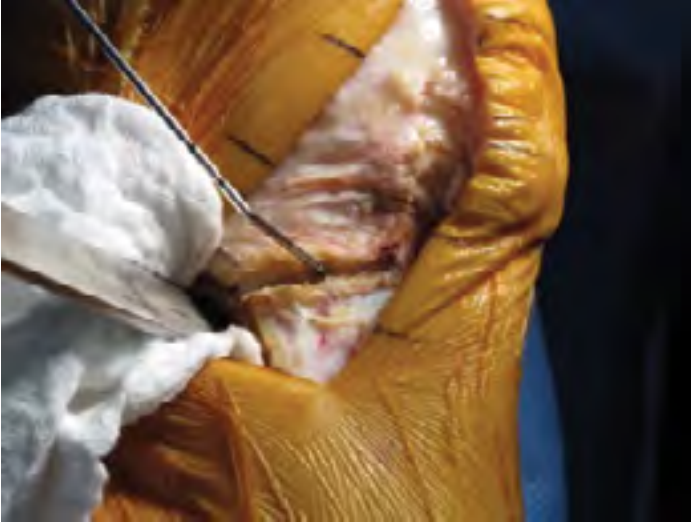

High Tibial Osteotomy Opening Wedge Technique

Fluoroscopic visualization of the hip, knee and ankle is required. A high thigh tourniquet can be used but not required. Most utilitarian is a standard midline incision, which allows for intra-articular work, i.e. meniscal transplantation, or can be re-used in the future for additional procedures. For isolated HTO, a shorter longitudinal incision can be placed midway between the anterior and posterior aspects of the proximal medial tibia extending from 1 cm below the joint line to below the level of the pes anserine. Full-thickness fasciocutaneous flaps are mobilized and the medial edge of the patellar tendon is exposed and protected by a retractor in the retropatellar bursa. From the several approaches to exposing the medial tibia, entering the deep posterior compartment and addressing the MCL (inverted “L-shaped” incision approach, MCL elevation approach and MCL incision in osteotomy line approach), the senior author’s preference is for the latter. The pes is incised along its superior border and reflected posterior and distally, exposing the MCL. The superficial MCL can be elevated as part of the flap or can be transected at the osteotomy level (Fig. 2); the deep MCL attaches more proximally and is left intact. The plate is placed on top of the MCL fibers; the pes is reflected back over the distal aspect of the plate, and the edges loosely re-approximated.

The deep posterior muscle compartment is entered at the posteromedial margin of the tibia. The popliteus muscle attachment is reflected posteriorly. On the posterior surface of the proximal tibia, blunt soft tissue dissection is performed across until the fibular head can be palpated and a retractor is placed to protect the neurovascular bundle.

01 Osteotomy planning on long leg radiograph (A) and on knee anteroposterior radiograph (B)



02

Under fluoroscopic guidance, a pin is placed obliquely across the proximal tibia, aiming towards the fibular head (Fig. 3). The lower leg must be slightly flexed until the tibial plateau is parallel to the fluoroscopic view. A second pin is placed parallel to the first pin, creating a plane that is parallel to the posterior tibial slope. The osteotomy should be placed at least 2cm below the tibial plateau to facilitate plate placement and reduce the risk of inadvertent extension of the osteotomy into the tibial plateau. Centrally, the osteotomy is generally performed above the level of the tibial tubercle. However, some patients have a more proximal attachment of the patellar tendon on the tibia. In these cases, the proximal aspect of the patellar tendon attachment can be carefully elevated off the tibial tubercle in a subperiosteal fashion by approximately 1 cm, or alternatively, a biplanar osteotomy can be performed. For the latter, a counter-cut is made behind the tibial tubercle, parallel to the long axis of the tibia, extending distally by approximately 2 cm. This allows the osteotomy cut to be performed more distal, essentially behind the tibial tubercle.

Under constant irrigation, the osteotomy cut is made distal to and along the previously placed pins with the oscillating saw, being mindful of the neurovascular bundle, and stopping short by 1–1.5 cm to preserve a lateral hinge. With some valgus stress there should be some opening (1–2 mm) of the osteotomy site indicating the osteotomy cut was extended laterally the right amount to allow opening. Utilizing metal wedges, a custom “jack” device or stacked osteotomes, the osteotomy is opened slowly to the desired gap. Any significant resistance to opening should prompt careful revisiting of the osteotomy to divide any constraints—most commonly the posterolateral cortex. Failure to do so may result in inadvertent fracture into the tibial plateau. The knee is fully extended and the leg placed in neutral rotation to allow correct fluoroscopic evaluation. The hip-knee-ankle alignment is now fluoroscopically checked with the Bovie cord, or preferably, a rigid alignment rod. The osteotomy is secured with a plate, generally a locking plate construct. Depending on the amount of correction and surgeon’s preference, the osteotomy gap can be left empty (<10mm with current generation locking plates), bone grafted or filled with artificial bone void filler such as tri-calcium phosphate wedges 3,5.

Knee immobilizer or hinged knee brace is recommended at least until quad control has been re-established.

Technical Considerations

Choice of Fixation Device

Current locking plate constructs are preferred especially for larger corrections, as they provide more mechanical stability than first generation systems with stainless steel plates with conventional screws. Newer devices are available to avoid hardware irritation and avoid alteration of the slope.

Posterior Slope in HTO

The goal of realignment osteotomy is usually to effect change in the coronal plane alone. However, tibial slope can intentionally be changed to compensate for ligamentous deficiency. Generally, opening wedge osteotomy increases posterior slope. Any significant increase in posterior slope can compromise full extension and promotes anterior tibial translation, accentuating a pre-existing ACL deficiency (or alleviating PCL deficiency) and shifting the center of load on the tibial plateau posteriorly. To minimize changes to the posterior slope the surgeon should aim to preserve a lateral, rather than posterolateral, cortical hinge, ensure that the posterior osteotomy gap is twice the width of the anterior gap, and place the plate as posterior as possible.

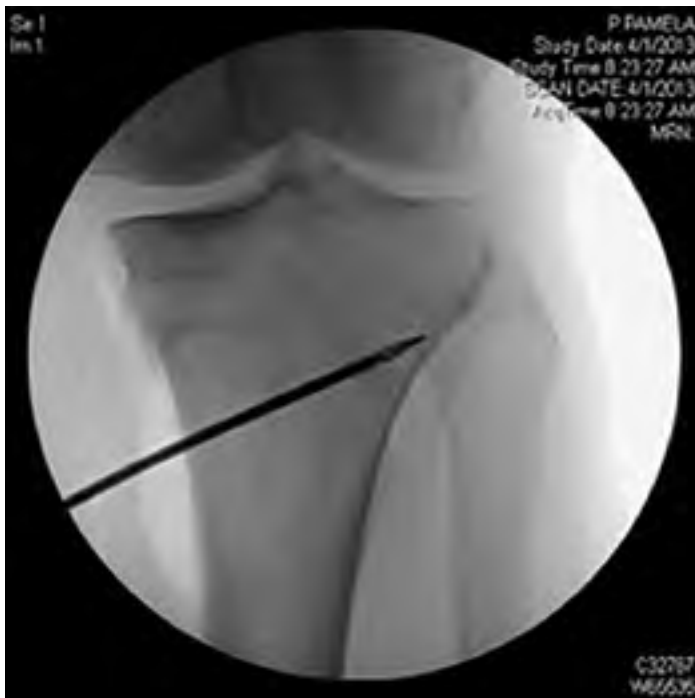Technical Pearls for Open Wedge High Tibial Osteotomy

Patellar Height in HTO

Changes in patellar height occur when the osteotomy is made proximal to the tibial tubercle. Opening wedge osteotomy distalizes the tubercle, potentially resulting in patellar baja. This effect is usually minor when attention is paid closing the osteotomy gap anteriorly (half the medial osteotomy gap width). Also release of the medial fibers of the patellar tendon attachment will minimize the osteotomy effect. Patients with pre-existing patella baja should be considered for either closing wedge osteotomy, or opening wedge osteotomy with the tubercle left attached to the proximal tibial plateau (biplanar osteotomy with distal, rather than proximal counter-cut).

Hinge Disruption

Hinge disruption can occur through extension of the saw cut or inadvertent fracture, especially in large corrections. It reduces axial and torsional stiffness, risking loss of fixation and hardware failure with non-union. The risk of lateral hinge fracture may be reduced by aiming the osteotomy towards the proximal half of the fibular head. If noticed intra-operatively, the cortical disruption can be stabilized by placement of a staple or small plate across the defect, thus restoring stability, unless the surgeon feels confident in the mechanical stability of the construct (e.g. heavy angle-stable locking plates in smaller corrections).



03

Intra-Articular Fracture

When an intra-articular fracture occurs, the osteotomy should be closed, thus reducing the fracture, and several medial to lateral screws are placed close and parallel to the tibial plateau, taking care they will not interfere with the osteotomy hardware placed subsequently. Thereafter, the osteotomy cut is revisited with the osteotome, then slowly reopened with wedged osteotomes across the entire length of the osteotomy to support the tibial plateau. Bone grafting should be considered and weight-bearing limited for longer than usual with careful serial x-ray monitoring.

Bone Grafting

Whether bone graft is required with current plate systems is controversial. Options include local autologous bone graft from the distal femur, structural iliac crest auto- or allograft, allograft chips, tricalcium phosphate (TCP) wedges or granules, or demineralized bone matrix. Autologous bone graft from the distal femur can be obtained through a small accessory incision just proximal to the medial or lateral femoral epicondyle. The harvest site can be back-filled with allograft bone or demineralized bone matrix. Although allograft bone or demineralized bone matrix is still used as back-fill, the osteotomy site will be filled with autologous graft with a better healing potential, while avoiding the adverse effects of iliac crest bone graft.

Complications

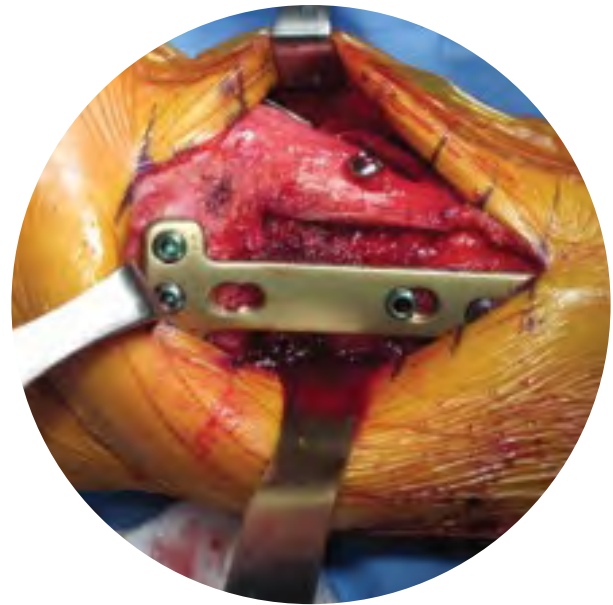
Intra-operative complications include the previously discussed hinge disruption, intra-articular fracture as well as neurovascular injury. Peroneal nerve injury is a known complication of closing-wedge HTO, but rare in opening wedge HTO. Vascular injury is quite rare (<1%) with appropriate precautions such as use of posterior retractors, and knee flexion during the osteotomy to provide a greater margin of safety since the popliteal artery is at its greatest distance from the posterior tibia. However, approximately 2% of the population has an anatomic variant in which the anterior tibial artery has an aberrant proximal take-off, coursing anterior, rather than posterior, to the popliteus muscle increasing risk of injury.

- 02 After the starting point of the osteotomy has been determined under fluoroscopic guidance, the MCL is transected at the same level.
- 03 A guide pin is placed oblique across the tibia, aiming for the fibular head.

Post-operative complications include general risks such as infection and deep vein thrombosis, and osteotomy-specific risks such as hardware failure, loss of correction, compartment syndrome and non-union. Plate breakage is rare with current implants. Non-union is not commonly observed after closing wedge osteotomy (<1%) nor opening wedge osteotomy (1.6%). Other post-operative issues include damage to the saphenous nerve; while numbness lateral to the incision is a predictable event after knee incisions, a saphenous neuroma is a painful complication that occasionally requires surgical intervention. Hardware can cause local irritation to the hamstring tendons, and can usually be safely removed after 9 to 12 months, after advanced healing of the osteotomy.

Rehabilitation

Historically, touch-down weight-bearing precautions were recommended for 6 to 12 weeks after opening wedge osteotomy, with subsequent transition to full. Newer plating systems generally allow accelerated rehabilitation, with some allowing immediate full weight-bearing as tolerated. Motion is not restricted; use of a continuous passive motion (CPM) machine is optional, especially when no concurrent intra-articular procedure was performed. Physical therapy includes isometric quadriceps and hamstring strengthening, with straight leg raises as soon as pain allows. Stationary bike can be started almost immediately post-op; resistance should be increased only slowly. Return to full activities can be expected between 3 and 6 months, but full healing of the osteotomy site should be documented radiographically before allowing unrestricted return to high impact and collision sports.



04

Case 1

Female, 46 years old with hypophosphatemic rickets. Lifelong short stature (1.52m), varus malalignment and medial knee pain bilaterally.

Underwent staged bilateral medial opening wedge high tibial osteotomy (Right 12mm, Left 18mm opening) 3 years ago. Biplanar retrotubercular osteotomy cuts were performed. On the right knee standard cut was directed proximally. Due to the predicted large gap opening, on the left knee, pre-emptive staple fixation for lateral hinge was added, and retrotubercular osteotomy was directed distally (Fig. 4).

- 04 Retrotubercular osteotomy directed distally fixed with a compression screw. Locking plate placed and osteotomy gap bonegrafted with mix of allograft chips and autograft obtained from the distal femur (note separate proximal incision for small medial subvastus approach to distal femur).

The Role of Hip Injections in the Diagnosis of Femoroacetabular Impingement



Leandro Ejnisman, MD, PhD
University of São Paulo, BRAZIL
Member of the ISAKOS Hip, Groin and Thigh Committee

Background

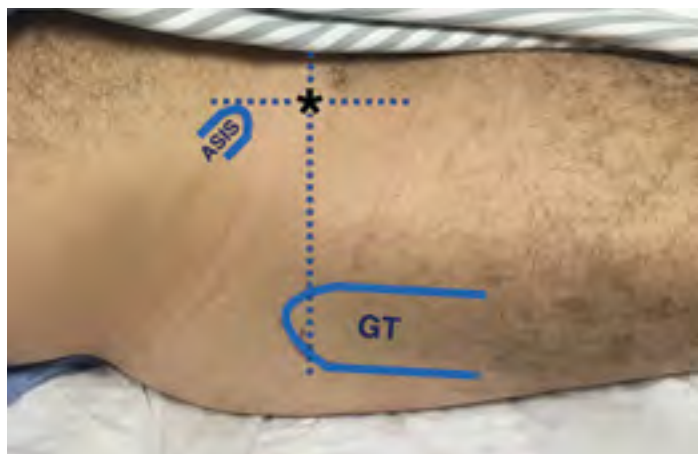Femoroacetabular impingement (FAI) is an important cause of hip pain in the athlete. Typically, the patient presents a history of groin pain, and during physical examination the anterior impingement sign is positive (pain during flexion, adduction and internal rotation). X-Rays demonstrate a decreased femoral head-neck offset in cases of cam impingement, and/or acetabular overcoverage in cases of pincer impingement. Magnetic resonance (MRI) demonstrates labral tearing, chondral damage, loose bodies, and ligamentum teres injuries.

However, the diagnosis may not be so straightforward. FAI patients demonstrate symptoms in different locations such as low back pain, posterior thigh, buttocks or even the knee. Moreover, alterations in hip imaging can be frequently found in asymptomatic patients. A cam deformity is found in 37% of hips, and can be present in a percentage as high as 55% in the athletic population. Also a labral tear is observed in 68.1% of MRI studies. Therefore, FAI diagnosis can be challenging, and it can be useful for the sports medicine physician to possess other diagnostic tools, such as hip injections.

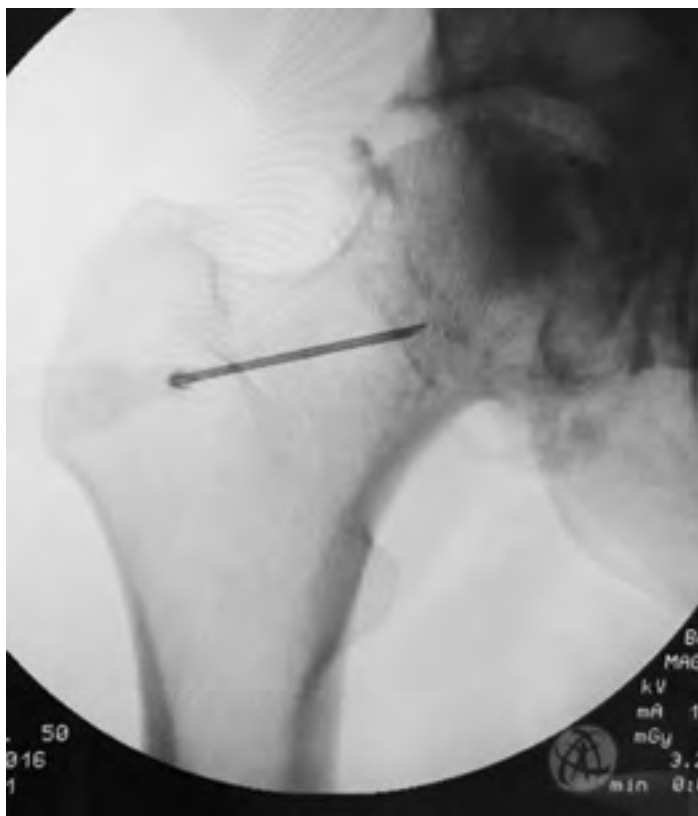Technique

Intra-articular hip injections can be performed using anatomical landmarks or image guidance. The main advantage of the non-image guided technique is the reduced cost, and a lack of need for any special equipment. The main disadvantage is the reduced precision of intra-articular placement.

A recent study described an anatomical landmark technique for intra-articular hip injections, and validated it through arthroscopic confirmation of needle placement, demonstrating a 93% success rate. The patient is positioned supine, and an assistant holds the patient's leg in order to keep him immobile and the feet parallel and pointing upward. It is important to check the pelvis is not rotated, so that both antero-superior iliac spines (ASIS) are level. The entry point of the injection is determined by the crossing of a longitudinal line passing through the medial aspect of the ASIS and a transverse line through a point 1 cm distal to the tip of the greater trochanter (Fig. 1). A spinal needle is inserted in a directly antero-posterior direction (90° angle) until the anterior part of the femoral neck is felt as a hard stop, and the injection is performed.



01



02

Fluoroscopy guided injections use radiographic parameters to find the best entry point for needle placement. A small amount of contrast is frequently used to confirm intra-articular placement of the needle (Fig. 2). Another possibility is to inject air, and an air arthrogram is observed. Disadvantages of fluoroscopy guided injections include radiation exposure both to patient and staff, and frequent need of a second patient visit to the medical facility. Ultrasound guided injections offer an advantage of visualization of soft tissues and lack of radiation. Moreover, ultrasound guided injections may be less painful than fluoroscopy guided. Time needed for needle manipulation and total time of the procedure influence patient discomfort during the procedure. Several substances can be injected. Frequently an anesthetic is used to evaluate the immediate response to the injection, which is the most important information in a diagnostic injection. The patient is oriented to perform activities where he experiences pain, and report if there was any improvement after the procedure. Corticosteroids are regularly utilized, including triamcinolone and methylprednisolone in various dosages. Moreover, injection of hyaluronic acid (HA) and platelet rich plasma (PRP) have also been described.

Results

A positive response to an intra articular hip injection may be an important predictor of clinical results after FAI surgery. Ayeni et al evaluated 52 patients who had a diagnostic hip injection prior to hip arthroscopy. Patients who did not experience pain relief from the injection were half as likely to have better function and reduced pain at 6 months post-surgery.

The therapeutic results of the injections in FAI patients are controversial. A recent systematic review found 3 studies on the topic. Abate et al reported an improvement in the visual analog scale and Harris Hip Score in all patients after injection of HA (23 cases, 1 year follow up). Hunt et al demonstrated pain relief one year after corticosteroid injection in 100% of patients (6 cases), while Krych et al reported that only 6% of patients (54 cases total) reported clinically significant decrease in pain after 6 weeks.

Author's Opinion

In my practice, I do not perform intra-articular injections in every FAI case. When a patient presents with classical FAI symptoms and radiographic FAI signs, I consider the injection to be unnecessary. However, when a patient presents with atypical pain, or negative/dubious imaging workup, I find the injection useful to confirm an intra-articular pathology. I usually perform the injection using the anatomical landmark guided technique as described above. In very obese patients, and patients who prefer to be sedated, I perform a fluoroscopy-guided injection in the OR. I prefer using a 16-gauge long Jelco™ or an epidural needle, because they are stiffer than a spinal needle, making it easier to find the right location. I inject 40 mg of triamcinolone plus 3ml of 1% lidocaine. Thirty minutes after the procedure, I re-examine the patient to check for pain and signs of impingement. I ask the patient to observe thoroughly how his pain behaves the next 4 hours and the following 2 weeks after the injection. In patients who present pain only in specific activities, I ask them to perform these activities after the procedure. In patients who are aware of the impossibility of performing surgery even if indicated after the injection (such as athletes in mid-season), I also inject hyaluronic acid, in an attempt to prolong the duration of symptoms relief. I consider the diagnostic injection to be positive, if the patient refers any improvement of his symptoms.

- 01 Entry point of the anatomical landmark technique of intra-articular hip-injection (GT: greater trochanter, ASIS: antero-superior iliac spine, black star: entry point).
- 02 Fluoroscopy image of a right hip demonstrating needle placement in the anterior neck and homogeneous extension of the contrast inside the joint

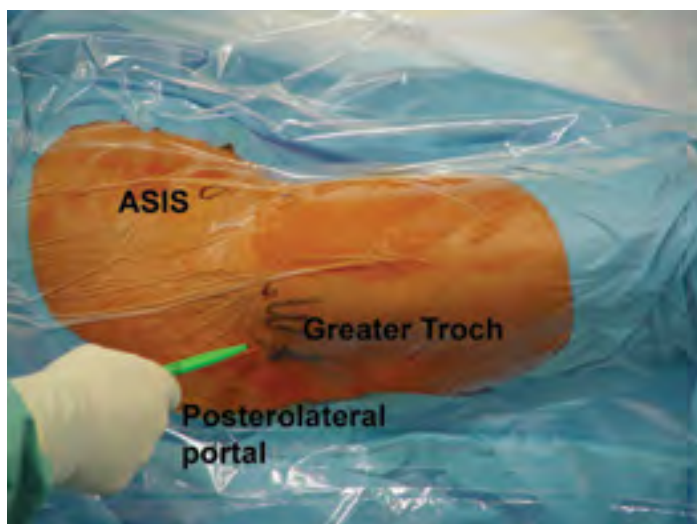
Point: Why Do I Use The Posterolateral Portal During Hip Arthroscopy?



Nick Mohtadi, MD, MSc, FRCSC
Calgary, AB, CANADA

As an arthroscopist that was originally trained in the shoulder and subsequently learned how to do hip arthroscopy well into my career, it was logical for me to use the posterolateral portal when performing hip arthroscopy. The parallels with shoulder arthroscopy are obvious; “keep the scope in the back and operate in the front.” I should point out that I first enter the central compartment with the anterolateral portal under fluoroscopic control and secondarily make the posterolateral portal. Here are the salient points related to why I routinely but not exclusively, use the posterolateral portal during hip arthroscopy.

The posterolateral portal (PLP) is easy to identify through clearly recognizable landmarks. The posterosuperior aspect of the greater trochanter is essentially a subcutaneous landmark when performing hip arthroscopy in either the supine or lateral position. This picture shows a right hip in the supine position (ASIS = Anterior Superior Iliac Spine) with the three standard portals; marked with white crosses (Anterolateral; Anterior; Posterolateral). The posterolateral portal is indicated with the pen.



01

I have yet to have any complications from using the PLP. The spinal needle is introduced parallel to the femoral neck with the femur in the neutral position i.e. neutral femoral anteversion. The more prominent posterior aspect of the greater trochanter is therefore rotated anteriorly. This reduces the chance of deflecting the spinal needle posteriorly, diminishing the possibility of injuring the sciatic nerve. And there have only been two reported cases of sciatic nerve injury in the literature, that occurred on the same day to the same surgeon.

The PLP is directed through the posterior capsule, which is much easier to penetrate compared to the anterior or anterolateral portals. The supporting posterior ischiofemoral ligaments are thinner and not nearly as robust as the capsule and supporting structures anteriorly. As a result penetrating the capsule to enter the central compartment requires less force and therefore is less likely to cause iatrogenic articular cartilage or labral damage.

Placing the arthroscope in the PLP allows for greater separation between the scope sheath and the other portals / cannulas; used for palpating structures and operating. In other words, the ability to “triangulate” is enhanced.

Because the PLP allows for greater coverage of the joint by three portals, the need to make large capsulotomies is diminished, reducing the risk of problems associated with large capsulotomies, such as hip instability

Using a 70° arthroscope from the posterolateral portal allows the surgeon to see virtually the entire central compartment of the hip joint. The only challenging area to see is the anteroinferior aspect of the acetabulum and adjacent femoral head. And that can be accomplished by moving the camera to an anterior portal. Therefore, visualizing more than 85% of the central compartment without excessive traction is routinely possible.

When performing routine anterosuperior pincer overcoverage surgery i.e. acetabuloplasty, it is easy to keep the arthroscope in the PLP. I can operate using the motorized burr from either the anterolateral or anterior portals. In this way, I can remain orientated in one position. This reduces the need for constantly going back and forth between portals to facilitate the safe removal of bone.

...and last but not least...Reparative surgery to the posterior labrum or posterior acetabuloplasty can be achieved through the posterolateral portal.

I would recommend that all surgeons performing hip arthroscopy, independent of their experience, consider the posterolateral portal. It is easy to enter the hip, facilitates excellent visualization, enables specific surgical procedures and above all is safe.

Counterpoint: I Rarely Use The Posterior Lateral Portal



Thomas G. Sampson, MD
San Francisco, CA, USA

We developed the lateral approach to hip arthroscopy (the patient in the lateral decubitus position) and reported on it in the early 1980's, as a two portal technique and used for all cases the anterolateral and posterolateral portals (originally named: anterior peri-trochanteric and posterior peri-trochanteric). The indications were limited to debridement, removal of loose bodies and labrectomy. James M. Glick designed long cannulated instruments and hip scopes with the 30° arthroscope as the workhorse for the majority of the procedures and the 70°arthroscope to see into difficult areas and recesses. Capsular incisions primarily to expand the portal allowed for better instrument excursion and mobility and expanded the central compartment views allowing for better instrument mobility and more advanced techniques.

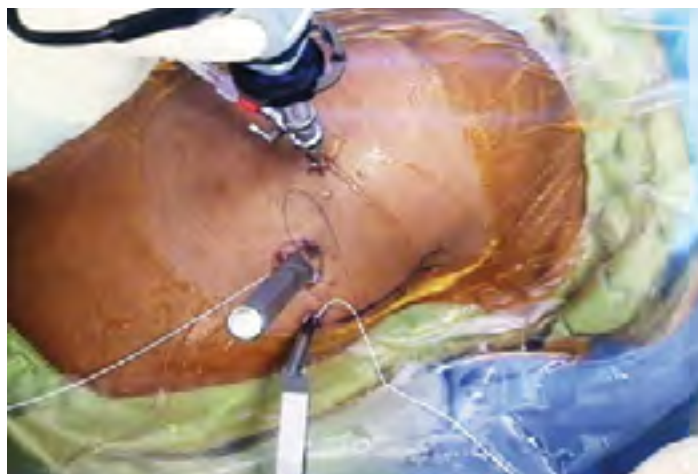
In the early 1990's more advanced procedures necessitated more portals, and therefore, the anterior and anterior-inferior or distal portals were added. Around that time J.W. Thomas Byrd developed a cannulated system specifically for hip arthroscopy using standard length arthroscopes, and popularized the "Supine Approach." He published a specific technique using three portals and added the anterior portal to the already popular anterolateral and posterolateral portals.

Fast-forward to the turn of the millennium, it became very apparent that Femoroacetabular Impingement (FAI) was a major cause of hip pain. Although all portals were necessary to treat the pathology from FAI, it became evident most of the pathology was geographically located in the anterior portion of the hip. The introduction of extensive capsulotomy gave the advantage to maximally expand the width and breadth of each portal allowing for a reduction of the number of portal needed. Many have as a routine use only two portals, and some add convenience mini-portals for anchor placements.

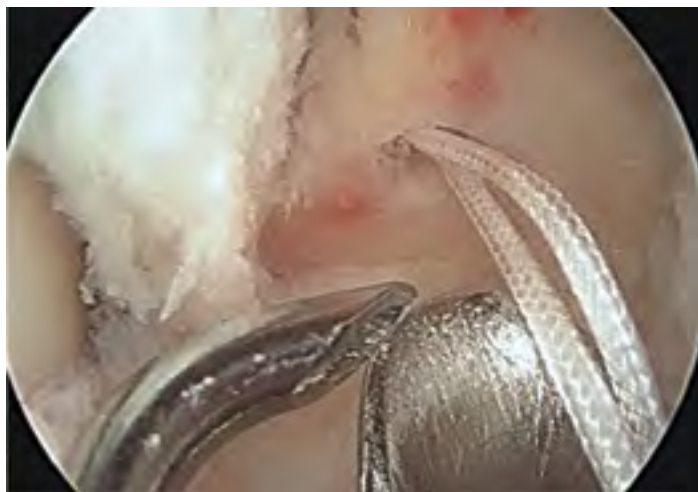The mid-anterior portal became the workhorse to address the most damage to the central compartment and has an ideal trajectory for bone removal of the CAM bump and acetabular rim as well as anchor placement. Therefore, today, we primarily use the anterolateral and the mid-anterior portals for nearly 99% of all hip arthroscopic surgeries, and have found the postero-lateral portal only useful for posterior osteotomies, posterior labral repairs and reconstruction (rare), as an accessory portal or for difficult access to the anterior acetabulum in need of micro-fracture.

There are few complications related to the mid-anterior and antero-lateral portals as lateral femoral cutaneous nerve damage is seen more commonly with the anterior portal, however, a word of caution using the posterolateral portal is to make sure the portal is not created with the hip in external rotation, as it places it in very close proximity to the sciatic nerve.

Edited by Marc R. Safran, MD USA



02a



02b

Infected ACL Reconstruction: Severe Consequences of Septic Arthritis



Moin Khan, MD, MSc, FRCSC
Clinical Fellow
McMaster University
Hamilton, ON, CANADA

Additional Author:

Sebastian Kopf, MD
Center for Musculoskeletal Surgery
Charité–University Medicine Berlin
Berlin, GERMANY

OR Ayeni, MD, MSc, FRCSC
Associate Professor
McMaster University
Hamilton, ON, CANADA

Introduction

Although complications are infrequent, septic arthritis following ACL reconstruction is significant and surgeons performing this procedure must be critically aware regarding early diagnosis and eradication in order to prevent or minimize the negative sequelae of infection.

Epidemiology

The risk of serious complication following ACL reconstruction is low however septic arthritis remains a rare but potentially devastating event. A recent review of the literature estimated the infection rate to be between 0.14–1.7%. A variety of organisms have been implicated in septic arthritis following ACL reconstruction; however, the vast majority of these infections are bacterial in nature. The most common organisms are coagulase negative staphylococci and *Staphylococcus (S.) aureus*. A recent systematic review of septic arthritis following ACL reconstruction found an increased likelihood of treatment failure in cases where the infecting organism is *S. aureus* likely due to its higher virulence.

Risk Factors

Patients may have risk factors which increase likelihood of infection following ACL reconstruction. A review of 2,198 patients by the Multicenter Orthopaedic Outcomes Network (MOON) group explored potential risk factors among the 17 (0.8%) cases of infection among the cohort. Risk factors evaluated included age, body mass index (BMI), diabetes mellitus and smoking.

Of these, only diabetes mellitus increased the likelihood of infection. Specifically, diabetes mellitus increased the odds of infection by 18.8 times (95% CI = 3.8 to 94.0; $p < 0.001$) with postoperative infections in 8.7% in patients with diabetes mellitus and 0.7% in patients without diabetes mellitus. Despite smoking increasing the risk of infection with other types of orthopaedic procedures, the study found insufficient evidence to confirm an association between smoking and infection following ACL reconstruction.

A number of surgical risk factors for infection have been discussed in the literature such as increased surgical time, multiple concurrent soft tissue procedures and the use of intra articular steroid injection. It is controversial whether graft selection contributes to risk of postoperative septic arthritis, however, a number of studies have found that graft selection does in fact affect risk of infection. For example in a retrospective review of 3,126 ACL reconstructions Barker et al found a higher infection rate with hamstring tendon autografts (1.44%) than BPTB autografts (0.49%) or allografts (0.44%). Other reports however have not found differences in infection rates with varying graft selection. Although a number of potential hypothesis exist regarding biological plausibility for increased infection rates with specific grafts, the available literature is of low quality evidence and limited by potential bias.

Controversy also exists regarding hardware selection and subsequent risk of infection. However, a high quality meta analysis of randomized controlled trials comparing bioabsorbable versus metallic screw fixation found no increased risk of infection with one selection over another.

Despite the best efforts of the surgeon occult contamination may still occur, though not all contaminated grafts will develop septic arthritis. A prospective level II study by Hantes et al found a 12% risk of contamination in 60 patients undergoing ACL reconstruction; however, no involved patients developed infection. Clinicians can decrease the risk of potential contamination and subsequent infection through the use of waterproof drapes to prevent contamination, keeping the foot on the operative table and utilizing trusted donor sources. One of the worst possible intraoperative complications is the scenario of a dropped ACL graft. A survey by Izquierdo et al found that of 146 surveyed surgeons, 49 had seen at least one ACL graft dropped during their career. In the case of a dropped graft, the correct sterilization agent for decontamination should be readily available if graft retention is planned. In the unlikely event of a dropped graft a systematic review by Khan et al of six laboratory studies involving 495 graft samples found the 98% sterilization with protocols that utilized chlorhexidine solution.

Diagnosis

Diagnosis begins with the careful history and physical exam. Patients may present with classic symptoms such as erythema (latin: rubor), effusion (tumor), warmth (calor), decreased range of motion (function laesa) and severe pain (dolor); however, these can be absent. The mean time to presentation following ACL reconstruction was found to be 22.8 days in a systematic review of 18 studies with a mean delay of 2.6 days between presentation and initiation of treatment. Laboratory testing is essential and serum values of erythrocyte sedimentation rate (ESR), C-reactive protein level (CRP) and white blood cell (WBC) are generally elevated. Significant variability exists in the literature regarding specific criteria for diagnosis and presentation can vary widely, so the surgeon should have a relatively low threshold for arthrocentesis and culture if infection is considered. This should be done prior to the administration of antibiotics. Aspiration of joint fluid generally demonstrates elevated synovial WBC (>100 000) with a shift in cell differential (>90% polymorphonuclear cells) however published reports demonstrate significant variability for diagnostic criteria.

Management

Following a diagnosis of septic arthritis, prompt surgical irrigation and debridement (with tissue and fluid sent for culture) and subsequent empiric antibiotic therapy is indicated. Extensive lavage with saline solution and complete synovectomy should be performed. Fluid and tissue should be sent for aerobic and anaerobic bacteria, as well as fungus and mycobacterium. In addition to aspiration a number of biopsy specimens should be taken at the time of arthroscopy for microbiological evaluation to further confirm specific infecting organism and to exclude contamination of the aspirate. The majority of studies describe typical treatment with culture specific intravenous antibiotics for 4 to 6 weeks followed by oral antibiotics for another 2 to 4 weeks with careful monitoring of clinical and inflammatory markers to determine cessation. The typical course is generally left to the discretion of the treating infectious disease specialist.

During the initial irrigation and debridement, the ACL integrity is carefully examined. Although debridement with graft retention has decreased morbidity there is debate in the literature between debridement with graft retention and immediate graft removal or removal in the case of persistent infection. A systematic review of 11 studies involving 90 patients found that irrigation and debridement with graft retention resulted in an overall success rate of 85%. Cases in which significant degeneration or gross compromise in graft function exists are appropriate for graft and hardware removal with staged treatment. If the graft is to be removed it is important that all associated hardware is removed at the same time and the femoral and tibial tunnels are debrided thoroughly.

Although it is ideal to retain all grafts, particularly virulent organisms such as methicillin-resistant *S. aureus* (MRSA) have high failed retention rates thus immediate graft removal and staged treatment is appropriate in such cases. A case report on MRSA documents its particular virulence and unresponsiveness to repeat irrigation and debridement.

In general repeat irrigation and debridement and potentially open procedures may be considered depending on the condition of the joint and integrity of the ACL and the overall clinical picture. Wang et al performed a review of 196 infections in over 30,000 ACL reconstructions and found that of 103 cases reporting the number of debridement procedures, 60.2% were treated with one, 28.2% with two and the remainder with three or four debridements to eradicate the infection. The study found delayed diagnosis over seven days or the presence of *S. aureus* infection required longer duration of antibiotic treatment and increased likelihood of graft removal and negative outcome. Variability in the timing of revision ACL surgery was also found which varied from six weeks following completion of antibiotic regimen and normalization of laboratory investigations to 12 months or longer following resolution of infection.

Outcomes

Boström Windhamre et al performed a case control study and compared outcomes in patients with septic arthritis following ACL reconstruction who were treated with irrigation, debridement, antibiotic treatment and graft retention and non infected controls. The authors found that although objective knee function between groups was similar many patients who were treated for infection had prolonged rehabilitation course and a decreased rate of return to sports. Makhni et al published a comprehensive systematic review that found patients have similar LysoM scores to those patients who were not infected. Additionally, patients who have had an infection are at higher likelihood to develop degenerative changes when compared to those without infection.

Conclusion

Septic arthritis following ACL reconstruction is a potentially devastating complication. Rapid diagnosis and management is critical to optimize graft preservation and to prevent the sequelae of septic arthritis, including joint destruction. Irrigation and debridement with graft retention and culture specific antibiotic treatment is necessary for the vast majority of cases with good long-term outcomes in cases where there is prompt recognition and management.

Arthroscopic Debridement and Bone Marrow Stimulation for Talar Osteochondral Lesions



Gian Luigi Canata, MD
 Centre of Sport Traumatology, Koelliker Hospital, Torino ITALY

Additional Author:
 Valentina Casale, MD ITALY

Background and Classification

The lesions of the talar cartilage and subchondral bone are mostly caused by a single or multiple traumatic events, with a partial or complete detachment of the fragment as a consequence. These injuries may occur in any location on the talar dome, even though they are typically observed posteromedially or anterolaterally.

Lateral osteochondral lesions are often associated with a traumatic event, while medial lesions are more frequently caused by spontaneous events. In fact, in the absence of trauma, ossification defects, abnormal vasculature, emboli or endocrine disorders may account for focal pathologic subchondral fractures of the talar dome.

The Berndt and Harty scale is the most widely recognized classification. It is based on radiographic images or intraoperative findings (Table 1). In 2001, Scranton and McDermott added to this classification system a further stage corresponding to those cases in which a subchondral cyst formation develops within the talar dome.

Stage	Description
Stage I	Small, subchondral compression of the bone
Stage II	Partial detachment of the fragment from the chondral surface
Stage III	Complete fragment detachment with no displacement
Stage IV	Total detachment of fragment with displacement

Table 01

The diagnosis can be delayed because plain radiographs may often appear normal or only slightly altered. The real onset of symptoms ranges between 4 months and 2 years, as the ankle may appear completely normal during the inspection. For this reason, the diagnosis of this kind of injury requires a high index of suspicion. In addition to plain radiographs, more detailed studies include Computer Tomography (CT) scans, Magnetic Resonance Imaging (MRI) studies and direct arthroscopy of the ankle.

Surgical Treatment

Management decisions should be based on symptoms, on size (>1,5 cm) and on the grade of the lesion. Surgery is reserved for lesions that fail to respond to conservative measures, but it is also appropriate for patients with unstable lesions and mechanical symptoms: in this case, a long period of conservative management is not recommended, as there is little hope for spontaneous improvement. Specifically, surgical options include excision with or without fibrocartilage growth stimulation techniques, such as microfracture, curettage, abrasion or transarticular drilling.

If a fragment is large enough, it could be reattached to the talar dome through retrograde drilling, bone grafting or internal fixation, using screws and pins, bone pegs or Kirschner wires. The results are fairly good, although this is one of the most invasive techniques. Other options include cancellous bone grafting and osteochondral transplantation through osteochondral autografts, allografts or cell culture.

In 1999, Taranow et al first described the retrograde drilling, effective when a subchondral cyst is present or when the lesion is hard to reach with the usual anteromedial and anterolateral portals. Anterograde drilling can also be effective (Fig. 1, 2). In 2002, Schuman et al reported 82% good to excellent results in 38 patients after arthroscopic curettage and drilling.

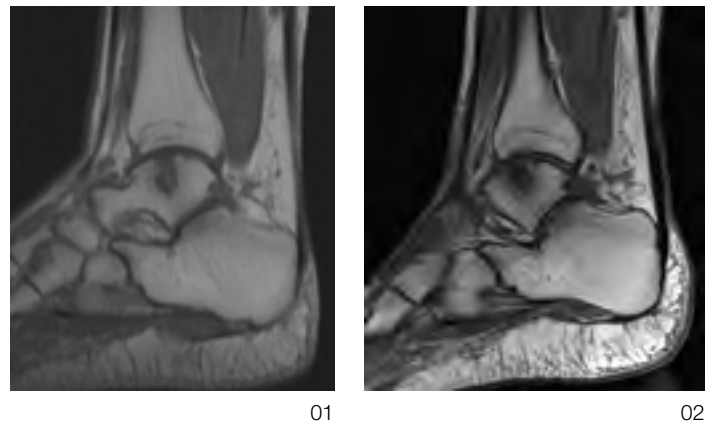


Table 01. Radiographic Classification of Osteochondritis Dissecans (Berndt and Harty)

- 01 Talar osteochondral lesion with cystic degeneration
- 02 MRI 2 months later. Asymptomatic patient after 6 months (AOFAS score evaluation: 100)

Debridement, Microfractures and Drilling

Arthroscopic debridement and bone marrow stimulation currently stand out as the gold standard treatment for talar osteochondral lesions, especially when a complete detachment of the lesion is present, and an internal fixation is not amenable. Bone marrow stimulation techniques promote the development of a fibrocartilaginous formation over the defect, as frequently occurs in the case of small lesions.

They are also supplemented by excision and curettage of the damaged tissue for better results, as arthroscopic debridement entails. It is well documented that arthroscopic excision, curettage and bone marrow stimulation should be the first treatment of choice for primary osteochondral talar lesions: these procedures are relatively inexpensive, there is low morbidity, a quick recovery and a high success rate.

The best indications for bone marrow stimulation techniques are a lesion smaller than 1,5 cm² with frayed cartilage, primary surgery, patients younger than 50 years old, a traumatic etiology, lateral lesions, and low body mass index.

When advanced fraying of the lesion is present, whether or not the lesion is stable, curettage is indicated and can be eventually combined with penetration of the subchondral bone. Among bone marrow stimulation techniques, the arthroscopic drilling is one of the most frequently used methods both for the advantage of being less invasive than microfractures and because it requires only a short period of hospitalization. For Takao, arthroscopic drilling is less invasive than microfractures. It must be said that no reports of long-term follow-up results have been published yet; therefore, the incidence and degree of complications are not clear.

On the other hand, a disadvantage of the microfracture technique is that the repaired cartilage is fibrous, with inferior mechanical qualities when compared to hyaline cartilage, and it can often degenerate eventually causing osteoarthritis. For this reason, if cartilage is intact, a retrograde drilling of the subchondral bone can be considered, without damaging the overlying cartilage. Retrograde drilling was first described in 1999 by Taranow et al: it avoids removal of healthy articular cartilage. It has been reported that there is often no difference in functional outcomes between the transmalleolar and the retrograde drilling. However, retrograde drilling avoids damage to healthy articular structures. Retrograde drilling can be performed using an anterolateral approach, but there are risks of injuring the talar attachment of the anterior talofibular ligament (ATFL) or mechanoreceptors around the sinus tarsi. The posterolateral approach seems safer.

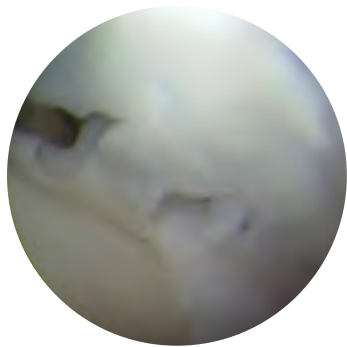A disadvantage of this technique is that the surgeon might have difficulty in visualizing it accurately, if it results far from the insertion point. In this respect, a preoperative MRI or CT scan can be important. Microfracturing and microdrilling are mini-invasive techniques which require a short period of hospitalization, avoiding risks of thermal damage with easier access to the defects without more invasive steps such as transtibial drilling or osteotomy of the medial malleolus. Nevertheless, these two techniques show some differences. Chen et al. were the first to compare microfractures (MF) and microdrilling (MD); in particular, they compared acute osteochondral characteristics 24 hours after MF or MD procedures in a rabbit model. They found that MF produced a more compact bone around holes than MD did, avoiding marrow cells to reach the new holes and thus limiting the repairing process. On the other hand, MD did not produce the expected heat necrosis: this result was reached using a properly thin drill bit under cooled irrigation.

Concerning microfractures, attention should be paid to the correct dimensions and placement of the microfracture holes; in fact, there are differences between the use of microfracture awl and the drilling of a Kirschner wire. The flexible Kirschner wire eases drilling at different angles, while the rigid, angled awl gives a better control for creating holes at the desired depth and perpendicular to the surface; nevertheless, awls are difficult to use in posterior lesions. Arthroscopic debridement combined with drilling stands out as the best treatment for many authors. In 2002 Schuman and Van Dijk compared functional results between two distinct groups of patients, the first one treated with debridement or drilling and the other one treated with a combination of both the techniques.

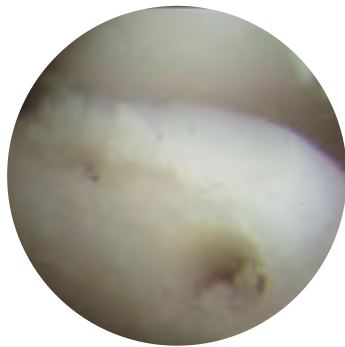
The results indicated that the second group obtained better scores, and similar outcomes had been reported also by Ogelvie-Harris and Sarrosa in 1999. In 2003, Robinson et al. sustained that excision and curettage could give equal or even better results compared with those obtained with excision, curettage and drilling. They observed that the drilling technique modifies the normal structure of the medial malleolus; thus, its adoption should be recommended only if strictly necessary. It is widely assumed in fact that when K-wires are used to drill into hard subchondral bone, they could generate heat and subsequent thermal necrosis of the tissue that should refill the chondral defect. Based on this concept, as described above, Chen et al. in 2009 observed the thermal consequences on the subchondral bone 1 day postoperatively. They demonstrated that microdrilling did not produce apparent heat necrosis.

Arthroscopic Debridement and Bone Marrow Stimulation for Talar Osteochondral Lesions

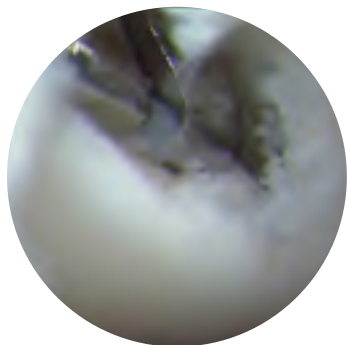
Among the several techniques available, this procedure represents at the moment a valid and effective treatment option (Fig. 3, 4, 5, 6, 7).



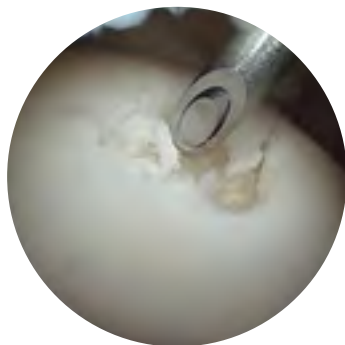
03




06



04



07



05

However, there is still no consensus in the existing literature about the timing of rehabilitation or return-to-sports activity after treatment with bone marrow stimulation of talar osteochondral defects. Van Eekeren et al considered and reviewed this theme, observing potential favoring factors for the optimal rehabilitation: some examples were young age, low body mass index, small osteochondral lesion size, use of growth factors or hyaluronan acid. Regarding this last option, Doral reported that an additional treatment with intra-articular hyaluronan injection could improve results.

Conclusions

Good to excellent results can be consistently reached in more than 85% of patients undergoing arthroscopic debridement, microdrilling and microfracturing. Only symptomatic cases need operative treatment, since minimally symptomatic osteochondral lesions do not appear to progress or worsen over time when treated nonoperatively. Arthroscopic treatment using debridement and mini-invasive drilling is an effective, less invasive and not expensive strategy to treat small- to medium-sized lesions (less than 2 cm²) (Fig. 3).

- 03 Detached fragment
- 04 Debridement of the lesion
- 05 Anterograde drilling
- 06 The holes after drilling
- 07 A spinal needle traces the way before a mini invasive drilling

Shoulder Stiffness: Current Concepts and Concerns



Eiji Itoi MD, PhD*
Department of Orthopaedic Surgery
Tohoku University School of Medicine
Sendai, JAPAN

Additional Authors:

Guillermo Arce, MD, ARGENTINA
Gregory I. Bain, PhD, MBBS, FRACS, FA(Ortho)A, AUSTRALIA
Ronald L. Diercks, MD, PhD, NETHERLANDS
Dan Guttman, MD, USA
Andreas B. Imhoff, MD, PhD, GERMANY
Augustus D. Mazzocca, MS, MD, USA
Hiroyuki Sugaya, MD, JAPAN
Yon-Sik Yoo, MD, PhD, REPUBLIC OF KOREA
*From the Upper Extremity Committee, ISAKOS

Abstract

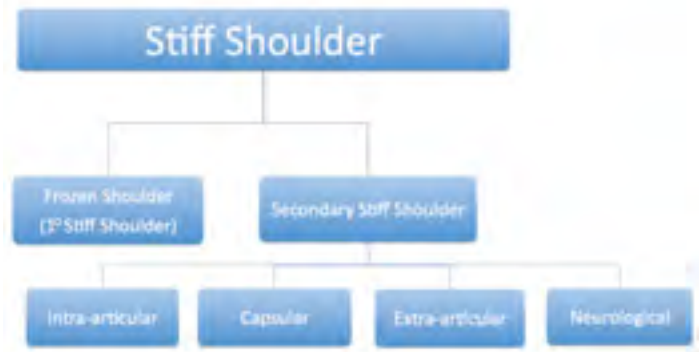This is the summary of the consensus meeting of the Upper Extremity Committee primary idiopathic stiff shoulder. Secondary stiff shoulder is a term that should be used to describe shoulder stiffness with a known etiology. The pathophysiology of frozen shoulder is capsular fibrosis, inflammation, and chondrogenesis, but the etiology is still unknown. Conservative treatment is the primary choice. In cases with refractory stiffness, arthroscopic capsular release may be indicated.

Introduction

The members of the Upper Extremity Committee of ISAKOS met in Amsterdam in May 2014 to create a consensus statement on the definition, classification, and treatment of the stiff shoulder. A detailed report was published in the monograph titled "Shoulder Stiffness: Current Concepts and Concerns" and an extensive summary of this meeting was also published in *Arthroscopy*. This is a brief summary of the review article published in *Arthroscopy*.

Classification and Epidemiology

The term "frozen shoulder" was first used by Codman. Since then, stiff shoulder has been divided into intrinsic and extrinsic causes. Our definitions of stiff shoulder and its subgroups are as follows (Fig. 1):



01

Stiff Shoulder—This term should be used to describe the shoulder with a restricted range of motion. The etiology can be due to primary or secondary causes.

- A) **Frozen Shoulder**—This term should be used exclusively to describe the primary idiopathic stiff shoulder. If a patient has a predisposing factor such as diabetes, smoking, etc., it will still be considered idiopathic.
- B) **Secondary Stiff Shoulder**—This term should be used to describe shoulder stiffness with a known etiology, such as a stiff shoulder after trauma or surgery.

The causes of secondary stiff shoulder can be categorized into 4 groups: intra-articular, capsular, extra-articular and neurological causes.

1. Intra-articular causes: chondral lesions, labral tears, or loose bodies.
2. Capsular causes: contracture following capsular injury or immobilization.
3. Extra-articular causes: muscle tightness, heterotopic ossification, or skin contracture from burns.
4. Neurological causes: cerebral palsy, spinal cord injury, or brachial neuritis.

The incidence of frozen shoulder is 2–5% of the general population. Males with frozen shoulder are at greater risk for longer recovery and greater disability. Co-morbidities are present in 85% of the patients with a frozen shoulder. Multivariate analysis identified thyropathy (especially hypothyroidism), diabetes, nephrolithiasis, and cancer being statistically significant. Other possible factors include Parkinson's disease, Dupuytren's contracture, immobility, smoking, neck and cardiac surgery.

01 Classification of Stiff Shoulder. (From *Shoulder Stiffness: Current Concepts and Concerns*. Itoi E, et al. (eds), ISAKOS 2015, Springer, Heidelberg, 2015)

Shoulder Stiffness: Current Concepts and Concerns

Etiology

Epidemiologic data has established the relationship between diabetes mellitus and frozen shoulder. Other recognized predisposing factors are immobilization, thyroid disorders, cardiac diseases, pulmonary disorders, smoking and Dupuytren's contracture. These predisposing factors may affect both the primary and secondary stiff shoulders.

Frozen shoulder or primary shoulder stiffness occurs when no findings on history, examination, or imaging explain the onset of disease. Thus, the etiology of frozen shoulder is still unknown. Cytokines and matrix metalloproteinases might play a role.

Secondary stiff shoulders can be triggered by various causes, but most commonly by trauma and surgery. Post-traumatic shoulder stiffness can grossly be structured into three major groups: extra-articular adhesions; direct injuries to the intra-articular structures; secondary intra-articular scarring or fibrosis after a defined trauma.

Postoperative shoulder stiffness is most likely caused by the surgical violation of tissue planes, resulting in contractures of the soft tissue surrounding the articulations, pathologic connections between motion interfaces, and/or shortened muscle-tendon unit excursion. One of the most frequent complications of rotator cuff repair is the postoperative shoulder stiffness, with an incidence of 4.9 to 32.7% of all repairs. Both open and arthroscopic instability repair procedures can result in loss of external rotation range of motion, but open repair has a higher incidence of this complication. Significant stiffness is a relatively rare complication (0.9%) in patients undergoing unconstrained shoulder arthroplasty. The most common cases of stiffness are associated with either posttraumatic arthroplasty or in the presence of subtle infection, most commonly *Propionibacterium acnes*.

Biomechanics

Frozen shoulder patients may exhibit significant alterations in shoulder kinematics, including increased elevation and upward scapular rotation. Upper trapezius muscles are more activated than lower trapezius, creating an imbalance of the scapular stabilizers. The subscapularis may have an independent role in frozen shoulder: it has been proposed that a greater loss of external rotation at 45° of abduction versus 90° of abduction indicates more specific involvement of the subscapularis.

Contracture of the rotator interval structures results clinically in loss of flexion and external rotation in adduction. The anterior inferior capsule and the middle glenohumeral ligament are adhered to each other, resulting in further limitations of external rotation at the side. Contracture of the inferior glenohumeral ligament results in significant losses of abduction, forward flexion and both external and internal rotations.

Examinations

The typical finding in frozen shoulder is a global reduction of the range of motion. The Upper Extremity Committee of ISAKOS advises as a guideline: if the range of motion is less than 100° in flexion, less than 10° in external rotation, and less than L5 in internal rotation, we define this as global limitation of the range of motion, which is typically seen in the frozen phase of frozen shoulder.

In the frozen phase with global motion loss, a typical MRI finding is a thickening and shortening of the inferior capsule with concomitant volume reduction of the axillary pouch. During the freezing phase, on the other hand, no abnormalities can be seen on imaging modalities.

Conservative Treatment

NSAIDs are one of the most common interventions in treating frozen shoulder, but only one comparative study was found in which treatment with oral analgesics was inferior to all other conservative interventions. There is evidence that treatment of frozen shoulder with only NSAIDs has no effect on the natural course of frozen shoulder. Intra-articular corticosteroid injection is a common intervention in treating frozen shoulder. Multiple injections are beneficial until 16 weeks from the date of the first injection. There is no evidence supporting more than six injections. There is no difference in the outcome between lower and higher doses of corticosteroids. In the setting of diabetes mellitus, steroid injection may be contraindicated.

Physical therapy is one of the most used interventions in frozen shoulder. Nevertheless, most studies with good end results include physical therapy as an adjunctive intervention together with mobilisation, joint distension, steroid injection or capsular release. In general and according to the existing evidence, physical therapy program to treat this disease should be executed in the pain-free zone during the frozen phase. During the thawing phase, exercise intensity advances and the range of motion increases so as to achieve maximum ADL functionality.

Capsular distension is often performed, but there is no proven superiority of joint distension over to other therapeutic options. There is no difference in the outcome shown between adding steroids, and different volumes. More than one repeated distension after two weeks has no added effect. In a study comparing joint distension with manipulation under anesthesia, similar improvements were noted after 6 months.

Surgical Treatment

Manipulation under anesthesia is commonly used when other conservative treatment does not work in patients with frozen shoulder. Randomized clinical trials comparing manipulation under anesthesia and other treatment options showed no significant difference in the outcome. It is as effective as but less costly than arthroscopic capsular release. Serious complications are fractures or neurovascular lesions, and should be avoided with use of a short lever arm with slow and gentle motion.

In refractory cases, arthroscopic capsular release may be indicated. Arthroscopic capsular release provides precise and controlled release of the capsule and ligaments reducing the risk of traumatic complications observed after forceful manipulation. There is considerable debate regarding the optimal amount of surgical release during arthroscopic capsular release. Preoperative assessment of motion loss may be helpful to guide the degree of capsular release. The best timing to proceed with arthroscopic capsular release is also a matter of controversy. Traditionally, surgeons used to wait for failure of conservative measures for 6–12 months. There is no evidence whether an early surgical intervention would shorten the recovery time of this disease. A recent systematic review reported that there were minimal differences in the outcome between manipulation under anesthesia and arthroscopic capsular release. As the quality of evidence is low, it is difficult to provide any strong clinical recommendation based on the existing literature.

Summary

There is very little evidence in the field of shoulder stiffness, and build up of high quality evidence is strongly required. The ISAKOS Upper Extremity Committee has made a start by developing a classification system based on clinical and imaging findings, and summarizing the existing evidence on treatment modalities in shoulder stiffness. The goal of this review is to support the orthopedic surgeons in differentiating between the two main types of shoulder stiffness, i.e., frozen shoulder and secondary stiff shoulder, and to provide them with the evidence to choose the best patient-tailored intervention. In frozen shoulder or primary stiff shoulder, conservative therapy, including injection therapy and corticosteroid medication, should be the first choice. Arthroscopic capsular release can be offered to patients with refractory symptoms. In secondary stiff shoulder, defining and treating the underlying cause of restricted mobility is essential.

ISAKOS Members Receive Full Access to OrthoEvidence

ISAKOS/OrthoEvidence Portal

OrthoEvidence's database has more than 3,400 evidence-based summaries from more than 360 journals of the highest-quality research in orthopaedics.

1

Log in to myISAKOS at www.isakos.com/myISAKOS

myISAKOS

2

Click on myPublications in the myISAKOS Dashboard



3

Click "Access" the ISAKOS/OrthoEvidence Portal

Access

ORTHOEVIDENCE

in partnership with



Shoulder Instability in the Collision Athlete



Brendan Coleman, FRACS
NEW ZEALAND

Collision sports such as rugby and American football are associated with high impact contact situations during both game and practice situations. Rugby injury rates of up to 15 per 1000 athlete exposures have been reported with shoulder injuries representing 16% of injuries with the highest number of injuries sustained during the game situation as opposed to the training environment. Often players do not describe a dislocation event but describe “stingers”, a transient dead arm feeling or numbness due to a transient brachial plexopathy. Kawasaki’s recent study showed that one third of rugby players reported a history of stingers and 20% of players had at least one episode during the season. Although these injuries had a short recovery period there was a high rate of re-injury.

More than 90% of traumatic shoulder instability is anterior. Although traumatic posterior instability is less common, it is still a major cause of morbidity in collision athletes. Professional rugby players lose 81 days from competition after a shoulder dislocation, and have a recurrence rate of 62%. The effect of shoulder instability is significant on athletes’ playing career with the result being a shortened career or inability to return to an elite level.

Consideration needs to be given to multi-directional instability in athletes with no history of injury. A history of decreasing force causing instability episodes such as occurring during sleep or with minimal trauma raises the concern of glenoid bone loss from recurrent instability. Age of the initial dislocation is the most important determinant of recurrence with a high rate of recurrence seen in traumatic shoulder instability in young athletes.

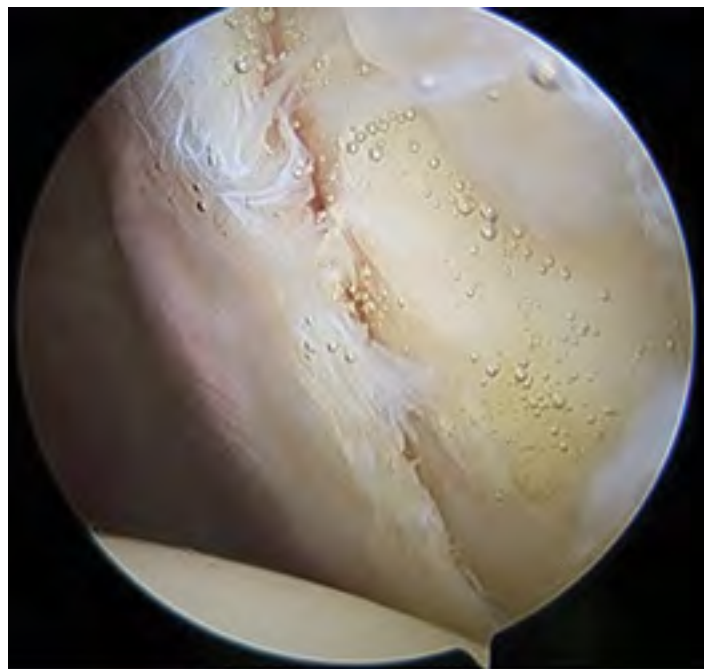The primary pathology in shoulder instability in collision athletes remains the anterior-inferior glenoid and labrum complex. 79% of shoulders have been shown to have an antero-inferior labral tear and 26% have a bony Bankart injury. If the mechanism of injury was a direct impact to the shoulder rather than an abduction-external rotation injury, it is more common to have a posterior labral injury and neurological symptoms, but there is a reduction in injuries to the antero-inferior glenoid and labrum.

Partial injuries to the rotator cuff are seen in one-third of collision athletes with shoulder instability. It is common during collision sports for other injuries to occur including AC joint injuries, and fractures of the shoulder girdle including the clavicle, glenoid, coracoid and scapula.

A thorough examination is necessary to exclude other injuries and to ensure there is not multi-directional instability. A complete neurovascular examination is imperative due to the high rate of nerve injuries such as the axillary, suprascapular and musculocutaneous nerves. EMG studies have shown the rate of axillary nerve injury in shoulder instability to be as high as 42%.

Radiographic evaluation begins with an AP of the shoulder in the scapular plane, scapular lateral and axillary lateral. This assessment ensures a reduced joint and can determine associated injuries such as AC joint subluxation or concurrent fractures of the coracoid or scapula. Although bony Bankart fractures can be seen on an AP x-ray, alternative views such as the West Point view are more sensitive. Hill Sachs lesions can be further assessed with AP views in internal rotation or Stryker notch views.

Computed tomography is the current gold standard to assess glenoid or humeral bone loss in shoulder instability and should be considered if there are clinical findings or radiographs suggestive of bone loss. Glenoid deficiency can be quantified using Sugaya’s technique to determine the percentage bone loss.



MRI can provide excellent assessment of soft tissue injuries in the shoulder and can also be very useful in assessing bone defects. Although, we prefer CT for this purpose. MR Arthrography aids in assessment of the glenoid labrum, humeral avulsions of the glenohumeral ligaments and capsular redundancy.

Non-operative treatment of shoulder instability for collision athletes is associated with high rates of recurrence and the surgical treatment of first time dislocation in collision athletes is becoming more popular. The non-operative treatment for shoulder instability includes immobilization, physical therapy and bracing on return to sport. External rotation immobilization after shoulder instability was initially described by Itoi and showed early promise of reducing recurrence rates but issues with compliance have been described. More recent evidence suggests that recurrence rates are not reduced with external rotation immobilization. The primary determinant of recurrence remains the age at the time of the initial instability event rather than the length of immobilization and early mobilization after an instability event has not been shown to significantly increase the recurrence rate. Although braces that limit abduction and external rotation may provide a subjective sense of stability in the shoulder, they have not been shown to reduce the recurrence rate on return to collision sports. Hovelius and Saeboe showed that shoulders with a high recurrence rate were more likely to develop arthropathy.

Indications for surgery

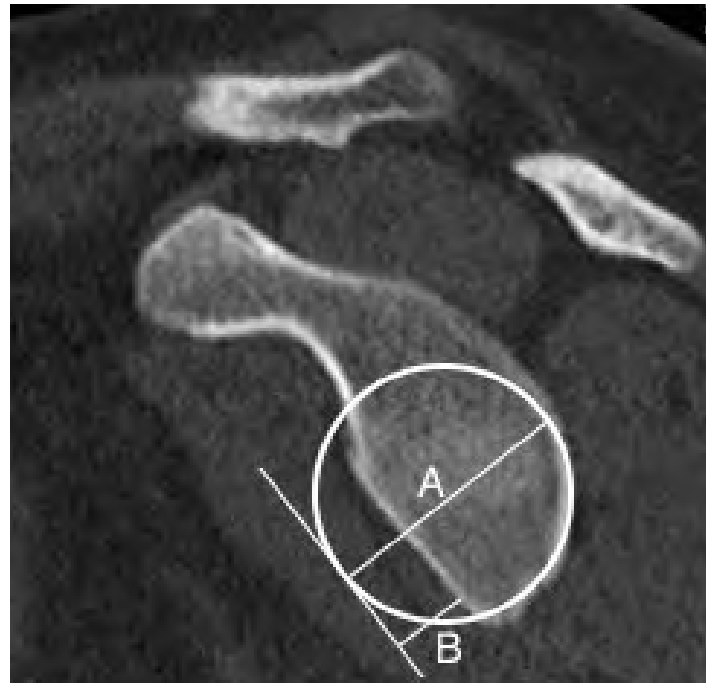- Irreducible dislocation
- Non-concentric dislocation with tissue interposition
- Certain associated injuries
- Failure of non-operative management to maintain shoulder stability

Relative indications

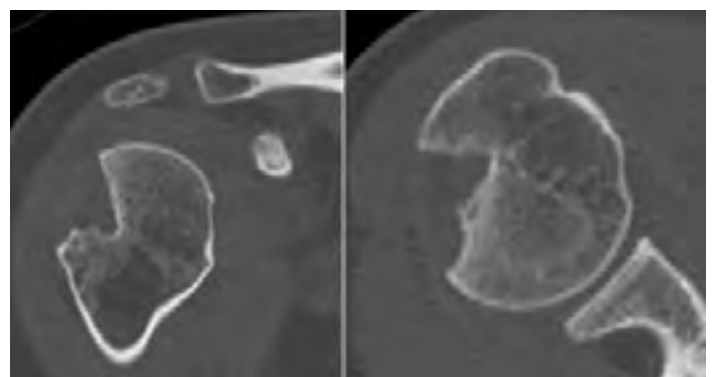
- >2 shoulder dislocations in season
- Age < 20 years for a first-time dislocator

If there are no absolute indications for surgery, the athlete may be allowed to return to sport and surgery can be planned for the off-season. Collision athletes have a low rate of success when returning to play in-season after a shoulder instability event. Only 27% of athletes after instability are able to return and complete the season without experiencing another instability episode. Of those athletes who do return to play, approximately two-thirds will experience further instability on return to play. Athletes with subluxation were more likely to be able to return to play than those with dislocation. If the athlete had recurrence on return to play, generally they should be removed from competition and undergo surgical stabilization.

Two prospective cohort studies have compared the surgical outcomes in collision and non-collision athletes. Ide et al reported on 55 athletes who underwent arthroscopic stabilization with suture anchors and had a 9% redislocation rate in the contact group vs 6% in the noncontact group. Cho and colleagues reported a higher recurrent instability rate in the collision group, with a 29% postoperative subluxation or dislocation rate compared with 7% in the non-collision group.



02



03

- 01 Labral tears remain the primary pathology in collision instability
- 02 Sugaya's technique to determine glenoid bone loss is A/B
- 03 Humeral head defects are associated with recurrent instability which require surgery

Shoulder Instability in the Collision Athlete

Early methods of arthroscopic stabilization were associated with high rates of failure in terms of recurrent instability. Variables including technique, implants used, patient populations and differing pathologic lesions meant that the results often compared unfavourably to open surgery. With refinement of techniques, advancement in technology, an improved understanding of concomitant lesions and refinement of the indications for arthroscopic surgery have led to the results of arthroscopic stabilization being comparable to that of open surgery. Burkhart and De Beer showed that the inverted pear glenoid with bone loss on the anteroinferior glenoid had a high rate of recurrence in arthroscopic surgery when associated with an engaging Hill Sachs lesion. When patients with risk factors for recurrence after surgery such as humeral or glenoid bone defects greater than 25%, humeral avulsion of the glenohumeral ligament and those with poor capsular tissue and laxity are excluded from arthroscopic surgery, then the result of arthroscopic stabilization are similar to open techniques in stabilizing the shoulder in collision athletes. Larrain and colleagues showed in rugby players that the results were the similar between the techniques with a recurrence rate of 5% in acutely treated athletes and 8% in athletes with recurrent instability. Anatomic repair and restoration of the anterior labrum and inferior glenohumeral ligament without violating subscapularis remains the key to arthroscopic shoulder stabilization.

The Latarjet procedure can restore anterior glenoid bone loss through augmentation with the coracoid process. Arthritis has been reported after the Latarjet procedure although this may represent the natural history of instability in these high energy injuries, rather than being related to the procedure itself. Remplissage of the Hill Sachs defect can also be performed and may be promising.

Shoulder instability in collision athletes is associated with a high rate of recurrent instability. Arthroscopic stabilization is a reliable procedure in non-collision athletes, and can be considered in athletes with minimal bone loss and no capsular laxity. However, collision athletes and surgeons need to be aware that the recurrence rate in this high risk population group is potentially higher than seen in open surgery. If investigations confirm either humeral or glenoid bone defects, then consideration should be given to open shoulder stabilization or bone augmentation procedures.



**Available on
Global Link**

**2015 ISAKOS Congress
Content and Videos**

Videos and papers from the **2015 ISAKOS Congress** in Lyon, France are **LIVE** on **ISAKOS Global Link**


2015 Congress Surgical Demo Video Courses—Now Available!

ISAKOS **global link**

isakos.com/GlobalLink

Members in Memoriam

Daniel M. Adair, MD UNITED STATES
Terrence J. Barry, MD UNITED STATES
Tomihisa Koshino, MD, PhD JAPAN
Joseph John Marotta, MD UNITED STATES



Paolo Aglietti, MD 1942–2013

Paolo Aglietti will be remembered for his numerous contributions to knee surgery. He was Professor and Chief of Orthopaedics and Traumatology at the University of Florence. Paolo was a founding member of both the Italian

Arthroscopy Society (SIC) and the Italian Society of Knee Surgery (SICG). He promoted the integration of the Italian knee, cartilage and sports trauma societies under the newly founded Italian Society of Knee Surgery, Arthroscopy, Sports Traumatology, Cartilage and Orthopaedic Technologies (SIGASCOT). His study on "New Patellar Prosthesis" is still considered a keystone paper. He was President of ISAKOS in 2007–2009. In the summer season, during his precious free time away from the rigors of his academic commitments, he enjoyed sailing in the Mediterranean with his wife, Chiara.



Jan I. Gillquist, MD 1934–2016

Jan Gillquist was born in Sweden in 1934. He served on staff at the Department of Orthopaedic Surgery at University Hospital, Linköping, Sweden. Dr. Gillquist, together with Einar Eriksson, were the "Fathers of Arthroscopy" in

Europe. They started developing education courses in the beginning of the 1970s. He was the only person to be president of both IAA (International Arthroscopy Association) and ISK (International Society of the Knee). He organized the IAA/ISK combined meeting in Copenhagen in 1993, preceding the start of ISAKOS in 1995. Around 2002, he and his wife, Karola, retired from academic life and started the award-winning "Garden of Love". The garden covers roughly six acres, complete with thousands of roses and sculptures of Adam and Eve.



Pau Golanó, MD 1964–2014

ISAKOS Member since 2001, Dr. Golanó was a great surgeon and friend to many. He was a brilliant Professor of Pathology and Experimental Therapeutics at the University of Barcelona, and an Adjunct Professor in the Department

of Orthopaedic Surgery at the University of Pittsburgh School of Medicine. Dr. Golanó leaves behind a legacy with his exceptional anatomical dissection skills and passion for education. In May 2014, Dr. Golanó was honored with the Most Dedicated Individual Award at the 16th ESSKA Congress in Amsterdam. In addition to being a world-renowned surgical anatomist, Dr. Golanó spent his spare time as photographer and illustrator.



William A. Grana, MD, MPH 1942–2013

William A. Grana was born and raised in St. Louis, Missouri, USA and graduated from Harvard medical School. Grana was part of the Orthopaedic department at the University of Oklahoma Medical Center where he did extensive research on

artificial knee ligaments. In 1983, he founded the state's first multidisciplinary sports medicine facility, Oklahoma Center for Athletes. In 2000, he became the University of Arizona College of Medicine's first department head of Orthopaedic Surgery. He was past president of the American Orthopaedic Society for Sports Medicine. Even retired of his Faculty position, he was very active in Orthopaedic Education until his passing.



Robert W. Jackson, MD 1932–2010

Robert W. Jackson was born in Toronto, Canada, in 1932. Bob started Wheel Chair Sports in Canada in 1966 and was also the Canadian Olympic Consultant for the 1964 Olympics in Japan. In 1994, he was honored by Sports Illustrated

magazine as one of the 40 individuals who had most dramatically elevated and altered the games we play and watch by introducing arthroscopic surgery to the western world. He was a Professor of Surgery at the University of Toronto and Chief of Orthopedics at Baylor University Medical Center in Dallas. He was also appointed Professor of Surgery at the University of Texas Southwestern Medical Center.



Dr. James S. Mulhollan 1941–2013

James S. Mulhollan was a prominent knee surgeon in Little Rock, Arkansas. In the late 70s, Dr. Mulhollan recognized the arthroscope's potential to help patients overcome common knee problems without invasive procedures,

and decided to bring it to Arkansas. In 1979, he established a solo practice called Arkansas Knee Clinic. Dr. Mulhollan was recognized as one of knee arthroscopy's foremost practitioners. He was a member of the Board of Directors of the Arthroscopy Association of North America, taught courses around the country, and held five US patents for surgical devices used in the procedure. He retired having performed more than 10,000 cases of arthroscopic knee surgery.

Dr. Baskaran Subramaniam 1969–2013

Baskaran Subramaniam was a well known surgeon at Queen Elizabeth Hospital, Kota Kinabalu. He was particularly experienced in total joint surgery and sports medicine, specializing in Rugby. He had established clinics and did arthroplasty surgery in places like Keningau, Lahad Datu, Sandakan, Tawau and Labuan. Dr. Subramaniam also helped start a clinic with PERKESO that rehabilitated workers who had sustained a work place injury. He leaves behind a loving wife and three children.

III ASTAOR International Congress

24-25 March 2016

Moscow, RUSSIA

The Third ASTAOR International Congress in collaboration with ESSKA and ISAKOS, held in Moscow, brought together more than 500 experts in the field of traumatology, orthopaedics, rehabilitation and related specialties from 11 countries.

The event was organized by the Association of Sports Traumatology, Arthroscopy, Orthopaedic surgery, Rehabilitation (ASTAOR). Co-organizers of the meeting were: European Clinic of Sports Traumatology and Orthopaedics (ECSTO), European Medical Center (EMC) and PFUR Traumatology and Orthopaedics Department.

ASTAOR President, ECSTO Chief Doctor and Medical Director, PFUR Traumatology and Orthopaedics Department professor Andrey Korolev (Russia) and ISAKOS Educational Committee Chairman, Dr. Alberto Gobbi (Italy) became co-presidents of the Third ASTAOR International Congress.



The two-day scientific program of the meeting was full of lectures and oral presentations, general and round table discussions on the most important issues of sports traumatology, orthopaedics and rehabilitation, and was accompanied by numerous workshops given by world famous scientists.

A unique Presidents Meeting was organized within the Congress to unite more than 30 presidents of Russian and foreign scientific societies and associations, directors of medical institutes and heads of departments of traumatology and orthopaedics of the most respected medical universities in Russia. The main purpose of this meeting was to discuss plans for the widest possible involvement of specialists from Russian-speaking part of the world into the work of the international scientific societies of orthopaedics and traumatology.

ISAKOS Educational Committee Chairman, Congress co-president Dr. Alberto Gobbi, ESSKA Educational Secretary Prof. Pietro Randelli and SECEC-ESSSE Past President Dr. Jaap Willems presented the societies to Russian medical audience and spoke on the benefits of membership and cooperation with ESSKA, ISAKOS and SECEC-ESSSE.



During the III ASTAOR International Congress, a traditional Orthopaedic Scrub Nurse Course was held. It was organized under the supervision of EMC/Orlovsky clinic head nurse, NASA and Roscosmos certified nurse, Raksana Batsmanova.

The two-day course comprised lectures and practical training in the operating unit of one of the best private clinics in Russia - ECSTO (EMC).

ECSTO Chief doctor and Medical Director, Prof. Andrey KOROLEV also invited his foreign guests to the clinic, informed them about patient care organization and told about the latest clinic achievements, which earned high praise from the visitors.

The cultural program, organized for the foreign members of the Scientific Faculty was solidly considered as a magnificent and unforgettable one. Scientists visited the most popular Moscow museums, including The State Tretyakov Gallery, Memorial museum of Cosmonautics and Memorial house of Sergey Korolev, Prof. Korolev's grandfather, a great Soviet rocket engineer and spacecraft designer, father of practical cosmonautics. Another option to get introduced with the Russian history was city sightseeing tour around the capital of Russia. A ballet performance at the world famous Bolshoi Theatre definitely touched the hearts of the scientists.

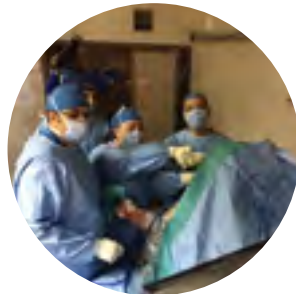
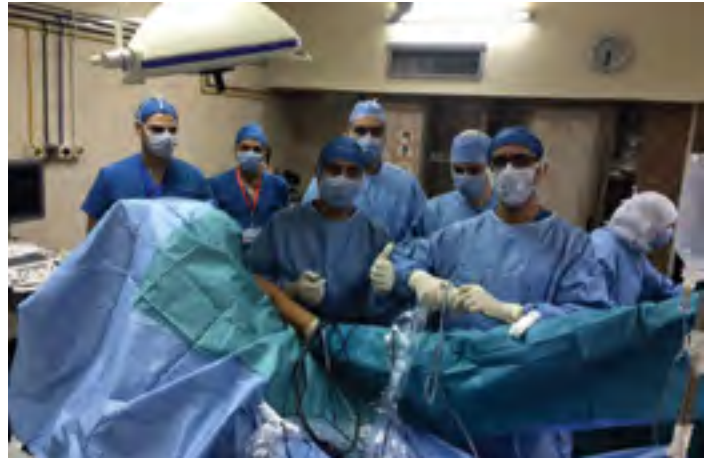
2nd Assiut Shoulder Arthroscopy Course

26-28 November, 2015

Assiut, EGYPT

The course was held at Assiut Arthroscopy and Sports Injuries unit and Anatomy Department of Assiut Faculty of Medicine. Participants had the chance to scrub in for live shoulder arthroscopic surgeries, watch the audio-visual transmission of these surgeries and discuss the technical details with expert course faculty from Egypt and Jordan. The candidates also practiced rotator cuff and Bankart repair on plastic models and for the first time in Egypt, the course allowed the trainees to perform the most important shoulder arthroscopy techniques on fresh cadavers in the anatomy department. Both model workshop and the wet lab had the same instruments used for live surgery. The 34 registrants from Egypt, Sudan and United Arab Emirates attended a series of lectures and discussions about the basic aspects of shoulder arthroscopy practice including clinical examination, imaging interpretation and decision making.




ISAKOS PUBLICATIONS



Full Access in myISAKOS

ISAKOS Members can access all official ISAKOS Publications through myPublications in myISAKOS—including *Journal of ISAKOS*!



www.isakos.com/myISAKOS

37th Annual Conference of Indian Association of Sports Medicine (IASMCON)

5-7 February, 2016

Chennai, INDIA

Sri Ramachandra University, Chennai hosted "IASMCON2016" – the 37th Annual Conference of the Indian Association of Sports Medicine – at its new state-of-the-art Sports Medicine Complex "SRASSC" inside the University campus.

The IASM was established in 1971 and has been conducting annual conferences for the last 36 years. It is affiliated with the International and Asian Federations of Sports Medicine. Its objectives include providing scientific guidance to sports fraternity, conducting research in sports medicine and sciences and organizing workshops, seminars for advancement of knowledge. The conference provides Continuing Medical and Professional Education in Sports Medicine, Arthroscopy, Sports Rehabilitation, Sports Science, Exercise Physiology and Sports Nutrition.

This edition of the conference saw over 20 international experts from USA, UK, South Africa, Middle East, Sri Lanka, Singapore, Malaysia, Thailand, and Australia along with 50 experts from across India sharing their knowledge with the nearly 400 delegates in attendance. Highlights of this year's conference were keynote lectures by Dr. Willem van der Merwe, ISAKOS 2nd Vice President and an eminent sports surgeon from South Africa, Prof. R.J. Abboud, a notable Biomechanics expert from University of Dundee, UK, Dr. Thurairaja who is a pioneer in Sports Medicine from Sri Lanka and Dr. S. Venkat a renowned orthopaedic surgeon from London.



There were three Pre-Congress Courses on Arthroscopy, Sports Medicine and Sports Rehabilitation which were certified by the Indian Association of Sports Medicine and Asian Federation of Sports Medicine. The courses featured didactic lectures and various workshops on Arthroscopic surgery, Sports Radiology, Exercise Physiology, Sports Biomechanics, Back Pain Rehab, Anthropometry and Kinesio-taping.



The Arthroscopy Course was a full-day event that covered basic and advanced arthroscopy techniques of Knee and Shoulder. Apart from the didactic lectures, five live surgeries were performed. The delegates observed the live surgeries and interacted with the surgical team through two-way audio-video communications.

The Main Conference took place over two days, and featured Keynote presentations, didactic lectures, networking interactive sessions, free scientific papers, and poster presentations on various tracks related to sports surgery and medicine. The Trade Exhibition featured more than a dozen stalls showcasing the latest in sports surgery and sports medicine to the participants of the conference. There were Fun Physical Activity events including Campus Run, Swimming & Rowing and Friendly Futsal to keep the participants occupied throughout. The conference also gave ample opportunities for faculty and delegate interaction over the Congress dinners along with rich entertainment.

In short, IASMCON 2016 provided a good platform in India for Doctors, Physiotherapists, Sports Science Professionals, Students, Sportspersons and Fitness Enthusiasts to interact with so many experts in one place. It also provided opportunities to network, exchange views and gain insights into the latest advancements in the field of Sports Medicine and Surgery.

2016 Metcalf/AANA Arthroscopy Course

3 February, 2016

Sun Valley, ID, USA

The Metcalf/AANA Arthroscopy Course had one of its most successful courses in 2016. Returning to Sun Valley, Idaho, participants were met with great skiing, perfect weather, and a tremendous program of faculty interactive discussion and education.

Comments from attendees included: “The best course I have ever been to;” “I have never seen a better combination of fun and learning in 20 years of coming to meetings;” “Burks really outdid himself with the program and case discussions.”



Robert T. Burks, MD
Course Chairman



John M. Tokish, MD
Course Co-Chairman

The Metcalf/AANA meeting began on February 3rd with an evening social where residents and fellows had the opportunity to meet and “rub elbows” with the faculty. Many old friendships were rekindled and new friendships formed over good wine and great stories. The formal program included 25 faculty from around the United States and was highlighted by Dr. Lars Engebretsen from Norway, who shared his experience in knee surgical advances, outcomes collection, and delivered an unforgettable keynote address on “The Life of an Olympic Doctor and the IOC trying to reduce injuries.”

Thursday began with discussion and debate surrounding the knee and biologics, including the latest research on stem cells, and adjunctives to surgical treatment. The hall was truly standing room only, as participants were treated to a lively debate and held to the fire by moderators who presented challenging questions and clinical scenarios. After a mid-day break where Sun Valley delivered absolutely perfect weather and ski conditions, we returned for an afternoon of discussion on the economic side of surgical practice management. The evening was capped with a wine and cheese social, where over thirty of the orthopaedic industry’s most innovative companies showcased their latest techniques and allowed for demonstrations and discussions between faculty, innovators, and participants alike. The venue remained at capacity attendance until the very end of the evening.

And this was just day one.

Friday’s program added moguls and ski jumps to the discussion, with a knee program that covered every possible pathology and solution, from osteotomy to the patella and cartilage to the knee in all ages of patients. There was no knee topic left uncovered by the faculty and moderators. Participants were treated to fresh snow and no lift lines for the mid-day break, delivering the kind of skiing that Sun Valley is famous for on her best days. The discussion resumed with great food and difficult cases and the night was capped off by our keynote address from Dr. Engebretsen, sharing his wisdom and experience from 30 years of caring for Olympic athletes. The venue was filled to capacity, and Lars delivered a truly inspiring message to all of us.

By Saturday, the program skis were fully waxed and sharpened for the shoulder – The faculty included no less than 4 subspecialty presidents and 12 nationally recognized experts debating the advances in rotator cuff, the AC joint and scapular dyskinesis. After more new snow and the final thrashing of everyone’s leg muscles on the ski slopes, the afternoon program brought together a “Who’s Who” of hip arthroscopists to discuss the latest innovations in hip preservation surgery. Participants had the evening to explore the world class restaurants in and around the Sun Valley resort, including a world class spa and outdoor thermal pool with views overlooking the mountains. Faculty caught a gondola up to the top of the mountain for an exquisite evening of great food, friends, and stories.

Sunday returned like a medal round on a downhill race. The topic was shoulder instability with lively discussion, innovation, and debate and in spite of it being the last day of the conference, the attendance was as full as it had been throughout the meeting. Steve Snyder, who has been there from the beginning, stood and proclaimed that this had been the best Metcalf he had ever attended.

This will only be true until next year. The Metcalf meeting will convene for its final time in 2017 at Snowbird, Utah. It will be the capstone of over 30 years of innovative teaching and the Metcalf Swan Song. The entire program will be double black diamond and everyone takes the lift to the top.



23rd Severance Arthroscopy Symposium: Knee & Ankle

24 January, 2016
Seoul, KOREA

The Symposium is a traditional arthroscopy symposium; it has been held at Yonsei University Health System in Seoul, Korea 23 times since 1995, and has been ISAKOS Approved Courses since 2004.

On behalf of the entire Symposium Program Committee, I would like to thank all the attendees and members of the Severance Arthroscopy Society for their great contributions.

The 23rd Severance Arthroscopy Symposium had 302 participants, and 33 distinguished speakers from all around the country delivered lectures in their areas of expertise.

The program was unique in that topics concerning knee and ankle arthroscopy were dealt with within a single symposium to help time-constrained surgeons to fast grasp the recent advances in the rapidly evolving field of Arthroscopy. In the Knee sessions, various topics ranging from multiple ligaments and meniscus injuries to osteotomy were dealt with in sufficient depth to actually help the audience better practice with confidence. In the Ankle sessions, topics concerning cartilage defect and chronic ankle instability were dealt and the audience paid a great deal of attention, reflecting the continuous enthusiasm in ankle arthroscopy.

After the symposium, the members of the Severance Arthroscopy Society and the speakers celebrated their friendship at the Symposium banquet.

The Severance Arthroscopy Symposium will continue to strive to enhance the opportunity to engage in exchange and dissemination of knowledge that the Severance Arthroscopy Society is famous for.



ISAKOS Approved Course & Teaching Center Applications

Applications for ISAKOS Approved Courses and Teaching Centers may be completed online at www.isakos.com

Apply today!



3rd ISAKOS Knee Course & 6th Pune Knee Course

22, 23 April 2016
Pune, INDIA

The Combined 3rd ISAKOS and 6th Pune Knee Course 2016 was held at Hotel J. W. Marriott, Pune. The event was a great success with about 650 Orthopaedic surgeons as delegates, as well as five international and 21 national faculties. The format of the meeting included Live Surgeries, Consensus Panel Discussions, Patient Evaluation sessions and didactic lectures. Special breakfast sessions were held to enable the Masters to interact with smaller groups of surgeons and give them a spectrum view on the concerned topics in arthroscopy.

The International faculty included Prof. Dr. Joao Espregueira-Mendes, Dr. Luigi Pederzini, Dr. David Parker, Dr. Alan Barber and Dr. Richard von Bormann.

Dr. Parag Sancheti & Dr. Sachin Tapasvi were the Course Chairmen, Dr. Dinshaw Pardiwala was the Scientific Chairman while Dr. Nilesh Kamat, Dr. Shirish Pathak, Dr. Shantanu Patil, Dr. Kailash Patil and Dr. Atul Patil were the course co-organizers.

The opening day started with six breakfast sessions chaired by stalwarts in the field of arthroscopy.

The main conference opened with an ACL Session. This was followed by a brief ISAKOS statement of Purpose and PKC-ISAKOS Oration on “ACL reconstruction in 2016 – controversies and consensus” by Prof. Dr. Espregueira-Mendes. This was given a standing ovation by the audience! Next, a live demonstration of ACL Reconstruction using bone-patella tendon-bone graft was shown. This was followed by ACL Consensus Panel Discussion. The Plenary lectures were again followed by a live surgical demonstration of a hybrid physeal sparing ACL reconstruction in an adolescent knee.

The post-lunch session started with a live surgical demonstration of Oxford Partial Knee Replacement. This was followed by a clinical evaluation session where the art of examining a knee with ligament injury was evaluated. This was especially targeted at young surgeons to underscore the vitality and significance of a thorough patient examination.

The First issue of the Asian Journal of Arthroscopy was then inaugurated by senior radiologist, Dr. Ram Tapasvi. A live surgery of a medial meniscus posterior root tear repair using a tibial tunnel was demonstrated. This was followed by a session on Surgical Options for Young Arthritic Knee.

A unique session called the “Fire-side Chats” was introduced for limited number of invited delegates in six different meeting rooms. It had sessions like Biomaterials & Meniscus Repair, Save the Meniscus, ACL Femoral Footprint, Conservative Management of the Knee Injuries, Complete Knee Symposium and Osteoarthritis Expert Forum, conducted for an hour simultaneously.

The course dinner was held at the same venue. It was indeed an excellent gathering for all the delegates since they had a unique opportunity to interact with the faculty members informally.

After the breakfast sessions, 23 April took off with the Cartilage Session. It started with a live demonstration of Osteochondral Cylinder Transfer Using the Fibular Head Autograft and was followed by a Cartilage Lesion Treatment consensus panel discussion.

A book compiled by Dr. Sachin Tapasvi on Patellofemoral Instability was launched by honorable Padmavibhushan Dr. K.H. Sancheti.

The Best Paper was then presented by the winner, Dr. Dinesh Choudhary on “Improving Femoral Component Rotation in Total Knee Arthroplasty by Combining the Salcus Line and Posterior Condylar Axis.” He was awarded a registration for the ISAKOS Congress in Shanghai, 2017. This was followed by a live surgical demonstration of Navigated High Tibial Osteotomy with Revision ACL. After that, another Live surgery of Trochleoplasty with MPFL Reconstruction was performed. Both these demonstrations were a treat to watch indeed and were widely appreciated!

The next session was the PCL and Multiple Ligament Deficient Knee Session which had talks like Failed PCL surgery-causes for failure and revision surgery and PCL surgery – when & how, followed by the acute multiple ligament injured knee treatment decisions.

Post lunch saw the Video sessions “How I Do It” – where four innovative video techniques, selected from the many received, were presented. Participants were encouraged to send in a 6-minute video of any new technique they had devised to make their surgery/practice/diagnosis easier. The Multi Ligament Instability Consensus Panel thereafter saw a lot of interactive discussion on managing this vexing issue.

This full scientifically packed program ended at 5:00pm as scheduled and we were overwhelmed to see the delegates glued to their seats in full strength till the very end. The Combined 3rd ISAKOS and the 6th Pune Knee Course concluded very successfully on a happy note. The delegates were satisfied and content giving positive feedbacks for hospitality, content of the course, the quality of the audio-visuals, the cases chosen for live demonstration and many more reasons. Most importantly, the schedule was followed minute to minute and the program, though fully packed with Live demonstrations and discussions with audience response system strictly followed the time-table.

VII SLARD Congress

1–4 June, 2016

Buenos Aires, ARGENTINA

The Latin-American Society of Arthroscopy, Knee Surgery and Orthopaedic Sports Medicine (SLARD) held its 7th SLARD Congress in Buenos Aires. More than 1,000 attendees were present to discuss and learn about the hot topics in arthroscopy and sports medicine—in their native language.

Cutting edge techniques and the best available data were presented via interactive formats. Eighteen hybrid symposia (lectures plus problem cases) were added to instructional courses and there were more than 150 podium presentations. Current controversies were addressed from different perspectives to allow for a comprehensive approach to patient care.

The 2016 SLARD Award to the best paper concerning shoulder pathology was awarded to M. Caloia, H. Caloia Gonzalez, D. Scotti and M. Lois for their talk entitled “Meniscal allograft and humeral resurfacing prosthesis for gleno-humeral arthritis in the young patient.”

AANA, was represented by its leadership, including Drs. Richmond, Angelo, Ryu, Abrams, Byrd and Hunter who all contributed substantially to the scientific and clinical discussions.

ISAKOS was represented by the current President Philippe Neyret and the Journal of ISAKOS Editor-in-Chief Niek Van Dijk. They gave many lectures and moderated the ISAKOS symposium and instructional course. In addition, the ISAKOS booth at the technical exhibit was visited by hundreds of colleagues looking for information about the upcoming ISAKOS Congress in Shanghai and the many advantages of membership.

The friendly Latin-American atmosphere always makes the SLARD Congress a fun and enjoyable event to attend. Don't miss the opportunity to join us at the 8th SLARD Congress in Curitiba, Brazil next year. We look forward to seeing you!

Guillermo Arce, MD
ARGENTINA
SLARD President 2014–2016

Benno Ejnisman, MD
BRAZIL
SLARD President 2016–2018

2017
11TH BIENNIAL
ISAKOS
CONGRESS
JUNE 4–8, 2017

REGISTER
TODAY



4th Theoretical and Practical Course of SIGASCOT on Patellofemoral Surgery Combined Meeting SIGASCOT IPSG Salone D'Onore-Palazzo Del Coni Rome, Italy

December 2-3, 2016

Chair(s): Alfredo Schiavone Panni, Giuseppe Milano

For further information, please contact:

Nives Sagramola
Tel: 0039 338 3837991
Fax: +39 055 4641490
WWW.SIGASCOT.COM

Orthopaedic Summit Evolving Techniques Mirage Hotel

Las Vegas, NV UNITED STATES

December 7-10, 2016

Chair(s): Kevin D. Plancher, MD

For further information, please contact:

Kevin D. Plancher, MD
Tel: 203-863-2003
Fax: 203-869-4040
www.orthosummit.com

2016 63rd, 64th Severance Arthroscopy Cadaver Workshop

Yonsei University Health System Seoul, KOREA, REPUBLIC OF

December 10-17, 2016

Chair(s): Sung-Jae Kim MD, PhD

For further information, please contact:

Gil Sung Yoon
Tel: +82-10- 9272-7471
Fax: +82-2-2227-7799
http://iseveranscopy.com

2017 International Sports Medicine Fellows Conference Sheraton Carlsbad Resort & Spa Carlsbad, CA UNITED STATES

January 20-22, 2017

Chair(s): Bert Mandelbaum, MD

For further information, please contact:

ISMF Course Office
Tel: 925-807-1190
Fax: 925-807-1199
www.ismf-conference.com

The 2nd Annual Meeting of the Academic Foot & Ankle Society (AMFAS) International 2017

Phyathai Nawamin International Hospital Bangkok, THAILAND

January 21, 2017

Chair(s): Chayanin Anghthong, MD, PhD

For further information, please contact:

Chayanin Anghthong
Tel: +66-81-989-2781
Fax: +66-2926-9793
http://footankle4u.blogspot.com/

Orthopedic Surgery Controversies 2017 Marriott Dana Cliffs Hotel

Dana Point, CA UNITED STATES

January 27-28, 2017

Chair(s): Wesley M. Nottage, MD

For further information, please contact:

Kathryn Snell
Tel: 949-632-7055
Fax: 949-581-8410
www.thesportsclinic.net

PISC 2017 - Paris International Shoulder Course

Marriott Rive Gauche, Congress Center Paris, FRANCE

February 9-11, 2017

Chair(s): Philippe Valenti

For further information, please contact:

Carine de Poncins
Tel: 0033 635323791
Fax: 0033 491945400
http://www.paris-shoulder-course.com

Delhi Arthroscopy Course 2017 The GRAND, Vasant Kunj New Delhi, INDIA

February 18-19, 2017

Chair(s): Dr. Deepak Chaudhary

For further information, please contact:

Deepak Joshi
Tel: +91 9810430634
Fax: +91 1126181917
www.sportsinjurycentre.nic.in

2017 Metcalf/AANA Arthroscopic Surgery Seminar Snowbird Ski and Summer Resort Snowbird, UT UNITED STATES

February 23-26, 2017

Chair(s): Robert T. Burks, MD

For further information, please contact:

Sue Duncan
Tel: 801-560-2446
Fax: 801-587-5411
www.metcalfmeeting.org

Lima Knee Symposium (LKS) 2017 Lima Chamber of Commerce

Convention Center Lima, PERU

March 2-3, 2017

Chair(s): Rolando Suarez, MD

For further information, please contact:

Rolando Suarez, MD
Tel: (+51)12641747
Fax: (+51)12643623
www.maeventosycongresos.com

Is your Course an...

ISAKOS
Approved-Course

www.isakos.com/meetings

UPCOMING ISAKOS APPROVED COURSES

Kasr Al-Ainy 2nd Cadaveric Shoulder Arthroscopy Course
Kasr Al-Ainy School of Medicine,
Cairo University
Cairo, EGYPT

April 6, 2017

Chair(s): Prof. Khaled Shohayeb

For further information, please contact:

Ahmed Fouad Seifeldin
Tel: +2 010 999 55 723
Fax: +2 37489841
<http://www.stylish-events.com/cs-course/>
<http://orthopaedics.kasralainy.edu.eg/>

17th Amsterdam Foot and Ankle Course
Academic Medical Center Amsterdam
Amsterdam, NETHERLANDS

July 12–13, 2017

Chair(s): Prof. C.N. van Dijk

For further information, please contact:

Gwendolyn Vuurberg
Tel: +31(0)205662474
Fax: +31(0)205669117
www.ankleplatform.com

3rd Advanced Amsterdam Foot and Ankle Course
Academic Medical Center Amsterdam
Amsterdam, NETHERLANDS

July 13–14, 2017

Chair(s): Prof. C.N. van Dijk

For further information, please contact:

Gwendolyn Vuurberg
Tel: +31(0)205662474
Fax: +31(0)205669117
www.ankleplatform.com

VIII Jornada Lyonesa no Brasil–ACL
Centro de Convenções de Goiania-GO
Goiania, BRAZIL

August 31–September 2, 2017

Chair(s): Guilherme Zuppi

For further information, please contact:

Vitor Padua
Tel: 55 14 991239932
Fax: 55 14 34549326
<http://rventos.net>

International Consensus Meeting on Cartilage Repair of the Ankle
Pittsburgh, PA UNITED STATES

November 17–18, 2017

Chair(s): John G. Kennedy, MD

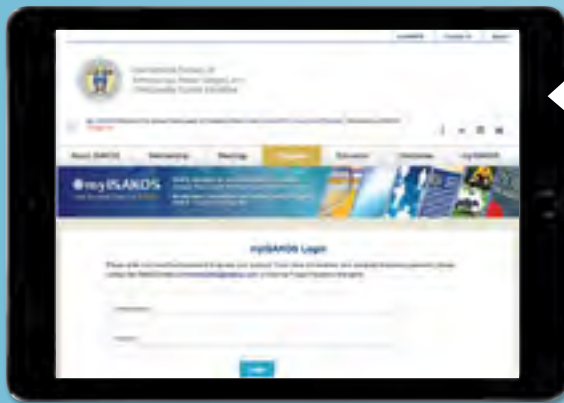For further information, please contact:

Christopher Murawski
Tel: 570 236 4628

ISAKOS SITE SELECTION

2023

REQUEST FOR PROPOSAL



Now available through your
myISAKOS profile

www.isakos.com/myisakos



ISAKOS



Knee Repair Solutions

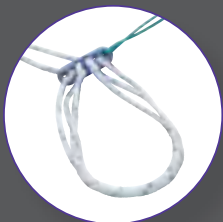When you demand performance from start to finish...

We've got you covered. Our comprehensive offering of arthroscopic knee repair solutions helps surgeons keep pace with the latest developments in knee repair – from meniscal-sparing techniques to anatomic ACL reconstruction – to preserve knee function and minimize the progression of osteoarthritis.


To learn more about our complete knee solutions, go to www.smith-nephew.com, contact your Smith & Nephew sales representative or call +1 800 343 5717.

Comprehensive product offerings for your next knee repair.

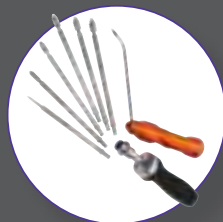ULTRABUTTON[°]
Adjustable
Fixation Device*



ACUFEX[°] PINPOINT
Anatomic ACL Guide
System**



**CLANCY[™] ANATOMIC
CRUCIATE GUIDE**
Flexible Drill System**



**ENDOBUTTON[°] CL
ULTRA**
Fixation Device**



FAST-FIX[°] 360
Meniscal Repair
System**



Supporting healthcare professionals for over 150 years

*Manufactured by:
ArthroCare Corporation
7000 West William Cannon Drive
Austin, TX 78735 USA

**Manufactured by:
Smith & Nephew, Inc.
150 Minuteman Road
Andover, MA 01810 USA

www.smith-nephew.com
T +1 978 749 1000
US Customer Service:
+1 800 343 5717

[°]Trademark of Smith & Nephew.
©2016 Smith & Nephew. All rights reserved.
Printed in USA. 05453 V2 07/16



International Society of Arthroscopy,
Knee Surgery and Orthopaedic Sports Medicine
2410 Camino Ramon, Suite 215
San Ramon, CA 94583-4318 USA

Telephone: +1 925 807-1197
Fax: +1 925 807-1199
isakos@isakos.com
www.isakos.com

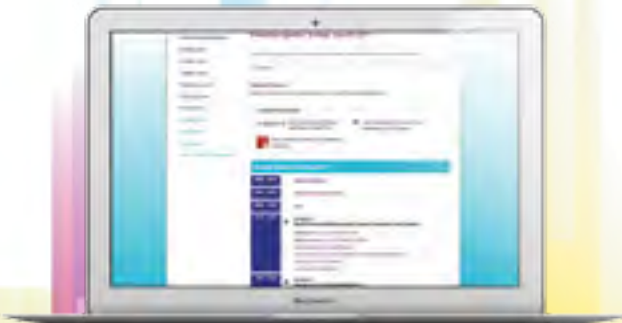


REGISTRATION NOW OPEN

INTERACTIVE AGENDA AVAILABLE ONLINE



View the complete schedule of events and faculty for the six Pre-Courses and Congress Scientific Program. Mark your favorites using the mySchedule feature!



11TH BIENNIAL

ISAKOS CONGRESS

JUNE 4-8, 2017 | SHANGHAI, CHINA