

ISAKOS

ISAKOS NEWSLETTER 2022 • VOLUME I

Current Concepts on Arthroscopy, Knee Surgery & Orthopaedic Sports Medicine



2023
CALL FOR ABSTRACTS
Open March 1

ISAKOS CONGRESS 2023
 Boston
Massachusetts
June 18 - June 21

SAVE the Date

ISAKOS CONGRESS 2021 | **GLOBAL**
Nov 27 - 28

BUENOS AIRES | **SAN FRANCISCO**

ISAKOS 2021: Global Congress WAS A **SUCCESS!**

INSIDE

- 6** ANNOUNCEMENT OF 2021-2023 BOARD OF DIRECTORS
- 11** 2021 AWARD AND FELLOWSHIP WINNERS
- 18** 2021 GLOBAL CONGRESS - A RECAP
- 30** CURRENT CONCEPTS FOR ORTHOBIOLOGICS IN ACL SURGERY
- 33** MENISCUS "AUTOTRANSPLANT"
- 36** REHABILITATION AFTER MENISCAL ROOT REPAIR
- 38** TOTAL KNEE ARTHROPLASTY
- 41** ALL-INSIDE SUTURE MENISCUS REPAIR
- 44** ADVOCACY FOR THE "EUROPEAN TOUCH" OF ANKLE ARTHROSCOPY

in this issue

Editor's Message	1
<i>JISAKOS</i> Editor in Chief's Message	4
2021 Global Congress—A Recap	18
Current Concepts	30
Approved Courses	68

EDITOR

Robert G. Marx, MD, MSc, FRCSC UNITED STATES

EDITORIAL BOARD

Iftach Hetsroni, MD ISRAEL, Associate Editor

Tahsin Beyzadeoglu, MD, Prof. TURKEY

Raju Easwaran, MS(Orth) INDIA

Joshua D. Harris, MD UNITED STATES

Michail I. Iosifidis, MD, PhD GREECE

Yee-Han Dave Lee, MD, MBBS, FRCS(Orth)
SINGAPORE

Daphne Ling, PhD, MPH UNITED STATES

Halit Pinar, MD, Prof. TURKEY

Dipak Raj, FRCS(Tr&Orth), MCh(Orth), MS(Orth)
UNITED KINGDOM

Sachin R. Tapasvi, MBBS, MS, DNB, FRCS INDIA

Samuel A. Taylor, MD UNITED STATES

Soshi Uchida, MD, PhD JAPAN

Kyoung-Ho Yoon, MD, PhD, Prof.
REPUBLIC OF KOREA

Omer Mei-Dan, MD UNITED STATES, Past Chair



**International Society of
Arthroscopy, Knee Surgery and
Orthopaedic Sports Medicine**

567 Sycamore Valley Road West
Danville, CA 94526–3900 USA
Telephone: +1 925 807–1197
Fax: +1 925 807–1199
Email: isakos@isakos.com

OFFICE MESSAGE

ISAKOS' 1st Virtual Congress



**ISAKOS
CONGRESS
2021**



GLOBAL
Nov 27 - 28

A Tremendous Success!

ISAKOS' first virtual Congress was a tremendous success! With nearly 2,000 registrants representing 100 countries, *ISAKOS 2021: Global* was a truly global and international experience.

We invite you to read more about the *ISAKOS 2021: Global Congress* on pages 18–25 of this newsletter. A special thank you and congratulations to Volker Musahl, 2019–2021 ISAKOS Program Chair, Marc Clatworthy, Program Deputy Chair, and the rest of the Program Committee for their diligent efforts over the past two years. Though the COVID-19 pandemic changed our plans for in-person Congress in Cape Town, ISAKOS would not have been able to successfully pivot to this virtual Congress without the direction and support of our leadership and committees. Thank you for your contributions!

During *ISAKOS 2021: Global*, Willem van der Merwe of South Africa passed the title of ISAKOS President to Guillermo Arce of Argentina. Learn more about Dr. Arce, his plans for ISAKOS, and an announcement of the 2021–2023 Board of Directors on page 2. The new committees for this term also are already hard at work, with consensus meetings, *JISAKOS* articles, webinars, books, and more in the works. A complete list of the 2021–2023 ISAKOS Committee members can be found on pages 26–29. Stay tuned for more information on upcoming committee projects—we encourage members to follow ISAKOS on social media and download the society mobile app for the latest updates.

It's not too early to start thinking about the next ISAKOS Congress! The 14th Biennial ISAKOS Congress is set to be held on June 18–21, 2023 in Boston, Massachusetts USA. We look forward to seeing all of our ISAKOS members, leadership, and faculty in person next year! The Call for Abstracts opens on March 1, 2022—submit your abstracts early and join us for #ISAKOS2023.

As we embarked on this new year, ISAKOS officially took the next step for the *Journal of ISAKOS*—moving to Gold Open Access with our new publisher, Elsevier! Authors who publish in *JISAKOS* can make their research work immediately, permanently, and freely accessible worldwide. ISAKOS members are eligible for a **20% APC discount!** Learn more at isakos.com/JISAKOS/Open-Access.

Also, as we headed into 2022, ISAKOS leadership outlined plans to explore new opportunities in education, research and infrastructure by updating ISAKOS' Strategic Plan with a new 3-year work plan. Over the next three years, ISAKOS aims to continue developing its education portfolio by trialing interim meetings between Congresses, by expanding surgical skills labs, and by making ISAKOS 2023 the #1 “must attend” global event for international surgeons in our specialty. ISAKOS also will continue to focus energy on building the *JISAKOS* content and reputation, while still publishing quality books that fill a topic or knowledge gap. We will be taking a look at our research infrastructure, as well, to identify ways to expand ISAKOS' commitment to supporting research. And of course, for membership—the foundation of our society—ISAKOS will continue increasing engagement of females and young professionals, while making the opportunity to become a member of ISAKOS more widely available, taking advantage of our global reach. To help us do so, ISAKOS has recently expanded our global group membership campaign to national and international societies around the world. Interested and eligible societies interested in a discounted rate for their members, who would be new to ISAKOS, should contact membership@isakos.com to learn more.

Cheers to an exciting start to 2022 and to all of the opportunities that lie ahead!

ISAKOS Meeting Virtually Great



Although my first trip to South Africa ended up being cancelled, the learning experience at our virtual meeting was incredible, as usual. There were over 1,900 registrants, which indicates our Society's thirst for knowledge. There were sixteen hours of live content, including lots of lively discussion. There were also over a hundred hours of on-demand content, which is still available to registrants on ISAKOS Global Link through 2022.

The best parts of this Congress for me included Freddie Fu's "ACL Career Highlights" lecture which was extremely well attended and very popular. Freddie was a visionary and a legendary leader for his faculty, but also for Orthopaedics worldwide, and especially ISAKOS. He will be missed very much not only by his family, but by the city of Pittsburgh and the orthopaedic community across the globe.

Willem van der Merwe from the host city, Cape Town, South Africa, presented a fantastic Presidential Lecture and also passed the Presidential Medallion to his successor Guillermo Arce from Argentina. Willem's hard work and dedication to the Society leave us in excellent shape despite the state of the world related to the pandemic.

I was also personally thrilled to see two close friends named 2021 honorary members. They were Past-President Philippe Neyret from France and Jon Karlsson from Sweden. Their tireless contributions to leading ISAKOS, as well as to advances in orthopaedic surgery and clinical research, have been paramount. This very well-deserved recognition for these two accomplished Professors was great to see.

Lastly, one of my favorite parts of our ISAKOS Congress is the in-person, informal discussion, networking and socializing with colleagues from around the world. Although this was not possible in the usual fashion, we did have well attended "welcome networking receptions" with breakout rooms by category and subject that were a good substitute. I look forward to resuming our in-person meeting in Boston, USA, in 2023 when we can raise a glass together and look back at having navigated this pandemic as well as possible.

Robert G. Marx, MD

ISAKOS Newsletter Editor
UNITED STATES



Greetings Everyone!

There are “big shoes to fill,” but I am ready for the job. It is a privilege for me to be included in this group of leaders—thank you.

—Guillermo Arce, MD ARGENTINA, President

I am honored to follow the strides of Willem van der Merwe and step into the role of the next ISAKOS President.

This role has been held by many legends in our field. There are “big shoes to fill,” but I am ready for the job. It is a privilege for me to be included in this group of leaders—thank you.

I was delighted to lead my national society, Argentine Arthroscopy Association, and then the continental society SLARD. Both experiences were extremely positive. With solid teams, we made our societies grow and expand good quality medical education all around our continent.

After these two exciting experiences, I look for a real Global Society to expand my knowledge with a broad perspective. What drew me to join ISAKOS was its unique, international platform, unlike any other association I knew.

I attended the first ISAKOS Congress in Buenos Aires in 1997 and joined ISAKOS as a member in 2001 at the Montreux Congress 21 years ago.

I was amazed then—and still am today—with ISAKOS' unbroken strides to be diverse, not only when it comes to programs and offerings but also with race, geographic regions, languages, and gender.

ISAKOS' reach is truly global. Today, ISAKOS gathers about 3,000 members—representing more than 90 countries. ISAKOS has about 150 female members, and close to one-third of our membership is under 45 years of age. I am very proud to be leading such a forward-thinking and inclusive society!

In the past two years, under the leadership of Willem van der Merwe, ISAKOS has grown and accomplished many things. One of the biggest to note is the growth of the *Journal of ISAKOS*, doubling submissions while achieving Medline/PubMed indexing, and following up the journal's move to open access with our new publisher, Elsevier.

The pandemic has presented the world with several challenges, and ISAKOS faces them with lots of work and wise decisions.

However, the pandemic has also opened new doors and opportunities for ISAKOS. It has given us the impetus to increase and ramp up virtual and digital education programs, and it has also allowed us to reach a broader audience.

The society launched many new educational offerings; including the very successful monthly ISAKOS Webinar series, our opening Knee Arthroplasty Virtual Course, more than ten new books published by the Committees, a new micro-learning library on Global Link, the Giants in Orthopaedic Sports Medicine video series, a brand-new mobile app, and so much more!

We have also taken the time to reevaluate and update ISAKOS' strategic plan with a new 3-year work plan. Thank you, all the participants. The brainstorming was critical for the future.

We encourage a continued increase in partnership and collaboration with our regional Partner Societies, who help us extend our reach. ESSKA, APKASS, SLARD, AANA, and AOSSM projects in common will always be a priority.

We will continue to support research initiatives, such as offering more than \$175,000 in grant funding for research in our specialty, an essential part of our ISAKOS mission.

During my term and the next few years, ISAKOS plans to enhance our education portfolio with more surgical skills labs, industry workshop partnerships, and additional interim courses between the biannual congresses. Please be ready to join us for these fantastic opportunities.

A new ISAKOS Task Force will focus on new technologies, AI, Big data, virtual reality training, robotics, and many other challenges to help members be updated with the cutting-edge technology.

For our daily practice, we need scientific knowledge and a solid skillset for surgery. But moreover, we need self-confidence, motivation, and inspiration to enjoy the time. By participating in ISAKOS, you are closer to getting these feelings.

I am sure that we are all anxious to get back together, meet in person once again and renew the international friendship and social networking that ISAKOS is known for!

It's never too early to mark your calendars for the 2023 ISAKOS Congress in Boston on June 18–21, 2023. And hopefully, we will find other opportunities to gather even sooner.

ISAKOS's future is bright. It has a fabulous team. A fantastic office led by Sue Reibold with good, creative and efficient people in her group. They always give their best to achieve our goals. Thank you.

In addition, we have a dream team at the Executive Committee and the Board of Directors fully committed to making ISAKOS the best society in the field.

Thank you to the ISAKOS family and colleagues. I am very excited to have this chance to lead our society and face the future together.

Our dream of a Global Society to learn, discuss controversies, meet consensus, make friends, and enjoy life, comes true by joining ISAKOS.

Thanks again for this terrific opportunity to lead the team.

My best wishes to you all in the New Year!

THANK YOU!

SAVE THE DATE



ISAKOS
CONGRESS
2023



Boston
Massachusetts
June 18–June 21

2023

www.isakos.com/2023Congress



JOURNAL OF ISAKOS

Joint Disorders & Orthopaedic Sports Medicine

Being Seen, Being Heard, Being Seen as a Human Being.

When I started my career in orthopaedics, about 6% of my work consisted of administration. In 2004 non-patient related activities had risen to 26%. I predicted in my inaugural address in 2002 that it would be 40% by 2024. But it already is and if it continues like this, it will be half of our work by 2024.

There is so much administrative load that there is only limited time to see the patient. Because of the limited time for each patient we rely more and more on the report of the radiologist. We order imaging for everything which as a consequence leads to a loss of clinical skills. The radiologist tells us what we have to do.

Machine Learning and robotics will certainly take over some of our work. Calculate probabilities and recognize patterns. According to Harari, general practitioners will be the first to be replaced by Artificial Intelligence doctors. But is that what we want? I recently visited the 170th anniversary congress of the Dutch Medical Association. One of the central themes was 'Doctors and patients in 2040'. The physicians in the auditorium were polled on the following question: "if you are a patient in 2040, what would you find most important?"

And the No. 1 response was "Being seen, being heard, being seen as a human being, not just a collection of lab results and MRI images".

In other words: Make eye contact with the patient and listen to the patient....the patient is always right!

That was the subject of this editorial in *JISAKOS*: Treat the patient, not the MRI! (*C Niek Van Dijk; Treat your patient, and not his MRI! Journal of ISAKOS: Joint Disorders & Orthopaedic Sports Medicine Jan 2020, 5 (1) 1–2; DOI: 10.1136/jisakos-2019-000419*)

The editorial was based on an article in which an MRI was performed in 30 professional volleyball players. They were all non-symptomatic, they all volunteered to take part in the study. In all 30—yes in 100%!—there was extensive pathology in the shoulders of all these athletes, ranging from (partial-) cuff tears in 65.4%, tendinopathy in 88.5 % and labral tearing and/or fraying in 46.2%. (*Lee CS et al JISAKOS 5.1 2020*)

These findings are not new. MRI findings in the lumbar spine of 98 elite junior tennis players (mean age 18 years) showed abnormalities in 94 of them. Disc degeneration was noted in 62.2% of players and disc herniation in 30.6% of these junior players. (*Rajeswaran G, Turner M, Gissane C et al Skeletal Radiology 43 (7) 2014 MRI findings in the lumbar spines of asymptomatic elite junior tennis players*)

These findings are not just typical for athletes. In a study of asymptomatic people—non-athletes—the prevalence of abnormal hip findings was 73%. (*Register B1, Pennock AT, Ho CP, Strickland CD, Lawand A, Philippon MJ. Prevalence of abnormal hip findings in asymptomatic participants: a prospective, blinded study. Am J Sports Med. 2012 Dec;40(12):2720–4. doi: 10.1177/0363546512462124. Epub 2012 Oct 25*)

In a study of 44 asymptomatic individuals (aged 20–68 years) with no history of knee pain, injury or bone or joint disease, MRI of the knee showed evidence of abnormality in 43 individuals. (*Beattie KA et al 2005 181–186 Abnormalities identified in the knees of asymptomatic volunteers using peripheral magnetic resonance imaging*)

What can we learn from all of this? Don't treat the MRI! Treat the patient.

Listen to the Patient—the patient is always right.

It is these type of articles which we like to publish in our *Journal of ISAKOS (JISAKOS)*. Meaningful articles which have impact on our practice. Your articles will be immediately, permanently, and freely accessible worldwide since, from January 2022 onwards, we are Gold Open Access!

We are Gold Open Access!

To submit a manuscript or see the latest issue of our Gold Open Access Journal, go to [JISAKOS.com](https://www.jisakos.com).



**C. Niek van Dijk, MD, PhD
NETHERLANDS**

Editor in Chief, *JISAKOS*
c.niekvandijk@jisakos.com

ISAKOS Research Grants

ISAKOS Research Grants are offered every two years (next term: 2021–2023) within four categories:

New Research

Four possible grants for eligible applications with scientific merit. One grant up to \$25,000 and three additional grants up to \$10,000 each.

- New Researcher grant qualification: has not received external funding over \$15,000; no significant history of publications, presentations or research/experiment participation

Translational Research

Four possible grants for eligible applications with scientific merit. One grant at up to \$20,000 USD and three additional grants at up to \$10,000 each.

- Foster high quality clinical or translational research in early osteoarthritis and prevention, as well as treatment of osteoarthritis.
- Could include total knee replacement, osteotomy, meniscal transplant, OCD transplant, etc.

Clinical Outcomes

One grant for eligible applications with scientific merit up to \$50,000.

- Support outcomes research through well-designed clinical trials to evaluate the efficacy of interventions in orthopaedic sports medicine
- Example: Level I–III study on biologics in Rotator Cuff repair

Countries with Limited Resources

Two possible grants for eligible applications with scientific merit. One grant at up to \$15,000 and one additional grant at up to \$10,000.

- Awarded to a Finalist from a Country with Limited Resources defined by the World Health Organization

The objective of the ISAKOS Research Grants is to encourage quality research in the topic areas of knee surgery, sports medicine and arthroscopy. Clinical relevance must be clearly noted in the abstract and specific aims and be obvious from the title and the study design. Both laboratory and clinical projects are suitable, but in either case, clinical relevance must be explicitly and clearly described.

Application Deadline is: **March 31, 2022**

Learn more at [isakos.com/researchgrants](https://www.isakos.com/researchgrants)

ISAKOS Welcomes the 2021 – 2023

ISAKOS Board of Directors

ISAKOS 2021 – 2023

Executive Committee



Guillermo Arce, MD ARGENTINA
President

David A. Parker, MBBS, BMedSc, FRACS AUSTRALIA
First Vice President

João Espregueira-Mendes, MD, PhD PORTUGAL
Second Vice President

Robert G. Marx, MD, MSc, FCS(SA)Ortho UNITED STATES
Treasurer

David H. Figueroa, MD, Prof. CHILE
Secretary

Mark G. Clatworthy, FRACS NEW ZEALAND
Assistant Treasurer

Jason L. Koh, MD, MBA UNITED STATES
Assistant Secretary

Alberto Gobbi, MD ITALY
Consultant

Laurie A. Hiemstra, MD, PhD, FRCSC CANADA
Consultant

Norimasa Nakamura, MD, PhD JAPAN
Consultant

Patrick S. H. Yung, FRCS(Orth), FHKCOS, FHKAM, FRCS,
MBChB HONG KONG
Consultant

Willem M. van der Merwe, MBChB, FCS(SA)Ortho
SOUTH AFRICA
Past President

ISAKOS

Members-at-Large

Nobuo Adachi, MD, PhD JAPAN, 2021 – 2025

Gian Luigi Canata, MD ITALY, 2021 – 2025

Myles R. J. Coolican, FRACS AUSTRALIA, 2021 – 2025

Benno Ejnisman, MD BRAZIL, 2019 – 2023

Jason L. Koh, MD, MBA UNITED STATES, 2019 – 2023

Philippe Landreau, MD UNITED ARAB EMIRATES,
2019 – 2023

Sebastien Lustig, MD, PhD, Prof. FRANCE,
2021 – 2025

Rodrigo Maestu, MD ARGENTINA, 2021 – 2025

Shuichi Matsuda, MD, PhD JAPAN, 2021 – 2025

Manuel F. Mosquera, MD COLOMBIA,
2019 – 2023

Peter Verdonk, MD, PhD BELGIUM,
2019 – 2023

Daniel C. Wascher, MD UNITED STATES,
2019 – 2023

Welcome the 2021
ISAKOS
Honorary
Members



Jon Karlsson, MD, PhD, Prof.
SWEDEN



Philippe Noel Neyret, MD,
PhD, Prof. FRANCE





ISAKOS CONGRESS 2021


GLOBAL
Nov 27 - 28

THANK YOU!

Thank you to the 2019 - 2021 ISAKOS Program Committee

Volker Musahl, MD UNITED STATES,
Chair

Mark G. Clatworthy, FRACS
NEW ZEALAND, Deputy Chair

Olufemi R. Ayeni, MD, PhD, MSc,
FRCS CANADA

John A. Bergfeld, MD
UNITED STATES

Deepak N. Bhatia, MS(Orth),
DNB(Orth) INDIA

Nicolaas Cyrillus Budhiparama,
MD, PhD, FICS, Assoc. Prof.
INDONESIA

Emilio Calvo, MD, PhD, MBA SPAIN

Felipe E. Cámara, MD MEXICO

Gian Luigi Canata, MD ITALY

Shiyi Chen, MD, PhD, Prof. CHINA

Moises Cohen, MD, PhD, Prof.
BRAZIL

Myles R. J. Coolican, FRACS
AUSTRALIA

Leandro Ejnisman, MD, PhD BRAZIL

Karl Eriksson, MD, PhD, Asst. Prof.
SWEDEN

Julian A. Feller, FRACS AUSTRALIA

Mario Ferretti, MD, PhD BRAZIL

Christopher D. Harner, MD, FAOA
UNITED STATES

Iftach Hetsroni, MD, Associate Prof.
ISRAEL

Per Hölmich, DMSc, Prof.
DENMARK

Kenneth J. Hunt, MD
UNITED STATES

Mark R. Hutchinson, Professor, MD,
FACSM, FAANA, FAAOS
UNITED STATES

José F. Huylebroek, MD BELGIUM

Dimitr A. Jontschew, MD GERMANY

Mustafa Karahan, Prof. TURKEY

Jon Karlsson, MD, PhD, Prof.
SWEDEN

Jason L. Koh, MD, MBA
UNITED STATES

Ryosuke Kuroda, MD, PhD JAPAN

John G. Lane, MD UNITED STATES

Sebastien Lustig, MD, PhD, Prof.
FRANCE

Stephen L. Lyman, PhD
UNITED STATES

Robert G. Marx, MD
UNITED STATES

Augustus D. Mazzocca, MS, MD
UNITED STATES

Jacques Ménétreay, Prof.
SWITZERLAND

Norimasa Nakamura, MD, PhD
JAPAN

Luigi A. Pederzini, MD ITALY

Sérgio R. Piedade, MD, MSc, PhD,
Assoc. Prof. BRAZIL

Ehud Rath, Prof. ISRAEL

Per A. Renström, MD, PhD
SWEDEN

Felix H. Savoie III, MD
UNITED STATES

Kevin P. Shea, MD UNITED STATES

Daniel A. Slullitel, MD, Prof.
ARGENTINA

Sachin R. Tapasvi, MBBS, MS, DNB,
FRCS INDIA

C. Niek van Dijk, MD, PhD
NETHERLANDS

Joon Ho Wang, MD, PhD
REPUBLIC OF KOREA

Stefano Zaffagnini, MD, Prof. ITALY,
Past Chair

Thank you to the 2021 Global Congress live broadcast studio hosts & faculty!

CAPE TOWN, SOUTH AFRICA PROGRAM

BROADCAST STUDIO HOSTS

Willem M. van der Merwe, MBChB, FCS(SA)Ortho

Pieter J. Erasmus, MBChB, MMed, FCS(Orth)

João Espregueira-Mendes, MD, PhD

Pieter D'Hooghe, MD, PhD

Faculty

Andrew A. Amis, PhD, FREng, DSc

David James Dandy, MD, FRCS

Peter J. Fowler, MD, FRCSC

Alan Getgood, MD, FRCS(Tr&Orth), DipSEM

Laurie A. Hiemstra, MD, PhD, FRCSC

Yuichi Hoshino, MD, PhD

Magaly Iñiguez, MD

James J. Irrgang, PT, PhD, FAPTA

Yasuyuki Ishibashi, MD

Camila Cohen Kaleka, PhD

Jon Karlsson, MD, PhD, Prof.

Jason L. Koh, MD, MBA

Elizaveta Kon, Prof., MD

Bryson P. Lesniak, MD

Jacques Ménétrey, Prof.

Mary K. Mulcahey, MD

Gary G. Poehling, MD

Leonardo Addeo Ramos, MD, PhD

Per A. Renström, MD, PhD

Laura C. Schmitt, PT, PhD

Bertrand Sonnery-Cottet, MD

Barry R. Tietjens, FRACS

BUENOS AIRES, ARGENTINA PROGRAM

BROADCAST STUDIO HOSTS

Guillermo Arce, MD

David H. Figueroa, MD, Prof.

Juan Pablo Previgliano, MD

Horacio F. Rivarola-Etcheto, MD

Faculty

Knut Beitzel, Prof.

Emilio Calvo, MD, PhD, MBA

Felipe E. Cámara, MD

David H. Dejour, MD

Giovanni Di Giacomo, MD

Benno Ejnisman, MD

Bassem T. Elhassan, MD

Karl Eriksson, MD, PhD, Asst. Prof.

Julian A. Feller, FRACS

Christian Fink, MD, Prof.

Michael T. Freehill, MD, FAOA, FAAOS

Christopher D. Harner, MD, FAOA

Eiji Itoi, MD, PhD

Masahiro Kurosaka, MD

Albert Lin, MD

Augustus D. Mazzocca, MS, MD

Giuseppe Milano, MD

Gilbert Moatshe, MD, PhD

Joan C. Monllau, MD, PhD, Prof.

Nicolas Pujol, MD

Romain Seil, MD, Prof.

Daniel A. Slullitel, MD, Prof.

Tim Spalding, FRCS(Orth)

Rene E. Verdonk, Prof em, MD, PhD

Daniel C. Wascher, MD

John Xerogeanes, MD

Masahito Yoshida, MD, PhD

Stefano Zaffagnini, MD, Prof.

SAN FRANCISCO, CA, USA PROGRAM

BROADCAST STUDIO HOSTS

Marc R. Safran, MD, Prof

Volker Musahl, MD

Felix H. Savoie III, MD

Miho J. Tanaka, MD

Faculty

John A. Bergfeld, MD

Nicolas Bonin, MD

William Bugbee, MD

Gian Luigi Canata, MD

Constance R. Chu, MD

Moises Cohen, MD, PhD, Prof.

Pieter D'Hooghe, MD, PhD

Leandro Ejnisman, MD, PhD

David H. Figueroa, MD, Prof.

MaCalus V. Hogan, MD, MBA

Kenneth J. Hunt, MD

Andreas B. Imhoff, MD, Prof.

Christopher C. Kaeding, MD

John G. Lane, MD

Paulo J. Llinas, MD, Prof.

Timothy Lording, MBBS, FRACS

Rodrigo Maestu, MD

Nicola Maffulli, MD, PhD, MS, FRCS(Orth)

Robert A. Magnussen, MD, MPH

Mihkel Mardna, MD

Augustus D. Mazzocca, MS, MD

Eric C. McCarty, MD

Michael McClincy, MD

Ehud Rath, Prof.

Nahum Rosenberg, MD, PhD, MOrthop, FRCS, Prof.

Seth L. Sherman, MD

Luís Eduardo P. Tírico, MD

Soshi Uchida, MD, PhD

Ivan Wong, MD, FRCSC, MACM, Dip. Sports Med

**SYDNEY, AUSTRALIA
PROGRAM**

BROADCAST STUDIO HOSTS

David A. Parker, MBBS, BMedSc,
FRACS

Mark G. Clatworthy, FRACS

Myles R. J. Coolican, FRACS

Julian A. Feller, FRACS

Faculty

Nobuo Adachi, MD, PhD

Annunziato Amendola, MD

Olufemi R. Ayeni, MD, PhD, MSc,
FRCS

Gregory I. Bain, MBBS, FRACS, PhD

Roland Becker, MD, PhD, Prof.

Alessandra Berton, MD

Deepak N. Bhatia, MS(Orth), DNB(Orth)

Matthew J. Brick, MBChB, FRACS

Nicolaas Cyrillus Budhiparama, MD,
PhD, FICS, Assoc. Prof.

Jiwu Chen, MD, PhD

Shiyi Chen, MD, PhD, Prof.

Andrew J. Cosgarea, MD

João Espregueira-Mendes, MD, PhD

John P. Fulkerson, MD

Benjamin R. Graves, MD

Joshua D. Harris, MD

Gregory A. Hoy, FRACS, FAOrthA,
FACSP, FASMF

Sebastián Irrarrázaval, MD

Ryosuke Kuroda, MD, PhD

Philippe Landreau, MD

Bo Liu, MD, FRCS

Sebastien Lustig, MD, PhD, Prof.

Margaret Fok, FRCSEd(Ortho), MBChB

Fabrizio Margheritini, MD

Robert G. Marx, MD

Philippe N. Neyret, MD, PhD, Prof.

Sam Oussedik, FRCS

Thierry Pauyo, MD, FRCSC

Marc J. Philippon, MD

Andrew James Price, DPhil,
FRCS(Orth)

Kristian Samuelsson, Prof, MD, PhD,
MSc

Parag Sancheti, FRCS (Ed),
MS(ORTH), DNB(ORTH),
MCh(UK), Ph.D(UK)

Vicente Sanchis-Alfonso, MD, PhD

Andrew Sprague, PT, PhD, DPT

Sachin R. Tapasvi, MBBS, MS, DNB,
FRCS

Francesco Della Villa, MD

Kate E. Webster, PhD



THANK YOU

FOR MAKING THE

ISAKOS 2021:

GLOBAL CONGRESS

A GREAT SUCCESS

CONGRATULATIONS TO THE ISAKOS AWARD & FELLOWSHIP WINNERS



In 1981, Dr. John J. Joyce III offered a monetary prize for the best arthroscopy paper read by an orthopaedic surgery resident or fellow during the Scientific Program of the 4th Congress of the International Arthroscopy Association in Rio de Janeiro. Joyce then endowed a prize to be awarded at every IAA Congress thereafter. The award was created with the intention to stimulate and reward younger members who contribute high-quality data and presentations.

1st Place

Quadriceps Tendon Autograft for Primary Anterior Cruciate Ligament Reconstruction show comparable clinical, functional, and patient reported outcome measurements, but lower donor site morbidity compared with Hamstring Tendon Autograft: A Matched-Pairs Study with a Mean Follow-Up Of 6.5 Years



Armin Runer, MD
GERMANY



Lukas Nawid Muench, MD
GERMANY

2nd Place

Association Between Meniscal Allograft Tears and Early Surgical Meniscal Allograft Failure



Philipp W. Winkler, MD
GERMANY

2nd Place

Progression To Glenohumeral Arthritis After Arthroscopic Anterior Stabilization In A Young And High Demand Population



Bobby Yow, MD
UNITED STATES

CONGRATULATIONS TO THE ISAKOS AWARD & FELLOWSHIP WINNERS



Jan I. Gillquist was a pioneer in the fields of knee surgery and sports medicine, well known for his dedication to the scientific method, most particularly related to the systematic approach to the entire chain of treatment of knee injuries; a correct diagnosis and pre-operative assessment, surgery and post-operative rehabilitation and the treatment of ACL injuries without surgery but with rehabilitation alone. According to Prof. Guillquist, "Everything was possible and nothing impossible to question." His passion was good science, correct science, and he was never afraid of sharp and critical questions; everything should be questioned and systematically studied.

1st Place

Predicting Subjective Failure of ACL Reconstruction: A Machine Learning Analysis of the Norwegian Knee Ligament Register and Patient Reported Outcomes



**R. Kyle Martin,
MD, FRCSC
UNITED STATES**

2nd Place

Increasing the Posterior Tibial Slope Results in Decreased In Situ Forces in the ACL



**Philipp W. Winkler, MD
GERMANY**



Former ISAKOS President, Gary G. Poehling, is an innovator, teacher and leader in the field of Arthroscopy—specializing in the elbow, wrist and hand. Beginning at the 2017 ISAKOS Congress in Shanghai, China, a monetary prize in honor of Dr. Poehling is to be awarded to the best Elbow, Wrist and Hand paper read during the scientific program of the ISAKOS Congress.

1st Place

TFCC Tears Should Only Be Repaired in Symptomatic Patients with Distal Radius Fracture



**Margaret Fok,
FRCSEd(Ortho), MBChB
HONG KONG**

2nd Place

A Textile-based Wearable System Designed for Monitoring Elbow Movements



**Umile Giuseppe Longo, MD,
MSc, PhD, Prof. ITALY**



Sponsored by The Patellofemoral Foundation, Inc.

The Patellofemoral Research Excellence Award was conceived in 2005 by the Patellofemoral Foundation and ISAKOS to encourage outstanding research leading to improved understanding, prevention and treatment of patellofemoral pain or instability.

Winner

The Pathologic Double Contour Sign and the Trochlea Shape Patterns Can Diagnose Trochlear Dysplasia



**Rafael Sales
Fernández, MD
UNITED KINGDOM**



**Danko D. Milinkovic, MD
GERMANY**

In 1989, The International Society of the Knee established a Young Investigator's Research Award in memory of Professor Albert Trillat. Past President and founder of the International Society of the Knee, Trillat was a pioneer in knee surgery and sports traumatology. This award provides recognition for a young researcher who has done outstanding clinical laboratory research contributing to the understanding, care or prevention of injuries to the knee.

Winner

The Bankart Knee: Biomechanical Consequences of a Posterolateral Tibia Plateau Impression Fracture As Concomitant Injury of ACL Rupture





Sponsored by DJO, Inc.

The Achilles Orthopaedic Sports Medicine Research Award was created in 1995 to recognize the researcher(s) who have performed the most outstanding clinical or laboratory research in the field of sports medicine, such as the care and prevention of injuries.

Winner

Identification of Predictive Risk Factors for the Development of a Stress Fracture within 6 Months in Female Elite Long-distance Runners



**Harukazu Tohyama,
MD, PhD JAPAN**



Sponsored by Nicolaas C. Budhiparama, Jr. & Inge Widjaja Nicolaas Institute of Constructive Orthopaedic Research & Education Foundation for Arthroplasty & Sports Medicine

The Paolo Aglietti Award for Knee Arthroplasty is in recognition of Professor Aglietti's numerous contributions to knee surgery as a prolific researcher, teacher and surgeon. Professor Aglietti served as Chairman of the ISAKOS Knee Committee and was ISAKOS President from 2007–2009.

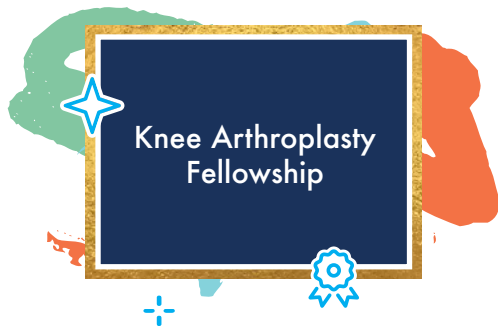Winner

Lateral Retinacular Release in Concordance with Medial Patellofemoral Ligament Reconstruction In Patients With Recurrent Patellar Instability–A Computational Model



**Umile Giuseppe Longo,
MD, MSc, PhD, Prof.
ITALY**

CONGRATULATIONS
ISAKOS CONGRESS
AWARDS & FELLOWSHIPS
WINNERS!



**Sponsored by Nicolaas C. Budhiparama & Inge Widjaja
Nicolaas Institute of Constructive Orthopaedic
Research & Education Foundation for Arthroplasty
& Sports Medicine**

Knee Arthroplasty Fellowships are available every other year to young orthopaedic surgeons interested in the study and advancement of Knee Arthroplasty. The dual purpose of the fellowship is to improve knee arthroplasty in developing nations and to promote better understanding and communication amongst knee surgeons around the world.

Recipients will present at the 2023 Congress in Boston, MA USA

The ISAKOS Global Traveling Fellowship is the marquee traveling fellowship offered by ISAKOS, established to foster the international exchange of knowledge and skills in the field of sports orthopaedic surgery. Fellows will have the opportunity to observe sports orthopaedic surgeries performed by highly respected surgeons, to discuss not only the surgical procedures but all aspects of patient management, and to discuss and share research experience.

Recipients



**Syed Faraz UI Hassan
Shah Gillani,
MBBS, MS Ortho, MME
PAKISTAN**



Amit Lakhani, MS INDIA



**Pamela Castro, MD
PERU**



**Saroj Rai, MD, PhD
NEPAL**



**Joseph Ruzbarsky, MD
UNITED STATES**



**Wybren van der Wal, MD
NETHERLANDS**



**Oyoo O. Were,
MBChB, MMed, Dip Sport Med
KENYA**



Patellofemoral Traveling Fellowship for 2019-2021

Sponsored by the Patellofemoral Foundation, Inc.

The Patellofemoral Traveling Fellowship was established in 2005 by the Patellofemoral Foundation and ISAKOS to promote better understanding and communication around the world regarding Patellofemoral pain. The Patellofemoral Traveling Fellowship is available on a competitive basis to an orthopaedic surgeon interested in the study and advancement of understanding of the Patellofemoral joint.

Recipients will present at the 2023 Congress in Boston, MA USA



**Juan Martinez-Cano,
MD, MSc COLOMBIA**



Maria Tuca, MD CHILE



ISAKOS Young Investigator Scholarship & Research Mentoring Program

The ISAKOS Young Investigator's Scholarship and Research Mentoring Program was developed by the ISAKOS Scientific Committee as a mentor-mentee program for young investigators with specific focus on developing countries. The Young Investigator program seeks to stimulate research and education in developing countries, foster international collaboration, and promote academic excellence in arthroscopy, knee surgery and orthopaedic sports medicine.

Recipients

Fabio V. Arilla, MD BRAZIL

Manit Arora, MS(Ortho), MSportsMed, MRCPS (Glasgow) INDIA

Purevdorj Avirmed, MD MONGOLIA

Girinivasan Chellamuthu, MBBS, MS INDIA

Anindya Debnath, MS, DNB INDIA

Mamo Deksisa Dessu, MD ETHIOPIA

Ignacio Garcia-Mansilla, MD ARGENTINA

Tarun Goyal, MS, MCh INDIA

Siti Maizatul Akmal Ismail, MS MALAYSIA

Makena Jean Mbogori, MBChB KENYA

Rodolfo Morales-Avalos, MD, MSc. MEXICO

Ramakanth Rajagopalakrishnan, D. ortho, DNB (ortho). D. SICOT INDIA

Sumit Jain Sethia, D. ORTHO, MS ORTHO INDIA


Kiran Kumar Shah, MD CHINA

Bhim Bahadur Shreemal NEPAL

Yogesh Soni, MS Ortho, DNB Ortho INDIA

Prasad Soraganvi, MBBS, MS, DNB, MRCS, SICOT-dip INDIA

Lokesh Kumar Yogi, MD INDIA



Access ISAKOS On-the-Go with the ISAKOS App

Connect with others through Anatomical & Specialty
Community Forums!



JISAKOS articles
one touch away



Directory of
colleagues at the
ready



Global Link videos
with the push of a
button



Congress
content instantly
accessible



ISAKOS

International Society of Arthroscopy,
Knee Surgery and Orthopaedic Sports Medicine

Download ISAKOS App





**ISAKOS
CONGRESS
2021**

GLOBAL
Nov 27 – 28

was a **GREAT SUCCESS!**

WELCOME & THANK YOU

Welcome to the *ISAKOS 2021: Global Congress!*

We appreciate your ongoing support and commitment to ISAKOS! Your participation and engagement has helped ISAKOS transition this year's Congress into a unique and truly international online meeting.

Coming To You From Around the World

We are excited to be broadcasting the ISAKOS Biennial Congress—16 hours of live programming—from four different studios around the world. We are starting here in Cape Town, then heading to studios in Buenos Aires, San Francisco, Sydney—with members of the ISAKOS presidential line serving as hosts, plus several in-studio guests.



JOURNAL OF
ISAKOS

Joint Disorders & Orthopaedic Sports Medicine

**JISAKOS 5th
Anniversary
Best Article**

Best Article on the Foot and Ankle

Posterior ankle arthroscopy:
current state of the art

Gwendolyn Vuurberg
Jorge Batista
C. Niek Van Dijk
Pieter d'Hooghe

Best Article on the Hip

Despite its current widespread use,
evidence to support the indications
for hip arthroscopy lags behind:
a review of current literature

Eyal Amar
Ivan H. Wong
Catherine M. Coady
Mark A. Glazebrook

Best Article on the Shoulder

Rotator cuff pathology:
state of the art

Matthias A. Zumstein
Mark Künzler
Taku Hatta
Lessa M. Galatz
Eiji Ito

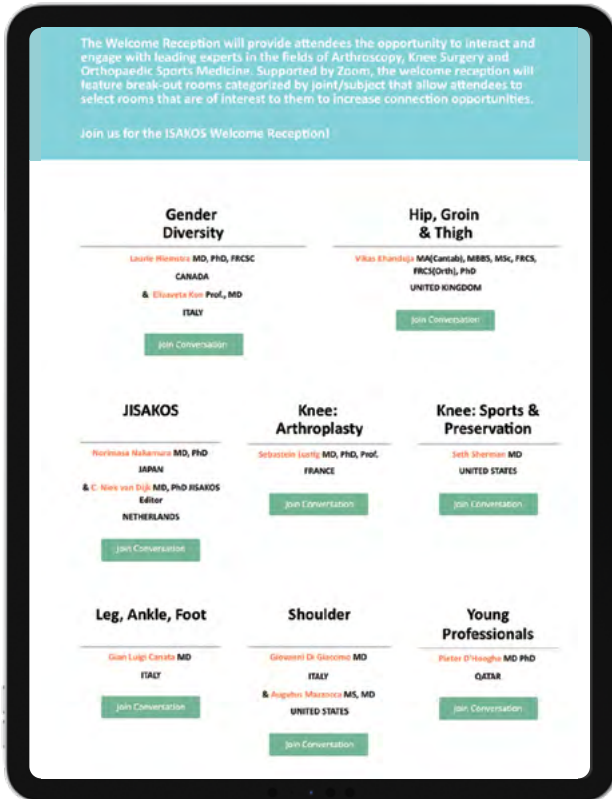
Best Article on the Elbow and Wrist

Optimal management of physéal
elbow injuries in the skeletally
immature athlete remains undefined:
a systematic review

Brittany E. Haws
Austin V. Stone
Andrew O. Usoro
Alejandro Marquez-Lara
Sandeep Mannava
Michael T. Freehill

WELCOME RECEPTION

The ISAKOS 2021: Global Congress Welcome Reception provided attendees the opportunity to interact and engage with leading experts in the fields of Arthroscopy, Knee Surgery and Orthopaedic Sports Medicine. Supported by Zoom, the welcome reception featured break-out rooms categorized by joint/subject that allowed attendees to select rooms that are of interest to them and maximize connection opportunities.



PRESIDENTIAL MEDALLION PRESENTATION

Dr. Willem van der Merwe of South Africa, ISAKOS President 2019–2021

passed the Presidential Medallion to

Dr. Guillermo Arce of Buenos Aires, ISAKOS President 2021–2023



CAPE TOWN SESSIONS





Increase Female Membership

- In **2018**, 106/2959 (3.6%) female members in ISAKOS
- In **2021**, 123 female members

Increase Female Involvement in Leadership

- 2018**, 11 female committee members in 14 positions
- 2019-2021**, 24 positions of 289 were filled by women, 2/53 Chair or Deputy Chair were women
- 2021-2023**, 30 female committee members in 262 positions, 10/58 Chair or Deputy Chair were women

ISAKOS JOIN 199
ISAKOS is a member of the International Society of Arthroscopy, Knee Surgery and Orthopaedic Sports Science (ISAKOS) and is a member of the International Society of Arthroscopy, Knee Surgery and Orthopaedic Sports Science (ISAKOS) and is a member of the International Society of Arthroscopy, Knee Surgery and Orthopaedic Sports Science (ISAKOS)





Raising our Profile




Women in Research

Gender Equality Task Force

- Freddie Fu - Patron
- Philippe Heyret - Patron
- Marc Safran
- Willem van der Merwe
- Guillermo Aron
- David Parker
- Joko Espreguiza - Member
- Mark Clatworthy
- David Figueroa
- Bob Marx





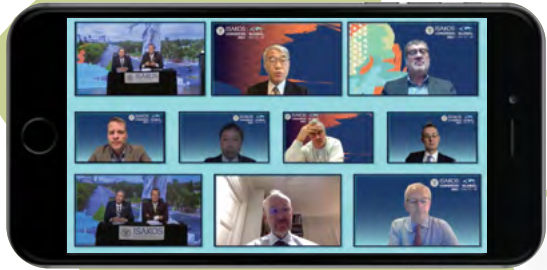
Presidential Guest Lecture

www.isakos.com/2021

#ISAKOS2021



BUENOS AIRES SESSIONS



SAN FRANCISCO SESSIONS

ISAKOS Executive Committee 2021-2023

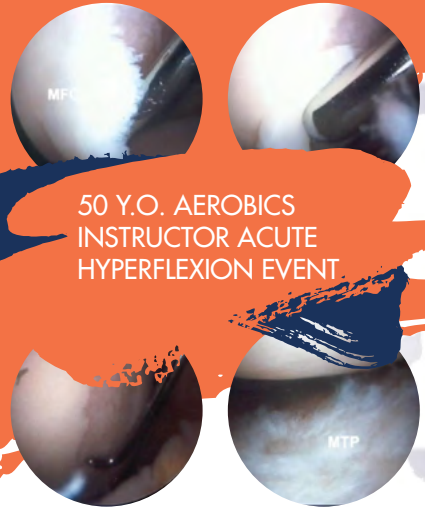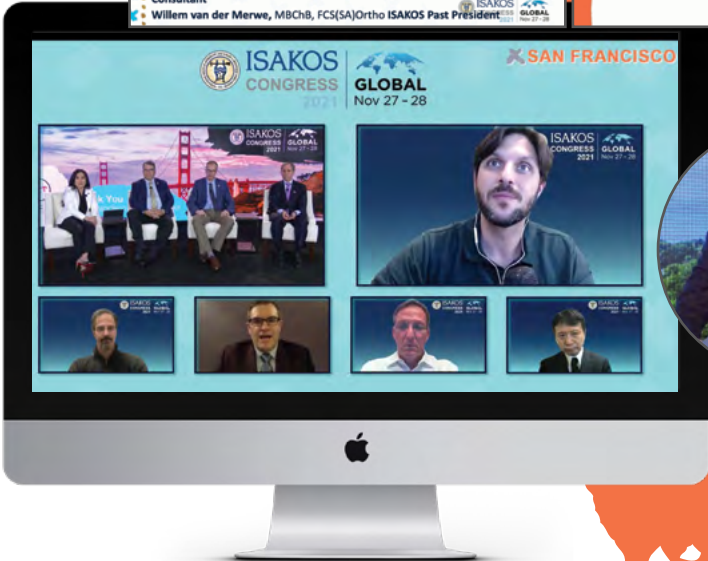
- Guillermo Arce, MD ISAKOS President
- David Parker, MBBS, BMedSc, FRACS ISAKOS 1st Vice President
- João Espregueira-Mendes, MD, PhD ISAKOS 2nd Vice President
- Robert Marx, MD ISAKOS Treasurer
- Mark G. Clatworthy, FRACS ISAKOS Asst. Treasurer
- David Figueroa, MD, Prof. ISAKOS Secretary
- Jason L. Koh, MD, MBA ISAKOS Asst. Secretary
- Alberto Gobbi, MD ISAKOS Consultant
- Laurie A. Hienstra, MD, PhD, FRCS ISAKOS Consultant
- Norimasa Nakamura, MD, PhD ISAKOS Consultant
- Patrick S. H. Yung FRCS(Orth), FHKCOS, FHKAM, FRCS, MBChB ISAKOS Consultant
- Willem van der Merwe, MBChB, FCS(SA)Ortho ISAKOS Past President

ISAKOS Board of Directors Member at Large

2019-2023	2021-2025
Benno Eijnsman, MD, BRAZIL	Nobuo Adachi MD, PhD, JAPAN
Jason Koh, MD, MBA, USA	Gian Luigi Canata MD, ITALY*
Philippe Landreau, MD, UAE	Myles R. J. Coolican FRACS, AUSTRALIA
Manuel Mosquera, MD, COLOMBIA	Sebastien Lustig MD, PhD, Prof., FRANCE
Peter Verdonk, MD PhD, BELGIUM	Rodrigo Maestu MD, ARGENTINA
Daniel Wascher, MD, USA	Shuichi Matsuda MD, PhD, JAPAN

Thank you to the departing ISAKOS Board of Directors Members at Large

- Nicolaas C. Budhiparama, MD, FICS, Assoc. Prof. INDONESIA
- Julian Feller, FRACS AUSTRALIA
- Alberto Gobbi, MD ITALY
- Yasuyuki Ishibashi, MD JAPAN
- Volker Musahl, MD USA



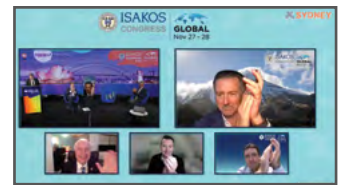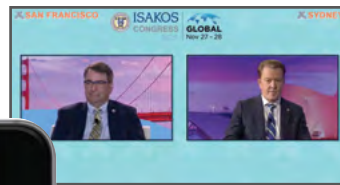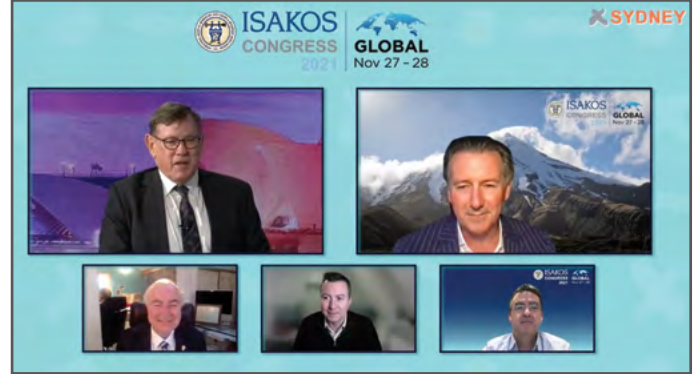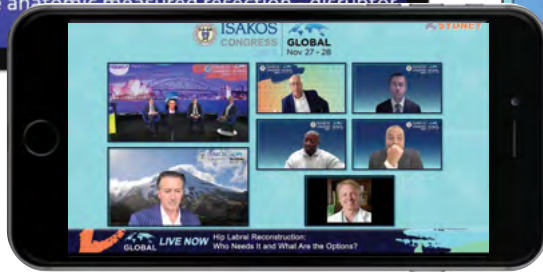50 Y.O. AEROBICS INSTRUCTOR ACUTE HYPERFLEXION EVENT.



SYDNEY SESSIONS

TKA Technique History

- Developed by John Insall & Michael Freeman - early 1970's
- Anatomic implant placement led to early failure so they moved to mechanical alignment with balanced gaps
Extension gap was balanced with ligament releases
The flexion gap was then created with a spacer block
- Femur First Measured Resection developed in the early 1990's. Primarily driven by implant companies who simplified technique by cutting the femur first and applying the same femoral rotation to most TKA's with the femoral sizing guide. As a consequence the femur and tibia are cut independently with the hope they marry up.
- Kinematic Alignment - True anatomic measured resection - disrupts



NOMINATING & 2ND VP



Recommendation Process for Office of ISAKOS 2nd Vice President

Recommendations for the position of the ISAKOS 2nd Vice President were received from Active & Honorary Members of ISAKOS. (August 1 –22, 2021)

Recommended Candidates were asked to confirm their willingness to serve if selected to be 2nd Vice President

Seconds were made by Active & Honorary Members for candidates for 2nd VP. (September 1 –15, 2021)

Each Recommended candidate had to receive 20 seconds to become a **Candidate for Consideration for the office of 2nd Vice President** by the Nominating Committee.

2021 Nominating Committee

- Chair (Past President)
 - Marc R. Safran, MD (North America)
- Two (2) Appointees by current President and Approved by BOD
 - Bert R. Mandelbaum MD, DHL(Hon) (North America)
 - Jon Karlsson Prof. (Europe)
- Four Members selected by the Membership
 - 1 Nobuo Adachi MD, PhD (Asia Pacific)
 - 2 Moises Cohen MD, PhD, Prof. (Latin America)
 - 3 Pieter D'Hooghe MD PhD (Africa/Middle East)
 - 4 Joan C. Monllau MD, PhD, Prof. (Europe)
- Past Chair (Non-Voting)
 - Philippe Neyret


ISAKOS 2nd Vice President 2021-2023

João Espregueira-Mendes, MD, PhD

CLOSING

Thank You to Our Broadcast Studios

The 2021 Congress programming was made possible by our Broadcast Studios, Local Hosts, the ISAKOS Program Committee, and all Chairs and Faculty.



THANK YOU

Thank you for joining us for the ISAKOS 2021 Global Congress!

We appreciate your ongoing support and commitment to ISAKOS. Your participation and engagement has helped ISAKOS transition this year's Congress into a unique and truly international, online meeting!



ISAKOS gratefully acknowledges our sponsors for the ISAKOS 2021: Global Congress

Smith+Nephew

CONMED DePuy Synthes rejoin+

ANIKA Arthrex Corin NEWCLIP TECHNIKS

BioTek EPISURF Medical Publishing Group ZIMMER BIOMET


ISAKOS 25 YEARS

Welcome to

ISAKOS 25th Anniversary:

The Road to Create ISAKOS
25 Years Ago.

Cape Town Program
Saturday November 27 at 16.00 UTC



CELEBRATING
25
YEARS
ISAKOS
1995-2020

HONORARY MEMBERS



Honorees are selected based on their exemplary services to ISAKOS, their global influence & leadership, and for their many contributions to the fields of arthroscopy, knee surgery and orthopaedic sports medicine.

ISAKOS congratulates two new Honorary Members; Jon Karlsson, MD, PhD, Prof. of Sweden and Philippe Neyret, MD, PhD, Prof. of France



“
If I have seen further, it is by of
standing on the shoulders of giants

—
Isaac Newton
...and of course Per Renström, Roland Jaokob and Rene Verdonk



1950 – 2021

Freddie Fu, MD MEMORIAL PRESIDENTIAL GUEST LECTURER

In honor of orthopaedic legend, **Freddie Fu, MD USA**, ISAKOS is proud to have shared his “ACL Career Highlights” with our community—he will be truly missed.



**ISAKOS
CONGRESS
2023**



Boston
Massachusetts
June 18–June 21

SAVE THE DATE

THANK YOU

to all for helping make the ISAKOS 2021:
Global Congress a success!

Please save the date for the 14th Biennial Congress
in Boston, MA, USA–June 18–21, 2023!

Call for Abstracts will open

March 1, 2022.

#ISAKOS2023



ISAKOS WOULD LIKE TO THANK THE FOLLOWING
SPONSORS FOR THEIR SUPPORT OF

ISAKOS 2021: GLOBAL



PLATINUM

Smith+Nephew

GOLD



SILVER



ANIKA



DJO®



An Update for the New Year



Jason Koh, MD
NorthShore University Health System
Sokkie, Illinois, UNITED STATES

The ISAKOS research grants program was established to inspire innovation among the Society's members and make a significant impact on scientific progress within orthopaedics. Now in its 10th year this program, led by the Society's Scientific Committee, continues to fulfill its goal of encouraging innovation and quality research in the topic areas of knee surgery, sports medicine and arthroscopy.

New for 2022, under the guidance of Scientific Committee members and supported by the Executive Committee, ISAKOS research grants have evolved to allow more access for new researchers and translational research projects. "We're excited to offer these new opportunities to ISAKOS members to apply for research grants in a variety of different areas," said Guillermo Arce, ISAKOS President. "The ISAKOS research grants program provides a meaningful way for members to get involved with research, wherever they are around the globe."

ISAKOS research grants cover four categories, including **"New Researcher"** grants, offered to up to four individuals for eligible applications with scientific merit. One grant is provided at up to \$25,000 USD and three additional grants at up to \$10,000 each. A new researcher is defined as an individual who has not received external funding over \$15,000, with no significant history of publication, presentations, or research/experiment participation.

"Translational Research" grants are awarded to up to four individuals for eligible applications with scientific merit, with one grant award offered at up to \$20,000 and three additional grants at up to \$10,000 each. This category of grants was established to foster high quality clinical or translational research in early osteoarthritis and prevention, as well as treatment of osteoarthritis.

The **"Clinical Outcomes"** grant category, offering one grant for eligible applications with scientific merit up to \$50,000, supports outcomes research through well-designed clinical trials to evaluate the efficacy of interventions in orthopaedic sports medicine.

"Countries with Limited Resources" grants are awarded to up to two individuals submitting eligible applications with scientific merit. Awardees come from countries defined as those with limited resources by the World Health Organization. Grant award amounts are provided at up to \$15,000 and another at up to \$10,000.

2019 – 2021 ISAKOS Research Grants were awarded to the following individuals for their studies:

- Jorge Chahla, MD, PhD UNITED STATES, (Clinical Outcomes: Operative vs. Non-operative Management of Posterior-medial Meniscal Root Tears: A Randomized Multicenter International Trial)
- Paulo H. M. Araujo, MD, PhD BRAZIL (Countries with Limited Resources: Correlation Between Knee Functional Scores and Pivot Shift Test Measurements In Anterior Cruciate Ligament Deficient)

- Duncan E. Meuffels, MD, PhD NETHERLANDS (Osteoarthritis: Early Signs of Osteoarthritis After ACL-Rupture; A Window of Opportunity for Osteoarthritis Prevention) and
- Ross Radic, MBBS FRANCS (Ortho) FEOrthhA AUSTRALIA (New Researcher: Hamstring Tendon Autograft versus Quadriceps Tendon Autograft for Anterior Cruciate Ligament Reconstruction: A Randomised Controlled Trial)

Reporting on the progress of his research, Dr. Chahla commented: "The ISAKOS grant allowed us to expand our initial single-center RCT study design into a robust international multi-center RCT intended to capture a more diverse patient population and increase the generalizability of the results from our study. The funds have provided us the ability to support permanent research staff for this study and a team of legal experts to manage protocol compliance and accurate data collection across 11 sites on 6 different continents. We hope the results from this investigation will provide impactful guidance to clinicians regarding the most optimal treatment option for meniscal root tears. We are confident these findings will result in multiple high-quality peer-reviewed publications."

Dr. Radic's update provided detail on the progress of his study: "The ISAKOS New Researcher Grant allowed us to set up a robust RCT study design to ensure high quality research. Our team has designed a study to compare the clinical outcomes of hamstring and quads tendon autografts for use in Anterior Cruciate Ligament Reconstruction. Dr. Radic and his team have completed patient recruitment, with final two-year data due by 2023, with Dr. Radic presenting interim data at the recent Australian Knee Society Clinical Meeting. Obtaining the research grant enabled the support of research staff to manage and ensure accurate data collection throughout the study, in addition to supporting an in depth clinical assessment by trained exercise physiologists at standard time points throughout the patient's recovery. We look forward to analyzing final clinical data, and envisage reporting our results at varied international meetings with a number of publications planned."

Dr. Meuffels offered a recent update to his study, stating: "10 years ago we selected a unique cohort of 154 patients with acute ACL injuries, who were prospectively characterized over the first two years post-injury. ACL rupture is a strong risk factor for knee OA. Unfortunately, there are no treatment options to prevent OA development in subjects with ACL rupture. Being able to predict occurrence of OA by relating early changes in symptoms and structural features to long-term disease development will enable the identification of new treatment targets for orthopaedic surgeons that could prevent future knee OA development. Also, it will allow for the identification of relevant subgroups of patients at high risk for future OA development that could serve as target population for future trials. The ISAKOS grant has enabled us to invite these participants for a ten-year follow up. Questionnaires, radiography and MRI will allow the evaluation of the natural course of structural and symptomatic knee OA development. COVID restrictions have slowed our planned research, but we have been able to examine and scan the majority of these knees. We are strongly motivated to finish this follow up and share our outcome with the worldwide ISAKOS community. We would like to thank the ISAKOS board and community for this valuable and unique support."

The Scientific Committee would like to encourage all active members who have an interest in applying for ISAKOS grant funding during the 2021 – 2023 grant cycle to review the grant application criteria and submit a proposal for a research grant. As is clearly demonstrated, these grants have been able to make a meaningful difference for researchers and patients, and it would be wonderful to have as many members participate in these funded activities. Grant applications must be completed and submitted by March 31, 2022.

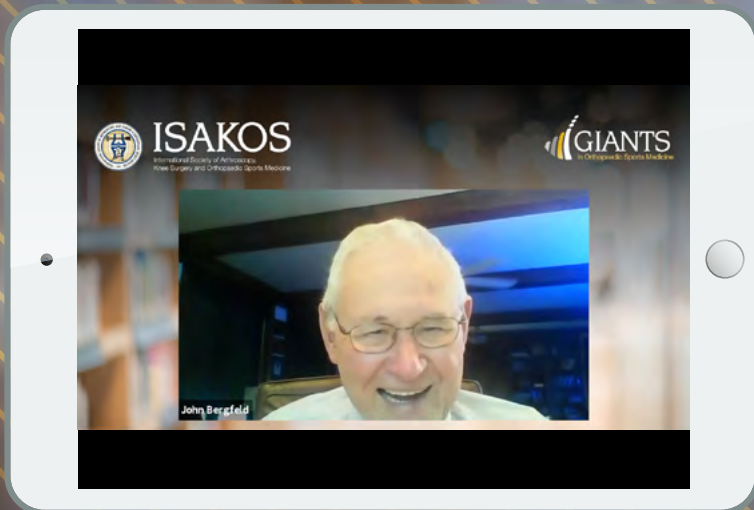


ISAKOS



ISAKOS has a new video series available on Global Link

Giants in Orthopaedic Sports Medicine



Each episode features an up-close interview with incredible legends of ISAKOS.

View the latest interview with ISAKOS Past President, John Bergfeld, MD from the United States.



Videos are available on Global Link and podcast versions are also available wherever you get your podcasts.

isakos.com/GlobalLink/Giants-in-Ortho



ISAKOS GLOBAL CONNECTION

Education, Research and Collaboration

Thanks Our Industry
Partners for Their
Educational Grant Support

Smith+Nephew



DJOTM
GLOBAL

To learn more or to make a donation, visit isakos.com/GlobalConnection

ISAKOS gratefully acknowledges the generous support of our Annual Fund donors*

Amaury Canate, MD, MEXICO

Jesus Ignacio Cardona-Munoz, MD, MSc, MEXICO

Yi Hung Chiang, MD, PhD, TAIWAN

Jose Prospero Hernandez de la Fuente, MD, MEXICO

Jaime Espinoza, MD, CHILE

Freddie Fu, MD, UNITED STATES

Albert O. Gee, MD, UNITED STATES

Marek Kacer, MD, POLAND

Jun Koh, MD, PhD, Professor, KOREA, REPUBLIC OF

Daisuke Mori, MD, JAPAN

Hiroaki Nishioka, MD, PhD, JAPAN

Martin Jervis Nsubuga, MB, Bh, BAO, FRCSI, NORWAY

Juan Miguel Osorio, MD, PANAMA

Andreas Panagopoulos, Associate Professor, GREECE

Akira Tsujii, MD, PhD, JAPAN

Jinzhong Zhao, MD, CHINA

ISAKOS thanks the following individuals for their generous support of the Society and participation in the ISAKOS Godfather / Godmother program*

John A. Bergfeld, MD, USA

Ramon Cugat, MD, PhD, SPAIN

Freddie Fu, MD, USA

Michele C. Johnson, USA

Marco Patacchini, MD, ITALY

Sue Reimbold, MA, CAE, USA

Sachin Tapasvi, MBBS, MS, DNB, FRCS, INDIA

Rene Verdonk, MD, PhD, BELGIUM

* July 1, 2021–January 15, 2022



ISAKOS
International Society of Arthroscopy,
Knee Surgery and Orthopaedic Sports Medicine

Current Concepts for Orthobiologics in ACL Surgery



Reha N. Tandogan, MD, Prof.
*Ortoklinik & Cankaya Orthopedics,
Orthopaedics & Traumatology;
Ankara, TURKEY*



Tahsin Beyzadeoglu, MD, Prof.
*Beyzadeoglu Clinic, Orthopaedics &
Traumatology, Istanbul, TURKEY
Halic University, Faculty of Health
Sciences; Beyoglu, Istanbul, TURKEY*



Kerem Yildirim, MD
*Beyzadeoglu Clinic, Orthopaedics &
Traumatology, Istanbul, TURKEY
Istanbul Gelisim University,
Faculty of Health Sciences;
Avcilar, Istanbul, TURKEY*

Introduction

Although reconstruction with autologous tendon grafts is accepted as the gold standard treatment in anterior cruciate ligament (ACL) injuries, failures and re-ruptures are still a concern in younger patients returning to high-impact sports. There is a need for strategies to improve graft healing, accelerate recovery, and decrease failures.

Autologous regenerative orthobiologics such as platelet-rich plasma (PRP), platelet-rich fibrin (PRF), autologous conditioned plasma (ACP), and mesenchymal stem cells (MSCs) derived either from adipose tissue or bone marrow aspirate concentrate (BMAC) have been widely used in the treatment of sports injuries in the last two decades. The use of these orthobiologics to accelerate functional recovery and to improve graft maturation after ACL reconstruction have been extensively studied; however, the clinical benefit of these additional interventions needs to be clarified. Another area of interest is the role of orthobiologics in the treatment of partial ACL tears, with PRP having been used with microfracture to create a healing response. Orthobiologic augmentation also can be an option to improve the maturation of allografts in ACL reconstruction.

Although orthobiologics have been used in a variety of studies to enhance ACL surgery, the preparation, composition, and dosing of these agents are not standardized.

Moreover, several different delivery methods are available, such as intraligamentary or intra-articular injection, local application on the tendon graft surface, local injection into the bony tunnels, or multiple intratendinous depot injections.

Several recently published randomized clinical trials and high-quality meta-analyses have expanded our knowledge on orthobiologics. The aim of the current article is to summarize the current status of PRP, PRF, and stem cells in ACL surgery.

ACL Surgery and Healing

The primary goal of ACL reconstruction is to create a stable knee with good biomechanical properties similar to those of the native ACL. A successful outcome depends on the healing quality of the reconstructed graft. The 3 phases of the autograft maturation process are inflammation, proliferation (reparation), and remodeling. Growth factors such as platelet-derived growth factor (PDGF), transforming growth factor beta (TGF- β), insulin-like growth factor (IGF), fibroblast growth factor (FGF), and vascular endothelial growth factor (VEGF) have been reported to take part in every step of the healing process, with the ability to activate the membrane receptors in integrins and enhancing the production of components of collagen matrix¹.

PRP

PRP is thought to play the greatest role in the inflammatory phase as it has been shown to increase the release of growth factors intra-articularly². Although PRP is used as a universal term to describe concentrated platelets and growth factors, the preparation of PRP has differed widely among studies. Several classification systems have been proposed to better define the properties of the injected material, taking into account the platelet concentration, spin count, presence of leukocytes and red blood cells, activation method, and injection technique.

Studies on the use of PRP in ACL reconstruction surgery have focused on several processes, such as integration of the graft into the tibial and femoral tunnels, tunnel widening, graft maturation, mechanical properties of the reconstructed ACL, anterior tibial translation, knee function, harvest-site healing, and pain reduction following ACL reconstruction with both bone-patellar tendon-bone (BPTB) and hamstrings autografts³. A recent meta-analysis of 17 randomized controlled trials demonstrated better pain and IKDC scores at 6 months in knees treated with PRP as compared with controls; however, this benefit was not significant after 1 year⁴. The biological augmentation effect was less clear, with only one-third of the studies favoring PRP to facilitate graft-healing, reduce harvest-site morbidity, and prevent tunnel widening.

Graft Integration and Maturation

Although early studies provided mixed results after PRP applications in ACL reconstruction, recent data have shown only a non-significant difference in favor of PRP in terms of graft integration and maturation³. Some studies have shown significantly improved and faster maturation and ligamentization of the graft, but no long-term clinical or functional benefits^{2,3}. A systematic review of 11 studies showed that PRP had positive effects on graft maturation in 6 studies, with one study finding no difference³. However, these changes did not translate to better clinical outcomes or IKDC scores in most of the studies.

Tunnel Widening

A recent meta-analysis showed that PRP use provided no benefit with regard to tunnel widening as assessed with magnetic resonance imaging (MRI) and computerized tomography (CT)³. Interestingly, one study showed non-significant differences in favor of the control group.

Mechanical Properties

Studies on the effect of PRP on the mechanical properties of the reconstructed ACL (including linear stiffness, maximum load, and yield) also have been contradictory, with results in favor or no benefits of PRP use².

Functional Outcomes and Knee Stability

Several studies have evaluated functional outcome scores (including IKDC, Tegner, and Lysholm scores) after ACL reconstruction combined with PRP application, but none have demonstrated significant improvement in association with PRP³. A recent meta-analysis of 9 studies involving 525 patients showed that the addition of PRP to primary autogenous ACL reconstruction provided no improvement in objective outcomes such as ligamentization and tunnel widening while providing only small, clinically insignificant improvement in Lysholm scores, VAS scores, and knee laxity.

Another meta-analysis of 13 randomized controlled trials evaluating the efficacy of PRP on ACL reconstruction in 765 patients showed no clinical improvement in outcome scores, regardless of graft type (hamstring and bone-patellar tendon-bone autografts and allografts)³. Two of the analyzed studies demonstrated improved MRI findings in association with hamstring autografts.

Healing of the Donor Site and Pain

Early studies showed that the application of PRP to the donor site provided a slight benefit in terms of bone filling of the donor site and patellar tendon healing as compared with controls. However, a more recent, double-blinded, randomized controlled trial of 50 patients demonstrated no benefit of PRP on the patellar donor site of BPTB grafts at all time points³. De Andrade et al., in a recent meta-analysis of 4 studies, found that the addition of PRP to the patellar donor site resulted in decrease in pain scores at 6 months follow-up, but this effect disappeared at 24 months.

Moreover, this reduction in pain did not reach clinical relevance and did not lead to better functional knee scores.

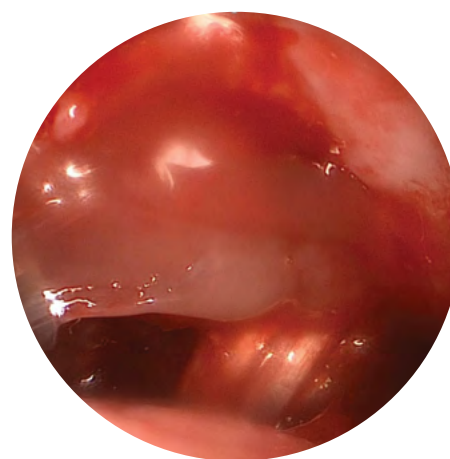
Partial ACL Injuries

The efficacy of intra-ligamentous autologous conditioned plasma (ACP) combined with microfracture at the femoral insertion site for the treatment of partial ruptures of the ACL was evaluated in 42 patients⁵. The authors reported excellent IKDC, Tegner, and Lysholm scores at 33 months of follow-up, with negative pivot-shift tests and a side-to-side difference of 0.6 mm in knee laxity. Return to sports was possible in 71% of the patients at 6 months. However, that study lacked a control group. A recent systematic review identified 6 case series with encouraging results but stressed the need for randomized controlled trials⁵.

PRF

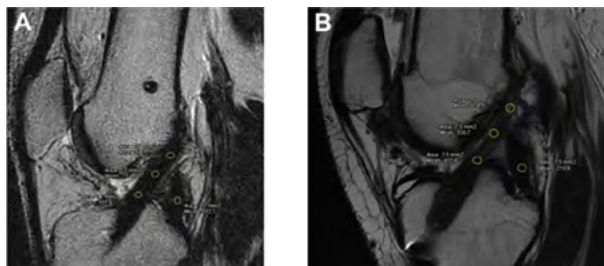
PRF has been shown to cause a sustained release and protection against degradation of endogenous fibrogenic factors, facilitating enhanced wound-healing. PRF also has been shown to reduce matrix metalloproteinase-9 (MMP-9) by 139-fold while concentrating the presence of a variety of growth factors that enhance tissue regeneration by 1.6-fold to 75-fold. However, clinical studies on the use of PRF in ACL surgery are scarce¹.

In 2014, a prospective study showed that the use of PRF matrix (PRFM) augmentation in ACL reconstruction did not improve radiologic graft integration and knee stability after 1 year but provided a short-term improvement of subjective knee function⁵. However, in 2020, another study demonstrated that the use of PRF provided better MRI maturation characteristics in the proximal third of the graft at 5 months, along with better hemostasis, while providing no improvement in clinical outcomes¹ (Figures 1 and 2).



01 Application of platelet-rich fibrin in the setting of dry arthroscopy.

Current Concepts for Orthobiologics in ACL Surgery



02A With platelet-rich fibrin. 02B Without platelet-rich fibrin.

Evaluation of the graft's maturation according to signal intensity and the presence of synovial fluid at the tunnel-graft interface on the MRI taken at the fifth postoperative month¹.

Stem Cells

Stem cells have the capacity for self-renewal (giving rise to more stem cells) and the ability to differentiate into tissues of various lineages under appropriate conditions. MSCs may be derived either from adipose tissue (ADMSC) or bone marrow (BMAC).

There is a lack of consensus regarding the use of ADMSC and BMAC in ACL surgery, with only a small number of studies reporting limited results. In 2012, a study on the use of BMAC in ACL surgery showed that application of non-cultivated bone marrow stem cells did not accelerate the graft integration to the femoral tunnel. In 2019, another study showed that the use of ADMSC provided no advantage in terms of knee function, pain, or graft maturation⁵.

Conclusion

Early enthusiasm for the biologic augmentation of ACL injuries and favorable animal studies have not translated to better clinical outcomes. Orthobiologics may have positive effects on graft incorporation and maturation and early postoperative pain scores; however these benefits are clinically insignificant and do not result in better knee stability or lower failure rates. Further well-designed, controlled studies are needed to define the exact role of these biological agents.

References

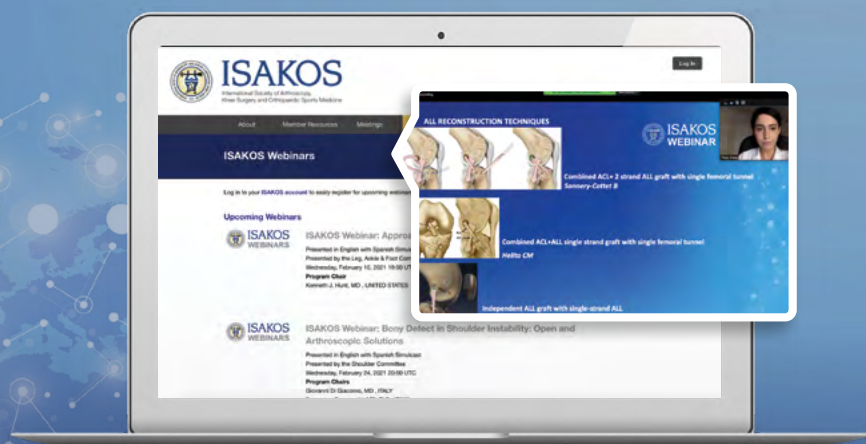1. Beyzadeoglu T, Pehlivanoglu T, Yildirim K, Buldu H, Tandogan R, Tuzun U. Does the Application of Platelet-Rich Fibrin in Anterior Cruciate Ligament Reconstruction Enhance Graft Healing and Maturation? A Comparative MRI Study of 44 Cases. *Orthop J Sports Med.* 2020 Feb 20;8(2):2325967120902013. doi: 10.1177/2325967120902013. PMID: 32128315; PMCID: PMC7036517.
2. Wasserman A, Matthewson G, MacDonald P. Platelet-Rich Plasma and the Knee-Applications in Orthopedic Surgery. *Curr Rev Musculoskelet Med.* 2018 Dec;11(4):607-615. doi: 10.1007/s12178-018-9521-0. PMID: 30215165; PMCID: PMC6220003.
3. Trams E, Kulinski K, Kozar-Kaminska K, Pomianowski S, Kaminski R. The Clinical Use of Platelet-Rich Plasma in Knee Disorders and Surgery-A Systematic Review and Meta-Analysis. *Life (Basel).* 2020 Jun 25;10(6):94. doi: 10.3390/life10060094. PMID: 32630404; PMCID: PMC7344495.
4. Lv ZT, Zhang JM, Pang ZY, Wang Z, Huang JM, Zhu WT. The efficacy of platelet rich plasma on anterior cruciate ligament reconstruction: a systematic review and meta-analysis. *Platelets.* 2021 May 28:1-13. doi: 10.1080/09537104.2021.1902969. Epub ahead of print. PMID: 34048294.
5. Kon E, Di Matteo B, Altomare D, Iacono F, Kurpyakov A, Lychagin A et al. Biologic agents to optimize outcomes following ACL repair and reconstruction: A systematic review of clinical evidence. *J Orthop Res.* 2021 Feb 15. doi: 10.1002/jor.25011. Epub ahead of print. PMID: 33586785.



ISAKOS WEBINARS

ISAKOS Webinar Collection

Available on Global Link!
View the entire collection of webinars presented by the ISAKOS Committees and featuring world-renowned faculty discussing a variety of current trends and techniques.



Join a LIVE Webinar!

For a schedule of upcoming webinars, visit

isakos.com/webinars



Meniscus “Autotransplant”: A Meniscal Retensioning Surgical Technique for Treatment of Meniscus Extrusion in Early Knee Osteoarthritis



Ricardo Bastos
*Clínica do Dragão,
Espregueira-Mendes Sports Centre–
FIFA Medical Centre of Excellence,
Porto, PORTUGAL*



Renato Andrade
*Clínica do Dragão,
Espregueira-Mendes Sports Centre–
FIFA Medical Centre of Excellence,
Porto, PORTUGAL*



João Espregueira-Mendes
*Clínica do Dragão,
Espregueira-Mendes Sports Centre–
FIFA Medical Centre of Excellence,
Porto, PORTUGAL*

The Concept

Treatment of osteoarthritis (OA) is still a challenge in orthopaedics, particularly when dealing with the knee joint. Synovial, ligaments, subchondral bone, meniscus, and particularly, cartilage tissue are affected, and the damage is progressive and irreversible. The biological characteristics of the cartilage, especially the absence of vascular supply and the consequent limitation of repair capacity, lead to unsatisfactory and limited options of treatment.

Conservative treatment of early OA progression consists of measures considered to be palliative. The natural history of the disease cannot be modified, and OA continues to progress. Although temporary relief of symptoms can be achieved, cartilage tissue deteriorates and is not restored. Anti-inflammatory and analgesic medications can be effective for relieving pain and other symptoms, but potential complications associated with long-term use are an important concern. Chondroprotective agents such as chondroitin and glucosamine sulfate are substances that are present in the native cartilage and have been developed in an attempt to restore the cartilage structure. Unfortunately, the performance is limited to a questionable relief of pain and a

long-term option of medication. Changes in activities of daily life and weight loss are important, but, in most cases, can be considered an “impossible mission” for patients with lack of motivation due to pain and mobility limitations. Corticosteroid injections also can be considered, but such treatment has only short-term efficacy and is associated with deleterious local and systemic effects.

Surgical treatments for knee early OA are also very questionable. Arthroscopic debridement procedures can be considered in some cases but have been associated with unpredictable results and with the possibility for serious complications related to meniscectomy (e.g., knee osteonecrosis). Osteotomies around the knee are effective in cases of unicompartmental OA associated with lower-limb varus or valgus deformities. However, progression of the disease often leads to the deterioration of outcomes over time. Moreover, femoral and tibial osteotomies are invasive, often require hardware for osteosynthesis, and occasionally are associated with complications related to over- or under-correction, infection, and delayed bone-healing or non-union. Meniscal transplantation, performed following meniscectomy for the prevention or treatment of early OA, has been associated with good results in the literature but has important restrictions related to allograft availability. At the end of the line, total knee replacement (TKR) can be considered but is always an irreversible option. Rarely indicated for early OA, TKR is the most invasive procedure and is associated with high rates of complications.

Tissue engineering and regenerative medicine (TERM) is a promising option for the treatment of symptoms and the regeneration of damaged tissue, especially for cartilage lesions. A considerable amount of scientific research has emerged regarding intra-articular injections of stem cells and platelet-rich plasma in knees with OA. Pain relief and symptomatic improvement can be achieved, but satisfactory regeneration of cartilage tissue has not been observed.

Unsatisfactory results after conservative treatment and severe complications after aggressive surgical treatment have suggested the need for a more effective, reliable, and minimally invasive option for the treatment of early OA. Meniscal extrusion is commonly observed on the magnetic resonance imaging (MRI) scans of knees with early OA. This abnormality, similar to a meniscal root tear, is comparable with a total or subtotal meniscectomy. A knee with an extruded meniscus loses the biomechanical capacity to distribute loads and to protect cartilage tissue, resulting in exacerbation of the symptoms related to OA. In order to address these anatomical and biomechanical meniscal dysfunctions, we developed a minimally invasive surgical technique for the treatment of early OA in knees with an extruded meniscus, with the aim of restoring the native position and protective function of the meniscus.

Meniscus “Autotransplant”: A Meniscal Retensioning Surgical Technique for Treatment of Meniscus Extrusion in Early Knee Osteoarthritis

Surgical Technique

Step 1: Preoperative Planning and Patient Selection

The indications for the procedure include early OA of the knee, normal limb alignment, radiographic and MRI findings consistent with unicompartmental OA (Kellgren-Lawrence grade 1 to 3), and an extruded meniscus in the damaged compartment.

The patient is positioned supine with the tourniquet at the proximal aspect of the thigh.

Step 2: Arthroscopic Procedure and Articular Evaluation

The surgical retensioning technique can be used for both the medial and the lateral meniscus. Here, we describe a medial meniscus retensioning procedure; in the case of the lateral meniscus, the arthroscopic portals have to be exchanged.

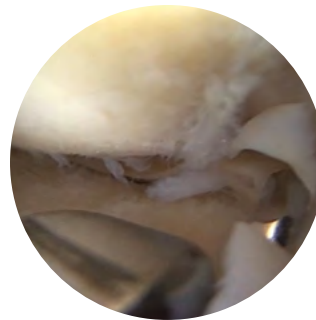Conventional anteromedial (AM) and anterolateral (AL) arthroscopic portals are created, and a 10-mm cannula is inserted in the AM portal to facilitate the articular procedures. The distance between the anterior and posterior meniscal root insertions is measured with a 60° arthroscopic measurement probe that is introduced through the AM portal.

Step 3: Posterior and Anterior Tibial Tunnel Drilling

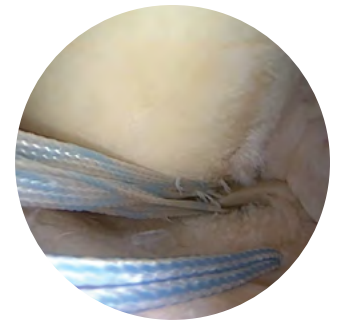A 6-mm inside-out tunnel is drilled from 10 mm anterior to the posterior attachment of the meniscus to the AL cortex of the tibia with use of a meniscal root marking hook (Figure 1). With the same technique, a 6-mm anterior tunnel is drilled from 10 mm posterior to the meniscal anterior horn attachment to the AM cortex of the tibia.

Step 4: Meniscus Posterior Horn Suture

A SutureLasso with Nitinol passing wire is passed through the AL tibial tunnel and is recovered with a mini suture retriever through the AM portal. A loop is created with a 2–0 Fiberwire as a shuttle suture and is passed down through the tibial tunnel. The FiberWire loop is maintained at the AM portal while the two extremities of the wire are passed through the tibia. A Knee Scorpion suture passer preloaded with 1.3-mm SutureTape is used to tie the midportion of the posterior horn of the meniscus at 20 mm medial to its insertion. Consequently, a second stitch is made 10 mm medial to the first tape with another 1.3 mm SutureTape. Both tapes are passed through the AL tibial tunnel (Figure 2).

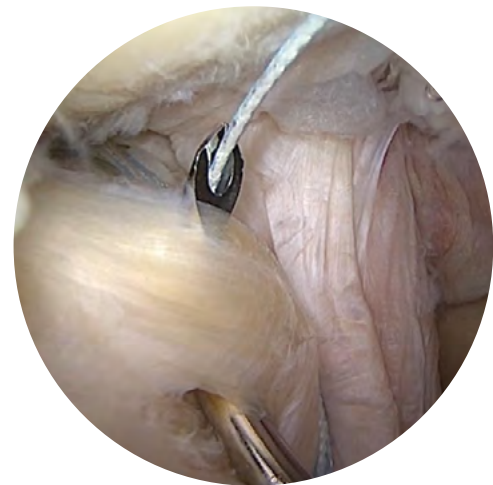

01 Posterior tibial tunnel drilling through the anterolateral cortex.



02 Passage of SutureTapes through the anterolateral tibial tunnel.

Step 5: Meniscus Anterior Horn Suture



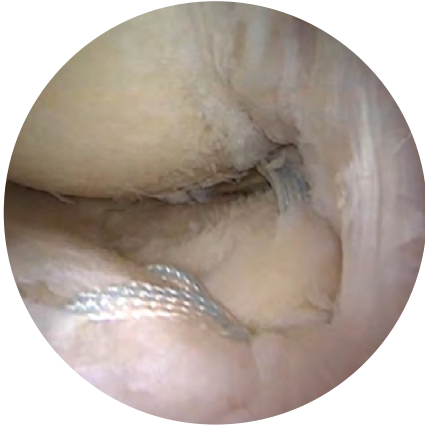03 The midportion of the anterior horn of the meniscus is punched using a QuickPass Lasso.

Step 6: Meniscal Tensioning and Tibial Fixation

After the anterior and posterior meniscal horns are sutured, the tapes are tensioned until the meniscus displaces to its original position, with use of the peripheral limits of the tibial joint surface as a reference. The midportion of the extruded meniscus is reduced and centralized, and the joint-space opening can be easily seen (Figure 4). Tibial fixation is performed with two 11-mm concave ABS buttons after the final desired tension is achieved.

Postoperative Management and Rehabilitation

The patient is allowed to immediately start active flexion of the knee but is restricted to 90° during the first 4 weeks. Partial weight-bearing is maintained during the initial 6 weeks. Following the initial 6 weeks, range of motion is increased as tolerated and full weight-bearing is gradually allowed. Rehabilitation is focused on restoring full knee range of motion, patellar mobilization, quadriceps muscle activation and strength, effusion control, and pain management.



04 Reduction and centralization of the midportion of the extruded meniscus

Discussion

The meniscus has an important role in preventing articular cartilage degeneration. Radiographic changes that are observed in knees with OA, such as compartmental space narrowing and limb alignment changes (varus or valgus), can be explained by meniscal loss of function due to extrusion. Therefore, in knees with meniscal extrusion, restoration of the native meniscal position and function can be performed for the purpose of reestablishing the protective function of the meniscus in terms of the absorption and distribution of forces.

The presented surgical technique provides a less-invasive, biological option for the treatment of unicompartmental OA that can simultaneously achieve the aims of a meniscal root repair and a meniscal transplantation. By retensioning the native extruded undamaged meniscus, we can achieve a “meniscal auto-transplant.” This term seems to be very appropriate as the protective function of the meniscus can be restored in a patient with an extruded meniscus that biomechanically could be considered to be meniscectomized. The presented arthroscopic procedure is a minimally invasive option for the treatment of early OA with the potential to relieve pain, avoid disease progression, and postpone the need for more complex procedures such as knee replacement.

In summary, meniscal retensioning or “meniscal auto-transplantation” can increase meniscal coverage in the compromised compartment, prevent cartilage degeneration, decrease subchondral bone exposure, restore compartmental space, and, consequently, relieve symptoms related to early OA.

An expanded version of this technique with a step-by-step video demonstration is available in Arthroscopy Techniques¹.

Reference

1. Espregueira-Mendes J., Andrade R., Silva L., Pereira P., Sevivas N., Bastos R. (2019). Meniscus subluxation retensioning: “autotransplant”. Arthroscopy Techniques.



Dear ISAKOS Members,

ISAKOS Annual Membership fees for 2022 were **due by December 31, 2021**

To avoid disruption of any of your ISAKOS member benefits, including ISAKOS Books and Global Link, please renew your membership at isakos.com/myISAKOS/membership.

You may also contact membership@isakos.com or +1 925-807-1197 for assistance with your renewal.

THANK YOU

for being a valued member!

Rehabilitation After Meniscal Root Repair: Current Concepts



Theodorakys Marin Fermin, MD
*Aspetar Orthopaedic and Sports
Medicine Hospital,
Doha, QATAR*



Ashraf Hantouly, MD, MSc
*Orthopaedic Surgery Department,
Hamad General Hospital,
Doha, QATAR*



Konstantinos Epameinontidis, PT
*Aspetar Orthopaedic and Sports
Medicine Hospital,
Doha, QATAR*



Emmanouil Papakostas, MD, FEBSM
*Aspetar Orthopaedic and Sports
Medicine Hospital,
Doha, QATAR*

Introduction

The menisci are anatomical structures composed of water and a network of fibroelastic cartilage, glycoprotein, and proteoglycans, that are responsible for shock absorption, weight distribution, joint congruency, and knee stabilization. They are crescent-shaped and attach to the tibial plateau by their anterior and posterior extremities (known as the horns or roots).

The function of the menisci heavily relies on its indemnity. The harmonious force transmission from the femur to the tibia depends on the equilibrium between the meniscal extrusion induced by loading and the counteraction of the meniscal circumferential fibers tensile stress, the so-called “hoop stress.” Thus, injuries can profoundly impact the ability of the menisci to decrease focal loading and protect the knee articular cartilage.

Meniscus root avulsion and radial tears within a centimeter of the insertion site are equivalent to total meniscectomy and translate into rapid deterioration of knee articular cartilage. Such abnormalities are found in 7%–9% of patients and can be categorized as acute or chronic tears. Acute lateral meniscus root tears are 10 times more likely to be associated with ACL injuries. In contrast, chronic or degenerative injuries are more common in the medial meniscus posterior root tear and concurrently up to six times more with cartilage defects. Nevertheless, they remain underdiagnosed and unrecognized.

A growing body of literature on the importance of meniscal root repair has been established in the last decade, and several promising techniques have been described. However, postoperative rehabilitation remains yet to be standardized.

Postoperative Rehabilitation of Meniscal Root Tears

The evidence concerning rehabilitation following meniscal root repairs is mainly based on animal and human cadaveric biomechanical studies. To date, there have been no comparative studies between rehabilitation protocols. Therefore, combining the findings of those studies, biological principles, and healing time ensures a comprehensive postoperative rehabilitation approach².

It is essential to regularly incorporate a rehabilitation phase to improve injury recovery and readiness for surgery, similar to what is recommended for ACL reconstruction rehabilitation. Systematic cryotherapy, range of motion exercises, and isometric strengthening will help to reduce joint effusion while preserving the strength and motion of the injured knee before any surgical intervention.

Abraham et al.², in an in vitro biomechanical study involving six human cadaveric knees, found that the highest pressure in the posterior root of the medial meniscus occurred during static loading with the knee in full extension, with even greater pressure after ACL transection.

Stärke et al.³, in a study of six human cadaveric knees, reported that internal femoral rotation resulted in incremental increases in tensile forces on the repaired posterior root of the medial meniscus³. In contrast, flexion of up to 120° resulted in no significant variations in tensile forces on the posterior root.

Steineman et al.⁴, in a study of 16 ovine knees, demonstrated accumulative and unrecoverable loosening of the root repair during a simulated postoperative rehabilitative protocol involving cyclical loading. This finding is particularly important when one considers that displacement of root repairs by ≥3 mm has been correlated with poor outcomes^{4,5}.

These studies suggest that avoiding weight-bearing, hamstring activation, and active range of motion restriction are the keystones during the first six weeks after surgery.

This six-week period is critical to the success of meniscal root repair and should be guided closely³⁻⁵. Thus, non-weight-bearing and bracing the knee in extension during this period is recommended to prevent the potential displacement of the repair, thereby maximizing the likelihood of meniscus healing^{4,5}.

Passive range of motion between 0°-90° in neutral rotation should be initiated as soon as possible to restore symmetry, with progression to full passive range of motion after two weeks^{3,4}. Isometric quadriceps strengthening and 0°-30° open kinetic chains are permitted. Active flexion must not be allowed to avoid hamstrings and popliteus activation that would harm the repair due to their meniscal attachments during the first six weeks.

In addition, following the initial postoperative restrictions, patellar and patellar tendon mobilization and core strengthening should be encouraged. After achieving a symmetric passive range of motion and no joint effusion, a two-week progression from partial to full weight-bearing and isometric hamstring training should be started.

Thereafter, endurance and strength training should be started¹. A slow and careful progression is the key to avoiding significant repair displacement. Endurance training embracing higher repetitions with low loads and short rest periods should be promoted during the eighth to sixteenth weeks. Cardiovascular exercise (stationary biking with resistance, swimming, and treadmill walking), with the avoidance of knee flexion angles of >90°, should also be incorporated starting at the twelfth week¹.

Activities progressing from double-legged closed kinetic chain exercises to dynamic single-leg activity should then be integrated while monitoring pain and knee effusion. Squatting deeper than 70° should be avoided as the repair is still maturing. Once single-legged exercises are mastered, exercises challenging stability should be integrated while maintaining the prescribed parameters¹.

Strength training should follow endurance training and should be associated with the expected time of partial meniscus healing^{1,4,5}. During this phase, a standard progression from monoplanar to multiplanar movements performed on even and unstable surfaces is advocated. Non-isometric hamstring exercises are allowed, but full squatting should be restricted until the 24th week¹.

An objective assessment of strength and balance symmetry must precede the incorporation of power, running, and return to sports in the 22nd week. Designing an individualized program for sports-specific exercises and drills is the goal for an appropriate readaptation. Training in proper jumping and landing biomechanics is necessary to avoid future injuries¹.

Testing for return to unrestricted activities should be tailored to the needs of the sport. Response to fatigue, fear of re-injury, and functional testing should be considered after a successful progression in the rehabilitation protocol¹.

Conclusions

A guided rehabilitation program during the first six postoperative weeks ensures better outcomes by protecting the repaired meniscus throughout this critical period. Advances in our understanding of meniscal healing during rehabilitation will give us novel evidence to improve the timeframe and results after this complex surgery. Studies focusing on outcomes after rehabilitation protocols and comparison studies will support the standardization of postoperative interventions following meniscal root repair.

References

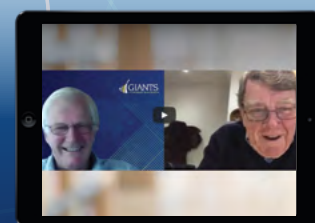1. Mueller BT, Moulton SG, O'Brien L, LaPrade RF. Rehabilitation Following Meniscal Root Repair: A Clinical Commentary. *J Orthop Sports Phys Ther.* 2016 Feb;46[2]:104-13.
2. Abraham AC, Villegas DF, Kaufman KR, Haut Donahue TL. Internal pressure of human meniscal root attachments during loading. *J Orthop Res.* 2013 October; 31[10]: 1507-1513.
3. Stärke C, Kopf S, Lippisch R, Lohmann CH, Becker R. Tensile forces on repaired medial meniscal root tears. *Arthroscopy.* 2013 Feb;29[2]:205-12.
4. Steineman BD, LaPrade RF, Haut Donahue TL. Loosening of Transtibial Pullout Meniscal Root Repairs due to Simulated Rehabilitation Is Unrecoverable: A Biomechanical Study. *Arthroscopy.* 2019 Apr;35[4]:1232-1239.
5. Chahla J. Meniscal Root Repairs: Let the Biology Help You! *Arthroscopy.* 2019 Apr;35[4]:1240-1242.



ISAKOS PODCAST

ISAKOS has two podcasts!

Joining the already popular *JISAKOS* Podcast, ISAKOS has launched the



ISAKOS Podcast. Each episode features a different topic, covering everything from interviews with the Giants in Orthopaedic Sports Medicine to highlights from the ISAKOS Newsletter.

**Available wherever you get
your podcasts!**

Total Knee Arthroplasty— Where have we been and where are we headed?



Myles Coolican, FRACS
*Orthopaedic Surgeon,
Knee Surgery
Sydney, AUSTRALIA*



Sebastien Lustig, MD, PhD, Prof
*Lyon North University Hospital,
Hamad General Hospital
Lyon, Rhône Alpes FRANCE*

Total knee replacement followed closely on the heels of hip replacement; the latter was developed over many years, beginning in earnest in the 1960s. Of the many pioneers of hip replacement, Sir John Charnley is given the most credit for the evolution of an idea to reality. Of the many problems Charnley sought to resolve, the greatest was the production of wear particles and the response to this foreign material, with subsequent osteolysis and loosening of the implants. Charnley recognized the deleterious effect of wear particles and indeed referred to his implant as a “low friction arthroplasty” as it was designed to reduce wear. Total knee replacement began a decade or so after hip replacement and had to overcome the same obstacles, and many others, on its journey to become the reliable procedure that it is today. This journey has been one of twists and turns and has included changes to implant design, composition, and fixation; changes to the nature of the bearings, the incision and exposure, and the tools to insert and balance the implants; and debate regarding the alignment strategy. What is clear is that not every new idea has resulted in better outcomes.

The knee implants were hinged devices (Figure 1), but better understanding of knee kinematics led to the development of the resurfacing implants that we still use today. In 1988, Ranawat and Boachie-Adjei published the first survivorship data for total condylar knee replacement¹. At 8–11 years, the survivorship rate was 94.1%, but revision for loosening and lysis remained a persistent problem that led to the development of various remedies, including alterations to the composition and design of implants as well as fixation.

One manufacturer added carbon fiber to polyethylene (Figure 2) to improve its strength and wear performance, while implant design was altered from the constrained total condylar model to a round-on-flat design best epitomized by the Miller-Galante implant. It was hypothesized (1) that constrained total condylar implants imparted torque forces to the bone-cement interface that promoted loosening and (2) that such forces would not occur with a round-on-flat design. The Miller-Galante implant included a vast range of tibial base plate sizes to increase coverage, and the implant was available as either cemented or porous. The porous femoral component was manufactured from titanium, which had been shown in the 1950s by our dental colleagues to have an enhanced capacity for bony ingrowth, particularly when fiber metal pads were compared to the sintered beads that were then available for porous chrome cobalt implants. Unfortunately, titanium proved to be a less-resilient bearing surface (Figure 3) that was associated with the production of metallic debris, and chrome cobalt again became the standard.



01 Hinged Knee
Replacement



02 Worn carbon fiber reinforced
polyethylene

Other adaptations to implants occurred over time, including the routine use of metal-based tibial implants rather than the all-polyethylene tibial components that were part of the first survivorship data, with a subsequent evolution from base plates that were rigidly fixed to polyethylene to modular implants. We also saw mobile bearings in various forms (Figure 4), including those that allowed rotation as well as coronal and sagittal motion. While posterior cruciate-sacrificing implants were more commonly used in the early days of knee arthroplasty, there has been a shift toward cruciate-retaining implants, which have been shown in registries to have slightly higher survivorship.

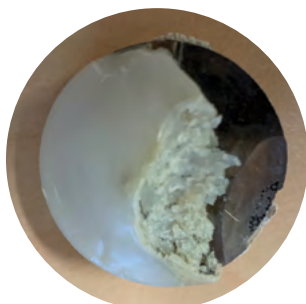

03 Titanium femoral component with marked scoring

More recently, medial pivot knees have been developed; these devices were designed to respect native knee kinematics and to emulate the native medial ball and socket, with rollback occurring more on the lateral side. And let's not forget the patella, where the success of metal tibial baseplates and porous implants led to the metal-backed patella (Figure 5), which could disassociate from its polyethylene with rapid femoral implant scoring and failure.



04 Mobile bearing tibial implant



05 Worn metal backed patella

The diminished survivorship of the round-on-flat implant led to a further change to something between the constrained Insall-Burstein total condylar knee design and the round-on-flat design, namely, an unconstrained conforming implant that was designed to reduce polyethylene fragmentation and delamination. Variations in the fixation method included cement, porous, and hybrid forms.

The early 2000s saw the introduction of "minimally invasive surgery," in which knees were replaced through an incision half the size of that typically used. A mobile window was created that could be translated proximally and distally, and it was thought that this procedure would result in more rapid recovery with improved range of motion.

Unfortunately, this procedure was associated with a higher incidence of malpositioning of the implant and infection. Although no longer routinely practiced, minimally invasive surgery did result in most surgeons performing knee arthroplasty with a shorter incision. This period also saw the introduction of various smart tools to improve surgical outcomes, in particular, pressure-sensitive devices to digitize ligament balance.

There has been a gradual evolution of the instrumentation utilized to accurately insert a knee replacement. For the past 40 years, surgeons have used what has become known as conventional instrumentation, with the plane and depth of the distal femoral cut being referenced off an intramedullary rod in the femur and with either a similar rod or an extramedullary alignment jig being utilized for the proximal tibial cut. This form of alignment has been shown to produce outliers ($>3^\circ$ outside the intended range) in $>30\%$ of patients and has led to the development of more accurate methods. Shape-matched cutting guides manufactured from images of the knee and lower limb were popularized as an alternative to conventional jigs, with varying reports on accuracy.

Computer-navigated total knee replacement was introduced in significant numbers in the early 2000s and has been shown to be more accurate than conventional instrumentation, with fewer outliers, and some studies have demonstrated a higher satisfaction rate and PROMS in association with navigated surgery as compared with conventional surgery. The Australian Orthopaedic Association National Joint Replacement Registry² has demonstrated a lower revision rate for navigated total knee replacements as compared to conventional implants in patients <65 years of age. Navigation carries the benefit of avoiding the shower of emboli associated with the placement of an intramedullary guide, but there is a risk, albeit small, of fracture of the femur through pin tracks. More recently, robots have been added to the operating room as a new tool that carries the benefits of computer navigation along with the ability to perform the surgery virtually. An implant can be accurately positioned to match the patient's anatomy, including the gaps between implants through range of motion, potentially recreating an identical articulation to the pre-disease state, with perfect ligament balance. Some systems use a preoperative planning image combined with intraoperative registered data and haptic control and perform the bony cuts within boundaries (thereby minimizing any damage to the soft tissues), whereas others only offer placement of cutting jigs.

The most recent challenge for the orthopaedic surgeon performing knee arthroplasty is the choice of alignment strategy. Mechanical alignment (MA) (initially popularized by Insall) or gap balancing (from the work of Hungerford and others) led to a straight mechanical axis that ensured approximately equal loads on the medial and lateral sides of the knee.

Total Knee Arthroplasty – Where have we been and where are we headed?

This avoided overloading one compartment, which was considered important at a time when the available polyethylene was less resistant to wear than the current polyethylene, which has been irradiated for cross-linkage, sterilized in an inert gas, and, in some cases, manufactured with the addition of the antioxidant Vitamin E.

Changes in alignment strategy have been proposed in order to decrease the dissatisfaction rate from between 9% and 20% to around 5% as seen in hip arthroplasty. Howell developed the concept of calipered kinematic alignment, in which the surgeon calculates bone and cartilage loss resulting from disease and accurately removes precisely enough bone and cartilage to equal the thickness of the implant. The bony cuts match the patient's anatomy in the sagittal, coronal, and axial planes, and calipers are used to measure the thickness of bone resection with adjustment for bone and cartilage loss and the thickness of the saw blade.

Kinematic alignment (KA) restores the knee to its pre-disease alignment, and, as such, there is no requirement for ligament balancing. KA does have a potential for patients to be significantly maligned after surgery and has led to the development of restricted KA, in which surgeons refrain from making bone cuts beyond a pre-determined range from the mechanical axis, often 3°.

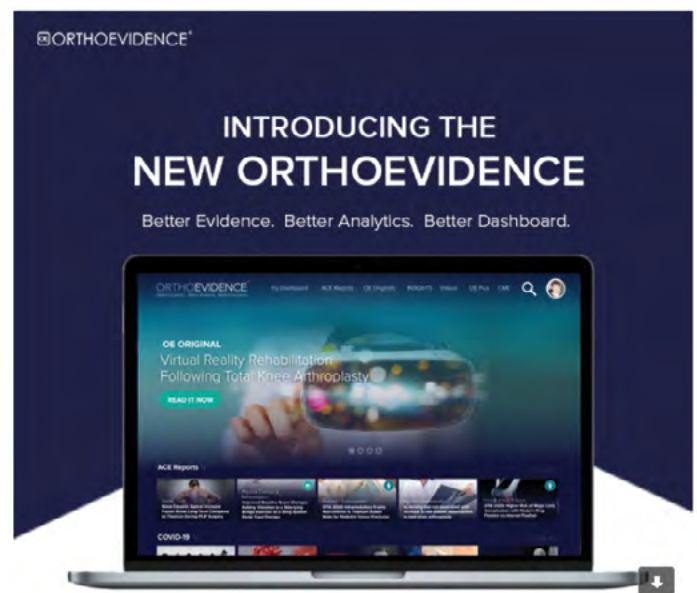
Other personalized approaches to alignment include the inverse kinematic approach, in which the tibia is resected with equal medial and lateral bone resections to maintain joint line obliquity, with the posterior condyles of the femur being cut parallel to the tibial cut with the knee in 90° of flexion, creating a rectangular parallelogram that is recreated in extension with the distal femoral cut. Functional alignment is an evolution of the KA philosophy, with the implant being positioned virtually with use of a robot in order to restore the native knee kinematics³.

What is clear from this short and limited history of knee arthroplasty is that not all of the changes that we surgeons and our engineering and implant-design colleagues have made have led to improvements in patient outcomes. Some skepticism is required, and, accordingly, it would be foolish to assume that, after over four decades of adherence to the concept of MA, the change to KA and its variations would necessarily be associated with improvement or that computer navigation and robotic surgery has all the answers.

All who are involved in TKA—particularly surgeons, engineers, and implant manufacturers—will continue to work to improve outcomes, with current efforts being centered on alignment strategies and the use of smart tools in the operating room. It is imperative that we remain vigilant and review and publish the outcomes of surgery, including both the short-term PROMS and long-term revision rates, before we can confidently state that what is new is an improvement.

References

1. Ranawat CS and Boachie-Adjei O. Survivorship Analysis and Results of Total Condylar Knee Arthroplasty. Clin Orth Rel Res 226 p6-13 1988.
2. Australian Orthopaedic Association National Joint Replacement Registry Annual Report 2018 p277.
3. Lustig S, Sappey-Mariner E, Fary C, Servien E and Parratte S. Personalised Alignment in Total Knee Arthroplasty: Current Concepts. SICOT-J 2021 7,19.



A New Look

Easily navigate our new dashboard and stay up to date on the latest high quality evidence with new content being added to the dashboard daily



Trending

See what evidence is trending on OrthoEvidence in real-time. The new dashboard allows you to stay up-to-date to with what others are reading



Interactive Dashboard

You can now customize your dashboard by filtering subspecialties, rearrange sections, save reports to read later, and much more!



Manage Email Subscriptions

Our new platform allows you to easily manage your email preferences so that you get the evidence you want, directly to your mailbox.

All-Inside Suture Meniscus Repair



Ryohei Uchida, MD, PhD
Kansai-Rosai Hospital
Hyogo, JAPAN



Shuji Horibe, MD, PhD
Osaka Prefecture University
Osaka, JAPAN



Konsei Shino, MD, PhD
Sports Orthopaedic Center,
Yukioka Hospital
Osaka, JAPAN

Introduction

The menisci are fibrocartilaginous, crescent-shaped wedges located in the femoral condyle and tibial plateau of the knee joint that enable load transmission, stability, and lubrication. Despite playing these important roles, the meniscus is relatively avascular in structure with an extremely limited blood supply and, thus, its healing potential is poor. Moreover, a post-meniscectomized knee will cause early degenerative changes and decreased knee function even in young athletes. This has recently led to the spreading of the concept of “save the meniscus” and meniscus-sparing techniques, including various meniscus-repair techniques. In this paper, we introduce one such meniscal repair technique: the all-inside suture (AIS) repair.

New Classification of Meniscal Repair Techniques

In the past, total or partial meniscectomy was an acceptable treatment, although subsequent degenerative changes after meniscectomy were reported. Since then, to preserve the function of meniscus, meniscal repair has developed from open to all-inside arthroscopic repairs. There are three basic arthroscopic procedures for meniscal repair: inside-out, outside-in, and all-inside techniques.

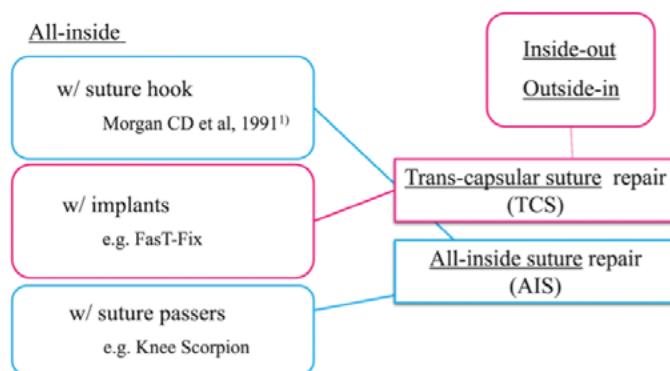
Many surgeons still consider the inside-out technique to be the gold standard of meniscal repair, even though this technique has a risk for neurovascular injury with accessory posterior incisions.

Tears of the posterior and middle thirds of the meniscus are suitable for the inside-out technique, whereas outside-in techniques are more suitable for repair of the anterior and middle thirds. All-inside techniques with implants were developed because they were easy to perform without additional incisions. Suture-based devices with an anchor, such as the T-Fix (Smith & Nephew, Andover, MA, USA) and rigid bioabsorbable implants, including the Meniscus Arrow (ConMed Linvatec, FL, USA), were then developed. However, a number of complications have been reported in association with the use of suture-based devices with anchors or rigid bioabsorbable implants.

Morgan et al.¹ introduced the first-generation all-inside technique with accessory posterior portals and only curved suture hooks without implants. This technique was used only for posterior root meniscus tears. More recently, new suture passers for all-inside techniques have been developed. Techniques involving these suture passers allow torn menisci to be repaired with only sutures and without the interposition of extra-articular soft tissues, including capsules, unlike inside-out / outside-in techniques and all-inside techniques performed with anchors or implants.

Apart from the conventional classification of meniscal repair techniques (“inside-out,” “outside-in,” or “all-inside”), these techniques with or without implants/anchors can be regarded as trans-capsular suture (TCS) repairs from the perspective of using sutures with penetrating capsules. Moreover, recent AIS techniques with suture passers and the first-generation all-inside technique with suture hooks described by Morgan et al. are considered to be all-inside suture (AIS) repairs as well (Fig. 1). AIS with only intra-meniscus suturing can directly close a gap between torn edges.

Figure 1. New classification of meniscal repairs



- 01 New classification of meniscal repair. The left column includes all-inside repair techniques with implants or suture passers, including the first-generation all-inside technique by Morgan². In the upper row of the right column, inside-out and outside-in techniques are shown. According to our new classification of meniscal repair, inside-out and outside-in repair and all-inside repair with implants or anchors are classified as trans-capsular suture (TCS) repair techniques (techniques within red squares). In contrast, recent all-inside repair techniques with suture passers and first-generation all-inside techniques with suture hooks, described by Morgan, are classified as all-inside suture (AIS) repairs with only suture (techniques within blue squares).

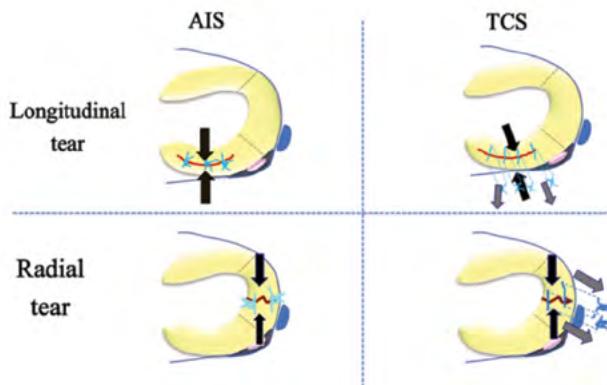
All-Inside Suture Meniscus Repair

AIS for Longitudinal Tear

There have been only a few reports about the biomechanical properties of AIS repairs of longitudinal tears, and thus the biomechanical superiority was not clear between AIS and TCS repairs.

Clinically, AIS was often adopted for repairs of longitudinal tears with concomitant ACL injuries, especially tears at the posterior horn. In past comparative studies, the clinical scores and healing based on MRIs after AIS repair were equivalent to those after inside-out repairs and all-inside repairs with implants. Regarding the healing status on second-look arthroscopy, satisfactory results were found after inside-out repairs of longitudinal tears². Therefore, for longitudinal tears, inside-out repairs can be sufficient. However, our yet unpublished data suggest that the AIS repair of lateral meniscus tears—most tears in the red-white zone—led to better healing (Fig. 2) and significantly smaller lateral meniscal extrusions than those after inside-out repairs. Moreover, a recent study also showed better healing after AIS as compared with all-inside repairs with implants³.

Figure 2. AIS vs TCS repairs

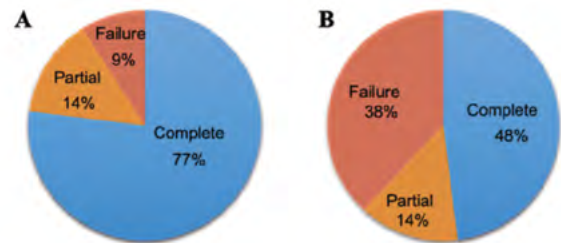


02 Effects of repair techniques on the repair site (shown for the lateral meniscus of right knee). Schematic diagrams depict the lateral meniscus of the right knee with a posterior-segment longitudinal tear (upper row) and a middle-segment radial tear (bottom row). In the left column, the effects of all-inside suture (AIS) repair are shown for longitudinal and radial tears. In the right column, the effects of inside-out repair (a representation of trans-capsular [TCS] repair) are shown for longitudinal and radial tears. After AIS, direct compressive force (black arrows) by intra-meniscus suturing without penetrating the capsule could maintain the stability of the repair site. In addition to compressive force, tensile force (gray arrows) to the periphery by suture while penetrating the capsule during TCS would lead to the loss of stability at the repair site, especially during knee motion.

After AIS repairs, the stability at repair sites can be sustained with use of intra-meniscus suturing. Furthermore, in inside-out repairs or all-inside repairs with implants, there is soft-tissue interposition between suture and meniscus, leading to stress to the repair site when the knee is in motion.

This could be an explanation for the better healing after AIS for longitudinal tears, as previously mentioned (Fig. 3). However, further research is needed to clarify the superiority of AIS.

Figure 3. Healing rates after repairs of longitudinal tears of the lateral meniscus



03 Healing rates after repairs of longitudinal tears of the lateral meniscus, including the rates of complete or partial healing and failure at second-look arthroscopy after all-inside suture repair (A) and inside-out repair (B). The number of patients is 22 after all-inside suture repair and 21 after inside-out repair.

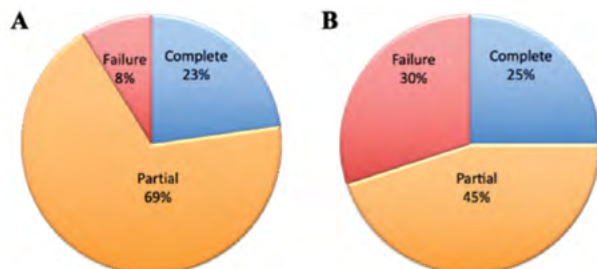
AIS for Radial Tears

For radial tears, AIS repairs have been clearly shown to be superior to TCS repairs in terms of failure load, stiffness, and gap after cyclic loading in porcine and cadaver models. With regard to failure mode, porcine models demonstrated that most menisci after AIS repairs showed suture failures, whereas most after TCS repairs showed tissue failure. Compared with the inside-out technique, the AIS technique provides better support of full-thickness meniscal microarchitecture. Additionally, the resulting reactive force of the AIS stitch is made directly opposite of the direction of displacement, whereas a TCS repair stitch is made oblique to it. In a comparison of double and single horizontal sutures using the AIS technique, failure load and stiffness after double horizontal AIS were more than double of those after single horizontal AIS. This finding suggests that AIS repairs with at least two sutures are better for radial tears.

Clinically, there is little evidence, with only one study focusing on AIS repair for radial tears⁴. That study revealed satisfactory clinical outcomes but poor healing on arthroscopy. In our unpublished data, the successful clinical score and poor healing rate after AIS repairs for radial tears of the lateral meniscus were equivalent to those after inside-out repairs. However, after AIS repairs for radial tears of the lateral meniscus, we found lower failure rates and smaller lateral meniscal extrusions compared with those after inside-out repairs (Fig. 3). Supposedly, AIS repairs only apply direct compressive force against the torn edges, whereas TCS repairs apply not only compressive force against the torn edges but also tensile force to the periphery by means of the sutures tied on the capsule (Fig. 4). For radial tears, stability at the repair site is more sustainable after AIS repair without soft-tissue interposition than that after TCS repair.

As such, AIS repair can be recommended for radial meniscus tears; this recommendation is supported by biomechanical studies and our clinical study. For radial tears, further research of AIS is also needed.

Figure 4. Healing rates after repair of radial tear of lateral meniscus



04 Healing rates after repairs of radial tears of the lateral meniscus, including the rates of complete or partial healing and failure at second-look arthroscopy after all-inside suture repair (A) and inside-out repair (B). The number of patients is 26 after all-inside suture repair and 20 after inside-out repair.

Characteristics of AIS

The AIS technique has remarkable advantages: (1) the stitching of AIS penetrates the meniscus vertically in full thickness, (2) the stitching can be tied perpendicular to the tear, and (3) the procedure can be performed without soft-tissue interposition between the sutures and the meniscus. These characteristics of AIS create a compressive force to close the gap at the tear site with minimal meniscal extrusion. Additionally, stability at the repair site can be sustained by means of intra-meniscus suturing without penetrating the capsule. As a result, AIS repair appears to be superior to TCS repair in terms of biomechanical properties and meniscus healing on arthroscopy.

AIS repair also has some limitations. First, there are some regions where it is difficult to apply AIS repair. Suture passers for AIS repair can be broadly classified into two types: the “hook type” and “needle type.” Hook types include suture hooks (ConMed Linvatec, FL, USA) and Micro SutureLasso (Arthrex, FL, USA), while needle types include Knee Scorpion (Arthrex, FL, USA), FIRSTPASS Mini (Smith & Nephew, Andover, MA, USA), and NovoStitch Pro (Smith & Nephew, Andover, MA, USA). In our opinion, the hook-type suture passer is recommended for the whole lateral meniscus, anterior segment and posterior horn of the medial meniscus. Conversely, needle-type suture passers are recommended for the posterior half of the lateral meniscus and the posterior horn of the medial meniscus. Second, the AIS technique has few opportunities to stimulate soft tissues with abundant vascularity surrounding the meniscus, whereas TCS repairs can provide a vascular access channel⁵. While AIS is disadvantageous in this regard, this disadvantage can be overcome with additional procedures, such as by using fibrin clot and/or bone-marrow stimulation by microfracture.

The hybrid repair—that is, the combination of AIS and TCS repairs—can also provide a vascular access channel, which potentially would promote meniscal healing. Third, there is potential for intra-articular knot impingement with AIS, given that knot impingement and a mirror lesion of erosive change in the acromion was found after rotator cuff repair. While there have been no reports on this complication after AIS meniscus repair, further careful observation on the impingement and mirror chondral lesion will be needed.

Conclusion

AIS repair can be considered an “anatomical suture repair” because torn edges can be repaired directly by means of intra-meniscus suturing without penetrating the capsule.

Therefore, we prefer AIS repair regardless of the type of meniscus tear. Further studies using newer / more sophisticated devices and surgical techniques are required.

References

1. Morgan CD, Wojtys EM, Casscells CD, Casscells SW. Arthroscopic meniscal repair evaluated by second-look arthroscopy. *Am J Sports Med.* 1991;19(6): 632–7.
2. Horibe S, Shino K, Maeda A, Nakamura N, Matsumoto N, Ochi T. Results of isolated meniscal repair evaluated by second-look arthroscopy. *Arthroscopy.* 1996;12(2):150–5.
3. Seo SS, Kim CW, Lee CR, Park DH, Kwon YU, Kim OG, Kim CK. Second-look arthroscopic findings and clinical outcomes of meniscal repair with concomitant anterior cruciate ligament reconstruction: comparison of suture and meniscus fixation device. *Arch Orthop Trauma Surg.* 2020;140(3):365–72.
4. Choi NH, Kim TH, Son KM, Victoroff BN. Meniscal repair for radial tears of the midbody of the lateral meniscus. *Am J Sports Med.* 2010;38(12):2472–6.
5. Heatley FW. The meniscus: can it be repaired? An experimental investigation in rabbits. *J Bone Joint Surg Br.* 1980;62(3):397–402.

Advocacy for the “European Touch” of Ankle Arthroscopy



Stéphane Guillo, MD
SOS Pied Cheville Center
Bordeaux, FRANCE



Mai Katakura, MD, PhD
Assistant Professor, Department
of Joint Surgery and Sports Medicine
Tokyo Medical and Dental University
Tokyo, JAPAN



Haruki Odagiri, MD, PhD
Kumamoto Foot and Ankle Center,
Hotakubo Orthopedic Hospital
5-7-27, Hotakubo, Higashi-ku
Kumamoto, JAPAN



Christel Charpail, MD
SOS Pied Cheville Center
Bordeaux, FRANCE

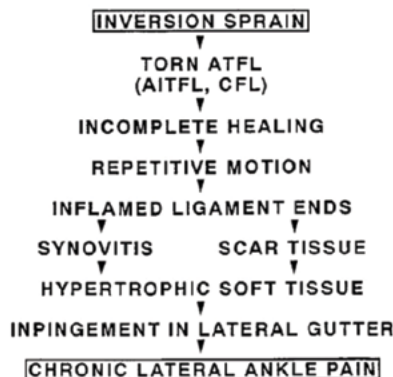Four mm Arthroscope, No Traction is the Best Way to Assess the Lateral Gutter of the Ankle via Standard Arthroscopic Ankle Portal

Over the last 70 years, ankle arthroscopy has been fundamentally performed into two different ways. We generally distinguish between the American approach (performed with a 2-mm arthroscope, traction, and the ankle in plantar flexion) and the European approach, developed by Niek Van Dijk (performed without traction and with a 4-mm arthroscope). It is therefore very interesting to focus on what has been published about anterolateral impingement (ALI).

In the last several decades, one of the main indications for ankle arthroscopy has been the treatment of anterolateral impingement. It is very important to come back to this concept in the light of our current knowledge in order to draw conclusions about how to perform arthroscopy.

This article provides an overview of the review by Mai Katakura, Haruki Odagiri, and Christel Charpail, which was recently published in the official journal of the French Society for Orthopaedic Surgery and Traumatology (SOFOT)¹.

The concept of anterolateral impingement was born 70 years ago and matured in the 1990s with a detailed explanation of its presumed pathogenesis by Ferkel et al.². In 1991, Ferkel et al. labelled the persistent lateral ankle pain after



01 Sequence of lateral ankle pain (Ferkel, 1991).

an inversion injury as “anterolateral impingement”. The illustration provided in that article (Figure 1) postulated the Anterior Talo-Fibular Ligament (ATFL) injury, caused by an inversion of the ankle, as the main cause for symptoms.

Abnormal motion following ATFL injury, even if not severe enough to cause mechanical instability, may lead to inflammation and the formation of scar tissue, resulting in soft-tissue impingement and lateral ankle pain. It is also widely accepted that synovial hypertrophy around the ATFL and impingement of the distal fascicle of the anterior inferior tibiofibular ligament (AITFL) may cause ALI. In the review by Katakura et al.¹, very little information was provided about residual instability or recurrent ankle sprains. One of the eight studies included in that review evaluated the frequency of ATFL injuries observed during surgery, and three studies evaluated the pathology of the distal fascicle of the AITFL, which also has been deemed to cause ALI by impinging on the talus.

The review mentioned above¹ indicates that, in the literature, there is an over-representation and probably an over-description of everything that is visible in the upper and lateral part of the joint space. On the other hand, there is very little information in the literature on what is located in the external gutter and in the first place the ATFL, which was however described by Ferkel as being the cause of the problem. Besides, there is paucity of articles that clearly show the lateral gutter and the ATFL. Published images of ankle arthroscopy often show only the upper and lateral corner. We believe that this is a consequence of the technique generally chosen for performing arthroscopy. If it is performed with use of traction, the arthroscopic view can

only show the joint space. It is therefore very difficult, if not impossible, to examine the lateral gutter through a standard arthroscopic portal when traction is performed.

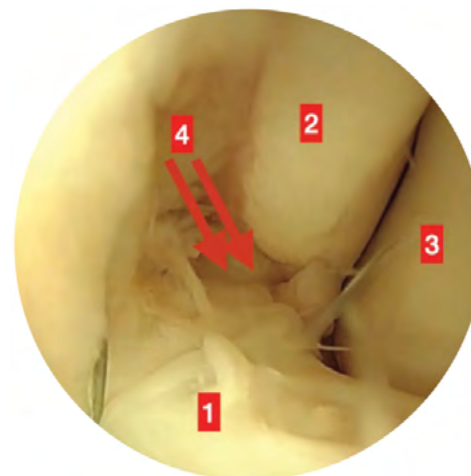
This is surprising if one considers the fact that it was Ferkel et al. who described the importance of ATFL involvement in ALI, and yet that group advocated the distraction arthroscopic technique. In support of the theory of Ferkel, one study in our review reported that 20 (83.3%) of 24 patients presented with an abnormal ATFL. Other studies that were not included in that review have also reported injury of the ATFL. For a better understanding, it might be relevant to describe and classify the ATFL lesions observed under arthroscopy.

The high prevalence of ATFL injury in patients with ALI³ may be explained by poor ligament healing with subsequent synovitis and intraarticular fibrosis. The presence of synovial fluid surrounding the superior fascicle of the ATFL may lead to a reduced healing potential as is seen with the anterior cruciate ligament.

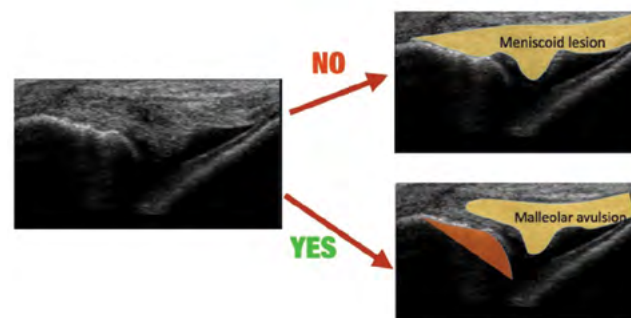
The anatomic work done by Dalmau-Pastor et al. is in favor of the limited healing potential of the ATFL from its intra-articular position, that can explain the abnormal movement of a subtly unstable ankle joint from inadequate healing of the ligament. This abnormal movement has been described as micro-instability, a concept previously observed in the shoulder. It has been postulated that a similar pathological process results from ATFL injury and ankle micro-instability, causing symptoms of ALI.

In conclusion, the level of evidence and recommendation grade for resection of hypertrophic tissue in the treatment of ALI is poor. Studies on ATFL tears and their consequences, especially instability and recurrent ankle sprain, are also lacking. Returning to the Ferkel's concept, our review suggests that the role and degree of instability require further investigation. Surgical treatment of ALI requires accurate ATFL assessment and abnormalities⁴.

Since the 1980s, the North American school of ankle arthroscopy has advocated the use of a small arthroscope, with ankle in plantar flexion and distracted (Andrews, 1985). This technique is widely used in English-speaking countries. However, this surgical technique allows a partial view of the ATFL because the lateral gutter is collapsed. On the other hand, the European school of ankle arthroscopy recommends the use of a large arthroscope, dorsiflexion, and no distraction of the joint, as described by Niek van Dijk in 1997⁵. In this situation, the lateral gutter is relaxed and the ATFL can be fully assessed (Figure 2). To conclude, this technique changes completely the approach and the way to deal with anterolateral impingement (Figure 3).



02 The vision of the lateral gutter to assess the ATFL: (1) ATFL, (2) malleolus, (3) lateral side of the talus, (4) ATFL avulsion.



03 Sonography assessment of the ATFL. The "meniscoid lesion" is in fact a torn ligament.

References

1. Katakura M, Odagiri H, Charpail C, Calder J, Guillo S. Arthroscopic treatment for anterolateral impingement of the ankle: Systematic review and exploration of evidence about role of ankle instability. OTSR. 2021;in press.
2. Ferkel RD, Karzel RP, Del Pizzo W, Friedman MJ, Fischer SP. Arthroscopic treatment of anterolateral impingement of the ankle. *Am J Sports Med.* 1991;19(5):440-6. Epub 1991/09/01. doi: 10.1177/036354659101900504. PubMed PMID: 1962707.
3. Guillo S, Bauer T, Lee JW, Takao M, Kong SW, Stone JW, et al. Consensus in chronic ankle instability: aetiology, assessment, surgical indications and place for arthroscopy. *Orthop Traumatol Surg Res.* 2013;99(8 Suppl):S411-9. Epub 2013/11/26. doi: 10.1016/j.otsr.2013.10.009. PubMed PMID: 24268842.
4. Guillo S, Odagiri H. All-Inside Endoscopic Brostrom-Gould Technique. *Arthrosc Tech.* 2020;9(1):e79-e84. Epub 2020/02/06. doi: 10.1016/j.eats.2019.09.003. PubMed PMID: 32021778; PubMed Central PMCID: PMC6993130.
5. van Dijk CN, Scholte D. Arthroscopy of the ankle joint. *Arthroscopy.* 1997;13(1):90-6. Epub 1997/02/01. doi: 10.1016/s0749-8063(97)90215-2. PubMed PMID: 9043610.

Disclosure of interest:

The authors declare that they have no competing interest.
Funding: None

only show the joint space. It is therefore very difficult, if not impossible, to examine the lateral gutter through a standard arthroscopic portal when traction is performed.

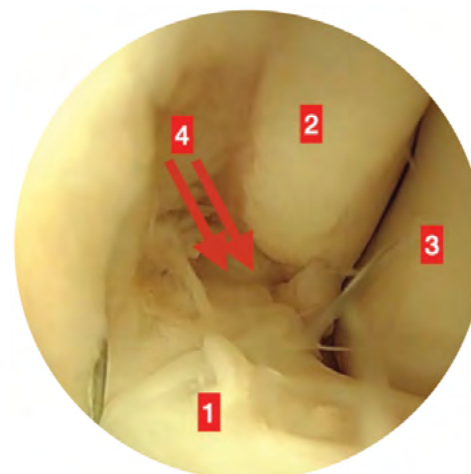
This is surprising if one considers the fact that it was Ferkel et al. who described the importance of ATFL involvement in ALI, and yet that group advocated the distraction arthroscopic technique. In support of the theory of Ferkel, one study in our review reported that 20 (83.3%) of 24 patients presented with an abnormal ATFL. Other studies that were not included in that review have also reported injury of the ATFL. For a better understanding, it might be relevant to describe and classify the ATFL lesions observed under arthroscopy.

The high prevalence of ATFL injury in patients with ALI³ may be explained by poor ligament healing with subsequent synovitis and intraarticular fibrosis. The presence of synovial fluid surrounding the superior fascicle of the ATFL may lead to a reduced healing potential as is seen with the anterior cruciate ligament.

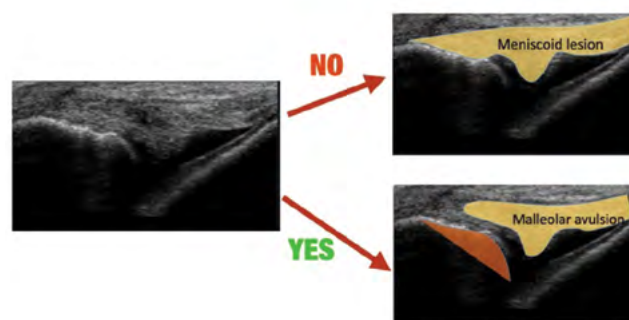
The anatomic work done by Dalmau-Pastor et al. is in favor of the limited healing potential of the ATFL from its intra-articular position, that can explain the abnormal movement of a subtly unstable ankle joint from inadequate healing of the ligament. This abnormal movement has been described as micro-instability, a concept previously observed in the shoulder. It has been postulated that a similar pathological process results from ATFL injury and ankle micro-instability, causing symptoms of ALI.

In conclusion, the level of evidence and recommendation grade for resection of hypertrophic tissue in the treatment of ALI is poor. Studies on ATFL tears and their consequences, especially instability and recurrent ankle sprain, are also lacking. Returning to the Ferkel's concept, our review suggests that the role and degree of instability require further investigation. Surgical treatment of ALI requires accurate ATFL assessment and abnormalities⁴.

Since the 1980s, the North American school of ankle arthroscopy has advocated the use of a small arthroscope, with ankle in plantar flexion and distracted (Andrews, 1985). This technique is widely used in English-speaking countries. However, this surgical technique allows a partial view of the ATFL because the lateral gutter is collapsed. On the other hand, the European school of ankle arthroscopy recommends the use of a large arthroscope, dorsiflexion, and no distraction of the joint, as described by Niek van Dijk in 1997⁵. In this situation, the lateral gutter is relaxed and the ATFL can be fully assessed (Figure 2). To conclude, this technique changes completely the approach and the way to deal with anterolateral impingement (Figure 3).



02 The vision of the lateral gutter to assess the ATFL: (1) ATFL, (2) malleolus, (3) lateral side of the talus, (4) ATFL avulsion.



03 Sonography assessment of the ATFL. The "meniscoid lesion" is in fact a torn ligament.

References

1. Katakura M, Odagiri H, Charpail C, Calder J, Guillo S. Arthroscopic treatment for anterolateral impingement of the ankle: Systematic review and exploration of evidence about role of ankle instability. OTSR. 2021;in press.
2. Ferkel RD, Karzel RP, Del Pizzo W, Friedman MJ, Fischer SP. Arthroscopic treatment of anterolateral impingement of the ankle. *Am J Sports Med.* 1991;19(5):440-6. Epub 1991/09/01. doi: 10.1177/036354659101900504. PubMed PMID: 1962707.
3. Guillo S, Bauer T, Lee JW, Takao M, Kong SW, Stone JW, et al. Consensus in chronic ankle instability: aetiology, assessment, surgical indications and place for arthroscopy. *Orthop Traumatol Surg Res.* 2013;99(8 Suppl):S411-9. Epub 2013/11/26. doi: 10.1016/j.otsr.2013.10.009. PubMed PMID: 24268842.
4. Guillo S, Odagiri H. All-Inside Endoscopic Brostrom-Gould Technique. *Arthrosc Tech.* 2020;9(1):e79-e84. Epub 2020/02/06. doi: 10.1016/j.eats.2019.09.003. PubMed PMID: 32021778; PubMed Central PMCID: PMC6993130.
5. van Dijk CN, Scholte D. Arthroscopy of the ankle joint. *Arthroscopy.* 1997;13(1):90-6. Epub 1997/02/01. doi: 10.1016/s0749-8063(97)90215-2. PubMed PMID: 9043610.

Disclosure of interest:

The authors declare that they have no competing interest.
Funding: None











ISAKOS

PUBLICATIONS












Free Access for ISAKOS Members

isakos.com/myISAKOS/myPublications



12 NEW BOOKS Available

A \$1500+ value, free for members!



isakos.com/books

12


New Books AVAILABLE



Advances in Knee Ligament and Knee Preservation Surgery

Norimasa Nakamura, Robert G. Marx, Volker Musahl, Alan Getgood, Seth L. Sherman, Peter Verdonk


Presents an overview of the latest advances in knee ligament and knee preservation surgery. Covers all aspects of soft tissue/sports medicine knee surgery. Offers a wide variety of international perspectives on managing complex knee problems.



Arthroscopy and Endoscopy of the Elbow, Wrist and Hand

Deepak N. Bhatia, Gregory I. Bain, Gary G. Poehling, Benjamin R. Graves


Presents basic and advanced arthroscopic and endoscopic surgical techniques of the elbow, wrist, and hand. Includes extensive cadaveric dissections to explain surgical anatomy. Features high-quality color illustrations and videos to simplify and complement the description of surgical techniques.



Cartilage Injury of the Knee

Aaron J. Krych, Leela C. Biant, Andreas H. Gomoll, João Espregueira-Mendes, Alberto Gobbi, Norimasa Nakamura

Discusses cartilage injury of the knee, focusing on reducing pain and improving dysfunction to allow return to activity. Covers cutting-edge cartilage repair techniques as well as the basic principles of addressing background factors of instability, meniscus pathology, and malalignment. Includes a case-based approach with clinical vignettes for the expert authors' preferred method of management.



Early Osteoarthritis: State-of-the-Art Approaches to Diagnosis, Treatment and Controversies

Christian Lattermann, Henning Madry, Norimasa Nakamura, Elizaveta Kon

Focuses on the early post-traumatic changes leading to the onset of osteoarthritis. Covers the basic premise of the early osteoarthritic process on a tissue and organ level. Discusses the scientific basis for the treatment of early osteoarthritis both non-operatively and operatively.



Infection in Knee Replacement

Umile Giuseppe Longo, Nicolaas C. Budhiparama, Sébastien Lustig, Roland Becker, João Espregueira-Mendes

Provides a detailed overview of prevention, diagnosis and treatment of infection following total knee arthroplasty. Presents up-to-date information on available techniques and salvage procedures for complex patients. Offers in-depth guidance on preoperative optimization and prevention.



Joint Function Preservation: A Focus on the Osteochondral Unit

Alberto Gobbi, John G. Lane, Umile Giuseppe Longo, Ignacio Dallo

Reviews the anatomy, biomechanics and function of joints. Provides an in-depth overview of strategies for both common and complex joint preservation. Discusses the effects of joint malalignment and joint failure knee problems.

The Habibie Prize



Nicolaas Cyrillus Budhiparama, MD, PhD, FICS, Assoc. Prof.
Nicolaas Institute of Constructive Orthopaedic Research & Education Foundation
 INDONESIA

The Habibie Prize is given to individuals who have contributed greatly to the discovery, development, and dissemination of various scientific and technological advances that have had significant benefits for improving welfare, justice, and peace in Indonesia. In Indonesia, this prize is as prestigious as the Nobel Prize. Since its inception in 1999, The Habibie Prize (previously called The Habibie Award) has been given to 71 scholars as a token of appreciation for their extraordinary intellectual contributions to the nation.

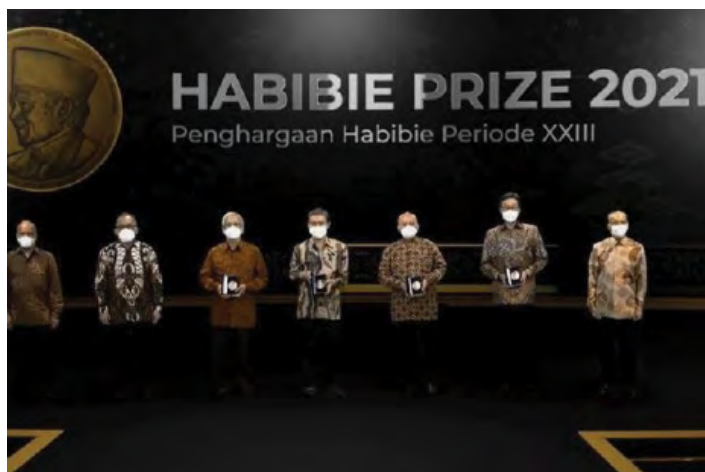The head of the National Research and Innovation Agency (BRIN), Laksana Tri Handoko, has said that the development of superior human resources will greatly support Indonesia's progress and will become one of the main keys to increasing competitiveness in the global arena. "The progress of a nation is not enough only with the availability of abundant natural resources and massive infrastructure development but must also be supported by improving the quality of human resources; Indonesian human resources who are able to innovate to build the nation," he explained in a quotation on the BRIN website. Handoko further explained that Bacharuddin Jusuf Habibie, for whom the award is named, exemplified the ability of the Indonesian people to innovate and utilize science and technology to advance the progress and sovereignty of the nation. Habibie, in addition to being the third President of Indonesia, was a genius in aeronautics research in Germany and was a pioneer in the aeronautics industry and technology in Indonesia.

Laksana Tri Handoko stated that, for the 2021 Habibie prize, there were five categories of science and technology and innovation: (1) basic science, (2) medicine and biotechnology, (3) engineering science, (4) economics, social, political, and legal sciences, and (5) philosophy, religion, and culture. That year, there were a total of 90 candidates from the five categories, which were then selected and assessed by a jury which is then determined in a plenary meeting chaired by the Chairperson of the 2021 Habibie Prize Committee/Jury.

Nicolaas C. Budhiparama, MD, PhD, received the award in the category of Medicine and Biotechnology for introducing surgical techniques and technologies in Indonesia. He also raised the prestige of Indonesian surgeons in the eyes of the global orthopaedic community when he was elected as the concurrent President of three Asia-Pacific arthroplasty societies, namely, the Asia Pacific Knee Society (APKS), the Arthroplasty Society in Asia (ASIA), and the Asia Pacific Arthroplasty Society (APAS). Nicolaas Budhiparama is one of the Founding Godfathers of the ISAKOS Global Connection Campaign. He is very enthusiastic about improving education, and, through his foundation (the Nicolaas Institute of Constructive Orthopaedic Research and Education Foundation), has personally donated to initiate the Paolo Aglietti Award and Knee Arthroplasty Travelling Fellowship at ISAKOS.

As an orthopedic surgeon and attached to Universitas Airlangga, Universitas Gadjah Mada, and Leiden University Medical Center, Nicolaas has had a significant impact on academic medicine through his contributions in faculty affairs and cross-lecture collaborations. His vision is for Indonesian surgeons to be recognized on a global level.

Nicolaas completed his orthopaedic residency at Leiden University Medical Center (The Netherlands) in 1992. After completing several fellowships in the U.S. and Europe, he started his clinical practice in Indonesia. Throughout the years, Nicolaas has actively lectured at scientific meetings, seminars, and workshops across the globe. His involvement in many different orthopaedic associations throughout the world has allowed him to become the bridge for young surgeons in the Asia-Pacific region to gain international connections and broaden their horizons. In his home country, he is also involved with many different national and world-class athletes in preparation for world championships. He currently serves as the official chief of medical team for Indonesian Badminton Federation.

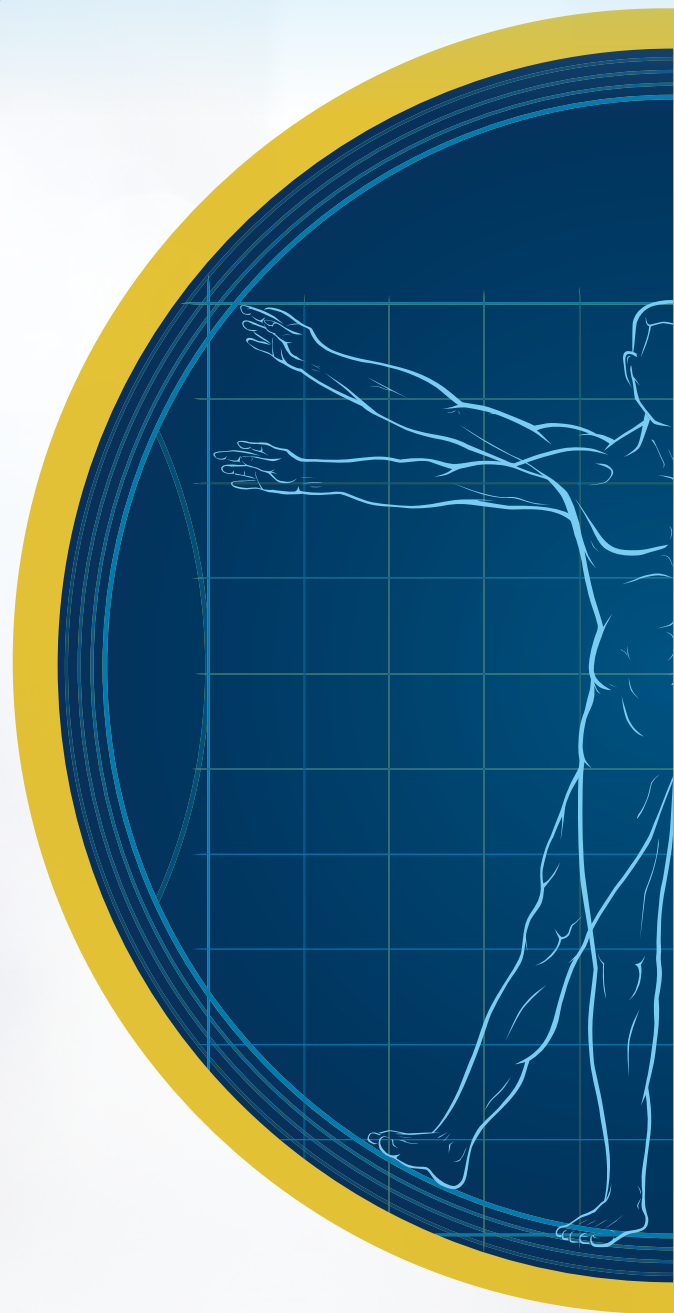
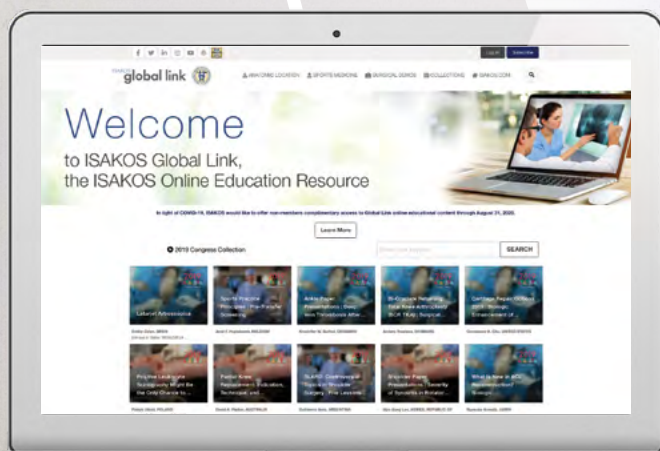


2021 CONGRESS
content is included
for registrants
and available for
non-attendees
for purchase

ISAKOS global link

Access 3,000+ Congress
presentations, surgical
demonstrations & courses,
webinars, current concept
articles, archive videos,
committee projects, industry
sponsored content...
and more!

isakos.com/GlobalLink





ISAKOS
CONGRESS
2023



Boston
Massachusetts
June 18–June 21



SAVE THE DATE

CALL FOR ABSTRACTS

OPEN MARCH 1

#ISAKOS2023
isakos.com/2023congress

Achilles Orthopaedic Sports Medicine Research Award Winner



Harukazu Tohyama, MD, PhD
Department of Rehabilitation Science,
Faculty of Health Sciences
Hokkaido University
Sapporo, JAPAN

The Achilles Orthopaedic Sports Medicine Research Award was created to recognize the researcher(s) who have performed the most outstanding clinical or laboratory research in the field of sports medicine

Identification of Predictive Risk Factors for the Development of a Stress Fracture within 6 Months in Female Elite Long-distance Runners

I was extremely flattered and honored to receive the Achilles Orthopaedic Sports Medicine Research Award at the *ISAKOS 2021: Global Congress*. The paper was entitled "Identification of Predictive Risk Factors for the Development of a Stress Fracture within 6 Months in Female Elite Long-distance Runners." The purpose of this study was to identify which factors predict the risk of stress fractures within 6 months in female elite long-distance runners.

During this study, I measured bone mineral densities of whole body and lumbar spine and body composition with use of DXA in elite female long-distance runners who belonged to a women's track team. I followed participants prospectively for 6-month periods. Using stepwise multivariate logistic regression with the ROC curve analysis, I examined the ability of bone mass and body composition parameters alone or in combination to predict the occurrence of a stress fracture within 6 months. The research revealed that bone mineral density of the lumbar spine alone was the strongest predictive factor. The ROC curve analysis demonstrated that bone mineral density (BMD) of the lumbar spine of <81.1% of the YAM (young adult mean) predicted a stress fracture within 6 months in female elite long-distance runners, with 88% sensitivity and 74% specificity. The findings suggest that female elite long-distance runners with a lumbar spine BMD of <81.1% of the YAM are at increased risk of stress fractures within 6 months and should reduce their high-impact sports activities as a preventive measure.

This award was earned thanks to the contributions of my team members. I am grateful to Tomoya Ishida, PhD, RPT, and Saori Iwata, MS, RPT, for their assistance with data-input and statistical analysis of the present research. I would like to thank Makoto Oda, BS, for her assistance with DXA measurement. Additionally, I appreciate their useful advice of Mina Samukawa, PhD, RPT, and Nodoka Ikegami, MS, RPT. Finally, I would like to extend thanks to members of ISAKOS Sports Medicine Committee and DJO Inc. for their continuous support to the Achilles Orthopaedic Sports Medicine Research Award. I hope I can continue to contribute to the field of sports medicine by research works for the care and prevention of sport injuries.

Gary G. Poehling Award



Margaret Fok, FRCSEd(Ortho),
MBChB
*Queen Mary Hospital,
The University of Hong Kong,
Hong Kong, CHINA*

TFCC Tears Should Only Be Repaired in Symptomatic Patients with Distal Radius Fractures

We are honored to have received the Gary G. Poehling Award for the article entitled “TFCC Tears Should Only Be Repaired in Symptomatic Patients with Distal Radius Fractures.”

Due to the pandemic, this was an unusual year in which we were unable to meet face to face, present our findings, and discuss our article in detail at the ISAKOS Congress. Nevertheless, we are grateful that the Hand, Wrist, and Elbow committee has found this article interesting and worthy.

Triangular fibrocartilage complex (TFCC) tears resulting in ulnar wrist pain and distal radioulnar joint (DRUJ) instabilities have gained awareness in the past decade. Different techniques of repair and reconstruction have been described to manage symptomatic patients.

Yet there remains a debate on whether TFCC tears will behave similarly (i.e., cause similar symptoms and signs) in patients with distal radial fractures. While some wrist surgeons advocate concomitant repair of TFCC during the fixation of distal radial fractures, some believe that the TFCC can be left unrepaired without causing much functional deficit.

We performed a prospective study to evaluate whether TFCC tears will heal without repair after the fixation of distal radial fractures. In addition, we appraised whether these patients will be symptomatic in the presence of TFCC tears. Our findings confirmed that there was a high incidence of TFCC tears in patients with distal radial fractures, as shown in the current literature. A significant percentage of TFCC tears did not heal after anatomical reduction and fixation of distal radial fractures. Yet not all TFCC tears caused symptoms. Our findings suggested that it is acceptable to perform a delayed repair in symptomatic patients with good functional outcomes.

We postulated that a specific group of distal radial fractures associated with TFCC tears may remain symptomatic after the fracture union. Yet until we can identify this group, it may not be beneficial to perform concomitant TFCC repair in all distal radius fractures, which may in turn lead to unnecessary prolonged immobilization and wrist stiffness.

Jan I. Gillquist Scientific Research Award



R. Kyle Martin, MD, FRCSC
*University of Minnesota
Minnesota, UNITED STATES*

It was an honor for our research team to receive the Jan I. Gillquist Scientific Research Award at the recent ISAKOS Global Congress. Our study was entitled “Predicting Subjective Failure of ACL Reconstruction: A Machine Learning Analysis of the Norwegian Knee Ligament Register and Patient Reported Outcomes.” This project was funded by a Norwegian Centennial Chair seed grant and represents a transatlantic collaboration between colleagues from Norway and Minnesota, USA.

The purpose of our study was to apply machine learning analysis to the Norwegian Knee Ligament Register (NKLr) in order to predict which patients would experience a subjective failure of anterior cruciate ligament (ACL) reconstruction postoperatively. The ultimate goal was to translate the analysis into a tool that can be used for future patients in the clinical setting to estimate their specific risk of subjective failure. Over 11,000 patients were included in the analysis, and the resulting model was well calibrated while demonstrating moderate discrimination with an area under the curve of 0.67-0.68. The algorithm was then used to create an online clinical calculator (https://swastvedt.shinyapps.io/calculator_koosqol/).

So much of what we have learned about ACL reconstruction has come from the knee ligament registers over the past two decades. This knowledge, coupled with the tremendous work of other researchers, has led to the identification of multiple risk factors contributing to a poor surgical outcome. Translating all of those risk factors into a quantifiable risk score for the patient seated in the office can be challenging, however, owing to the complex nature of the various factors that may be present in a given individual. Machine learning represents a novel approach to health-related research that may help to provide some measure of clarity. These advanced statistical techniques allow complex interactions between variables to be assessed and can produce highly accurate predictive models. Much has been publicized regarding the application of machine learning to various medical fields, but very few models have been developed for orthopaedic sports medicine to date.

On behalf of all of my co-authors, I want to sincerely thank ISAKOS and the Scientific Committee for supporting our study and for embracing the machine learning approach to orthopaedic research. We hope that future researchers will be able to improve on these early clinical models with the collection of more and better data. A key component to that will be the fostering of international collaborations and idea-sharing—a foundational component of all ISAKOS initiatives and events. See you in Boston!

John Joyce Award



Armin Runer
University Hospital for Orthopaedics and
Traumatology
Innsbruck, AUSTRIA



Philipp W. Winkler
Department for Orthopaedic
Sports Medicine
Technical University of Munich
Munich, GERMANY

I was recently honored to receive the John J. Joyce award for the best arthroscopic paper read at the 13th ISAKOS Global Congress, entitled “Quadriceps Tendon Autograft for Primary Anterior Cruciate Ligament Reconstruction Shows Comparable Clinical, Functional, and Patient-Reported Outcome Measurements, but Lower Donor-Site Morbidity, Compared with Hamstring Tendon Autograft: A Matched-Pairs Study with a Mean Follow-Up.”

The primary aim of the study was to compare the clinical and functional outcomes following primary, isolated anterior cruciate ligament reconstruction (ACLR) using either quadriceps tendon (QT) or hamstring tendon (HT) autograft after a minimum duration of follow-up of 5 years. After matching a total of 90 patients with an average follow-up of 6.5 years, we found that patient-reported outcome measures, knee laxity, functional testing results, and re-rupture rates were similar between patients treated with QT and HT autografts. However, patients with QT autograft had significant smaller tibial skin incisions and lower postoperative donor-site morbidity.

Great scientific work needs a great team. Therefore, I would like to thank all of my co-authors, namely, Dr. Aline Suter, Dr. Tommaso Roberti di Sarsina, Dr. Caroline Hepperger, Dr. Peter Gföller, Dr. Christian Hoser, and Dr. Robert Csapo, for their help with this study. A special thanks goes to Dr. Christian Fink for his continuous guidance and support throughout my medical and scientific career.

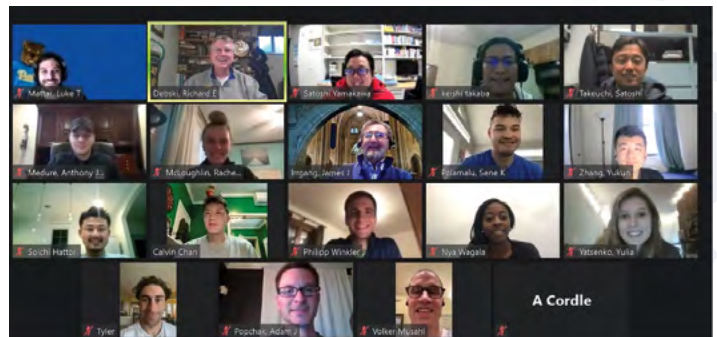
Finally, I am grateful to ISAKOS and the ISAKOS Program Committee for selecting our work for this honorable award and I am looking forward to seeing everyone in person in Boston 2023.

Association Between Meniscal Allograft Tears and Early Surgical Meniscal Allograft Failure

At the award ceremony of the 13th Biennial ISAKOS Congress, I was rewarded for my research efforts during my Knee Research Fellowship at the University of Pittsburgh, supervised by Dr. Volker Musahl. Although my research year was shadowed by COVID-19, I was able to meet icons of orthopaedic sports medicine, make mentors and friends for a lifetime, and discover the fascination of biomechanical and clinical research. I would like to thank all friends involved, especially Dr. Volker Musahl, Dr. Richard E. Debski, and Dr. Freddie H. Fu, without whom the two awards would not have been possible (Figure 1).

The clinical study entitled “Association Between Meniscal Allograft Tears and Early Surgical Meniscal Allograft Failure” was acknowledged with the second place of the John Joyce Award. Meniscal allograft transplantation (MAT) has become an important and viable treatment option for patients with symptomatic meniscus deficiency. Although many studies have shown improvement in terms of symptoms and athletic performance after MAT, the rates of reoperation and meniscal allograft failure remain considerable. Given that MAT has been an integral part of reconstructive knee surgery at the University of Pittsburgh for decades, it was possible to evaluate the causes of failure in >200 patients undergoing MAT. Our investigations found that almost one-third of patients develop meniscal allograft tears over time. In the awarded study, the types and distribution of meniscal allograft tears and the associated impact on meniscal allograft survival were investigated. The most important finding was that meniscal allograft tears may cause early meniscal allograft failure.

On behalf of the UPMC Freddie Fu Sports Medicine Center and the Orthopaedic Robotics Laboratory at the University of Pittsburgh, I gratefully accept the two awards and would like to sincerely thank ISAKOS for this opportunity.



01 The dedicated team of the Orthopaedic Robotics Laboratory of the University of Pittsburgh in 2020.

Global Traveling Fellowship Recipients



Oyoo O. Were, MBChB, MMed,
IOC Dip. Sport Phy.
*Defence Forces Memorial Hospital
Nairobi, KENYA*

I currently practice as an orthopaedic surgeon in Nairobi and work with various Kenyan sports teams, most recently as the Chief Physician of the Kenyan team to the Tokyo Paralympic Games that were originally scheduled for August–September 2021. During my preparations for the games, which were delayed due to the COVID-19 pandemic, I received word that I had been awarded the ISAKOS Global Traveling Fellowship, an exciting opportunity. However, the 2021 in-person event was canceled due to the pandemic and the travel was delayed to June 2023. However, the cancellation has not dampened my excitement but rather spurs me on, because I know that I will continue to learn between now and June 2023. I believe that the lessons learned will be key in building my curiosity. I know this to be true because I learn something new every time I do a scope, especially concerning the meniscus.

Although I could not attend in person, I was able to attend the Cape Town Summit virtually. This option was ideal for me given that there is only a 1 hour difference in time between Nairobi and Cape Town. The opening ceremony was quite absorbing, with the ISAKOS president reminding the audience that injured athletes do not usually play victim and pointing out that ISAKOS had adopted that outlook to organize a successful virtual Congress under the prevailing circumstances. The session also featured interesting anecdotes, such as the quote by Dr. Philippe Noel Neyret that you should never tell someone they are wrong but rather should allow them to give their opinion, and also give yours, because nobody is really right or wrong. On a personal level, this reminder will influence my future interactions with colleagues, trainees, and even those in non-professional settings. I was not able to attend all of the scientific sessions, but I continued accessing them online.

The closing ceremony was equally interesting. I derived several important lessons including not to be a “windgat” and to always remain enthusiastic. Moreover, I learned the values of ISAKOS, including the importance of brotherhood, from the president. The session on the ISAKOS Wine Club provided an interesting mix of orthopaedics, geography, and knowledge of wines.

I never met Dr. Freddie Fu in person, but I have interacted with him through his written work and through webinars. I join the orthopaedic and sports fraternity in mourning him and will endeavor to carry on his legacy in any way that I can.

Much as the virtual Congress has positively influenced my practice, I still look forward to the Traveling Fellowship in 2023 and the in-person Congress. I look forward to learning from accomplished arthroscopic and sports surgeons (literally standing on the shoulders of giants) and later passing the knowledge and skills to others.

Finally, I would like to thank the ISAKOS Traveling Fellowship Committee for the consideration and award of this Fellowship.



Saroj Rai, MBBS, MS (Ortho), PhD
*Blue Cross Hospital,
Kathmandu, NEPAL*

Like many others, I am deeply saddened by the passing of my most respected mentor, Dr. Freddie Fu, and would like to extend my sincere condolences to his family.

Owing to the ongoing COVID-19 pandemic, we faced not only the global economic crisis but we lost many friends, families and relatives. Nevertheless, we humans are very much adaptive creatures because in this harsh situation we have learned how to interact and learn virtually. Although we could not meet in person at ISAKOS Global Congress 2021, it was an amazing experience and widely successful online international meeting, and the organizing committee, including ISAKOS president Dr. Willem van der Merwe and program chair Dr. Volker Musahl, must be thanked.

My journey with ISAKOS started when I became the winner of the ISAKOS Young Investigator fellowship in 2017. This was my 3rd consecutive ISAKOS Congress, and this year has been particularly rewarding because I was declared as one of the winners of the prestigious ISAKOS Global Traveling Fellowship. Being a young orthopaedic sports surgeon from the developing country of Nepal, it was definitely not easy to compete with colleagues from the entire group of Asia-Pacific countries and win the fellowship. I feel extremely blessed.

As an ISAKOS Global Traveling Fellowship winner, I will be visiting different centers along with other fellow winners and an ISAKOS Godfather in 2023. I will have the chance to observe orthopaedic procedures performed by highly respected surgeons, discuss the procedures and all aspects of patient management, and share research experience. I am sure that this Traveling Fellowship will be extremely motivational and a most memorable lifetime opportunity. I cannot stop thanking my mentors Dr. Freddie Fu, Dr. Volker Musahl, and Dr. Binod Sherchan. I am also thankful to ISAKOS Traveling Fellowship committee and various ISAKOS staff, especially Joy Allen-Joseph.



Joseph J. Ruzbarsky, MD
*The Steadman Clinic and Steadman
Philippon Research Institute
Vail and Aspen, Colorado,
UNITED STATES*



Pamela Castro, MD
*Hospital Nacional Hipolito Unanue
Lima, PERU*

I feel extremely fortunate and grateful to have been selected as North America's 2023 ISAKOS Global Traveling Fellowship recipient. I am currently entering my second year of practice at The Steadman Clinic and Steadman Philippon Research Institute in Vail and Aspen Colorado, USA. Having completed both a sports medicine and hip preservation practice, I currently treat and investigate a broad array of musculoskeletal disorders encompassing elbow, shoulder, hip, and knee conditions. I am fortunate to have trained under great sports medicine thought leaders and surgeons at both The Hospital for Special Surgery and The Steadman Clinic, but I look forward to taking time out of my young practice to learn from international leaders in the field of sports medicine that are distinct from my training. I feel that this opportunity to experience unique perspectives will be invaluable, especially at a very malleable time in my career.

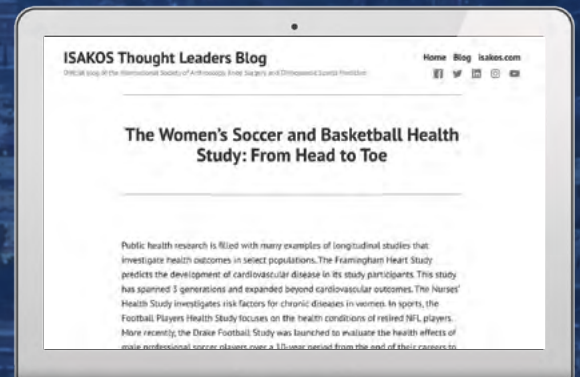Where better to immerse myself for a few weeks in the orthopaedic sports medicine world than a city and region that combines not only both great professional sports but also some of the strongest research and academic institutions in our country: Boston, MA? I am confident that this experience not only will enrich my career and practice but also will forge great friendships and a strong relationship with ISAKOS.

I feel very honored to have been selected for 2023 ISAKOS Global Traveling Fellowship. This program promises to be the experience of a lifetime, and I feel as happy as the time when I entered my residency program a few years ago.

I would like to thank ISAKOS for this amazing opportunity and for taking the initiative to promote the interchange of knowledge between sports orthopedic surgeons all over the world each and every year. This type of program provides its participants with exposure to a wealth of concepts, different techniques, and "tips and tricks". We all have experienced challenges during the COVID-19 pandemic, including changes in our lifestyles, the loss of many learning opportunities, and the need to exchange our familiar routines for other, uncomfortable ones—with many of us having seen our learning objectives and curves jeopardized. Receiving this award means so much to me: it provides a ray of hope, and I am looking forward to meeting all my fellow colleagues and our Godfather in June 2023 in the USA.

ISAKOS

Thought Leaders Blog



[ISAKOSBLOG.COM](https://www.isakosblog.com)

Read the latest post from Daphne Ling, PhD, MPH

The Women's Soccer and Basketball Health Study:
From Head to Toe

Patellofemoral Research Excellence Award



Rafael Sales Fernández, MD
Chorley, Lancashire,
UNITED KINGDOM

The Pathologic Double Contour Sign and the Trochlea Shape Patterns Can Diagnose Trochlea Dysplasia

We would like to thank ISAKOS for recognizing our work entitled “The Pathologic Double Contour Sign and the Trochlea Shape Patterns Can Diagnose Trochlea Dysplasia” and for granting us the Patellofemoral Research Excellence Award.

The ISAKOS 2021 meeting was a great success despite the significant worldwide disruptions caused by the COVID-19 pandemic. The quality and content of the program as well as the presentations by internationally renowned speakers were outstanding. We are looking forward to attending the next ISAKOS meeting in Boston 2023.

The memory of Freddie Fu and his legacy were present throughout the ISAKOS meeting. His contributions to sports orthopaedics and ACL reconstruction are second to none. I never met Freddie Fu in person, but his presentations immediately conveyed his charisma as well as his passion for anatomy, research, teaching, and communicating and engaging with orthopaedic surgeons and colleagues. He had the firm belief that outcomes after ACL reconstruction could be improved by better understanding anatomy and by developing and refining surgical techniques that could reproduce anatomy more precisely. His attention to detail, search for excellence, and research have been an inspiration to all of us and have left a massive legacy to the orthopaedic community. He will be missed but also will be remembered as one of the most influential figures in orthopaedics of all time. *Nanos gigantium humeris insidentes* (dwarfs standing on the shoulders of giants).

Freddie H. Fu’s research trajectory, like those of many other groundbreaking researchers, demonstrates how science can be advanced by questioning the established knowledge.

We define trochlear dysplasia as “an abnormally developed proximal trochlea with a distinctive pattern of deformity that causes patella maltracking and increased forces on the patellofemoral joint that can result in instability or chondral damage.” The diagnosis of trochlear dysplasia can be challenging for non-experts. Henry Dejour was a pioneer in defining qualitative and quantitative variables based on true lateral X-rays. David Dejour defined new qualitative radiologic signs (eliminating the quantitative variables described by his predecessor) and developed his own classification of trochlear dysplasia. Although that system is the most universally accepted classification method, it is not without problems. Specifically, not all trochlear dysplasia can fit into this classification scheme, it is difficult to obtain true lateral X-rays (unless fluoroscopy is used), the correlation between the radiologic signs and advanced imaging findings is not explained, poor interobserver and intraobserver reliability makes communication and research difficult, and the system does not provide a grade of severity (i.e., it does not distinguish between mild and severe grade-B dysplasia). The Bristol-Oswestry classification system does not completely solve the problems of the Dejour system.

Many other authors have tried to define variables for the diagnosis of trochlear dysplasia with use of advanced imaging studies (e.g., MRI or CT scans). These variables also have problems in that they are not very intuitive, are not based on pathophysiology, are time-consuming, are not user-friendly, are complex, and are not always reliable. As such, there was clearly a need to provide the general orthopaedic surgeon with a simple radiologic sign based on advanced imaging studies that could be used for the diagnosis of trochlea dysplasia.

In our study, we demonstrated that trochlear dysplasia can be defined by the presence of the Pathologic Double Contour (PDC) on axial MRI scans. The PDC is a pathognomonic sign of trochlear dysplasia (that is, it is not present in normal trochleae).

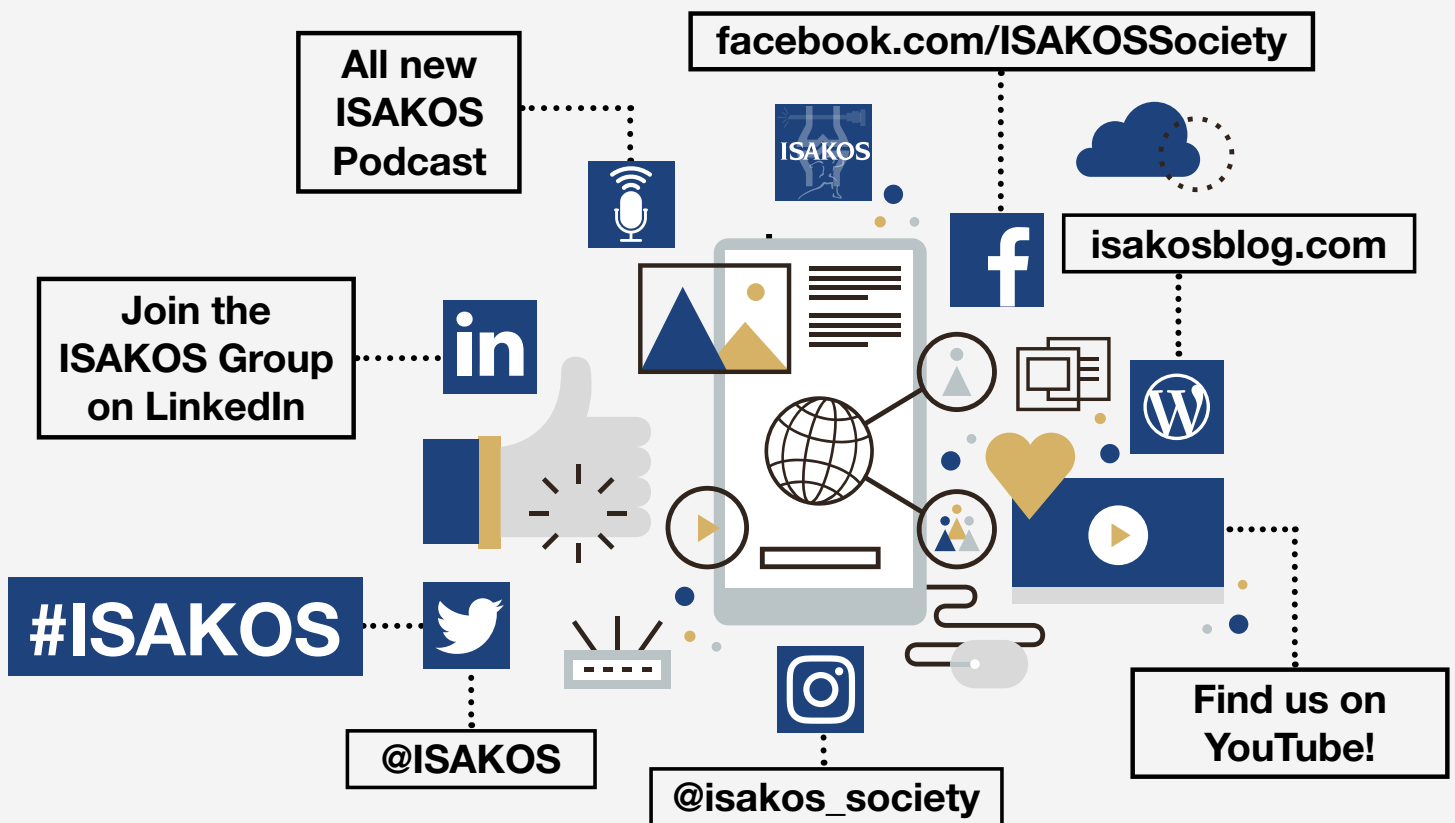Trochlear dysplasia is a complex three-dimensional deformity with different degrees of severity. However, a consistent pattern of deformity can be seen on axial MRI scans. In our report, we describe three patterns of trochlear morphology with use of Trochlear Shape Patterns (TSPs). TSP types 1 and 2 are consistent with normally developed trochleae, whereas TSP type 3 (defined as the presence of the PDC) is present in trochlear dysplasia.

We also describe two simple anatomical references (the Posterior Femoral Condyle Line and the Transverse Distal Femoral Physis Line) that allow consistent identification of the dysplastic trochlea. Trochlear dysplasia is a proximal deformity, and the PDC is always found at the level or proximal to the Posterior Femoral Condyle line.

The main finding of our study is that normal trochleae show TSP type 1 and 2 at any level above the Posterior Femoral Condyle line. Trochlear dysplasia (TSP type 3) is defined as the presence of the PDC sign at any level at or above the Posterior Femoral Condyle line.

We hope that this work will help orthopaedic surgeons to diagnose trochlear dysplasia, guide treatment, and refer patients when necessary.

Join the **ISAKOS** Global Conversation!



Tweeting About ISAKOS?

Include hashtag **#ISAKOS** in your Tweets to join the global conversation!

#ISAKOS

CALL FOR PAPERS

JISAKOS Has Advanced to Open Access and Moved to Elsevier

Learn more at
isakos.com/JISAKOS/Open-Access

ISAKOS
Members
Eligible for
20% Off APCs

The *Journal of ISAKOS* accepts submissions across a wide range of article types, including original articles and state of the art, systematic, current concept reviews, and case reports.



Interested in Becoming a Reviewer?

Log in to isakos.com/myisakos and select your preference in myAccount.

jisakos.org



ISAKOS 2021: Global Congress Albert Trillat Young Investigator's Award Winner



Danko Dan Milinkovic, MD
Resident Orthopedic Surgeon
Center for Musculoskeletal Surgery,
Charité-University Medicine Berlin
Berlin, GERMANY

I feel truly honored and privileged to have received the prestigious Albert Trillat Young Investigator's Award at the 13th Biennial ISAKOS Congress from a Committee of experts whom I have admired for years. To have the opportunity to be among the recipients of this award, which carries the name of one of the absolute legends of orthopedic surgery, is something that I will remember and appreciate for the rest of my professional life and career.

The study that I submitted for the award, entitled "The Bankart Knee: Biomechanical Consequences of a Posterolateral Tibia Plateau Impression Fracture As Concomitant Injury of ACL Rupture" was performed at the laboratory for biomechanical research of the Department of Trauma, Hand and Reconstructive Surgery of the Westphalian Wilhelms University in Muenster, Germany, under the supervision of my dear mentors, Prof. Mirco Herbolt from Munich, Germany, as well as Prof. Christian Fink from Innsbruck, Austria, along with support from Prof. Robert Smigielski from Warsaw, Poland. I would also like to express my gratitude to my colleagues and coauthors, Dr. Elmar Herbst and Dr. Christoph Kittl, for their immense help throughout this process, as well as the entire team of phenomenal engineers and fellow researchers at the Department for Biomechanical research in Muenster, Germany.


This study was a result of a mutual cooperation and continuous exchange of knowledge and ideas between the group of incredibly competent experts in their fields, whom I personally admire and from whom I have learned much. Therefore, I am very grateful to have had the opportunity to be a part of this entire process.

I would like to point out an interesting fact concerning this study, namely, that it was the very first study to address the potential biomechanical influences of posterolateral impression fractures of the tibial plateau in a setting of ACL deficiency. Even though some recently published studies have confirmed the high incidence of these fractures as concomitant lesions of an acute ACL injury, as well as high correlation between high-grade fractures and lateral meniscus lesions and consequent increase in clinical pivoting of the ACL-deprived knee joints, it is well known from the clinical practice that they are often left unattended. However, in our study, we were able to demonstrate that high-grade impression fractures of the posterolateral aspect of the tibial plateau do increase the instability of ACL-deficient knees from a biomechanical standpoint and that such fractures can result in a considerable increase in translational and anterolateral rotational instability of ACL-deprived knees. Therefore, our results can potentially help in providing and improving certain guidelines in the overall treatment decision-making process and present a solid basis for future considerations and further research with the focus on these concomitant lesions.

Finally, I am very grateful for this honorable award and would like to extend my gratitude to all ISAKOS Presidents, Committees, delegates, and members for their continued support of young researchers, for providing an immersive platform through which experts from around the world can share knowledge and build professional and personal ties, and for fostering a world-wide environment of collegiality and education from which we can all benefit.

If any colleague has additional interest, please feel free to contact me for any questions or possible research ideas regarding our study.

DISCOUNTED Arthroscopy Subscription for Members!



Through a strategic partnership with AANA, ISAKOS members are now able to purchase an annual, online *Arthroscopy* subscription for only USD \$65.

Log in to myISAKOS to add the online *Arthroscopy* subscription to your ISAKOS membership:
isakos.com/myISAKOS/myPublications

ISAKOS is committed to providing easier access to journals, publications, and industry updates. We encourage you to take advantage of this added opportunity and member benefit, as well as the opportunity to purchase a discounted online KSSTA subscription.

ISAKOS Young Investigator's Scholarship & Research Mentoring Program Finalist



Rodolfo Morales-Avalos, MD, MSc, MS (Ortho)
School of Medicine and University Hospital "Dr. Jose Eleuterio Gonzalez", Universidad Autonoma de Nuevo Leon Monterrey, MEXICO
Equilae Group, Knee and Arthroscopy Unit, ICATME, Hospital Universitari Dexeus, Universitat Autonoma de Barcelona Barcelona, SPAIN

I am a 30-year-old Mexican knee surgeon and clinical anatomist. I recently graduated from the annual Fellowship in Knee Surgery and Sports Traumatology Program headed up by Prof. Joan Carles Monllau in Barcelona, Spain. I am now participating in the PhD program in medicine and surgery at the Autonomous University of Barcelona. At present, I am working on my thesis under the supervision of Prof. Joan Carles Monllau again as well as Prof. João Espregueira-Mendes. It is this jointly-proposed thesis work that was sent in for this ISAKOS program. At present, I am back in Mexico, where I practice medicine and do research in the hospital where I completed my residency (Universidad Autonoma de Nuevo Leon). I am also a professor of Physiology and Orthopedics as well as a member of the national research program in Mexico. My main lines of research are the treatment of joint cartilage injuries in experimental models, anatomical studies applied to arthroscopic surgery, controlled clinical trials in reconstructive knee surgery, and allogenic meniscal transplantation.

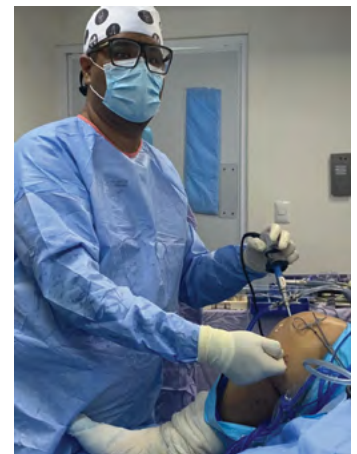We are currently conducting a study that aims to evaluate the biomechanics of the recently described meniscus-tibial-popliteal fibular complex through anatomical and radiological studies. The work will also cover the role of this structure in the radial mobility of the lateral meniscus, acting as a possible restrictor of the phenomenon of meniscal extrusion. Moreover, we are carrying out anatomical studies with the aim of finding and describing the variations between young and elderly specimens in terms of the morphology of the tibial and femoral insertions of the anterior cruciate ligament.

I would like to thank the organizers of the program for making it possible for me to receive a scholarship to attend the virtual congress in 2021 and the next in-person congress, scheduled to be held in Boston in 2023. This meeting represents a great opportunity for me to stay up to date on new developments in the field of knee surgery and share the results of our own research with the rest of the orthopedic community.

What I appreciate about ISAKOS is that it is an international society that has widely promoted scientific research by young surgeons through programs such as this one as well as through the ongoing mentoring and supervision efforts of its panel of experts. With those experts behind me, the study will be carried out in a timely, orderly way, following the scientific method.

The Young Investigator's Scholarship and Research Mentoring Program represents an excellent platform for the development of research work in developing countries as it puts the necessary resources within the reach of young investigators. Moreover, it provides a personal incentive for me to continue my research. As there is constant innovation in our specialty, it is sometimes difficult to keep up to date with the varying technological advances that are published every day in the different journals.

I look forward to seeing the rest of the finalists, winners, and members of the program at the next congress in Boston.



Knee & Shoulder Arthroscopy Lab Course

November 18–19, 2022

Miami Anatomical Research Center (MARC)

Doral, FL

Course Chairs



Guillermo R. Arce, MD
ARGENTINA



John G. Lane, MD
UNITED STATES

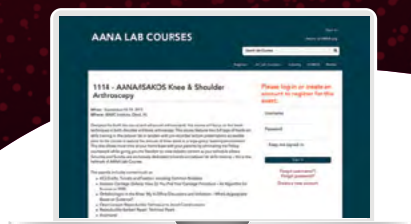


Nicholas Sgaglione, MD
UNITED STATES

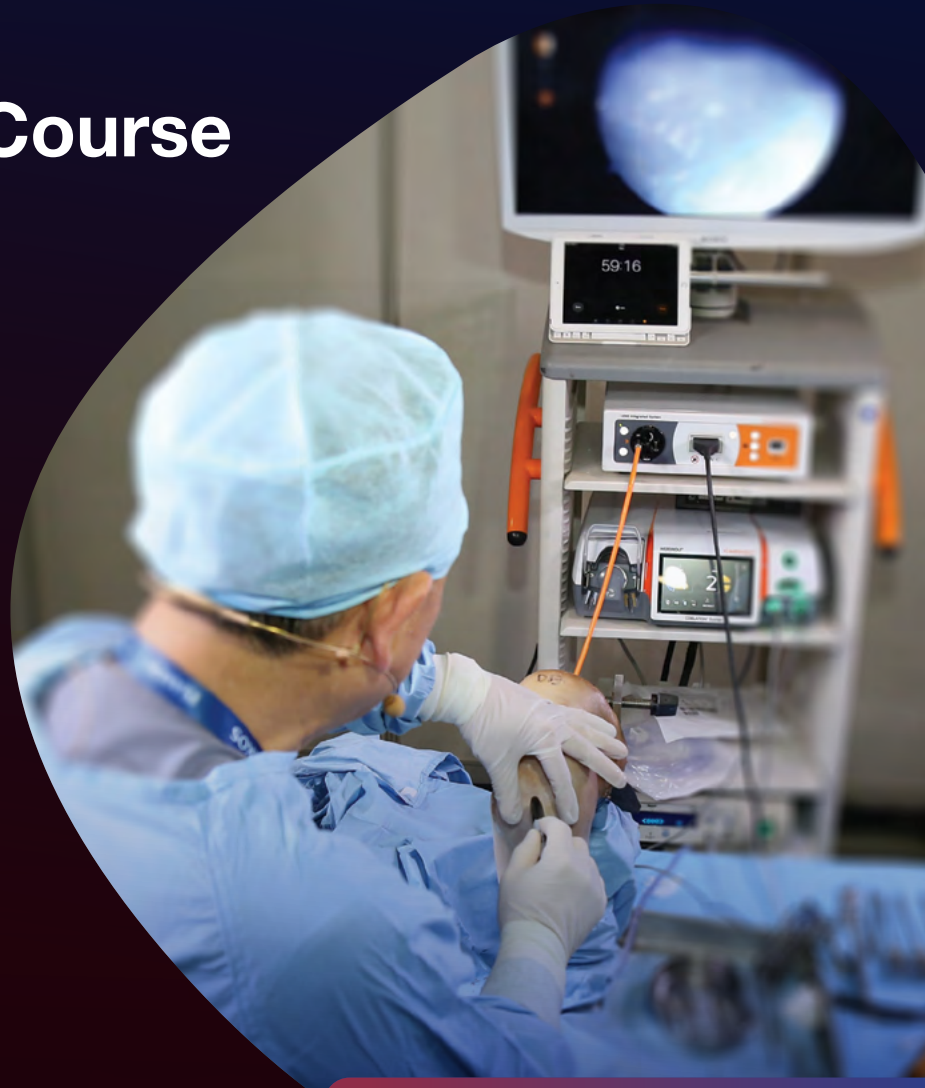

Larry D. Field, MD
UNITED STATES

Designed for both the casual and advanced arthroscopist, this course will focus on the latest techniques in both shoulder and knee arthroscopy. This course features two full days of hands-on skills training in tandem with pre-recorded presentations (accessible prior to the course!).



isakos.com/Arthroscopy2022



**IN-PERSON,
HANDS-ON CADAVER LAB!**

- ACL Grafts, Tunnels and Fixation
 - Isolation Cartilage Defects
 - Orthobiologics in the Knee
 - Open Latarjet
 - Reproducible Bankart Repair
- And More!**

 Limited Spots Available –
REGISTER TODAY!

ISAKOS Young Investigator's Scholarship & Research Mentoring Program Winner



Yogesh Soni, MS Orthopedics
DNB Orthopedics
Kondagaon, INDIA

I am currently working as a Consultant Arthroscopy & Trauma surgeon in a private setup in Bhilai, Chhattisgarh, India. I also work as an Assistant Professor at a medical college, SSIMS Bhilai, where I am actively involved in teaching program and clinical research activities. I am thankful to the ISAKOS Young Investigator's Scholarship committee for giving me this opportunity to improve my knowledge and skills in the field of arthroscopy, knee surgery, and sports medicine. I am eagerly awaiting the next physical congress in Boston in 2023, where I look forward to meeting the international experts of this field in person.

As a recipient of this award, I was able to attend the virtual congress on November 27 and 28, 2021. Although the meeting was virtual, the lessons learned were not diminished by any means.

The academic schedule started with the Cape Town session, continued with the Buenos Aires and San Francisco sessions, and finally ended with the Sydney session. It was amazing to learn about the journey of the organization, its transformation from the IAA and ISK to the ISAKOS, and its glorious 25-year history. Learning about the career highlights of the great surgeon and stalwart of ACL surgery, Dr. Freddie Fu, was a very emotional experience. It was wonderful to watch case-based discussions regarding a wide range of topics such as meniscus repair versus resection, failed rotator cuff repair, hip instability, shoulder instability, and ankle syndesmosis. Surgical videos of ACL reconstruction and meniscal repair as well as quadriceps tendon ACL and PLC reconstruction helped me to learn some novel techniques. Live symposia on different subjects such as osteotomies around the knee joint, the mental aspect of injury, TKR alignment, and basic wrist pathology provided the extra edge for my clinical skill development. Hearing my name on the list at this platform literally gave me goosebumps.

I would like to give the credit to my family, my colleagues, and all of my mentors, with special mention of Dr. Manit Arora, who encouraged me to become a member of this prestigious society. I also would like to congratulate my fellow colleagues who were selected for this award. It is a great honor and privilege to receive this award, and I am very much looking forward to the next congress.

ISAKOS Young Investigator's Scholarship & Research Mentoring Program Winner



Lokesh Kumar Yogi, MBBS,
MS-Ortho
Consultant, Department of Orthopaedics,
Bhilwara Multispeciality Hospital,
INDIA

I recently received a Young Investigator Scholarship award that allowed me to attend the ISAKOS 2021 conference. It was my privilege and honor to represent my country at an international global arthroscopy platform that provided me with the opportunity to learn about the recent advances in the field and to meet the international faculty. The conference was a wonderful experience and an enriching academic feast. It was an honor to meet the pioneers in the various fields of orthopaedics from India and around the world, and I very much enjoyed the opportunity to share this experience with the other award winners, who had also been selected to attend the meeting. One particularly memorable session was dedicated to providing young orthopaedic investigators with insights into the field of research and publication, with all attendees receiving a book entitled Basic Methods Handbook for Clinical Orthopaedic Research. I am very grateful to have had this opportunity and would like to extend my thanks to the ISAKOS organizing committee, the faculty, the delegates, the fellow young investigators, and, last but not least, my alma mater.



ISAKOS Young Investigator's Award 2021



Anindya Debnath, MS, DNB
Asha Nursing Home
Agartala, INDIA

I cordially thank ISAKOS for nominating me for the ISAKOS Young Investigator's Award 2021. The award was supposed to have been presented during the 2021 ISAKOS Biennial Global Conference, originally scheduled to be held in the pleasant ambience of Cape Town, South Africa. However, since the conference had to be held on virtual platform, the award is now slated to be presented during the next conference, scheduled to be held in Boston in June, 2023.

Our original research article is entitled "Medium-Term Results of One-Stage vs. Two-Stage Bilateral MPFL Reconstruction for Bilateral Patellofemoral Joint Instability: A Retrospective Cohort Study". The article has been shared with the 2021 ISAKOS audience in the on-demand content section (as a paper presentation). I and my co-authors from the Department of Trauma and Orthopedics, Princess of Wales Hospital, Bridgend, Wales, UK, express our immense pleasure to participate in the ISAKOS global conference, and we look forward to meeting our colleagues from around the world during the Boston conference. I also believe that our association with the ISAKOS community paves the way for sharing experiences and expertise and is greatly helpful in keeping updated with the latest advances in the field.

ISAKOS Knee Arthroplasty Fellowship Recipient



Dr. Amit Lakhani
Associate Professor AIMS
Punjab, INDIA

The *ISAKOS 2021: Global Congress* meeting was a great pleasure to attend. This meeting not only helps to improve the current knowledge in orthopaedics but, due to its flexibility and affordability, it also has become very convenient for a delegate to attend. Moreover, the educational content offers practitioners a comprehensive overview of the latest advances in orthopaedics, with topics updated on an annual basis to highlight new research, treatments, and technology.

Another reason for orthopaedic surgeons and other health-care professionals to attend this virtual conference was the high-level interaction, providing attendees with the opportunity to engage 1-on-1 with presenters and to participate in dynamic group discussions.

Finally, I express my heartfelt delight to have received the Knee Arthroplasty Fellowship. I consider myself lucky to have received this award from ISAKOS and the Nicolaas Institute of Constructive Orthopedic Research & Education Foundation. I hope to continue doing my best in the future. This accomplishment represents a significant milestone in my life. I extend my gratitude for allowing me to receive this Fellowship and for considering an orthopaedic surgeon from a rural setting in India to learn advances in arthroplasty and sports medicine. I am humbly thankful to the team who selected me for this award. Thank you for motivating me to continue to maintain the highest level of dedication for the welfare of my patients and to serve mankind.

2022 ISAKOS

by the Numbers

Congress

2021 ISAKOS Congress
in virtual Global Congress



450+

Faculty & Presenters
from 50+ Countries

36

Instructional Course
Lectures

23

Surgical
Demonstrations

10

Debates

1,600+

Abstracts
Submitted

15

Global Case-based
Discussions

2

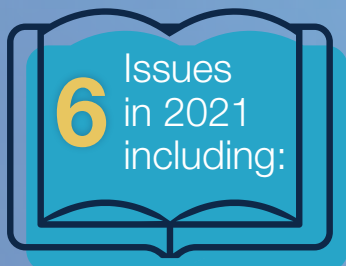Round Table
Discussions

41

Symposia

ISAKOS Publications

Journal of ISAKOS



6 Issues
in 2021
including:

38

Papers
Published

224

Unique
Authors

130

Unique
Reviewers

ISAKOS Biannual Newsletter

2

Issues
in 2021

15

Current
Concepts



2,500+

Print
Subscribers

4,030

Digital
Views

ISAKOS Books

37

Books and Booklets
Published to Date

6

New Books in
Production for '22-'23



Society

 **ISAKOS**
Membership

Over 90%

Member **Retention**

Members in

98

Countries

3,000+

Members
Worldwide



ISAKOS
Committees

29

Total
Committees

262
Committee
Members

33

Meetings
Held in 2021

ISAKOS Education

ISAKOS Webinars

10

Webinars
in 2021

10+

Webinars Planned
for 2022

Participants from

124

Countries



10,000
Registrations

ISAKOS Global Link

53

Surgical
Videos

23

Webinar
Recordings

100

Micro-Learning
Videos

1,000+

Media Items
from 2021 Global Congress



Research Grants

10+

Total Grants
Given

4

Research Grant
Categories

\$195K

Funding per
Grant Cycle

Awards,
Fellowships,
& Scholarships

13

Award & Fellowship
Opportunities

250+

Award & Fellowship
Applicants



International Society of
Arthroscopy, Knee Surgery and
Orthopaedic Sports Medicine

Thank you for helping ISAKOS continue to
provide excellence in research and education.

isakos.com

UPCOMING ISAKOS APPROVED COURSES

1st SIAGASCOT Annual Meeting
Seraphicum Convention center
Rome, ITALY

March 10–12, 2022

Chair(s): Nives Sagramola

For further information, please contact:

Email: nives.sagramola@siagascot-orto.com

Tel: 00393383837991

<https://siagascot-orto.com/siagascot2022/>

Principles of Knee Arthroscopy
Mater Misericordiae Hospital
Nairobi, KENYA

March 17–19, 2022

Chair(s): Samuel Owinga

For further information, please contact:

Email: owingasamuel@gmail.com

Tel: +254722522016

<https://www.arthroscopyeaa.org/about>

16th ICRS World Congress Berlin
Intercontinental Berlin
Berlin, GERMANY

April 12–15, 2022

Chair(s): Christoph Erggelet, MD

For further information, please contact:

Email: office@cartilage.org

Tel: +41 (0)44 503 73 70

<https://cartilage.org/icrs2021-world-congress-berlin/>

Shoulder360. The Comprehensive
Shoulder Course
Loews Hotel Miami
Boulder, Colorado, UNITED STATES

April 28–30, 2022

Chair(s): Raffy Mirzayan

For further information, please contact:

Email: lakersdoc@gmail.com

Tel: 310-909-6977

<https://www.shoulder360.org>

5th Athens Shoulder Course
Megaron Athens International
Conference Center
Athens, GREECE

May 4–7, 2022

Chair(s): Emmanouil Antonogiannakis

For further information, please contact:

Email: info@concopco.com

Tel: +302106109991

<https://www.athens-shoulder-course.com/>

4th International
Extreme Sports Medicine Congress
St. Julien Hotel and Spa
Boulder, Colorado, UNITED STATES

May 20–21, 2022

Chair(s): Omar Mei-Dan

For further information, please contact:

Email: Ellen.Rhodes@cuanschutzu.edu

Tel: 303 724 2961

<https://medschool.cuanschutzu.edu/orthopedics/clinical-services/sports-medicine/news-and-events/2022/05/20/sports-medicine/intern>

9th Biannual Congress of the Hellenic
Society of Arthroscopy, Knee Surgery and
Sports Traumatology “Georgios Noulis”
Thessaloniki, GREECE

June 9–11, 2022

Chair(s): Michael Iosifidis

For further information, please contact:

Email: info@orthobiologics.gr

Tel: +306977505275

<https://www.eae-net.gr/en/library/haa-meetings/107-90-eae-congress2022-en>

San Diego Shoulder Institute's 39th Annual
Course: Arthroscopy, Arthroplasty, Fractures
Hotel Del Coronado
Coronado, California, UNITED STATES

June 15–18, 2022

Chair(s): Patrick Denard, MD

For further information, please contact:

Email: Larky@shoulder.com

Tel: 760 445 2874

<http://www.shoulder.com>

ICRS Focus Meeting Thessaloniki
Hotel Mediterranean Palace
Thessaloniki, GREECE

June 23–26, 2022

Chair(s): Emmanuel Papacostas
& Christoph Erggelet

For further information, please contact:

Email: office@cartilage.org

Tel: +41 (0)44 503 73 70

<https://cartilage.org/icrs-focus-thessaloniki/>

31st Annual Arthroscopy & Arthroplasty
Utrecht Courses 2020
(5 courses on ankle, elbow, knee, shoulder)
University Medical Center Utrecht,
The Netherlands
Utrecht, NETHERLANDS

July 4–8, 2022

Chair(s): Rob P.A. Janssen, MD, PhD

For further information, please contact:

Email: info@shoulder-elbow-knee.nl

Tel: 3165146 5892

<https://www.shoulder-elbow-knee.nl>

20èmes Journées Lyonnaises de
Chirurgie du Genou – THE PATELLA
Convention Center
Lyon, FRANCE

September 22–24, 2022

Chair(s): Guillaume Demey

For further information, please contact:

Email: florence.bondoux@lysk.fr

Tel: 0033 632071990

<http://www.lyon-knee-congress.com>

The Combined Meeting of
TOSSM & APKASS 2022
PEACH, Royal Cliff Hotels Group
Pattaya, THAILAND

September 29–October 1, 2022

Chair(s): Chanakarn Phornphutkul

For further information, please contact:

Email: nprasathaporn@gmail.com

Tel: 662-716-5437

Fax: 662-716-5440

<https://apkass2022.org>

6th ICRS Summit – Joint Preservation –
Where We Are in 2022?
Doral National Miami
Miami, Florida, UNITED STATES

November 17–19, 2022

Chair(s): Tom Minas

For further information, please contact:

Email: office@cartilage.org

Tel: +41445037371

<https://cartilage.org/icrs-summit-miami/>



IS YOUR MEETING,
WEBINAR, OR
VIRTUAL COURSE AN...



ISAKOS
APPROVED
COURSE

www.isakos.com/meetings

Reach more + repair more

FAST-FIX FLEX enables all-zone all-inside meniscal repairs empowering surgeons to treat previously inaccessible tears*¹⁻³

Enhance Accessibility with needle and shaft modifications to access mid-body and anterior zones accounting for over 40% of tears^{+1,2,4}.

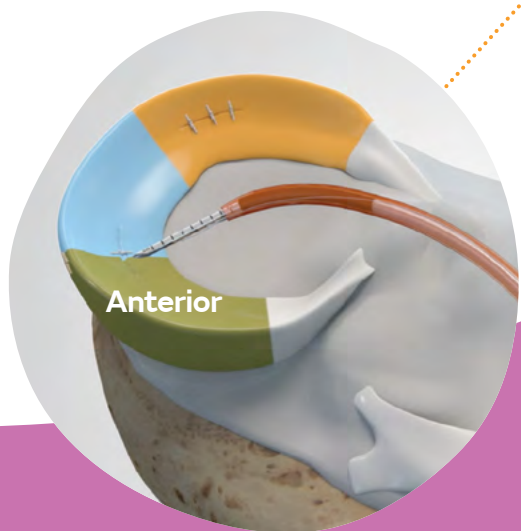
Preserve Anatomy with a ~25% smaller needle insertion area and a ~20% stronger repair^{**5,6}

Increase Reliability with implant deployment you can hear, feel and see¹. Go to [AllTearsAllRepairs.com](https://www.alltearsallrepairs.com).

Smith+Nephew



FAST-FIX[◇] FLEX
Meniscal Repair System



*Compared to predicate device +in stable adult knees ^as demonstrated in biomechanical testing **References 1.** Smith+Nephew 2021.Validation, FAST-FIX FLEX. Internal Report. 15010267 Rev A. **2.** Smith+Nephew 2021.Validation, FAST-FIX FLEX. Attachment B. Internal Report. 15010267 Rev A. **3.** Smith+Nephew 2021.FAST-FIX FLEX- Surgeon Surveys. Internal Memo. **4.** Metcalf MH, Barrett GR. Prospective evaluation of 1485 meniscal tear patterns in patients with stable knees. *Am J Sports Med.* 2004;32(3):675-680. **5.** Smith+Nephew 2021.Competitive, FAST-FIX FLEX Dimensional Analysis. Internal Report. 15010919 Rev A. **6.** Smith+Nephew 2020. Biomechanical Testing, FAST-FIX FLEX. Internal Report. 15010180 Rev A.

Smith & Nephew, Inc., 150 Minuteman Road Andover, MA 01810, www.smith-nephew.com, US Customer Service: +1 800 343 5717 [◇]Trademark of Smith+Nephew.
©2021 Smith+Nephew. All rights reserved. Printed in USA. 29391 V1 0521

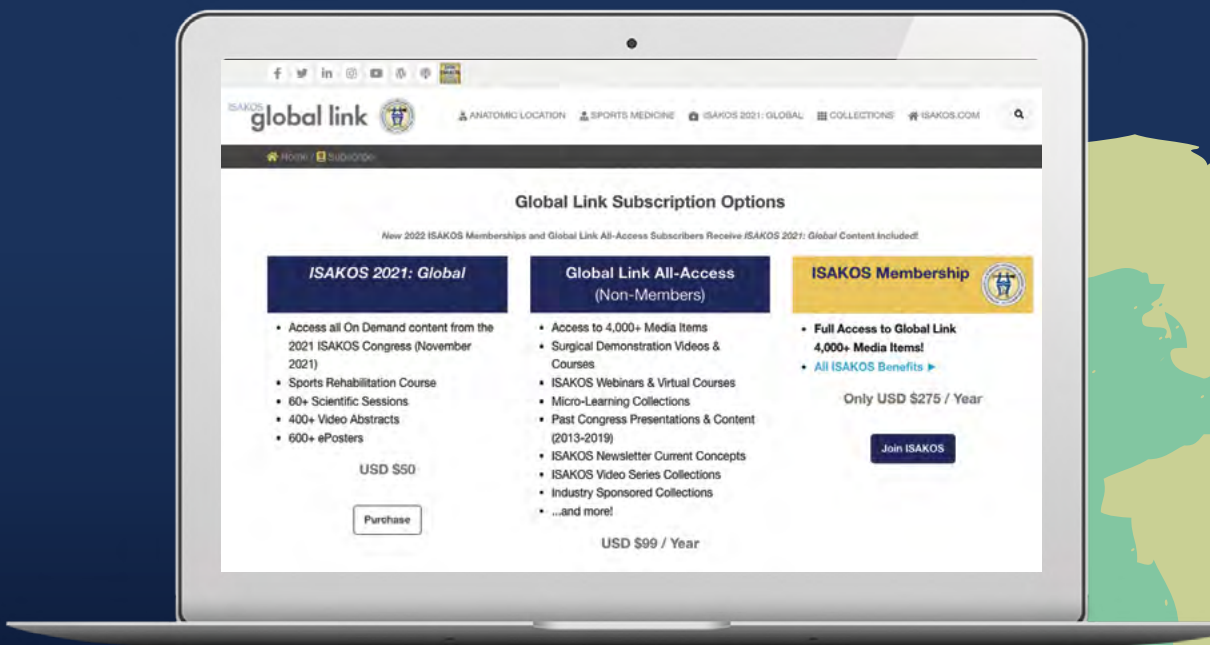


**ISAKOS
CONGRESS
2021**

GLOBAL
Nov 27 - 28

Content Available
on Global Link!

Registrants of the *ISAKOS 2021: Global Congress* get full access to all Congress presentations and content through December 31, 2022!



isakos.com/GlobalLink/Subscribe

Didn't attend the Congress?

Receive access to *ISAKOS 2021: Global* presentations by:

- Joining ISAKOS + Receive 2021 Congress content for free!
- Subscribing to Global Link + Receive 2021 Congress content for free!
- Purchasing 2021 Congress content for only USD \$50