

# ISAKOS

## ISAKOS NEWSLETTER 2021 • VOLUME II

Current Concepts on Arthroscopy, Knee Surgery & Orthopaedic Sports Medicine



REGISTER  
TODAY!



ISAKOS  
CONGRESS  
2021

GLOBAL  
Nov 27 - 28

CONGRESS  
PROGRAM

PG. 4

### INSIDE 2

*J*ISAKOS MOVES TO OPEN ACCESS  
& ELSEVIER

4

ISAKOS 2021 GLOBAL CONGRESS PROGRAM

16

MENISCAL TRANSPLANTATION, TECHNICAL  
INNOVATIONS & RETURN TO SPORTS

24

OSTEOCHONDRITIS DISSECANS  
OF THE CAPITELLUM

28

GLENOID TRACKS IN PATIENTS WITH  
ANTEROINFERIOR INSTABILITY WITH  
BIPOLAR BONE LOSS

34

WOMEN IN RESEARCH



# in this issue

Editor's Message . . . . .	1
<i>JISAKOS</i> Editor in Chief's Message . . . . .	2
ISAKOS 2021 Global Congress Program . . . . .	4
Memorials . . . . .	12
Current Concepts . . . . .	16
Approved Courses . . . . .	40

## EDITOR

Robert G. Marx, MD, MSc, FRCSC UNITED STATES

## EDITORIAL BOARD

Iftach Hetsroni, MD ISRAEL, Associate Editor

Tahsin Beyzadeoglu, MD, Prof. TURKEY

Raju Easwaran, MS(Orth) INDIA

Joshua D. Harris, MD UNITED STATES

Michail I. Iosifidis, MD, PhD GREECE

Yee-Han Dave Lee, MD, MBBS, FRCS(Orth)  
SINGAPORE

Daphne Ling, PhD, MPH UNITED STATES

Haliit Pinar, MD, Prof. TURKEY

Dipak Raj, FRCS(Tr&Orth), MCh(Orth), MS(Orth)  
UNITED KINGDOM

Sachin R. Tapasvi, MBBS, MS, DNB, FRCS INDIA

Samuel A. Taylor, MD UNITED STATES

Soshi Uchida, MD, PhD JAPAN

Kyoung-Ho Yoon, MD, PhD, Prof.  
REPUBLIC OF KOREA

Omer Mei-Dan, MD UNITED STATES, Past Chair



**International Society of  
Arthroscopy, Knee Surgery and  
Orthopaedic Sports Medicine**

567 Sycamore Valley Road W.,  
Danville, CA 94526-3900 USA  
Telephone: +1 925 807-1197  
Fax: +1 925 807-1199  
Email: [isakos@isakos.com](mailto:isakos@isakos.com)

## OFFICE MESSAGE

# The ISAKOS Office is excited

to take on the challenge of supporting the *ISAKOS 2021: Global Congress*, which promises to be a virtually unique and truly international online meeting. While we wish an in-person meeting in Cape Town were possible, we believe the ISAKOS Program Chairs and leadership have developed an exceptional *ISAKOS 2021: Global Congress* for November. Scheduled for the weekend of November 27-28, *ISAKOS 2021: Global* will meet you where you are—coming to you live from Cape Town and from studios around the world! International programming will be available online during attendees' local time zones, along with opportunities for networking and interaction. This meeting model has been reimagined to provide a safe and convenient way for the international ISAKOS community to gather online, expand surgical skills and knowledge, and learn from renowned experts in the field—all while enjoying the unparalleled international camaraderie that ISAKOS is known for. As a bonus, registrants will benefit from 30 days of exclusive access to all content. What's best: to attend, we ask that registrants pay what they can afford—if you haven't already, register today at [isakos.com/2021!](http://isakos.com/2021!)

Beyond planning for *ISAKOS 2021: Global*, the ISAKOS Office has been busy supporting production of additional educational offerings such as the ISAKOS webinars series—with 10 new webinars in 2021 alone. The latest webinar, "How to Get Published - Editor's Tips for Maximizing Your Journal Submissions," was held in early September and chaired by *JISAKOS* Editor in Chief Niek van Dijk from the Netherlands, plus Deputy Editor Elizabeth Arendt from the USA. In August, the Sports Medicine Committee presented a webinar with ESSKA titled, "Running Injuries in Athletics - How to Prevent and Manage." All ISAKOS webinar recordings are available to ISAKOS members and subscribers on ISAKOS Global Link along with accompanying micro-learning video clips.

Also on Global Link is the popular video series, *ISAKOS Giants in Orthopaedic Sports Medicine*. View the most recent interview with ISAKOS Past President John Bergfeld from the USA. Don't miss these up close and personal interviews and stories from legends in our field. For the ISAKOS Podcast, we had the pleasure of interviewing talented ISAKOS Member, Kamali Thompson, an orthopaedic surgery resident from the USA, in advance of her trip to Tokyo in July as an alternate with Team USA Olympic Fencing. Both the podcast and blog versions of the inspiring interview are available everywhere you get your podcasts and on [isakosblog.com](http://isakosblog.com). Don't forget, you can always stay up to date with the latest and greatest from ISAKOS through the weekly e-news brief, *ISAKOS Digital Digest*—complete with ISAKOS news and a variety of trending articles from *JISAKOS*, *ISAKOS Newsletter*, and other relevant orthopaedic journals and sources.

As you can see, the ISAKOS Office continues working behind the scenes prepping for *ISAKOS 2021: Global*, producing high-demand educational content, maintaining collaborations and seeking opportunities with our Partner Societies—all while settling into a brand new office! Beginning this past May, as vaccinations allowed COVID restrictions to lift, the ISAKOS team returned to the workplace in a hybrid model, moving into a new office in Danville, California. The staff have settled in nicely to their new space—while working with ISAKOS Committees to wrap up their 2019-2021 terms, preparing to onboard new committees in the coming months, and continuing to push forward with plans for the newly reformatted virtual Congress. We are truly invigorated by the continued innovation of ISAKOS and excited to virtually welcome you to





# The Evolving Role of ISAKOS in Global Education

ISAKOS plays many roles to advance learning worldwide. The dissemination of education, research and patient care is central to our mission for clinicians around the world. By the end of 2021, ISAKOS will have more than ten new books published with Springer. This is thanks to the work of our committees over the past two years and, more specifically, the editors and authors who contributed. In addition, there are several more books in progress for 2022.

The *Journal of ISAKOS* is moving to Open Access starting in 2022. This will make the content more available to clinicians around the world. Additionally, *JISAKOS* is now indexed on Medline and PubMed, which will make all articles easier to find and reference in the future.

ISAKOS is also expanding the diversity of the faculty invited to participate in ISAKOS 2021 in November. This will include greater gender, age and geographic diversity among the live and recorded presentations, compared to prior meetings. The event also will include global case-based discussions that engage leading experts from around the world.

As we look ahead to 2022 and as in-person meetings return, ISAKOS faculty are being recruited by our partner societies to help teach locally. ISAKOS lends the global perspective to our continental societies to provide a different perspective on the most important and cutting-edge clinical topics. We all look forward to in-person congresses returning; however, we have learned a lot through the ISAKOS Webinars and Virtual Courses, which we will continue to provide through our Global Link portal. This makes our educational content more accessible around the world, not only for ISAKOS members but also for those who want to register for the individual programs or who choose to view the content as Global Link subscribers.

## Robert G. Marx, MD

ISAKOS Newsletter Editor 2019–2021  
UNITED STATES



# JOURNAL OF ISAKOS

Joint Disorders & Orthopaedic Sports Medicine

So much is  
happening  
for *JISAKOS*

So much has happened for *JISAKOS* since my last Editor's message as we entered 2021, and I'm excited to share all this news with you. First of all, I hope you have seen my last 2 editorials in the journal, which also detail these exciting advances.<sup>1,2</sup> However, this Editor's Message repeats some of the key points of those editorials, as this news bears repeating!

## Medline/PubMed Indexing and Acceptance into the ESCI

*JISAKOS*' recent acceptance to be indexed in Medline and PubMed was a very welcome and satisfying bit of news. For the past 5 years, together with the Editorial Board we have worked hard to ensure *JISAKOS* was attracting and publishing high-quality papers and science, and the acceptance into Medline and PubMed was the validation of that work.

Just prior to that news, we had learned of *JISAKOS*' acceptance into the Clarivate Analytics Emerging Resources Citation Index (ESCI), a precursor to the Journal Citations Reports and Impact Factor rankings. Both of these important steps will ensure that *JISAKOS* is even more visible and accessible to physicians around the world. I also expect they will help us increase submissions to the journal, which already has seen a sizeable increase in 2020.

In order to provide continued momentum and share the content of *JISAKOS* with an even larger audience, I am announcing two more very exciting next steps for *JISAKOS*: a move to being an Open Access journal, and a move to a new publisher, Elsevier, beginning January 1, 2022. The choice for a new publisher was made after a rigorous and thorough process and the result of the significant hard work and expertise of the Journal's Board of Trustees, ISAKOS Board of Directors and the ISAKOS staff.

## JISAKOS Moving to Open Access

You may recall that I wrote a scathing editorial about Plan S, the funding coalition that dictates that any research funded by any of its members must be published in fully open access journals.<sup>3</sup> To be clear, I am not opposed to open access as a publishing model. On the contrary, it makes sense for research, especially clinical medical research and information, to be freely available to everyone upon publication. Preferably, one should have a choice of where and how to publish, and so I am still critical of a coalition that demands that a researcher publish their results with a specific type of journal. For *JISAKOS*, a move to open access fulfills the mission of ISAKOS as a not-for-profit medical education membership society.

So, this means that authors who publish in *JISAKOS* will make their research and articles immediately and permanently freely accessible worldwide. *JISAKOS* authors will pay an article publishing charge (APC), have a choice of license options, and will retain copyright to their published works. The APC will be requested after the article has been peer reviewed and only when it is accepted for publication. This will begin with accepted articles submitted after August 1, 2021. The APC will be \$1500 for full-length articles and \$750 for shorter articles such as case reports, technical notes and surgical technique video submissions. As a member benefit, ISAKOS members will receive a 20% discount on the fees. And our new Elsevier author portal will also provide information on institutions who help authors to offset APC fees, if they do not have a research grant with earmarked funds. Elsevier also participates in Research4Life, which is a program that can help authors in developing countries get access to funding and discounts, as well as potential fee waivers. All solicited articles will be waived. We will be posting more details and information about this shift to OA on the *JISAKOS* web site and author instructions.

I look forward to receiving your future submissions as **JISAKOS continues to grow, evolve and reach a broader global audience.**

## Publishing with Elsevier

I am also excited to work with our new publisher, Elsevier. *JISAKOS* has been published by the BMJ Group since 2016 and we deeply appreciate all that they have done to help *JISAKOS* as a start-up journal. As part of the journal's evolution and growth, we look forward to the journal being on the Science Direct platform, which is the largest and most widely accessed market leading online journal platform in the world. The exposure we will receive in addition to the journal moving to an Open Access model will ensure that the outstanding surgical research, techniques, and reviews will reach the broadest possible audience.

The move will also allow us to build online collections of article by topic, technique, or joint, and provide easier access and discoverability to the content we publish. As things move forward we will be announcing more new features and perks for authors and reviewers, such as the author feedback program, the reviewers' recognition program and the "your paper your way". I hope you will share in my excitement for this move!

The remainder of 2021 will see us highly engaged in the transition to Open Access, as well as publishing our first content with Elsevier in 2022. As the Editor in Chief of *JISAKOS*, I am enthusiastically committed to publishing the best papers that will make a positive impact on our field and for our patients.

## References

Medline is a database with publications of >4500 medical journals. PubMed is the search engine who brings us the data from Medline

1. van Dijk, CN. *JISAKOS* is now indexed in MEDLINE/PubMed. *Plan S. Journal of ISAKOS: Joint Disorders & Orthopaedic Sports Medicine* 2019; 6:125.
2. Van Dijk, CN. The next exciting step for *JISAKOS*: Transition to OA and a new publisher. *Journal of ISAKOS: Joint Disorders & Orthopaedic Sports Medicine* 2021; 5: 1-2.
3. van Dijk, CN. Science is being corrupted by governments and publishers; the argument against Plan S. *Journal of ISAKOS: Joint Disorders & Orthopaedic Sports Medicine* 2019; 4: 1-2.



**C. Niek van Dijk, MD, PhD**  
**NETHERLANDS**

Editor in Chief, *JISAKOS*  
c.niekvandijk@jisakos.com

# Why

Attend The

## ISAKOS 2021 GLOBAL CONGRESS?

### MISSION IMPOSSIBLE

With a global pandemic on our heels, we simply cannot be in-person in Cape Town this year. We are as sad as you are! But rest assured, your participation in *ISAKOS 2021: Global* will make it possible to carry out ISAKOS' mission.



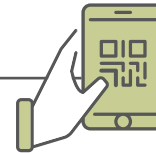
### ISAKOS-LEVEL EDUCATION

*ISAKOS 2021: Global* will still provide the premier, international education that ISAKOS is known for—including cutting-edge surgical techniques and approaches to clinical management, combined with overviews of current controversies in orthopaedics.



### ENGAGING

Coming to you live from Cape Town, plus studios around the world! The ISAKOS Presidential line and Program Chairs will help you engage and interact with world-renowned experts.



### CONVENIENT

Enjoy *ISAKOS 2021: Global* on any device—from home, the office, or even a locker room!

### FLEXIBLE

You choose your participation—join the 4-hour time block that best fits your time zone up to the full 16 hours of live-hosted, *ISAKOS 2021: Global* content, or anything in between.



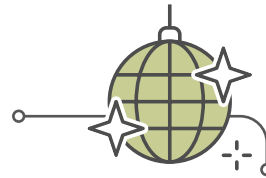
### ENDURING

Leave the meeting and rejoin at any time, when convenient for you. Bonus: view recordings of what you missed for up to 30 days!



### AFFORDABLE

We invite you to **pay what you can afford!** We appreciate your contributions, because that is how we advance ISAKOS' mission.



### FUN

With friendly-faced, live hosts, innovative virtual experiences, and networking receptions, you will remember what you love most about ISAKOS—the networking and fun!

Don't miss the opportunity to be a part of this one-of-a-kind meeting. This is the same ISAKOS Congress you know and love, revamped to meet you where you are! **#ISAKOS2021**

**REGISTER TODAY**  
at [isakos.com/2021](https://isakos.com/2021)

# Travel the World with



ISAKOS  
CONGRESS  
2021

GLOBAL  
Nov 27 - 28

Coming to you live from *ISAKOS 2021: Global* studios around the world! Your hosts—the ISAKOS Presidential line and Program Chairs—will engage with world-renowned experts, moderate panel discussions and surgical demos, monitor live chat, and address audience questions, engaging you every step of the way. It's the same ISAKOS Congress you know and love, revamped to meet you where you are!

In the time it would have taken you to fly to Cape Town, you can now sit back, relax, and enjoy *ISAKOS 2021: Global* content on any device—from home, the office, or even a locker room! You choose your participation—join the 4-hour time block that best fits your time zone up to the full 16 hours of live-hosted, *ISAKOS 2021: Global* content, or anything in between.



**Marc R. Safran, MD**  
ISAKOS Past President

- Past President Welcome
- ISAKOS Nominating Update
- Introduction of the ISAKOS 2nd Vice President
- Announcement of New Board of Directors, Members at Large



**David A. Parker, MBBS,  
BMedSc, FRACS**  
ISAKOS 2nd Vice President

- Welcome from 2023–2025 ISAKOS President
- 14th Biennial ISAKOS Congress in Boston, USA in 2023: Preview
- Announcement of 2025 Program Chair
- Thank You for Joining Us!



**Bonus:**  
Access tons of  
On Demand  
content for up to  
**30** days!



**Guillermo R. Arce, MD**  
ISAKOS First  
Vice President

- Passing of the ISAKOS Presidential Medallion
- Welcome from 2021–2023 ISAKOS President
- ISAKOS Award Ceremony
- *Journal of ISAKOS Awards & Highlights*



**Willem M. van der  
Merwe, MBChB,  
FCS(SA)Ortho**  
ISAKOS President  
2019–2021

#### Live Cape Town Program Highlights:

- Presidential Welcome & Opening of *ISAKOS 2021: Global*
- Announcement of 2021 Honorary Members
- Presidential Guest Lecture: ACL Career Highlights, Freddie H. Fu, MD USA
- ISAKOS 25th Anniversary: The Road to Create ISAKOS
- Surprise Presidential Guest Speaker!

# ISAKOS 2021: GLOBAL - LIVE PROGRAM\*

SATURDAY, NOVEMBER 27



## LIVE CAPE TOWN PROGRAM

15:00 – 15:20

### OPENING SESSION

15:00– 15:05

**Welcome by 2019–2021 President**

Willem M. van der Merwe, MBChB, FCS(SA)Ortho SOUTH AFRICA

**ISAKOS President 2019–2021**



15:05– 15:10

**2021 Program Chair Remarks**

Volker Musahl, MD UNITED STATES  
ISAKOS 2021: *Global Congress* Program Chair



15:10– 15:20

**Announcement of Honorary Members**

Willem M. van der Merwe, MBChB, FCS(SA) Ortho SOUTH AFRICA

**ISAKOS President 2019–2021**

15:20 – 18:40

### SCIENTIFIC SESSIONS

15:20– 15:40

**Lecture: Presidential Guest Lecture: ACL Career Highlights**

Freddie H. Fu, MD UNITED STATES



15:40– 16:10

**Special Event: ISAKOS 25th Anniversary: The Road to Create ISAKOS 25 Years Ago**

**Co-Chair:** Per A. Renström, MD, PhD SWEDEN

**Co-Chair:** Barry R. Tietjens, FRACS NEW ZEALAND

David James Dandy, MD, FRCS UNITED KINGDOM

Peter J. Fowler, MD, FRCSC CANADA

Roland P. Jakob, Professor Emeritus SWITZERLAND

Gary G. Poehling, MD UNITED STATES



16:10– 16:40

**Symposium: The Multiligament Knee: When, How, What?**

**Co-Chair:** James J. Irrgang, PT, PhD, FAPTA UNITED STATES

**Co-Chair:** Bryson P. Lesniak, MD UNITED STATES

Mario Ferretti, MD, PhD BRAZIL

Yasuyuki Ishibashi, MD JAPAN

Jacques Ménétrey, Prof. SWITZERLAND

Laura C. Schmitt, PT, PhD UNITED STATES

16:40– 16:55

**Surgical Demonstration:**

To Be Determined

16:55– 17:25

**Global Case-based Discussion Session: What Works Best For the Athlete: Meniscus Repair or Resection?**

**Co-Chair:** Peter Verdonk, MD, PhD BELGIUM

**Co-Chair:** Andy Williams, MBBS, FRCS(Orth), FFSEM(UK) UNITED KINGDOM

Charles H. Brown, Jr., MD

UNITED ARAB EMIRATES

Magnus Forssblad, MD, PhD SWEDEN

Alberto Gobbi, MD ITALY

Rainer Siebold, MD, Prof. GERMANY

17:25– 17:55

**Symposium: Is the Lateral-Extra Articular Really Needed?**

**Co-Chair:** Pieter J. Erasmus, MBChB, MMed, FCS(Orth) SOUTH AFRICA

**Co-Chair:** Jon Karlsson, Prof. SWEDEN

Andrew A. Amis, PhD, FREng, DSc UNITED KINGDOM

Alan Getgood, MD, FRCS(Tr&Orth),

DipSEM CANADA

Yuichi Hoshino, MD, PhD JAPAN

Bertrand Sonnery-Cottet, MD FRANCE

17:55– 18:10

**Surgical Demonstration:**

To Be Determined

18:10– 18:40

**Symposium: How to Repair the Meniscus in a Difficult Situation**

**Co-Chair:** Joan C. Monllau, MD, PhD, Prof. SPAIN

**Co-Chair:** Rene E. Verdonk, Professor Emeritus, MD, PhD BELGIUM

Felipe E. Cámara, MD MEXICO

Christopher D. Harner, MD,

FAOA UNITED STATES

Nicolas Pujol, MD FRANCE

Romain Seil, MD, Prof. LUXEMBOURG

18:40 – 19:10

### CLOSING SESSION

**Special Event: Presidential Guest Speaker**



## SATURDAY, NOVEMBER 27



## LIVE BUENOS AIRES PROGRAM

19:10 – 19:40

## OPENING SESSION

19:10–19:15

**Passing of the ISAKOS  
Presidential Medallion**

Guillermo R. Arce, MD ARGENTINA  
**ISAKOS President 2021–2023**  
 Willem M. van der Merwe, MBChB, FCS(SA)  
 Ortho SOUTH AFRICA  
**ISAKOS President 2019–2021**

19:15 – 19:20

**Welcome by 2021–2023  
President**

Guillermo R. Arce, MD  
 ARGENTINA

**ISAKOS President  
2021–2023**

19:20–19:35

**Award Ceremony**

19:35 – 19:40

**Journal of ISAKOS Awards & Highlights**

C. Niek van Dijk, MD,  
 PhD NETHERLANDS

JOURNAL OF  
**ISAKOS**  
Joint Disorders & Orthopaedic Sports Medicine

19:40 – 22:40

## SCIENTIFIC SESSIONS

19:40–20:10

**Symposium: Osteotomies Around  
the Knee**

**Co-Chair:** Elizabeth A. Arendt, MD  
 UNITED STATES  
**Co-Chair:** Karl Eriksson, MD, PhD,  
 Asst. Prof. SWEDEN  
 David H. Dejour, MD FRANCE  
 Lars Engebretsen, MD, PhD NORWAY  
 Tim Spalding, FRCS(Orth)  
 UNITED KINGDOM  
 Stefano Zaffagnini, MD, Prof. ITALY

20:10–20:40

**Symposium: Meet The Experts:  
Gender & Diversity**

**Co-Chair:** Laurie A. Hiemstra, MD, PhD,  
 FRCSC CANADA  
**Co-Chair:** Jason L. Koh, MD, MBA  
 UNITED STATES  
 Camila Cohen Kaleka, PhD BRAZIL  
 Magaly Iñiguez, MD CHILE  
 Elizaveta Kon, Prof., MD ITALY  
 Mary K. Mulcahey, MD UNITED STATES

20:40–21:10

**Symposium: Shoulder the Failed Rotator  
Cuff: Revision Repair**

**Co-Chair:** Augustus D. Mazzocca, MS, MD  
 UNITED STATES  
**Co-Chair:** Manuel F. Mosquera Arango, MD  
 COLOMBIA  
 Emilio Calvo, MD, PhD, MBA SPAIN  
 Benno Eijnisman, MD BRAZIL  
 Albert Lin, MD UNITED STATES  
 Geoffroy Nourissat, MD, PhD FRANCE

21:10–21:25

**Surgical Demonstration:**

To Be Determined

21:25–21:55

**Symposium: Quad Tendon ACL: Where We  
Are Now**

**Co-Chair:** Masahiro Kurosaka, MD JAPAN  
**Co-Chair:** Daniel A. Slullitel, MD,  
 Prof. ARGENTINA  
 Julian A. Feller, FRACS AUSTRALIA  
 Christian Fink, MD, Prof. AUSTRIA  
 Daniel C. Wascher, MD UNITED STATES  
 John Xerogeanes, MD UNITED STATES

21:55–22:25

**Symposium: ISAKOS & Patellofemoral  
Foundation Highlights of Current Research  
from 2018–2021**

**Co-Chair:** João Espregueira-Mendes, MD, PhD  
 PORTUGAL  
**Co-Chair:** John P. Fulkerson, MD  
 UNITED STATES  
 Alessandra Berton, MD ITALY  
 Andrew J. Cosgarea, MD UNITED STATES  
 Ryosuke Kuroda, MD, PhD JAPAN  
 Vicente Sanchis-Alfonso, MD, PhD SPAIN

22:25–22:40

**Surgical Demonstration:**

To Be Determined

22:40 – 23:00

## CLOSING SESSION

22:40–22:55

**Special Event: Incoming 2021–2023  
President Message**

Guillermo R. Arce, MD ARGENTINA

22:55–23:00

**Special Event: Closing Remarks from  
Buenos Aires & Torch Passing to San  
Francisco**

Guillermo R. Arce, MD ARGENTINA

Times are listed in UTC.

\*Invited Faculty. Program and Faculty Subject to Change.

Visit [isakos.com/2021](https://isakos.com/2021) for additional and  
 up to date program information

## SATURDAY, NOVEMBER 27



## LIVE SAN FRANCISCO PROGRAM

23:00 – 23:20

## OPENING SESSION

23:00–23:05

**Welcome by Past President 2017–2019**Marc R. Safran, MD,  
Prof. UNITED STATES**ISAKOS President 2017–2019**

23:05 – 23:10

**Nominating Update**

Marc R. Safran, MD, Prof. UNITED STATES

**ISAKOS President 2017–2019**

23:10–23:20

**Introduction of ISAKOS 2nd Vice President 2021–2023**

23:20 – 23:55

## SCIENTIFIC SESSIONS

23:20–23:40

**Global Case-based Discussion Session: Working Through COVID-19****Co-Chair:** Theresa Diermeier, MD GERMANY**Co-Chair:** Maria Tuca, MD CHILE

William N Levine, MD UNITED STATES

Gian Andrea Lucidi, MD ITALY

Norimasa Nakamura, MD, PhD JAPAN

Andrew D. Pearle, MD UNITED STATES

23:40–23:55

**Surgical Demonstration:**

To Be Determined

## SUNDAY, NOVEMBER 28



## LIVE SAN FRANCISCO PROGRAM

00:00 – 02:45

## SCIENTIFIC SESSIONS

00:00–00:30

**Symposium: Hip Instability****Co-Chair:** Leandro Ejnisman, MD,  
PhD BRAZIL**Co-Chair:** Marc R. Safran, MD, Prof. UNITED STATES

Nicolas Bonin, MD FRANCE

Michael McClincy, MD UNITED STATES

Ehud Rath, Prof. ISRAEL

Soshi Uchida, MD, PhD JAPAN

00:30 – 01:00

**Symposium: Meet The Experts: Shoulder Instability****Co-Chair:** Leesa M. Galatz,  
MD UNITED STATES**Co-Chair:** Andreas B. Imhoff, MD,  
Prof. GERMANYPaulo J. Llinas Hernandez, MD,  
Prof. COLOMBIA

Eric C. McCarty, MD UNITED STATES

Nahum Rosenberg, MD, FRCS, Prof. ISRAEL

Ivan Wong, MD, FRCSC, MACM, Dip. Sports  
Med CANADA

01:00–01:30

**Symposium: Failed Cartilage Surgery: What To Do Next?****Co-Chair:** William Bugbee,  
MD UNITED STATES**Co-Chair:** Rocky S. Tuan,  
PhD HONG KONG

David H. Figueroa, MD, Prof. CHILE

John G. Lane, MD UNITED STATES

Rodrigo Maestu, MD ARGENTINA

Seth L. Sherman, MD UNITED STATES

01:30–01:45

**Surgical Demonstration:**

To Be Determined

01:45–02:15

**Symposium: What Is New In ACL Reconstruction?****Co-Chair:** John A. Bergfeld,  
MD UNITED STATES**Co-Chair:** Constance R. Chu,  
MD UNITED STATES

Moises Cohen, MD, PhD, Prof. BRAZIL

Christopher C. Kaeding, MD UNITED STATES

Timothy Lording, MBBS, FRACS AUSTRALIA

Robert A Magnussen, MD, MPH  
UNITED STATES

02:15–02:45

**Symposium: When to Fix Syndesmosis Ankle Injuries****Co-Chair:** Gian Luigi Canata, MD ITALY**Co-Chair:** Kenneth J. Hunt,  
MD UNITED STATES

Pieter D'Hooghe, MD PhD QATAR

MaCalus V. Hogan, MD,  
MBA UNITED STATESNicola Maffulli, MD, PhD, MS, FRCS(Orth)  
UNITED KINGDOM

Mihkel Mardna, MD ESTONIA

02:45 – 02:55

## CLOSING SESSION

02:45–02:50

**Special Event: Announcement of New At Large Members of Board of Directors**

Marc R. Safran, MD, Prof. UNITED STATES

02:50 – 02:55

**Special Event: Closing Remarks from San Francisco & Torch Passing to Sydney**

Marc R. Safran, MD, Prof. UNITED STATES

## SUNDAY, NOVEMBER 28



## LIVE SYDNEY PROGRAM

02:55 – 03:05

## OPENING SESSION

02:55–03:00

**Welcome by 2023–2025 President and Announcement of 2025 Program Chair**

David A. Parker, MBBS, BMedSc, FRACS AUSTRALIA



03:00–03:05

**ISAKOS Congress 2023 in Boston: A Preview**

Mark G. Clatworthy, FRACS NEW ZEALAND



03:05 – 07:00

## SCIENTIFIC SESSIONS

03:05–03:35

**Symposium: Hip Labral Reconstruction: Who Needs It and What Are the Options?****Co-Chair:** Matthew J. Brick, MBChB, FRACS NEW ZEALAND**Co-Chair:** Joshua D. Harris, MD UNITED STATES

Olufemi R. Ayeni, MD, PhD, MSc, FRCS CANADA

Jiwu Chen, MD, PhD CHINA

Thierry Pauyo, MD, FRCS CANADA

Marc J. Philippon, MD UNITED STATES

03:35–04:00

**Symposium: Mental Aspects of Injury and Recovery****Co-Chair:** Francesco Della Villa, MD ITALY**Co-Chair:** Sachin R. Tapasvi, MBBS, MS, DNB, FRCS INDIA

Sebastián Irrázaval, MD CHILE

Philippe Landreau, MD

UNITED ARAB EMIRATES

Andrew Sprague, PT, DPT UNITED STATES

Kate E. Webster, PhD AUSTRALIA

04:00–04:30

**Symposium: Management of Revision ACL****Co-Chair:** Nobuo Adachi, MD, PhD JAPAN**Co-Chair:** Shiyi Chen, MD, PhD, Prof. CHINA

Fabrizio Margheritini, MD ITALY

Robert G. Marx, MD, MSc,

FRCS CANADA

Kristian Samuelsson, Prof, MD, PhD,

MSc SWEDEN

Jong-Keun Seon, MD, PhD, Prof KOREA,

REPUBLIC OF

04:30–04:45

**Surgical Demonstration:**

To Be Determined

04:45–05:15

**Symposium: Alignment in Total Knee Arthroplasty****Co-Chair:** Mark G. Clatworthy, FRACS NEW ZEALAND**Co-Chair:** Patrick S. H. Yung, FRCS(Orth), FHKCOS, FHKAM, FRCS, MBChB HONG KONG

Roland Becker, MD, PhD, Prof. GERMANY

Nicolaas C. Budhiparama, MD, PhD, FICS,

Assoc. Prof. INDONESIA

Sebastien Lustig, MD, PhD, Prof. FRANCE

Parag K. Sancheti, FRCS (Ed), MS(ORTH),

DNB(ORTH), MCh(UK), Ph.D(UK) INDIA

05:15–05:45

**Symposium: Basic Wrist: What a Sports Surgeon Should Know About the Wrist****Co-Chair:** Margaret W. M. Fok, FRCSEd(Ortho), MBChB HONG KONG**Co-Chair:** Bo Liu, MD, FRCS CHINA

Gregory I. Bain, MBBS, FRACS, PhD AUSTRALIA

Deepak N. Bhatia, MS(Orth), DNB(Orth) INDIA

Benjamin R. Graves, MD UNITED STATES

Gregory A. Hoy, FRACS, FAOrthA, FACSP,

FASMF AUSTRALIA

05:45–06:15

**Symposium: The Stiff Shouldert****Co-Chair:** Giovanni Di Giacomo, MD ITALY**Co-Chair:** Eiji Itoi, MD, PhD JAPAN

Knut Beitzel, MD, MA GERMANY

Michael T. Freehill, MD, FAOA, FAAOS

UNITED STATES

Giuseppe Milano, MD ITALY

Masahito Yoshida, MD, PhD JAPAN

06:15–06:30

**Surgical Demonstration:**

To Be Determined

06:30–07:00

**Symposium: Osteotomy and Knee Arthroplasty****Co-Chair:** Myles R. J. Coolican, FRACS AUSTRALIA**Co-Chair:** Philippe Noel Neyret, MD, Prof. FRANCE

Annunziato Amendola, MD UNITED STATES

Michael T. Hirschmann, MD, Prof.

SWITZERLAND

Sam Oussedik, FRCS UNITED KINGDOM

Andrew James Price, DPhil, FRCS(Orth) UNITED

KINGDOM

07:00 – 07:05

## CLOSING SESSION

**Special Event: Congress Closing: Thank You For Joining Us**

David A. Parker, MBBS, BMedSc, FRACS AUSTRALIA

Times are listed in UTC.

\*Invited Faculty. Program and Faculty Subject to Change.



ISAKOS GLOBAL CONNECTION

*Education, Research and Collaboration*

Thanks Our Industry  
Partners for Their  
Educational Grant Support

**Smith+Nephew**



To learn more or to make a donation, visit [isakos.com/GlobalConnection](http://isakos.com/GlobalConnection)

# Godfathers & Godmothers

The ISAKOS Godfather Initiative was created to provide high-quality, educational programs and resources to deserving individuals worldwide. If an individual donates \$5,000 or more to Global Connection and designates this money to the Godfather Initiative, a portion of that donation will be allocated toward an ISAKOS membership scholarship for individuals 45 years of age or under.

## ISAKOS Gratefully Acknowledges Our Renewing Godfather



Ramon Cugat Bertomeu,  
MD, PhD, SPAIN

[isakos.com/godfathers](https://isakos.com/godfathers)

## ISAKOS gratefully acknowledges the generous support of our Annual Fund donors\*

Annual Fund support ensures that the Society is able to fund and implement education and research initiatives created to support the needs of our membership worldwide. Gifts to the Annual Fund make an instant impact on the Society's ability to carry out our mission, help us plan for the future of the Society and ensure that ISAKOS strategic initiatives become a reality.

**Anita Boecksteiner, FRACS (Ortho) MBBS, AUSTRALIA**

**Amaury Canate, MD, MEXICO**

**Gregory Difelice, MD, UNITED STATES**

**Jose Figueroa, MD, CHILE**

**Jose Prospero Hernandez De La Fuente, MD, MEXICO**

**Freddie H. Fu, MD, UNITED STATES**

**Thomas P. San Giovanni, MD, UNITED STATES**

\*February 15–August 15, 2021



**ISAKOS**  
International Society of Arthroscopy,  
Knee Surgery and Orthopaedic Sports Medicine

In memory of their outstanding achievements and contributions to ISAKOS and the field of Orthopaedics.



**Kenneth E. DeHaven, MD USA 1939–2021**

Kenneth E. DeHaven, M.D., an orthopaedic surgeon renowned for revolutionizing the use of arthroscopy in the United States, died June 20 in Westminster, Colorado. He was Professor of Orthopaedics until his retirement in 2012, when he was appointed Professor Emeritus. Beginning in the early 1970s, DeHaven, a lifelong athlete, began using minimally invasive, arthroscopic surgery to diagnose and repair knee injuries in athletes. **“It’s not an overstatement to say his contributions to Sports Medicine and Arthroscopy are immeasurable,”** said Mike Maloney, M.D., Chief of Sports Medicine, who chose the University of Rochester for his residency training for the opportunity to learn from DeHaven. “His discoveries demonstrated we could perform meniscus repair and his efforts to develop and refine arthroscopic surgical techniques have saved many thousands of patients from needing a total knee joint replacement later in life.” DeHaven’s personal example as a clinician, teacher and role model should be noted along with his many contributions to orthopaedic medicine leadership. He was one of the pioneers of

sports medicine and arthroscopy, and despite being a giant in the field, he was a humble and gracious man. He was always very patient, always willing to spend the extra time explaining things to young athletes and their families. And for faculty and trainees, he was an impactful role model, a kind man, a genuine friend and mentor. He had such a positive impact on literally everyone he encountered. He made you feel valued and inspired and to have his friendship and respect was a tremendous gift. A testament to his incredible commitment and leadership skills, DeHaven is the only person to serve as a past president of the American Orthopaedic Society for Sports Medicine, the Arthroscopy Association of North America, the International Society of the Knee (a parent society to ISAKOS) and the American Academy of Orthopaedic Surgeons. He is survived by his wife, Jean, and daughter Kathleen. DeHaven is predeceased by his son, David.

**Michael D. Maloney, MD**

*University of Rochester Medical Center*



**Dr. Pravinchandra Harkishandas Vora, MD INDIA, MS. FRCS 1934–2021**

The late Dr. Pravinchandra Harkishandas Vora (MS. FRCS) was the founder, member, and first secretary of the Indian Arthroscopy Society (IAS) formed in 1983. It was 1977-1978 that the idea of bringing Arthroscopy was entertained, and to continue this passion, Dr. Vora, along with others, organized the first Arthroscopy Educational Meeting in Mumbai in 1983. Faculty from all over the globe were invited such as Drs. Dinesh Patel (USA), Stuart Springer (USA), E. Ericson (Sweden), Robert Jackson (Canada), and Witwitty (Germany) to name a few, to introduce the world of Arthroscopy to India. Dr. Vora became the President of the Society from 1987-99. During his tenure, the Indian Orthopaedic Association (IOA) recognized arthroscopy as a superspeciality, and the IAS, a subchapter of the IOA. Dr. Vora was instrumental in arranging many workshops and conferences, to train young Orthopaedic surgeons and spread Arthroscopic education in India.

Dr. Vora was the professor of Orthopaedic surgery at Sir J.J. group of Hospitals and Grant Medical College, and the Children’s Orthopaedic Hospital, Mumbai as he had great interest in CTEV and Polio. Dr. Vora was the President of the Bombay Orthopaedic Society in 2001-02.

A great thinker and visionary, Dr. Vora would often think laterally and out of the box as he guided the path of Arthroscopy in India. His motto was “never give up”. He passed away after a brief illness on April 26, 2021. He is survived by his wife Mrs. Urmilaben Vora and son Dr. Vaghmin Vora (USA).

**His contribution to Arthroscopy in India will always be remembered.**

**Dr. Nicolas Antao  
Dr. Dinesh Patel**



## Daniel Fritschy, MD SWITZERLAND 1947–2021

With profound sadness we announce the passing of Prof. Daniel Fritschy. He unexpectedly died on August 2, 2021 while vacationing in Sweden. He was 74 years of age.

Daniel Fritschy was born on May 12, 1947 in St. Imier, a town located in the Swiss Jura valley of Tavannes. Enthused by sports at an early age, especially soccer, he naturally focused on the musculoskeletal system. After medical school in Geneva, he embraced orthopaedics. Daniel accomplished his training at the University Hospital of Geneva, obtained a doctorate in 1977 and completed two fellowships, the first in 1978 in Paris, at the Cochin and Trousseau Hospitals, and the second in 1990, in San Diego with Dale Daniel at the Kaiser Permanente. This was a sports medicine research fellowship awarded to Daniel by the Swiss Society of Orthopaedics. He joined the staff in Geneva in 1985, obtained a Privat-Dozent in 1990 and began his 23-year career as a faculty member of the Department of Surgery of the University Hospital of Geneva where he rose to the rank of Associate Professor in 1999.

Starting from a general training in orthopaedic and trauma surgery including a year in neurosurgery, he belonged to the first generation of surgeons who specialized in knee surgery. During his academic career, he wrote and co-signed numerous book chapters and scientific articles. He notably co-edited a real bestseller entitled: “Traumatologie de l’appareil moteur: Stratégie pour le médecin de premier recours” awarded the Swiss Orthopaedic Society’s Debrunner prize. His research efforts focused on tendinopathy, meniscal repair, tissue healing, ACL injury, and later on TKA. He has also served on editorial boards of many journals (KSSTA, OTSR) and was currently an Associate Editor of EFORT Open Reviews. Daniel Fritschy was amongst the pioneers of sports medicine in this part of the world. He was notably a precursor and a great proponent of non-operative functional treatment which he successfully applied to tibial fractures of skiers and to the management of ankle sprains. A pioneer of operative arthroscopic surgery in Western Switzerland, Daniel excelled in the field where he was a renowned and sought-after master. Being a superb surgeon, he described a surgical technique for the treatment of patellar insertional tendinopathy that we still use today. Appalled by the results of closed wedge high tibial osteotomy, he introduced the open wedge technique to our area. He was also one of the developers of a contemporary knee prosthesis. Daniel was also amongst the first to recognize the importance of early rehabilitation after surgery.

Prof. Fritschy was a fantastic and entertaining teacher thereby initiating hundreds of seminars, symposia, meetings, specialty days, sports medicine weeks (FARD), and he was the co-founder of the Geneva knee arthroscopy course that has recently celebrated its 27th edition. Later in his career, he participated in humanitarian missions in Africa, where **his talent did wonders.**

Curious in nature, he travelled the world to share ideas and to be inspired by his visits and interactions. It allowed him to constantly implement cutting edge techniques always with a critical mind. In this part of the world, he has been one of the first, if not the first, orthopaedic surgeon to embrace a career of sports medicine doctor on field, and served for years as medical director for the Swiss Alpine Ski team, team physician of the Swiss Winter Olympic delegation in Nagano, and the Genève Servette Hockey Club. He attended four Olympic Games as physician caring for his national athletes, including Nagano, Lillehammer, Albertville, and Calgary. His enthusiastic devotion has led to a dynasty of sports medicine surgeons and physicians taking care of sports at home and abroad.

His passion for music, art, and nature developed early in life and was a constant source of enlightenment and intense interest. He showed us how important it was to have the mind nourished by something different than our overwhelming specialty. Besides being generous, joyful, luminous and humble, he was endowed with a genuine sense of humor and a charismatic personality. This was a constant inspiration to his colleagues, a role model for his students, interns, and fellows, and a source of comfort for his patients. Beyond being a talented and experienced surgeon and researcher, a highly appreciated teacher and a dedicated mentor, Prof. Fritschy was a humanist gentleman demonstrating exemplary openness, unlimited generosity, and elegance of the intelligence.

Daniel’s passing is a great loss for the ISAKOS family, and we send our sincere condolences to his wife Marika, to his children Géraldine, Pernelle, Justine, Margaux, and Joachim, as well as to his eleven grand-children and family.












# ISAKOS

## PUBLICATIONS

Free Access  
for ISAKOS Members

[isakos.com/myISAKOS/myPublications](http://isakos.com/myISAKOS/myPublications)











[isakos.com/books](http://isakos.com/books)



# COMING IN 2021

## 10+ New ISAKOS Books!



## Meniscal Transplantation, Technical Innovations, and Return To Sports



Gonzalo Samitier, MD, PhD  
Centro Quironsalud Aribau  
Barcelona, SPAIN



Gustavo Vinagre, MD, PhD  
Porto, PORTUGAL

### Introduction

Meniscal deficiency can compromise the future function of the knee by leading to premature, progressive osteoarthritis. Numerous studies have elucidated the importance of meniscal retention, repair, or replacement (with use of a meniscal scaffold or meniscal allograft transplantation [MAT]) to maintain knee joint homeostasis.

In general, the ideal candidate for meniscal transplantation is a young, symptomatic patient who has had a previous total or subtotal meniscectomy (i.e., post-meniscectomy syndrome). However, additional information should be evaluated before considering such a complicated surgical procedure (Table 1). As complementary examinations, we recommend weight-bearing anteroposterior (AP) and lateral radiographs, a posteroanterior (PA) radiograph with 45° of knee flexion, a standing long-leg radiograph, and magnetic resonance imaging (MRI) of the knee. It is also crucial to balance the intermediate and long-term risks and benefits and the patient's future expectations.

TABLE I. Indications and relative contraindications for meniscal transplantation.

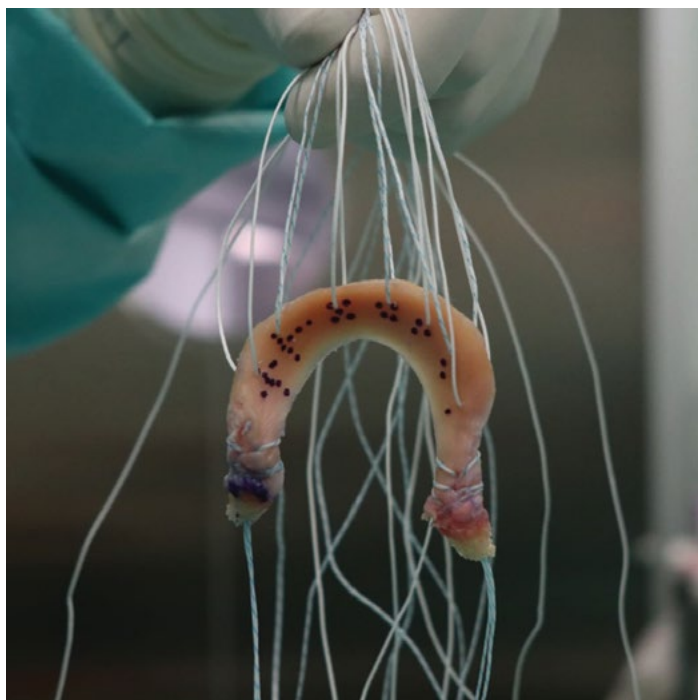
Indications	Relative Contraindications
<ul style="list-style-type: none"> <li>• Age &lt;40 years</li> <li>• Isolated unilateral limiting femorotibial knee pain (lateral or medial)</li> <li>• Previous subtotal, total, or functionally equivalent meniscectomy</li> <li>• Absence of radiographic evidence of advanced joint arthritis</li> <li>• Neutral alignment</li> <li>• Stable knee</li> </ul>	<ul style="list-style-type: none"> <li>• Chronic degenerative diffuse changes or advanced osteoarthritis</li> <li>• Axial malalignment (genu varus/valgus)</li> <li>• Open physis (skeletal immaturity)</li> <li>• Unstable knee</li> <li>• High-grade focal chondral or osteochondral defects</li> <li>• Obesity (BMI &gt;30) and smoking</li> <li>• Systemic or local infection</li> <li>• Autoimmune diseases of inflammatory arthritis</li> <li>• Knee arthrofibrosis</li> <li>• Synovial disorder</li> </ul>

The best time for the surgery seems to be as soon as the patient is having symptoms and has a decreased level of activity; the degree of cartilage wear at the time of the meniscal transplantation is the most critical variable predicting outcome. Unfortunately, candidates for MAT are often managed operatively several years (average, 13.8 years) after the initial injury and already have focal chondral lesions or some degree of diffuse cartilage degeneration, or even malalignment, at the time of MAT. In pediatric patients with post-meniscectomy syndrome, especially in the lateral compartment, early referral for MAT is justified.

### MAT Technique

Several MAT techniques (open, mini-open, or arthroscopic, with or without bone plugs) for the restoration of normal knee kinematics have been described in the literature; our group recently shared several innovations for the performance of all-arthroscopic MAT with bone plugs and preloaded sutures.<sup>1</sup>

In terms of graft sizing, matching patient height, weight, and gender are reliable methods to predict proper meniscal allograft dimensions. Fresh-frozen allografts are the most common grafts used. The allograft is prepared on the back table by trimming the meniscal root bone plugs to a truncated cone shape of 7.0 to 8.0 mm in diameter (Figure 1). Next, a number-2 high-strength looped suture is passed through a central hole of the bone blocks facilitating direct pulling; also 6 are to be placed throughout the meniscal circumference that will fix the graft to the meniscal remnant. Alternation of thread colors is recommended to facilitate sequential suture identification intraoperatively.

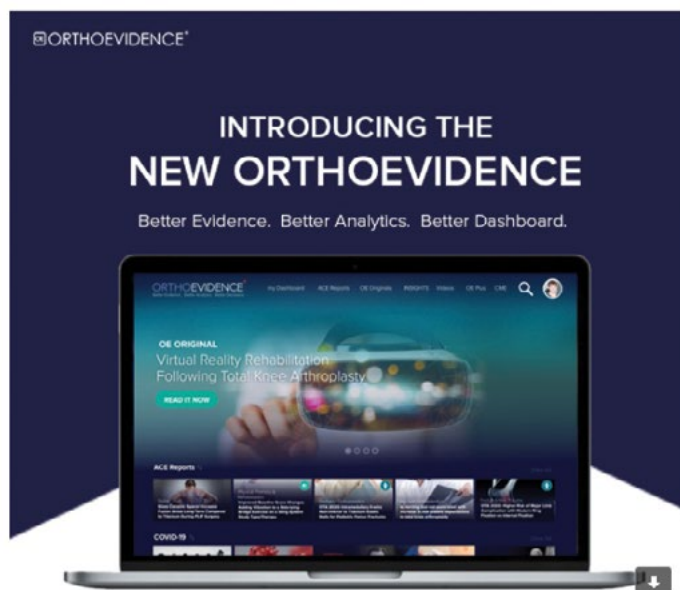


01 Meniscal allograft with bone plugs and preloaded vertical sutures.

After graft preparation, diagnostic arthroscopy is performed; a combination of meniscal biters and shavers is used to promote appropriate bleeding and to debride the remaining meniscal tissue, leaving a stable rim measuring 1 to 2 mm wide. The bone tunnel for the posterior root attachment is created by means of retrograde drilling with use of an ACL/meniscal root tibial guide inserted through the ipsilateral portal; a number-1 PDS suture is left inside the tibial tunnel for later shuttling.

Before the meniscal graft is inserted into the knee, 2 of the preloaded sutures at the posterior horn are passed through the posterior meniscal rim from bottom to top with use of a shoulder-type suture-passer device; this is an important innovation that places perfect vertical sutures in the posterior horn, reducing the need for all-inside meniscal sutures. Next, 2 spinal needles are passed outside-in vertically in the posteromedial (on the Medial Meniscus) or posterolateral (on the Lateral Meniscus) corner of the meniscal rim with use of 2 number-1 PDS sutures to shuttle the preloaded suture of the posterior meniscal angle. The meniscal allograft transplant is directed inside the knee through an ipsilateral enlarged portal by pulling from the sutures in the posterior root and the corner. Once the meniscal allograft is adequately balanced inside the knee, the 2 posterior horn meniscal sutures are tied down with use of a knot pusher, which provides the initial graft stability in the posterior aspect of the meniscus.

A piercing suture retriever is then used to collect all the preloaded meniscal sutures from the meniscal body and anterior horn (Figure 2).



#### A New Look

Easily navigate our new dashboard and stay up to date on the latest high quality evidence with new content being added to the dashboard daily.



#### Trending

See what evidence is trending on OrthoEvidence in real-time. The new dashboard allows you to stay up-to-date to with what others are reading.



#### Interactive Dashboard

You can now customize your dashboard by filtering subspecialties, rearrange sections, save reports to read later, and much more!



#### Manage Email Subscriptions

Our new platform allows you to easily manage your email preferences so that you get the evidence you want, directly to your mailbox.

[myorthoevidence.com](https://myorthoevidence.com)

November 10, 2021

Online Meeting Details to Follow  
[isakos.com/myISAKOS](http://isakos.com/myISAKOS)

## ISAKOS Member [VIRTUAL] Business Meeting

### Calling all ISAKOS Active & Honorary Members!

With the transition of the Biennial Congress to the virtual, *ISAKOS 2021: Global*, the in-person Business Meeting will now be held online. Active and Honorary Members\*, registered for *ISAKOS 2021: Global*, will be allowed to provide recommendations.

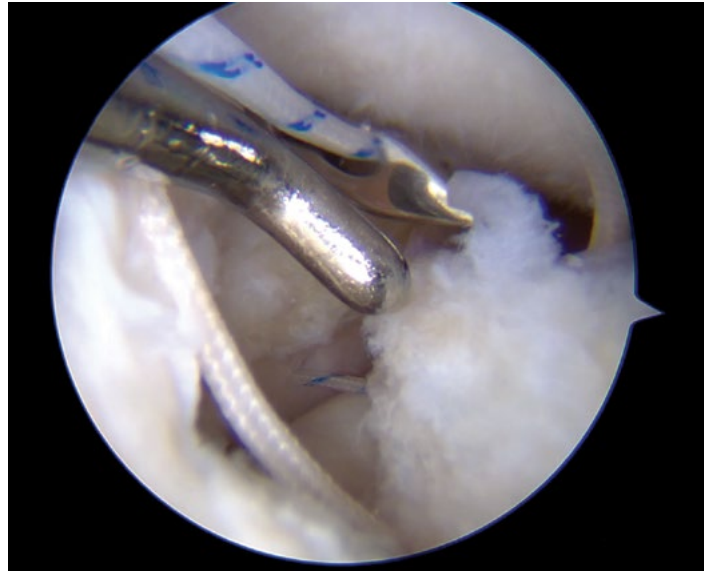
- **Recommendation of Candidates to serve on the ISAKOS Nominating Committee**
- **Recommendation of Candidates to serve as ISAKOS Board of Directors: Members at Large**

#### Online Voting for Nominating Committee & BOD:

Members at Large will be available to ISAKOS Active and Honorary Members from Wednesday, November 10 until Thursday, November 11 (Times TBD).

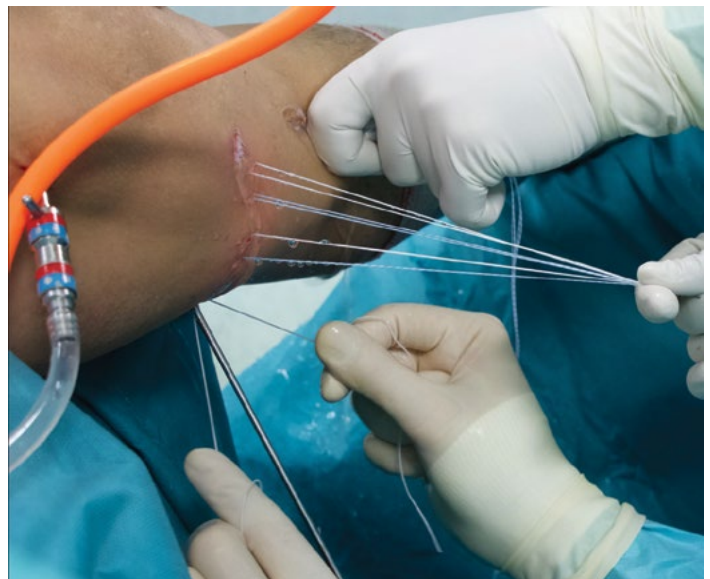\*Only ISAKOS Active (dues current, in good standing) and Honorary members have voting privileges. Must be registered for *ISAKOS 2021: Global* prior to attending the online Business Meeting.

### Meniscal Transplantation, Technical Innovations, and Return To Sports



02 The preloaded meniscal sutures are retrieved sequentially from posterior to anterior with use of a penetrating suture retriever. Visualization is optimized with use of a probe.

The anterior root tunnel is created once the meniscus is inside the knee and well balanced; this sequence allows the surgeon to have a more accurate idea about its precise location. The peripheral stitches are then tied from posterior to anterior (Figure 3); 2 or 3 all-inside meniscal sutures can be used to reinforce the posterior aspect of the meniscus, if needed. The procedure ends with anterior and posterior root fixation. The threads coming from the posterior and anterior meniscal roots can be sutured to each other or fixed separately to the anterior tibia with use of buttons or knotless implants while maintaining the knee at 45° of flexion.



03 Suture tightening is performed from the outside, generally from posterior to anterior, with a knot-pusher.

## Rehabilitation

Postoperatively, a knee brace must be always worn for 4 weeks; knee flexion up to 90° is allowed twice a day for the first 4-6 weeks. Weight-bearing is not recommended for 4 weeks; free activities are allowed 6 months postoperatively. Generally, we advise against high-impact, squatting, or pivoting sports activities for patients who have a meniscal transplant.

## Outcomes

MAT has been reported to reduce symptoms and to improve function and quality of life in the intermediate term (7 to 14 years).<sup>2</sup> LaPrade et al.<sup>3</sup> reported significant pain reduction, decreased activity-related effusion, and functional improvement following MAT. Verdonk et al.<sup>4</sup> reported cumulative survival rates of 74.2% and 69.8% for medial and lateral meniscal allografts, respectively, at 10 years.

## Return to Play

There are minimal data on return to sports following meniscal allograft transplantation (MAT). Hurley et al.<sup>5</sup>, in a systematic review of 67 studies, reported a high rate of return-to-play following MAT (77.4%), with 68.6% of patients returning to the same level at an average of 9 nine months; however, the authors reported significant variability in reported rehabilitation protocols and poor-quality reporting in terms of return-to-play criteria, indicating the need for further research.

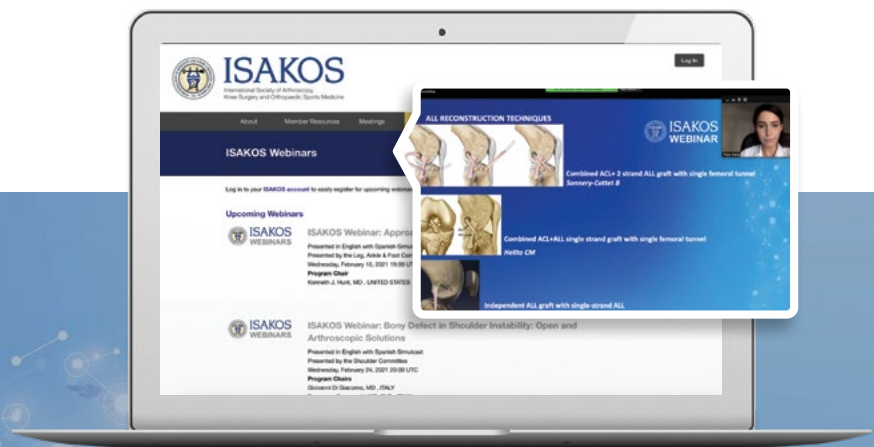
MAT in athletes has been recommended with caution because of concerns for high failure rates and long recovery times. This information should be provided to the patient before the procedure to manage the athlete's expectations regarding postoperative return to play.

## References

1. Samitier G, Vinagre G, Alentorn-Geli E, Sava M, Cugat R. All-Arthroscopic Meniscal Allograft Transplantation Technique with Bone Plugs and Preloaded Sutures. *Arthrosc Tech*. 2020;9(9):e1357-e62.
2. Samitier G, Alentorn-Geli E, Taylor DC, Rill B, Lock T, Moutzouris V, et al. Meniscal allograft transplantation. Part 2: systematic review of transplant timing, outcomes, return to competition, associated procedures, and prevention of osteoarthritis. *Knee Surg Sports Traumatol Arthrosc*. 2015;23(1):323-33.
3. LaPrade RF, Wills NJ, Spiridonov SI, Perkinson S. A prospective outcomes study of meniscal allograft transplantation. *Am J Sports Med*. 2010;38(9):1804-12.
4. Verdonk PC, Demurie A, Almqvist KF, Veys EM, Verbruggen G, Verdonk R. Transplantation of viable meniscal allograft. Survivorship analysis and clinical outcome of one hundred cases. *J Bone Joint Surg Am*. 2005;87(4):715-24.
5. Hurley ET, Davey MS, Jamal MS, Manjunath AK, Kingery MT, Alaia MJ, et al. High rate of return-to-play following meniscal allograft transplantation. *Knee Surg Sports Traumatol Arthrosc*. 2020;28(11):3561-8.



# ISAKOS WEBINARS



## ISAKOS Webinar Collection

Available on Global Link! View the entire collection of webinars presented by the ISAKOS Committees and featuring world-renowned faculty discussing a variety of current trends and techniques.



## Join a LIVE Webinar!

For a schedule of upcoming webinars, visit

[isakos.com/webinars](https://isakos.com/webinars)

## Surgical Resolution Sequence in Multiligamentous Knee Injury: A Case Report



Rodrigo Maestu, MD  
CETEA (Center for the Study  
and Treatment of Joint Diseases)  
Buenos Aires, ARGENTINA



Oscar Leon, MD  
CETEA (Center for the Study  
and Treatment of Joint Diseases)  
Buenos Aires, ARGENTINA



Fernando Hernandez, MD  
CETEA (Center for the Study  
and Treatment of Joint Diseases)  
Buenos Aires, ARGENTINA



Matias Medus, MD  
CETEA (Center for the Study  
and Treatment of Joint Diseases)  
Buenos Aires, ARGENTINA



Pablo Rainaudi, MD  
CETEA (Center for the Study  
and Treatment of Joint Diseases)  
Buenos Aires, ARGENTINA



Diego Miguez, MD  
CETEA (Center for the Study  
and Treatment of Joint Diseases)  
Buenos Aires, ARGENTINA

### Introduction

Multiligamentous knee injuries represent a challenge for surgeons due to the complexity of their management; both misdiagnosis and inadequate treatment can cause great joint damage. According to Richter et al., these injuries represent <0.5% of all joint dislocations and <0.02% of traumatic knee injuries. They most frequently affect males between 10 and 30 years of age and are caused by high-energy trauma in traffic accidents or during sports (skiing, hockey, skating, rugby)<sup>1</sup>. During the initial evaluation following high-energy trauma, it is essential to evaluate the neurovascular status and the tension of the soft tissues because of the risk of compartment syndrome<sup>2</sup>. To evaluate ligament stability, we perform the following comparative maneuvers: Lachman test, drawer test (anteroposterior, posterolateral, and anteromedial), pivot-shift test, shift yawn test (0° and 30°), dial test (30° and 90°), recurvatum test (heel-height test), and reverse pivot-shift test<sup>3</sup>. If these procedures are painful for the patient, we prefer to complete our evaluation with the patient under anesthesia.

As complementary tests, we request comparative stress radiographs in varus with 20° of flexion (with a difference of 2.7 to 4 mm suggesting an isolated lesion of the lateral collateral ligament and a difference of >4 mm indicating an associated grade-III lesion of the posterior cruciate ligament<sup>3</sup>) and in valgus with 20° of flexion (with a difference of 3.2 mm indicating an isolated lesion of the superficial medial collateral ligament and a difference of ≥9.8 mm indicating involvement of the entire posteromedial corner<sup>4</sup>).

We also routinely perform magnetic resonance imaging (MRI) to assess menisci, cartilage, and ligaments. Finally, in cases of suspected associated fractures (tibial plateau, tibial spine, Segond) we request computed tomography. In cases of chronic instability, it is essential to order telerradiography with measurements to consider a corrective osteotomy<sup>4</sup>.

There are 3 commonly used classification systems<sup>4</sup>. The Schenck system assesses instability on the basis of the number of affected ligaments, neurovascular involvement, and bone involvement<sup>5</sup>. The KD-III subtype is the most frequent pattern, representing 57.6% to 80.5% of knee dislocations<sup>5</sup>. In contrast, the Hughston and Fanelli systems only consider posterior and rotational instability of the posterolateral corner<sup>3</sup>.

In cases of Hughston grade-I and -II injuries, good results were reported in association with conservative treatment with the use of an extension brace for 4 to 6 weeks, with progressive unloading and passive flexion-extension mobility exercises for 3 to 4 months<sup>4</sup>. Control with comparative stress radiographs is recommended from the sixth week. Surgical treatment is recommended for grade-III injuries. It is advisable to perform reconstructive surgery (and not isolated repair) after 3 weeks because reconstruction is associated with a better outcome and a lower failure rate<sup>4</sup>.

In the present article, we describe the surgical treatment of a Schenck type-KD-III-L-N multiligamentous lesion.

### Case

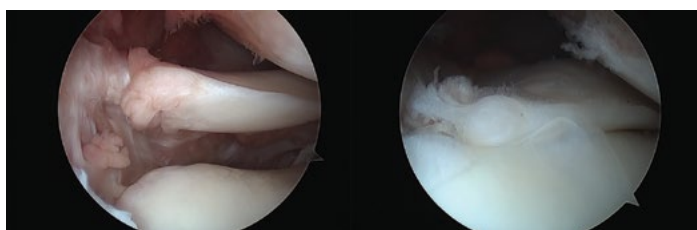
A 19-year-old male patient sustained forced varus trauma while playing rugby, with resulting multiaxial instability and damage to the peroneal nerve that required neurosurgical release, with no neurological sequelae. Four months after the injury, he was assessed by our team. Physical examination revealed the following test results: Lachman (+), anterior and posterior drawer (+++), lateral yawn at 0 and 30 (+++), dial test (+), and Hughston (+). MRI scanning revealed lesions of the anterior cruciate ligament (ACL), posterior cruciate ligament (PCL), posterolateral corner (PLC), and both menisci. A multiligamentous reconstruction with meniscal repair was planned.

### Diagnostic Arthroscopy and Graft Harvesting

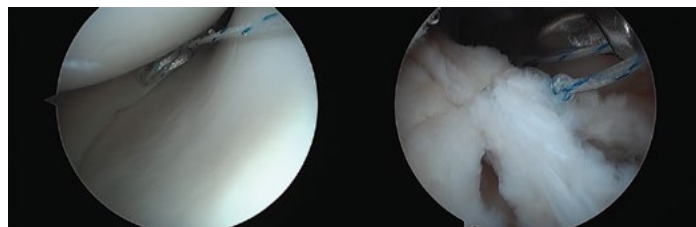
Through conventional portals, a longitudinal injury of the medial meniscus, complete injuries of the ACL and PCL, and a type-2 external meniscal root injury were confirmed. In turn, through the posteromedial portal (PMP), a ramp injury was observed. After inspection of all compartments, a patellar tendon graft was harvested for the anatomical reconstruction of the ACL.

### Meniscal Repair

First, the lateral meniscal root was repaired, with a bone bed made in its anatomical insertion site with a curette. With use of an ACL guide, a pin was placed (while taking into account the tunnels for the remaining ligamentous reconstructions) and a 4.5-mm tunnel was drilled in the tibia. With a suture passer, 2 stitches were made through the posterior horn of the lateral meniscus and were recovered through the tibial tunnel; fixation was performed as the last step in the sequence, at the end of the ligamentous (PCL and ACL) reconstructions (described below), with a cortical fixation with the knee in 20° of flexion. Fig 1 We performed an all-inside suture for a posterior longitudinal medial meniscus lesion. For the treatment of the ramp injury, we entered through the PM portal and 2 vertical stitches were made and were tied with SMC knots with an all-in technique. Fig 2



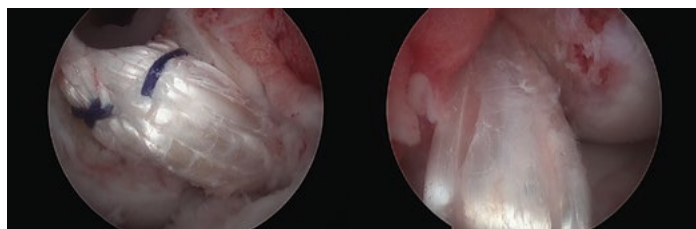
01A A lateral meniscal root lesion. 01B Fixation of the lesion.



02A All-inside suture for a posterior longitudinal medial meniscus lesion. 02B Gillquist view of the ramp suture

### Ligamentous Reconstruction (PCL and ACL)

The PCL and ACL were treated with simple band anatomical reconstruction and fixation with biodegradable interference screws; anterior tibial allograft was used for the PCL, and patellar tendon autograft was used for the ACL. Our preference is to fix the PCL, first proximally and then distally, with reduction of the tibia to an anterior drawer at 90°. Fig 3 We then moved on to proximal fixation of the ACL patellar tendon graft. We left distal fixation to the last moment, following the reconstruction of posterolateral corner (as described below). Fig 4



03 PCL reconstruction. 04 ACL reconstruction.

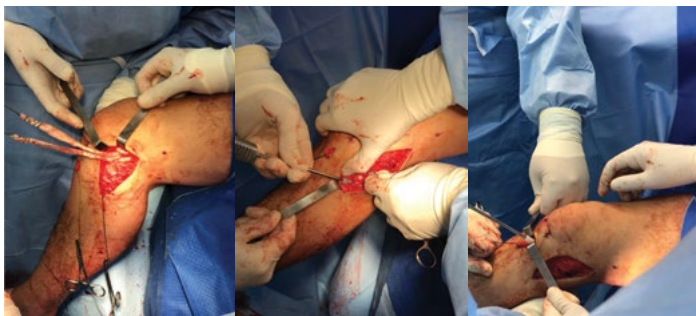### Reconstruction of the Posterolateral Corner

The McLee et al. technique was performed with the use of an Achilles tendon allograft (divided distally into 2 bands of 7 and 8 mm) with a 11 x 20-mm bone plug proximally, fixation was achieved with 3 biodegradable interference screws. The procedure was performed through a lateral hockey stick incision, starting 5 cm proximal to the lateral epicondyle of the femur and extending distally, directed to the midpoint between the head of the fibula and Gerdy's tubercle. The peroneal nerve was identified and repaired, and then 2 windows were made in the iliotibial band (ITB), through which 3 tunnels were made: one in the femur (at the anatomical insertion site of the popliteus muscle, anterior and distal to the lateral epicondyle), one in the tibia (with the tunnel being made with an ACL guide in an anteroposterior direction and slightly obliquely below Gerdy's tubercle toward the desired point at the level of the posterior cortical), and one in the head of the fibula (with a safety zone of up to 2 cm from the tip and with the ACL guide running obliquely in the anteroposterior direction, from bottom to top and from lateral to medial).

## Surgical Resolution Sequence in Multiligamentous Knee Injury: A Case Report

The graft was passed from proximal to distal through the windows in the ITB and was first fixed at the femoral level with a biodegradable interference screw. One of the bands was then passed through the fibular tunnel, and its remnant was ascended toward the anatomical site of the insertion of the lateral collateral ligament (LCL). The remaining band was passed through the tibial tunnel in a posteroanterior direction. Both bands were fixed in 30° of flexion with neutral rotation in both distal tunnels (fibular and tibial) with biodegradable interference screws, and then the remainder was fixed with transosseous points at the femoral insertion of the LCL. Fig 5

### Final Fixation



05A Femoral fixation of aquiles graf.

05B Fibula with a bio interference screw. LCL reconstruction.

05C Tibia fixation with a bio interference screw. Popliteal tendon reconstruction.

To conclude the procedure, the ACL was fixed in the tibia with biodegradable interference screws in 5° to 10° of extension, and, finally, the meniscal root was fixed in 20° with a cortical fixation.

### Postoperative Treatment

The patient was immobilized with a brace for 6 weeks. Quadriceps isometric exercises and ankle flexion-extension were started in the immediate postoperative period. At 2 weeks, the patient began progressive passive mobility, which was restricted to 90° of flexion during the first month, and started to use crutches with progressive partial weight bearing according to tolerance. An intermittent articulated brace was worn from 6 to 12 weeks. The patient returned to sports at 12 months. At the time of the latest follow-up, at 3 years, the patient was progressing favorably without pain, with good mobility, and without residual instabilities or blockages.

### Conclusion

Multiligamentous knee injuries are rare but can have catastrophic anatomical consequences if they are not properly diagnosed and treated. When such an injury is suspected following trauma, it is essential (1) to carry out a thorough physical examination in order to detect ligamentous instability and neurovascular injury and (2) to evaluate all associated meniscal, bone, cartilaginous injuries as well as alterations of the mechanical axis in order to correctly plan the surgical sequence. Conservative treatment is recommended for grade-I and -II instability, whereas operative treatment (i.e., delayed ligamentous reconstruction followed by a rehabilitation protocol) is recommended for grade-III rotational and translational instability in order to obtain better functional results.

### References

1. Knee Dislocation (KD) IV Injuries of the Knee: Presentation, Treatment, and Outcomes, Dustin L Richter 1, Christopher P Bankhead 1, Daniel C Wascher 1, Gehron P Treme 1, Andrew Veitch 1, Robert C Schenck Jr 2, PMID: 30878047 DOI: 10.1016/j.csm.2018.11.007, Review Clin Sports Med. 2019 Apr;38(2):247-260. Epub 2019 Jan 19.
2. "Manual de principios básicos de la cirugía artroscópica", Asociación argentina de artroscopia 2019
3. ACL and Posterolateral Corner Injuries, Robert S. Dean corresponding author and Robert F. LaPrade, Author information Copyright and License information Disclaimer, PMID: 31884674, Curr Rev Musculoskelet Med. 2020 Feb; 13(1): 123–132. Published online 2019 Dec 28. doi: 10.1007/s12178-019-09581-3
4. Classifications in Brief: The Schenck Classification of Knee Dislocations, Collin Patrick Goebel BS, Christopher Domes MD, Clin Orthop Relat Res (2020) 478:1368-1372, DOI 10.1097/CORR.0000000000001186, Copyright © 2020 by the Association of Bone and Joint Surgeons
5. Novel methods for diagnosis and treatment of posterolateral rotatory instability of the knee, Chong Bum Chang 1, Sang Cheol Seong, Sahnghoon Lee, Jae Ho Yoo, Yoon Keun Park, Myung Chul Lee, Affiliations expand, PMID: 17908867 DOI: 10.2106/JBJS.G.00582, J Bone Joint Surg Am. 2007 Oct;89 Suppl 3:2-14.



# CALL FOR PAPERS

***Starting in 2022, JISAKOS Advances to Open Access and moves to Elsevier!***

Learn more at  
[isakos.com/JISAKOS/Open-Access](https://isakos.com/JISAKOS/Open-Access)

The *Journal of ISAKOS* accepts submissions across a wide range of article types, including original articles and state of the art, systematic, current concept reviews, and case reports.



**Interested in Becoming a Reviewer?**

Log in to [isakos.com/myisakos](https://isakos.com/myisakos) and select your preference in myAccount.



## Osteochondritis Dissecans of the Capitellum



Tetsuya Matsuura, MD, PhD  
Tokushima University  
Tokushima, JAPAN

### Introduction

Osteochondritis dissecans (OCD) of the capitellum tends to occur in young throwers and athletes who repetitively load or bear weight on the upper extremities. Capitellar OCD does not occur frequently, but if advanced, could entail a prolonged absence from sports activities.

### Epidemiology

Few studies have investigated the epidemiology of capitellar OCD in young baseball players, despite a substantial number of patients with this condition being known to play this sport. Two cross-sectional studies that included a number of baseball players investigated the prevalence of capitellar OCD with use of ultrasonography. One of those studies was performed by our research group and included 1,040 baseball players aged 10-12 years; 2.1% of the players were found to have capitellar OCD, and 90.9% of affected players had stage-I lesions<sup>1</sup>. In the other study, Kida et al. found that 3.4% of 2,433 baseball players aged 12-18 years had capitellar OCD and that 14.7% of affected players had stage-I lesions, 38.2% had stage-II lesions, and 13.2% had stage-III lesions<sup>2</sup>. These findings suggest that the risk of developing capitellar OCD is highest in players aged 10-12 years. We also followed a group of preadolescent baseball players prospectively to identify the risk factors for capitellar OCD and found the 1-year cumulative incidence to be 1.8%<sup>3</sup>. Players aged 10-11 years were at significantly higher risk of capitellar OCD than their counterparts aged 6-9 years. Taking up baseball earlier in life, more years of play, and more training hours increase the amount of repetitive valgus stress on the humeral capitellum and may be risk factors for OCD at this site. However, our study showed that starting to play baseball earlier in life, a greater number of years played, and more training hours indicating repetitive valgus stress were not significantly associated with capitellar OCD<sup>3</sup>. Kida et al. found that baseball players with capitellar OCD had started playing baseball at an earlier age and had played for longer periods<sup>2</sup>. They also found that capitellar OCD was associated with elbow pain<sup>2</sup>, but this association was not found in our prospective study<sup>3</sup>.

Furthermore, the study by Kida et al. included a relatively small percentage of players with stage-I capitellar OCD and a greater percentage with advanced capitellar OCD, as mentioned earlier. These findings suggest that elbow pain and a longer playing history are associated with progression of capitellar OCD, but do not in themselves increase the risk of developing the condition. The number of throwing opportunities that baseball players have depends on the player position. Pitchers and catchers perform the most throws and playing in these positions is reported to be a risk factor for elbow injury. However, previous studies did not find an association of player position with capitellar OCD<sup>1-3</sup>.

### Etiology

Capitellar OCD is characterized by noninflammatory degeneration of subchondral bone. The exact etiology of capitellar OCD is unknown, but there is general agreement that it results from a combination of repetitive trauma to an area of the humerus with a tenuous blood supply. Compressive and shearing forces that result from repetitive overhead or weight-bearing activity are believed to be the link between playing baseball and developing capitellar OCD. The blood supply to the capitellum comes predominantly from the arteries entering posteriorly and passing through the compressible epiphyseal cartilage with no connection to adjacent metaphyseal vessels. This tenuous blood supply would be at risk in the presence of repetitive injury to the elbow. Genetic factors are also thought to play a role in the pathogenesis of capitellar OCD, but relevant data are limited.

### Imaging

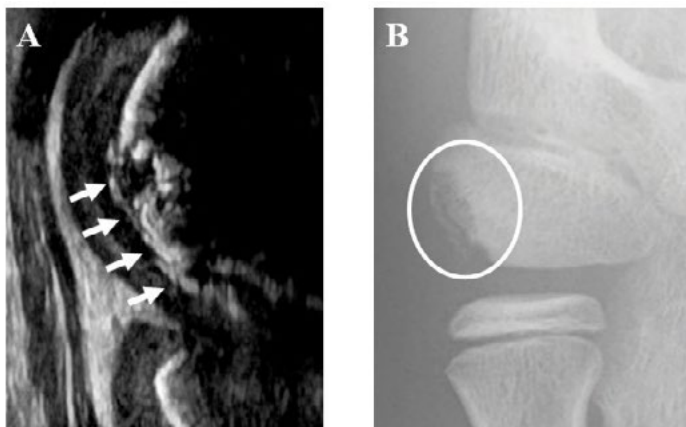
Careful evaluation is important when choosing the treatment that is most appropriate for the stage of capitellar OCD. A combination of radiography, computed tomography (CT), magnetic resonance imaging (MRI), and ultrasonography might facilitate accurate interpretation of the pathology of capitellar OCD.

Imaging evaluation of a patient with capitellar OCD begins with conventional radiography. Capitellar OCD is classified into three stages according to the findings on an anteroposterior view with the elbow in 45° of flexion<sup>4</sup>. Stage I is characterized by radiolucent areas; stage II, by nondisplaced fragments; and stage III, by loose bodies and sclerotic change.

MRI can detect early capitellar OCD when radiography demonstrates normal findings or only subtle changes. Early MRI findings include lesions of high signal intensity in the subchondral bone of the capitellum on proton-density fat-saturated images<sup>3</sup>. MRI can also reveal cartilage lesions that are not clear on radiographic images.

CT scans are not used as often as MRI for the detection of capitellar OCD lesions. However, a CT scan of the elbow seems to be the best imaging technique for confirming a diagnosis of capitellar OCD. An OCD lesion of the capitellum is not always visible on radiographs, and loose bodies are often missed on standard radiographs and MRI scans. Furthermore, CT allows the intra-articular position of loose bodies to be confirmed.

Ultrasonography is an inexpensive and portable diagnostic imaging modality that does not involve exposure to radiation and has been used successfully to assess elbow injuries. Early detection of capitellar OCD is desirable but difficult because most patients are asymptomatic or minimally symptomatic. However, screening for OCD with use of ultrasonography enables early detection and provides an opportunity for successful conservative treatment (Fig. 1)<sup>1-3</sup>. However, it is important to be aware that ultrasonographic examination may not be able to distinguish between OCD and minor injury or normal development during ossification. Therefore, OCD should be confirmed on additional radiographic examination.



- 01A Ultrasonographic screening enables early detection of osteochondritis dissecans of the capitellum (arrows).
- 01B Osteochondritis dissecans (circle) of the capitellum can be confirmed on an anteroposterior radiograph with the elbow in 45° of flexion.

### Treatment

Treatment has conventionally included both operative and nonoperative measures based on the stage of the lesion, skeletal maturity, subjective symptoms, lesion size, and the structural integrity of the cartilage.

### Nonoperative Treatment

The response of early-stage capitellar OCD to nonsurgical treatment is better than that of advanced-stage OCD, so identifying the condition early has a significant effect on prognosis (Fig. 2). We previously reported that conservative treatment, including avoiding heavy use of the elbow, promoted healing in 90.5% of patients with stage-I lesions and 52.9% of those with stage-II lesions<sup>4</sup>.



## Dear ISAKOS Members,

ISAKOS Annual Membership fees for 2022 are **Due by December 31, 2021**

To avoid disruption of any of your ISAKOS member benefits, including ISAKOS Books and Global Link, please renew your membership at [isakos.com/myISAKOS/membership](https://isakos.com/myISAKOS/membership).

You may also contact [membership@isakos.com](mailto:membership@isakos.com) or +1 925-807-1197 for assistance with your renewal.

# THANK YOU

for being a valued member!

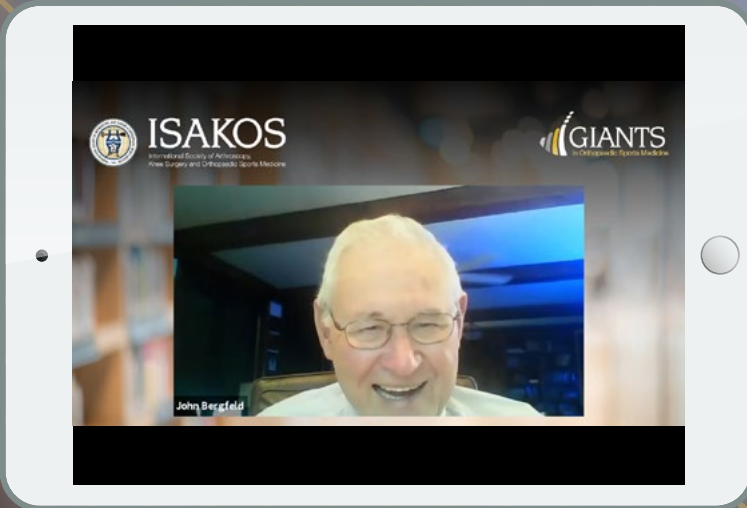

# ISAKOS



ISAKOS has a new video series available on Global Link

## Giants in Orthopaedic Sports Medicine



Each episode features an up-close interview with incredible legends of ISAKOS.

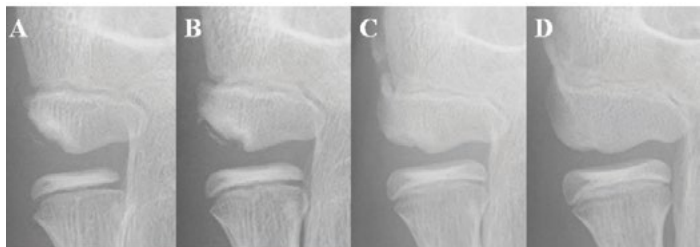View the latest interview with ISAKOS Past President, John Bergfeld, MD from the United States.



Videos are available on Global Link and podcast versions are also available wherever you get your podcasts.

[isakos.com/GlobalLink/Giants-in-Ortho](https://isakos.com/GlobalLink/Giants-in-Ortho)

## Osteochondritis Dissecans of the Capitellum

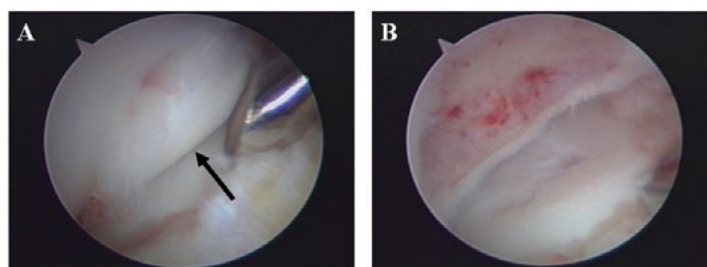


- 02 Radiographic imaging of the healing process in a patient with osteochondritis dissecans of the capitellum.
- 02A First examination.
- 02B Four months after the first examination.
- 02C Nine months after the first examination.
- 02D Twelve months after the first examination.

### Operative Treatment

The indications for surgery include persistent symptoms despite nonoperative treatment, symptomatic loose bodies, and displacement or detachment of the fragment. There is still debate concerning best practices for capitellar OCD lesions requiring surgical intervention. Several surgical methods have been reported, including arthroscopic removal of loose bodies with or without drilling or microfracture, arthroscopic or open fragment fixation, bone peg fixation, and osteochondral transplantation. In most cases, arthroscopic removal of loose bodies or osteochondral transplantation is indicated. Arthroscopic removal of loose bodies with or without drilling or microfracture may be indicated for patients who have a small lesion. This technique has become increasingly popular because it provides a minimally invasive alternative when surgical management is indicated (Fig. 3). Arthroscopic removal of loose bodies with or without drilling or microfracture has good to excellent functional results in the short to long term, although the relevant studies have often been retrospective in nature and have included patients with lesions of variable severity. There have been a few reports on the long-term clinical outcomes of surgical treatment. For example, we studied 23 patients who were followed for mean of 11.5 years (range, 10-13 years) after arthroscopic surgery<sup>5</sup>. Twenty patients (87%) returned to competitive baseball at their preoperative level; all 15 non-pitchers returned to the same position, but only 1 of 5 pitchers returned to pitching. These patients had little or mild pain and were capable of performing basic activities of daily living at the most recent follow-up, which was at least 10 years after surgery. Osteochondral defects detected on preoperative radiographs were small in 10 patients, moderate in 7, and large in 6. There were no significant between-group

differences in terms of range of motion or the Timmerman/Andrews score preoperatively or at the most recent follow-up. These findings indicate that arthroscopic debridement with or without drilling allows adolescent baseball players to return to play in positions other than pitcher and that the long-term outcomes are likely to be durable regardless of lesion size. However, despite the satisfactory outcomes in that study, more aggressive methods may be useful for patients with advanced lesions, given that 1 patient in our study who had large lesions eventually required reoperation. Osteochondral autologous transplantation may be indicated as a primary procedure for patients with large lesions or may be used as a salvage procedure if primary surgical treatment (debridement and marrow stimulation) has failed in athletes who desire to return to their preinjury level of activity or higher.



- 03A Arthroscopic view of the right elbow (via a posterolateral portal with a 70° arthroscope with the patient in the supine position). Note that the fragment is loose but is sitting within the site of the original lesion (arrow).
- 03B Arthroscopic view after fragment excision and debridement of the lesion in the same patient.

### References

1. Matsuura T, Suzue N, Iwame T, et al. Prevalence of osteochondritis dissecans of the capitellum in young baseball players: Results based on ultrasonographic findings. *Orthop J Sports Med.* 2014 Aug 12;2(8):2325967114545298. doi: 10.1177/2325967114545298.
2. Kida Y, Morihara T, Kotoura Y, et al. Prevalence and clinical characteristics of osteochondritis dissecans of the humeral capitellum among adolescent baseball players. *Am J Sports Med.* 2014 Aug;42(8):1963-1971. doi: 10.1177/0363546514536843.
3. Matsuura T, Iwame T, Suzue N, et al. Cumulative incidence of osteochondritis dissecans of the capitellum in preadolescent baseball players. *Arthroscopy.* 2019 Jan;35(1):60-66. doi: 10.1016/j.arthro.2018.08.034.
4. Matsuura T, Kashiwaguchi S, Iwase T, Takeda Y, Yasui N. Conservative treatment for osteochondrosis of the humeral capitellum. *Am J Sports Med.* 2008 May;36(5):868-872. doi: 10.1177/0363546507312168.
5. Matsuura T, Iwame T, Suzue N, et al. Long-term outcomes of arthroscopic debridement with or without drilling for osteochondritis dissecans of the capitellum in adolescent baseball players: A ≥10-year follow-up study. *Arthroscopy.* 2020 May;36(5):1273-1280. doi: 10.1016/j.arthro.2020.01.020.

## Glenoid Track Decision-Making Process in Patients with Anteroinferior Instability with Bipolar Bone Loss



Giovanni Di Giacomo, MD  
Concordia Hospital  
Rome, ITALY



Matthew T. Provencher, MD  
Steadman Philippon Research Institute  
The Steadman Clinic  
Vail, CO, USA



Annalise M. Peebles, BA  
Steadman Philippon Research Institute  
Vail, CO, USA



Nicola de Gasperis, MD  
Concordia Hospital  
Rome, ITALY

Post-traumatic anteroinferior glenohumeral instability is a much-debated topic. Two factors can influence the traits of this condition, and both can manifest simultaneously with variable degrees of gravity.

The first factor, the genetic profile, is difficult to evaluate quantitatively. This factor encompasses structural aspects of the ligaments, the morphology of joint extremities, and neuromuscular and proprioceptive control as part of the kinetic chain.

The second factor, the traumatic event, is also difficult to quantify and is frequently linked to complex traumatic mechanisms triggering triplanar angular momentum. A traumatic event with varying degrees of severity may disrupt the fine glenohumeral balance that is responsible for joint stability.

A predisposing genetic profile does not require significant trauma to cause shoulder instability. The pursuit of the ideal treatment for these patients is still the subject of research and discussion, often leading to contradictory results.

This review focuses on patients with traumatic recurrent anteroinferior instability caused by a traumatic event. It will highlight two main decision-making points for surgical treatment and outcomes: (1) glenoid bone loss (either critical or subcritical), and (2) the presence of a bony Bankart lesion.

### The Glenoid Track

The combination of a glenoid defect and a Hill-Sachs lesion, recently defined as “bipolar bone loss,” has been shown to be one of the important risk factors for postoperative recurrence of instability after arthroscopic Bankart repair.

Glenohumeral bone stability in the mid-range of motion is guaranteed by the integrity of the humeral head, and, perhaps most importantly, that of the glenoid cavity. Many surgeons believe that glenohumeral bone stability is a key factor that is necessary in order to adequately analyze the interplay between Hill-Sachs lesions and glenoid bone loss on the basis of the “glenoid track” concept, first introduced by Yamamoto. Today, authors recognize that both humeral bone loss and glenoid bone loss need to be assessed as part of a tailored treatment for shoulder instability, given that an increasing size of the Hill-Sachs lesion is an independent risk factor for recurrent instability, particularly if substantial glenoid bone loss is also present.

The glenoid track is defined as the contact zone between the glenoid and the humeral head. This concept is crucial to assess the risk of a Hill-Sachs lesion engaging the glenoid rim with or without a glenoid defect. The width of the glenoid track is reduced in patients with a glenoid defect, so this concept allows us to consider the influence of both lesions simultaneously when assessing shoulders with anterior instability.

Di Giacomo et al<sup>1</sup> proposed the term “bipolar bone loss” to describe bone defects, of varying sizes, affecting both the glenoid and the proximal humerus. They emphasized the importance of geometric interplay between lesions at these two sites when developing criteria for surgical treatment based on the glenoid track concept, and they stated that converting an off-track Hill-Sachs lesion into an on-track lesion is essential in order to stabilize shoulders with anterior instability, because an off-track lesion signifies that the shoulder is at high risk for engagement.

When applying measurements obtained with the glenoid track concept, we have to consider that MRI and CT scans provide variable measurements, with MRI tending to underestimate both glenoid bone loss and combined bone loss and linear measurements tending to overestimate glenoid bone loss. Inter-rater reliability is good for all measurements.

Nakagawa<sup>2</sup> showed that the frequency of glenoid defects is significantly higher—and the defects are larger—in shoulders with recurrent instability than in shoulders with primary instability; glenoid defects are enlarged by damage due to recurrent dislocation and subluxation, or by recurrent subluxation without dislocation, and enlargement can be observed even up to 1 year after trauma.

### Fragment Healing

Bony Bankart lesions can be reconstructed because it is possible to separate the osseous fragment from the glenoid neck, together with the labroligamentous complex, even in the chronic stage, and to restore the bone buttress effect by reducing the fragment with the use of suture anchors. As the bone fragment decreases in size, the risk of fragment resorption increases. Moreover, when the preoperative bone fragment is small, the postoperative bone union rate is reduced and union is delayed.

This can be explained by the fact that cancellous bone may be lost during bone surface debridement and decortication. Furthermore, blood supply and bone resorption could be influenced by bone fragment size: bony Bankart fragments have limited contact with surrounding labroligamentous tissue, which is responsible for blood supply and consequent osseous tissue viability. Therefore, smaller fragments may display a lower potential for postoperative integration due to an unfavorable biological environment.

If bone union occurs, the size of the glenoid defect decreases significantly, as does the recurrence rate. The postoperative recurrence rate is significantly higher in shoulders with preoperative small fragments, but the rate is significantly decreased in shoulders with bone union. The size of the preoperative glenoid defect does not influence the postoperative bone union rate.

Conversely, the effect of bone fragment incorporation on clinical outcomes varies according to preoperative glenoid defect size. In patients with preoperative glenoid defects measuring <20% of the glenoid width, bone fragment incorporation after the arthroscopic repair of a bony Bankart lesion does not alter clinical results, sports activity levels, or recurrence rates, whereas in patients with defects measuring >20% of the glenoid width, bone fragment incorporation improves clinical outcomes and recurrence rates as compared with functional outcomes in patients without bony Bankart lesions.<sup>3</sup>

These results imply that bone incorporation has little effect when the preoperative glenoid defect size is <20% of the glenoid width. Shoulders with glenoid defects smaller than this critical value already have sufficient bony buttress to avoid a highly unstable joint, even when they are not given the additional bony buttress provided by bone fragment incorporation.

### Subcritical Glenoid and Humeral Head Bone Loss

Traditionally, bone loss of >25% is considered to be a contraindication to soft-tissue repair alone because of a poor biomechanical environment and a high rate of clinical failure.

The concept of “subcritical bone loss” has been identified as a lower percentage of bone loss that, after arthroscopic Bankart repair, does not necessarily lead to recurrence or subluxation; instead, it leads merely to poor patient-reported clinical outcomes (WOSI scores) when compared with those of patients treated with bone augmentation.

Shaha et al<sup>4</sup> stated that in a population with a mandatory high level of activity, bone loss of more than 20% to 25% after Bankart repair increases failure rates but that subcritical bone loss of 13.5% leads to a clinically important worsening in WOSI scores, consistent with an unacceptable outcome, regardless of the presence of actual recurrence.

### Considering Subcritical Bone Loss in Bony Bankart Patterns

Critical bone loss is considered to be that measuring 25% of glenoid width. In general, guidelines state that Bankart repair is sufficient in patients with bone loss measuring <25%. In some cases, the engaging Hill-Sachs lesion can be corrected by adding an arthroscopic remplissage. If glenoid bone loss is >25%, the bone platform needs to be reconstructed.

The introduction of subcritical bone loss (13.5% according to Shaha et al<sup>4</sup> or 17.3% according to Yamamoto<sup>5</sup>) further subdivides patients with glenoid bone loss into two subgroups: (1) those with bone loss between 0% and 13.5% (or 17.3%), for whom Bankart repair is recommended, and (2) those with bone loss between 13.5% (or 17.3%) and 25%, especially those who routinely perform risky professional or sports activities, for whom Latarjet, other bone-reconstruction techniques, or even augmentation by means of remplissage can be considered.

Since the presence or absence of a bony Bankart lesion can have considerable influence on subcritical bone loss, it is necessary to share the following considerations.

In patients with erosion or compression patterns, subcritical lesions (glenoid bone loss between 13.5% [or 17.3%] and 25%), and peripheral Hill-Sachs lesions, bone-reconstruction techniques should be pursued because the WOSI outcomes are unsatisfactory in these patients.

The presence of a bony Bankart lesion may alter this algorithm in that it becomes crucial to assess not only the bony defects of the glenoid but also the size of the bony Bankart fragment in order to determine whether the glenoid rim can be repaired with use of the residual bone fragment. In the case of a successful repair, the bony Bankart healing will increase glenoid width, thereby increasing the glenoid track.

## Glenoid Track Decision-Making Process in Patients with Anteroinferior Instability with Bipolar Bone Loss

An increased glenoid track not only may transform a peripheral Hill-Sachs lesion into a central Hill-Sachs lesion (thereby ensuring an improved arthroscopic clinical outcome), but also may transform an off-track lesion into an on-track lesion or a subcritical on-track glenoid lesion into a minimal on-track glenoid lesion, with all of its related functional advantages.

In order to repair a bony Bankart lesion associated with glenoid bone loss below subcritical values, arthroscopic Bankart repair provides good outcomes, even if the bone fragment is not incorporated. If the bone loss is above the subcritical threshold and tending toward 20%, repair and bone fragment integration become crucial in order to obtain residual glenoid bone loss of <5%. However, in the case of glenoid bone loss of >20% and a fragment of minimal size, such that glenoid bone loss after healing will not be <5%, bone reconstruction is recommended.

### Principles of Surgical Management

Bipolar bone loss evaluation is paramount in the decision-making process for surgical management. With use of the glenoid track concept described above, we can use CT scans to distinguish on-track Hill-Sachs lesions from off-track Hill-Sachs lesions, after which a thorough quantification of glenoid bone loss is carried out. The first step is to identify all Hill-Sachs lesions (either on-track or off-track) and then to compare them with glenoid bone loss; this should be done preferably with CT imaging techniques, as described above. Patients can then be subdivided into 4 categories, as described below.

#### 1 On-Track Hill-Sachs Lesion and Glenoid Bone Loss of <25% (Subgroups A1 and A2: Below and Above Subcritical Glenoid Bone Loss)

In patients with on-track lesions and glenoid bone loss of <25%, it may be possible to treat instability successfully with arthroscopic repair alone. Nevertheless, it is known that the outcome of Bankart repair in patients with on-track lesions and glenoid bone loss of >13.5% or 17.3%, depending on the considered cut-off value, is not excellent.

When treating these patients, the amount of glenoid bone loss must be evaluated with utmost precision. First, if glenoid bone loss is below 13.5% (or 17.3%), the indication is for arthroscopic Bankart repair (Subgroup A1). If glenoid bone loss is above 13.5% (or 17.3%), it will be useful to reconstruct bone support with use of the Latarjet technique (Subgroup A2).

In patients with on-track lesions with glenoid bone loss of <25%, but with a concomitant bony Bankart lesion, incorporation of the Bankart fragment in the capsular ligament may potentially improve the outcome. This is because in cases of subcritical defects (between 13.5% [or 17.3%] and 25%), bone fragment integration may transform glenoid bone loss from subcritical to minimal and the increase of the glenoid track may transform a Hill-Sachs lesion from peripheral to central.

#### 2 On-Track Hill-Sachs Lesion and Glenoid Bone Loss of >25% (Subgroup B)

In this group of lesions, bone augmentation is considered the gold standard, even when the Bankart fragment has partially reabsorbed, which is often the case with erosion bone loss.

Conversely, if the bony fragment is still present and is of sufficient size to guarantee mechanical stability and biological integration, the surgeon may consider a bony Bankart repair, which will transform an on-track lesion with glenoid bone loss of >25% into an on-track lesion with subcritical bone loss (13.5% or 17.3% to 25%) or minimal bone loss (0% to 13.5% or 17.3%).

#### 3 Off-Track Hill-Sachs Lesion and Glenoid Bone Loss of <25% (Subgroups C1 and C2: Hill-Sachs-Based and Glenoid Bone Loss-Based)

In this pattern of bipolar bone loss, Hill-Sachs lesions can be subdivided into Subgroups C1 and C2. C1 lesions are “off-track Hill-Sachs lesion-based,” i.e., they are determined by medially extended humeral bone loss (more medial than peripheral), whereas C2 lesions are “off-track glenoid bone loss-based,” with glenoid bone loss playing a decisive role in engagement and recurrence.

If the distinction between minimal glenoid bone loss (0% to 13.5% or 17.3%) and subcritical glenoid bone loss (13.5% or 17.3% to 25%) is applied in this group, off-track Hill-Sachs lesions with glenoid bone loss between 0% and 13.5% or 17.3% can be considered as “off-track Hill-Sachs lesion-based,” whereas off-track Hill-Sachs lesions with glenoid bone loss of greater than 13.5% or 17.3% can be considered “off-track glenoid bone loss-based”.

An “off-track Hill-Sachs-based” lesion is considered to be “off-track” on the basis of the medial position of the Hill-Sachs lesion. Conversely, glenoid bone loss or a bony fragment, if present, will play no significant biomechanical or biological role.

Our rationale for surgery, therefore, aims at eliminating the “engaging” effect of the Hill-Sachs lesion with use of the remplissage technique associated with capsuloligamentous repair. The glenoid platform can be maintained as its biomechanical role is preserved and thus does not need to be addressed.

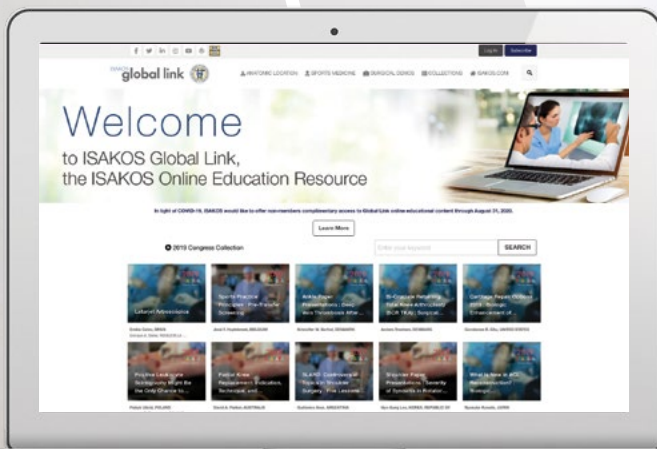
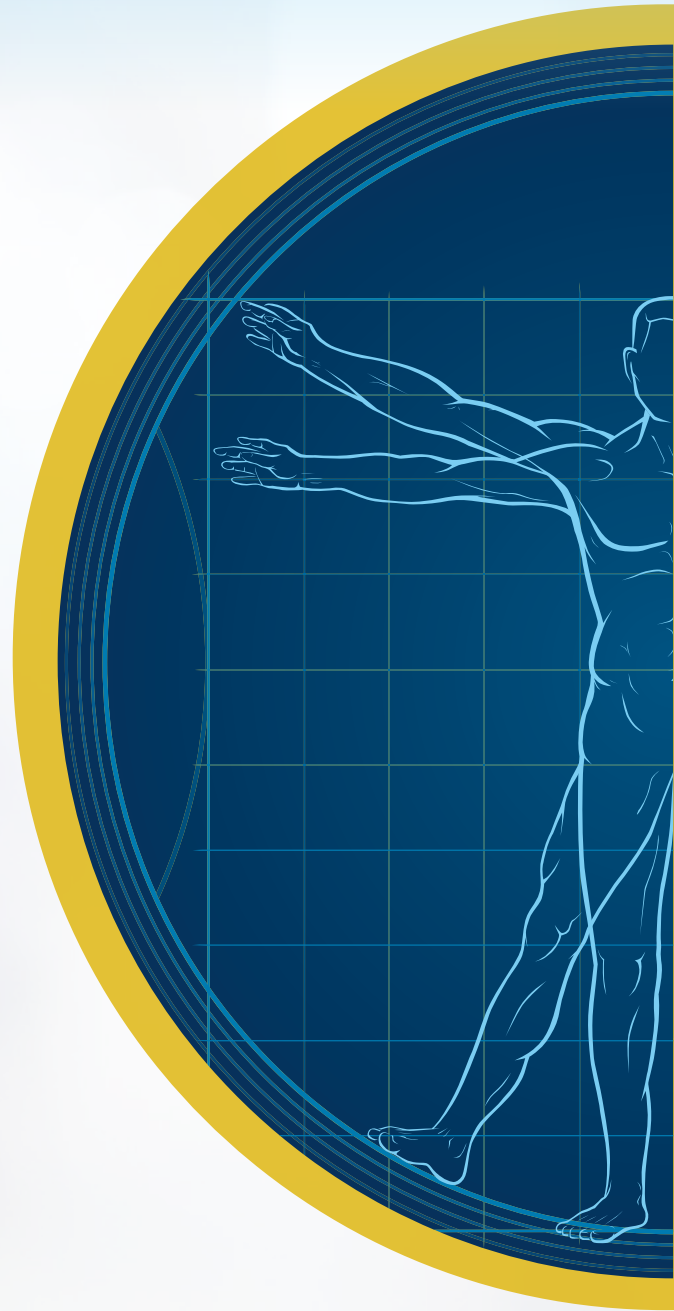


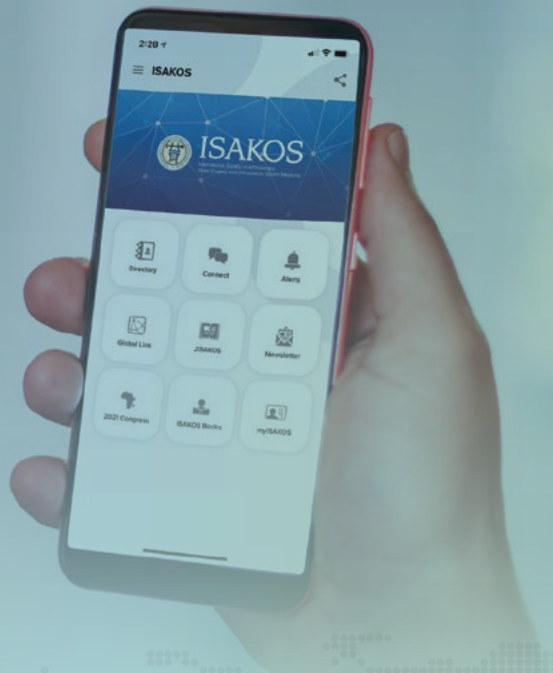
Check Out  
Our New  
Microlearning  
Videos

# ISAKOS global link

Access 3,000+ Congress presentations, surgical demonstrations & courses, webinars, current concept articles, archive videos, committee projects, industry sponsored content... and more!

[isakos.com/GlobalLink](https://isakos.com/GlobalLink)





# Access ISAKOS On-the-Go with the new ISAKOS App

Connect with others through Anatomical & Specialty  
Community Forums!



JISAKOS articles  
one touch away



Directory of  
colleagues at the  
ready



Global Link videos  
with the push of a  
button



Congress  
content instantly  
accessible

Download ISAKOS App



# ISAKOS

International Society of Arthroscopy,  
Knee Surgery and Orthopaedic Sports Medicine



## Glenoid Track Decision-Making Process in Patients with Anteroinferior Instability with Bipolar Bone Loss

In an “off-track glenoid bone loss-based” lesion, the bone support must necessarily be reconstructed. In this case, the glenoid bone loss tends to be greater than 13.5% or 17.3%. If the patient has glenoid bone loss with the concomitant presence of a bony fragment, it will be essential to perform an accurate preoperative measurement with CT scanning. This will allow us to assess whether a biological integration of the bony fragment will increase the glenoid width, thereby theoretically transforming the off-track lesion into an on-track lesion and turning the lesion into a Group-A type.

### 4 Off-Track Hill-Sachs Lesion and Glenoid Bone Loss of >25% (Subgroups D1 and D2: Hill-Sachs-Based and Glenoid Bone Loss-Based)

The presence of an off-track Hill-Sachs lesion and concomitant glenoid bone loss of >25% is a clear “bone-based unstable shoulder,” and recreating a bony buttress becomes mandatory; more aggressive operative management through the use of bone-block procedures is therefore warranted. In our experience, in >90% of cases, the glenoid reconstruction technique through coracoid process transposition (i.e., the Latarjet procedure) is able to transform an off-track lesion into an on-track lesion as the technique of coracoid transfer not only restores the bone tissue but also takes advantage of the sling effect provided by the conjoint tendon and the subscapularis, which act as stabilizing elements along with the coracoid graft itself.

In cases of severe bone loss, especially those involving a large Hill-Sachs lesion and extensive glenoid bone loss, other bone graft options can be considered, including autogenous iliac crest graft as well as various fresh and frozen osteochondral allografts (i.e., distal tibial grafts).

### Conclusion

When faced with glenoid bone loss and a Hill-Sachs lesion, the key point is to evaluate the interplay between the two areas of bone loss. The evaluation of the position of the Hill-Sachs lesion and medial extension is crucial; equally crucial is to know exactly which kind of glenoid bone loss is present. The quantification of bipolar bone loss can be done relatively easily via CT or MRI scans, taking into consideration the Hill-Sachs Interval (HSI) and glenoid track relationship. In the presence of glenoid bone loss accompanied a bony fragment (a bony Bankart lesion), the treatment strategy is still controversial.

### References

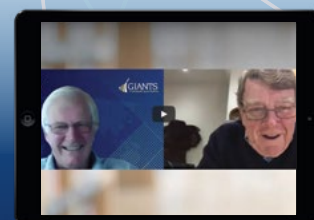1. Di Giacomo G, Itoi E, Burkhart SS. Evolving concept of bipolar bone loss and the Hill-Sachs lesion: from “engaging/non-engaging” lesion to “on-track/off-track” lesion. *Arthroscopy*. 2014;30:90-98.
2. Nakagawa S, Ozaki R, Take Y, Mizuno N, Mae T. Enlargement of Glenoid Defects in Traumatic Anterior Shoulder Instability: Influence of the Number of Recurrences and Type of Sport. *Orthopaedic Journal of Sports Medicine*. 2014 Apr;2(4):2325967114529920.
3. Nakagawa S, Mae T, Yoneda K, Kinugasa K, Nakamura H. Influence of Glenoid Defect Size and Bone Fragment Size on the Clinical Outcome After Arthroscopic Bankart Repair in Male Collision/Contact Athletes. *Am J Sports Med*. 2017;45(9):1967-1974.
4. Shaha JS, Cook JB, Song DJ, et al. Redefining “Critical” Bone Loss in Shoulder Instability: Functional Outcomes Worsen With “Subcritical” Bone Loss. *Am J Sports Med*. 2015;43(7):1719-1725.
5. Yamamoto N, Kawakami J, Hatta T, Itoi E. Effect of Subcritical Glenoid Bone Loss on Activities of Daily Living in Patients with Anterior Shoulder Instability. *Orthop Traumatol Surg Res*. 2019 Dec;105(8):1467-1470. doi: 10.1016/j.otsr.2019.08.015. Epub 2019 Oct 14.



# ISAKOS PODCAST

## ISAKOS has two podcasts!

Joining the already popular *JISAKOS* Podcast, ISAKOS has launched the



ISAKOS Podcast. Each episode features a different topic, covering everything from interviews with the Giants in Orthopaedic Sports Medicine to highlights from the ISAKOS Newsletter.

**Available wherever you get  
your podcasts!**

## Women in Research



Magaly Iñiguez MD  
Clínica Las Condes/Hospital Sotero  
del Río Santiago de Chile  
Santiago, CHILE

Scientific research knows no borders and brings together people with different backgrounds and areas of expertise. The resulting fusion of ideas and personal perspectives creates novelty in science and helps to improve scientific paradigms. However, according to the UNESCO Institute for Statistics (UIS)<sup>1</sup>, women represent just 29.3% of science researchers worldwide.

Gender diversity is still limited across distinct scientific fields, and orthopaedics is no exception. The low levels of participation among women can be attributed to many reasons that are beyond the scope of this article; however, in general, they can be traced back to cultural, educational, and social factors.

According to recent statistics from the International Orthopaedic Diversity Alliance (IODA)<sup>2</sup>, orthopaedics remains the least gender-diverse of all surgical specialties, with 28 of 30 countries surveyed reporting that females represent fewer than 15% of orthopaedists. Another recent publication showed that if the annual growth rate of female orthopaedic surgeons continues at 2% (as seen in the last 10 years), gender parity among orthopaedic surgeons will not be achieved until the year 2236.

As a result, our society has taken charge by focusing on the achievement of gender diversity and inclusion as the next challenge for ISAKOS. Therefore, an increase in female participation is expected in the next several years, not only in terms of the number of members but also in terms of specialty-related research.

This article highlights current statistics on women in research at ISAKOS and highlights the importance of stimulating, encouraging, and supporting fair and equal opportunities for female orthopaedic surgeons to engage in research. It is also a call for promoting diversity in research teams as a source of new points of view and a means of maximizing the strengths and talents of all members of our society.

### Female Participation in ISAKOS

According to the most recent society membership statistics as reported in the ISAKOS Newsletter in 2020, there are currently 3,086 members of ISAKOS, of whom just 142 (4.6%) are female.

Throughout its history, ISAKOS has forwarded its mission of promoting a high standard in scientific quality in a number of different ways, such as the creation of ISAKOS Research Awards, Fellowships, and research grants, among other initiatives. Female participation in these research activities has been steady over time, but the numbers remain small.

In the last 20 years, 81 individuals have received one of the eight main research awards granted by our Society in the recognition of scientific quality (including the John J. Joyce Award, Richard B. Caspari Award, Jan I. Gillquist Scientific Award, Gary G. Poehling Award, Albert Trillat Young Investigator's Award, Achilles Orthopaedic Sports Medicine Research Award, Paolo Aglietti Award, and The Patellofemoral Research Excellence Award); of these, only 5 have been women (Nicole Pouliart, Victoria Duthon, Michelle Cameron, Suzanne Witjes, and Alessandra Berton), representing 6% of the total prizes awarded. This statistic is particularly impressive when considered in light of the number of women who participate in orthopaedics and specifically in our society. Nevertheless, while this statistic produces enthusiasm and motivation, the flat trend over the years needs to be taken into consideration.

A similar trend is observed in the statistics on the fellowships awarded by ISAKOS in the last two decades, with a female representation in the awards since the first Congresses of the Society, but with a flat trend over time. Over the years, women have won 12.7% of these fellowships.

With regard to research grants, seven have been awarded by the scientific committee since 2017; unfortunately, to date, no female researchers have received such a grant.

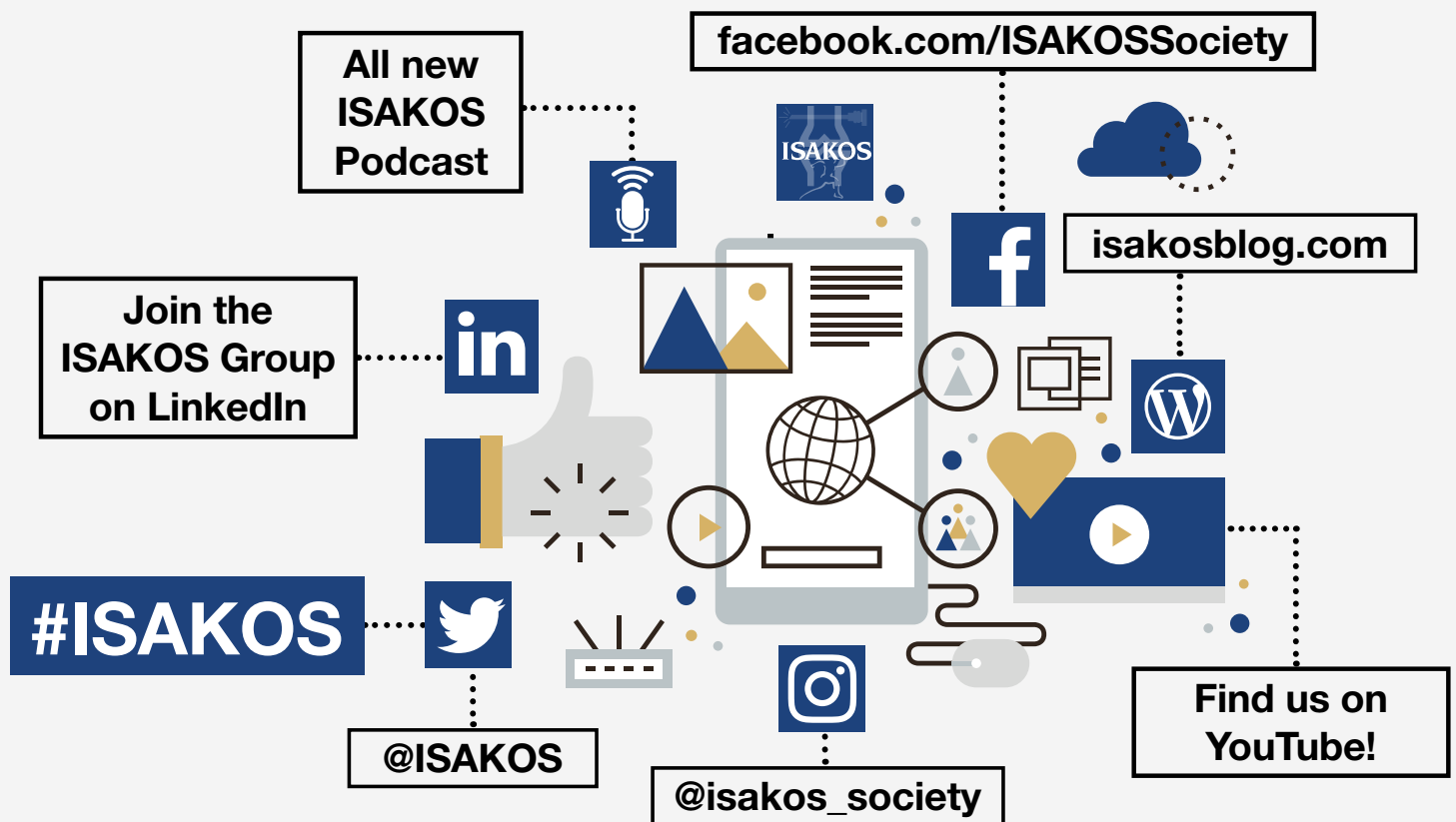
On the other hand, female participation in *JISAKOS* is encouraging, with 104 women having written or co-written 70 articles to date, with the journal representing an excellent forum in which to showcase scientific research.

Female participation in the different scientific activities at the ISAKOS Biennial Congress (Invited Presenters: Congress, Sports Rehab Concurrent Course, PreCourses, Abstracts, and e-poster presenters) is illustrated in Figure 3.

### Opportunities for Scientific Participation in ISAKOS

As part of its mission, ISAKOS supports orthopaedic research and education by funding the highest-quality international research proposals. We encourage participation in all of the following opportunities:

# Join the **ISAKOS** Global Conversation!



## Tweeting About ISAKOS?

Include hashtag **#ISAKOS** in your Tweets to join the global conversation!

#ISAKOS

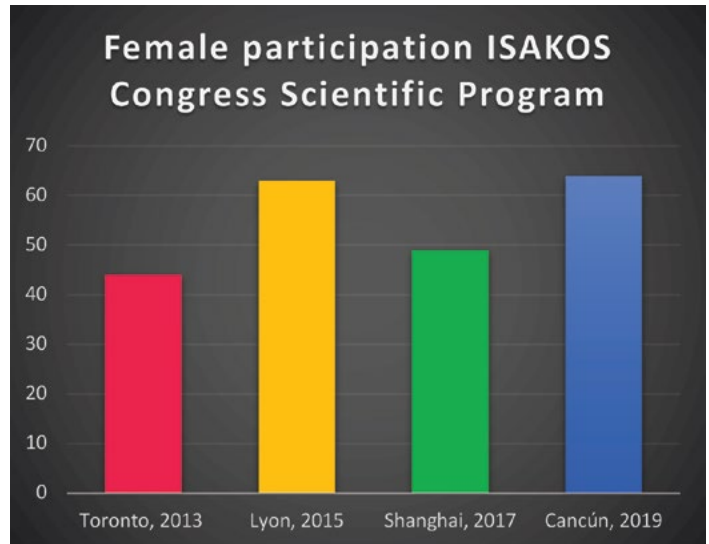
**Women in Research**

**ISAKOS Awards**

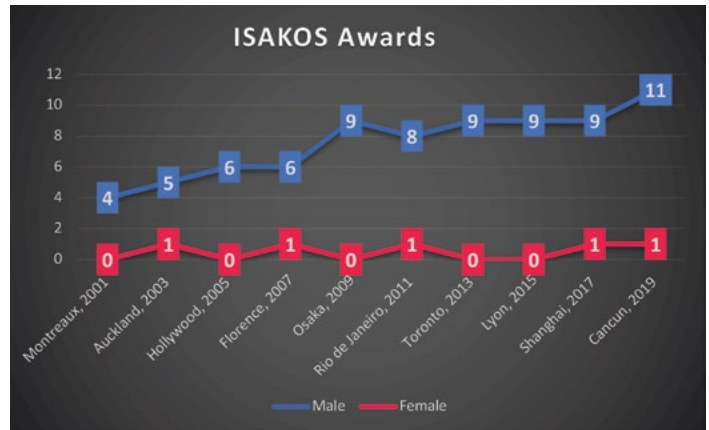
- John J. Joyce Award for the best arthroscopy paper
- Richard B. Caspari Award for the best upper extremity paper
- Jan I. Gillquist Scientific Award for the best scientific research paper
- Gary G. Poehling Award for the best elbow, wrist, and hand paper
- Albert Trillat Young Investigator’s Award for the best young clinical researcher
- Achilles Orthopaedic Sports Medicine Research Award for the best sports medicine research paper
- Paolo Aglietti Award for the best knee arthroplasty research paper
- Patellofemoral Research Excellence Award for the best patellofemoral research paper

**Fellowships and Scholarships**

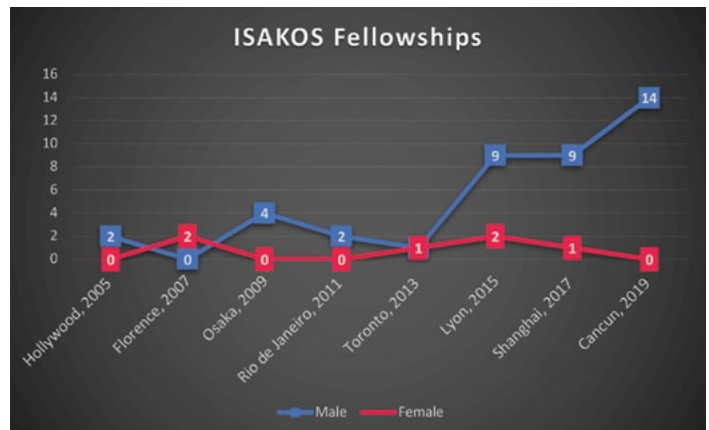
- ISAKOS Global Traveling Fellowship
- Patellofemoral Traveling Fellowship
- International Sports Medicine Fellows Conference Scholarship
- ISAKOS Young Investigator & Research Mentoring Program
- ISAKOS Knee Arthroplasty Fellowship



01



02



03

## Research Grants

The Scientific Committee oversees four ISAKOS research grants: (1) the New Researcher Grant, (2) the Osteoarthritis Grant, (3), the Clinical Outcomes Grant, and (4) the Countries with Limited Resources Grant.

## Scientific Participation in *JISAKOS* and Biennial ISAKOS Congress

Opportunities to showcase research include submitting articles to the recently indexed society journal, *JISAKOS*, and presenting scientific contributions as free papers and posters at the ISAKOS congress.

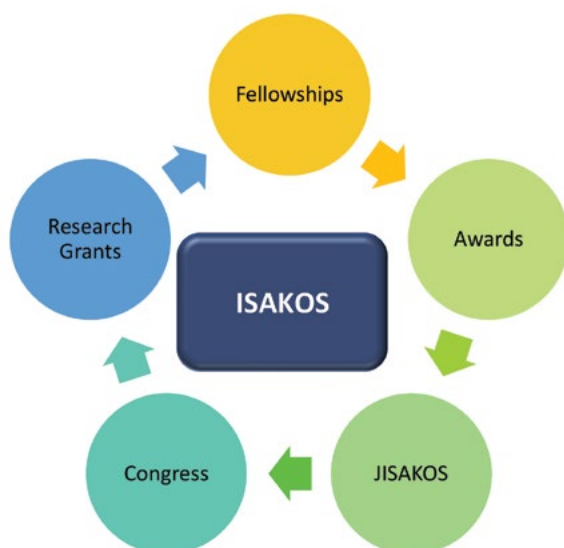## Looking to the Future

We encourage every member of ISAKOS, including women, to apply for ISAKOS research grants, fellowships, and research awards as a way of promoting diversity in our research groups and generating new leaders.

We hope that the enthusiasm shown by our female members is reflected in the participation curves of each of the scientific initiatives promoted by ISAKOS, with increasing numbers of participation as members and researchers, to enhance the benefits of diversity and bring new points of view and their effects in the scientific knowledge. ISAKOS's commitment to addressing geographic and cultural diversity is unwavering; as such, achieving gender diversity and inclusion presents as the next challenge for ISAKOS and the entire orthopaedic community. In this way, increased female participation in research should be a natural consequence.

## References

1. Unesco Institute for statistics: <http://uis.unesco.org/sites/default/files/documents/fs51-women-in-science-2018-en.pdf> 2. Diversity: Women in orthopaedic surgery -a perspective from the International Orthopaedic Diversity Alliance Article in Journal of Orthopaedics and Trauma · March 2020



# ISAKOS Research Grants



ISAKOS Research Grants are offered every two years (next term: 2021-2023) within four categories:

- 1 New Researcher**  
 Up to four possible grants for eligible applications with scientific merit.
- 2 Osteoarthritis**  
 Foster high quality research in early osteoarthritis and prevention, as well as treatment of osteoarthritis.
- 3 Clinical Outcomes**  
 Support outcomes research through well-designed clinical trials to evaluate the efficacy of interventions in orthopaedic sports medicine
- 4 Countries with Limited Resources**  
 Up to four possible grants for eligible applications with scientific merit. Awarded to finalist(s) from countries with limited resources, defined by the World Health Organization

Applications will open **December 1, 2021**  
**Learn more at [isakos.com/researchgrants](http://isakos.com/researchgrants)**

## “Guideline” to Define the Indications for Anterolateral Ligament Reconstruction During ACL Surgery



Matías Costa-Paz, MD, PhD  
Hospital Italiano de Buenos Aires,  
Argentina  
Buenos Aires, ARGENTINA



Juan Pablo Zicaro, MD  
Hospital Italiano de Buenos Aires,  
Argentina  
Buenos Aires, ARGENTINA



Carlos Yacuzzi, MD  
Hospital Italiano de Buenos Aires,  
Argentina  
Buenos Aires, ARGENTINA

The indication for anterolateral ligament reconstruction (ALL-R) during anterior cruciate ligament (ACL) repair or revision is not clearly defined in the literature and is often based on the surgeon’s experience<sup>1,2</sup>. The purpose of this presentation is to suggest a “Guideline” knee surgeons may use when deciding whether to perform an ALL-R together with an ACL reconstruction or revision. This “Guideline for ALL-R” is based on indications suggested in literature<sup>1-5</sup>, the risk factors for re-rupture of an ACL reconstruction, and our own experience in the Hospital Italiano de Buenos Aires (HIBA). The Guideline includes 14 criteria, divided into Major and Minor as follows:

### Major Criteria

The 5 major criteria include:

- Grade-III pivot shift (clear and explosive) (2 points)
- Contact, pivoting, or cutting sports (2 points)
- Competitive athletes (patients training at least twice a week, patients focused on winning competitions, professional and/or “elite” players) (2 points)
- Age,  $\leq 25$  years (2 points)
- ACL revision (especially in patients without previous surgical technical failures and those presenting with an ACL graft rupture following minimum impact and/or within 1 year postoperatively) (5 points)

### Minor Criteria

The 9 minor criteria include:

- Hyperlaxity / recurvatum: knee hyperextension of  $\geq 10^\circ$  and/or severe rotational instability (1 point)
- Arthrometry findings: KT-1000 testing with maximum manual force demonstrating side-to-side difference of  $\geq 8$  mm; contralateral knee must be normal (1 point)
- Chronic instability: instability for  $>6$  months (1 point)
- Meniscal injury: partial or total lesion of the medial meniscus, partial meniscectomy, and/or lateral meniscal root tear or meniscectomy (1 point)
- Contralateral knee instability associated with ACL lesion (1 point)
- Body mass index (BMI) of  $\geq 30$  (1 point)
- Tibial plateau slope of  $\geq 10^\circ$  as measured on profile radiographs (1 point)
- Severe anterior translation of the tibia:  $>6$  mm of subluxation of the lateral tibial plateau (1 point)
- Anterolateral ligament lesion on radiographs or MRI scans (a severe sprain is depicted as abnormal signal in the iliotibial band [ITB] and focal or diffuse thickening associated with adjacent soft-tissue edema; an ITB tear is seen as either a discontinuity in its fibers or a bone avulsion at the Gerdy tubercle [Segond fracture]) (1 point)

### Applying the Guideline

When applying this guideline, surgeons should take into account all 14 criteria when considering adding ALL-R to ACL reconstruction (Table I).

- A score of  $\geq 10$  points we believe is an indication for an ALL-R.
- A score of 8 points indicates that the surgeon should assess and decide whether to do ALL-R on a case by case basis.



## Conclusion

This guideline is designed to allow for the standardization of the indications for ALL-R, which presently depend on each surgeon's experience and criteria. This suggested guideline will hopefully be validated in the future by well-designed clinical studies.

TABLE I. HIBA Guideline for ALL-R

Major Criteria (2 points each)	Minor Criteria (1 point each)
<ul style="list-style-type: none"> <li>Grade-III pivot shift</li> <li>Pivot sports</li> <li>Competitive or "elite" athlete</li> <li>Age <math>\leq 25</math> years</li> <li>ACL revision*</li> </ul>	<ul style="list-style-type: none"> <li>Hyperlaxity/recurvatum <math>\geq 10^\circ</math></li> <li>KT-1000 <math>\geq 8</math> mm side-to-side difference</li> <li>Instability <math>\geq 6</math> months</li> <li>Medial meniscectomy and/or lateral meniscal root lesion</li> <li>Contralateral knee instability</li> <li>BMI <math>\geq 30</math></li> <li>Tibial plateau slope <math>\geq 10^\circ</math></li> <li>Severe anterior tibial translation</li> <li>Second fracture</li> </ul>

\*5 points.

## References

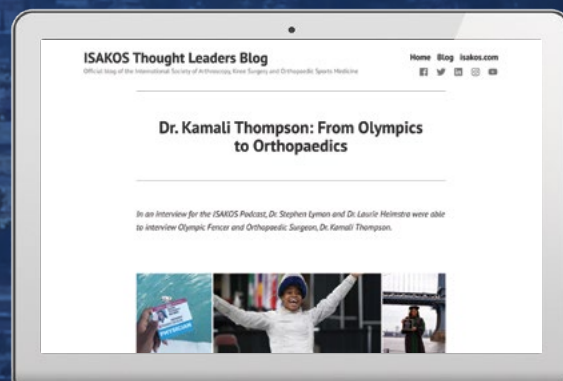
- Musahl V, Getgood A, Neyret P, Claes S, Burnham JM, Batailler C, Sonnery-Cottet B, Williams A, Amis A, Zaffagnini, Karlsson J. "Contributions of the anterolateral complex and the anterolateral ligament to rotatory knee stability in the setting of ACL Injury: a roundtable discussion," *Knee Surgery, Sport. Traumatol. Arthrosc.*, 25(4):997–1008, 2017.
- Ntagiopoulos P and Dejour D. "Extra-Articular Plasty for Revision Anterior Cruciate Ligament Reconstruction," *Clin. Sports Med.*, 37(1):115–125, 2018.
- DePhillipo NN, Cinque ME, Chahla J, Geeslin AG and LaPrade RF. "Anterolateral Ligament Reconstruction Techniques, Biomechanics, and Clinical Outcomes: A Systematic Review," *Arthrosc. - J. Arthrosc. Relat. Surg.*, 33(8):1575–1583, 2017.
- Cerciello S, Batailler C, Darwich N, Neyret P. "Extra-Articular Tenodesis in Combination with Anterior Cruciate Ligament Reconstruction: An Overview," *Clin. Sports Med.* 37(1):87–100, 2018.
- Weber A, Zuke W, Mayer EN, Forsythe B, Getgood A, Verma NN, Bach BR, Bedi A, Cole BJ. "Lateral Augmentation Procedures in Anterior Cruciate Ligament Reconstruction. Anatomic, Biomechanical, Imaging and Clinical Evidence" *Am. J. Sports Med.*, 47(3): 740-752, 2019.

# ISAKOS

## Thought Leaders Blog

Read blog posts from ISAKOS Thought Leaders around the globe.

The official ISAKOS blog is an initiative from the ISAKOS Communications Committee.



[ISAKOSBLOG.COM](https://www.isakosblog.com)



Read the latest post, **Dr. Kamali Thompson: From Olympics to Orthopaedics** interview by Dr. Stephen Lyman from the USA and Laurie Hiemstra from Canada. ISAKOS Gender & Diversity Task Force

## UPCOMING ISAKOS APPROVED COURSES

Patras-Fellowship 2021  
University Hospital of Patras  
Patras, GREECE

**September 8–10, 2021**

Chair(s): Andreas Panagopoulos

**For further information, please contact:**

Email: andpan21@gmail.com

Tel: 306944363624

<https://www.patrasfellowship.com>

Advanced Techniques in Shoulder Surgery  
ATT Center  
Athens, GREECE

**September 24–25, 2021**

Chair(s): Flora Sklia

**For further information, please contact:**

Email: secretariat@attcenter.eu

Tel: 2106109991

<https://www.projector-web.gr/attc/en/atss2021/welcome>

25th International Shoulder Course Munich  
Hanover Messe (NORD/LB Forum)  
Munich, GERMANY

**October 11–13, 2021**

Chair(s): Bastian Scheiderer

**For further information, please contact:**

Email: bastian.scheiderer@tum.de

Tel: +49 (0)89 4140 9532

<https://schulterkurs-muenchen.de>

## IS YOUR MEETING, WEBINAR, OR VIRTUAL COURSE AN...



### ISAKOS APPROVED COURSE

[www.isakos.com/meetings](http://www.isakos.com/meetings)

Minnesota Advanced Complex Knee  
International Symposium (MACKIS) 2021  
Radisson Blu at Mall of America  
Bloomington, UNITED STATES

**September 30–October 2, 2021**

Chair(s): Robert F. LaPrade MD, PhD

**For further information, please contact:**

Email: laprademdphd@gmail.com

Tel: 1-612-940-1836

<https://www.smith-nephew.com>

8th Stockholm Arthroscopy Conference  
Capio Arto Clinic, Sophiahemmet,  
Stockholm

Stockholm, SWEDEN

**October 14–15, 2021**

Chair(s): Anders Stålmán

**For further information, please contact:**

Email: anders.stalman@capio.se

Tel: 736665957

<https://ki.se/forskning/save-the-date-8th-stockholm-arthroscopy-conference>

6th ICRS Summit- Joint Preservation—  
Where We Are in 2021

Doral National Miami  
Miami, UNITED STATES

**November 18–20, 2021**

Chair(s): Melanie Twerenbold

**For further information, please contact:**

Email: office@cartilage.org

Tel: 41445037371

<https://cartilage.org/icrs-summit-miami/>

14th International Live Surgery  
Congress Shoulder  
Hanover Messe (NORD/LB Forum)  
Hanover, GERMANY

**November 11–12, 2021**

Chair(s): Alisa Ganter

**For further information, please contact:**

Email: alisa.ganter@intercongress.de

Tel: +49 761 69699 240

<https://international-live-surgery-congress.com>

## Arthroscopy

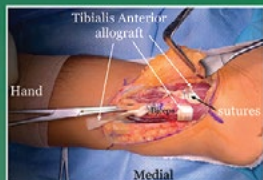
The Journal of Arthroscopic  
and Related Surgery

Volume 37 · Issue 8 · August 2021

**Infographic—Rotator Cuff Repair:  
The SCOI Row Technique**  
by Arroyo, Getelman, and Snyder

**Orthoregeneration of the Knee**  
by Knapik, Evarthierie, Frank, Steinwechs,  
Rodeo, Mummie, and Cole

**Return to Sport After Hip FAI  
Surgery**  
by Annin, Laili, Yelton, Shapira, Rosinsky,  
Meghpara, Maldonado, Arnkem, and Domb



Official Publication of the Arthroscopy Association of North America

## DISCOUNTED Arthroscopy Subscription for Members!

Through a strategic partnership with AANA, ISAKOS members are now able to purchase an annual, online *Arthroscopy* subscription for only USD \$65.

Log in to myISAKOS to add the online *Arthroscopy* subscription to your ISAKOS membership:  
[isakos.com/myISAKOS/myPublications](http://isakos.com/myISAKOS/myPublications)

ISAKOS is committed to providing easier access to journals, publications, and industry updates. We encourage you to take advantage of this added opportunity and member benefit, as well as the opportunity to purchase a discounted online KSSTA subscription.

# Reach more + repair more

**FAST-FIX FLEX enables all-zone all-inside meniscal repairs empowering surgeons to treat previously inaccessible tears\*<sup>1-3</sup>**

**Enhance Accessibility** with needle and shaft modifications to access mid-body and anterior zones accounting for over 40% of tears\*<sup>1,2,4</sup>.

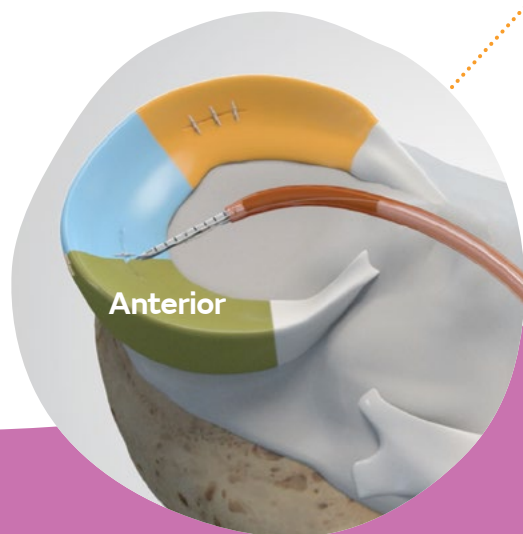
**Preserve Anatomy** with a ~25% smaller needle insertion area and a ~20% stronger repair\*\*<sup>5,6</sup>

**Increase Reliability** with implant deployment you can hear, feel and see<sup>1</sup>. Go to [AllTearsAllRepairs.com](https://www.AllTearsAllRepairs.com).

## Smith+Nephew



**FAST-FIX FLEX**  
Meniscal Repair System



\*Compared to predicate device +in stable adult knees ^as demonstrated in biomechanical testing **References 1.** Smith+Nephew 2021.Validation, FAST-FIX FLEX. Internal Report. 15010267 Rev A. **2.** Smith+Nephew 2021.Validation, FAST-FIX FLEX. Attachment B. Internal Report. 15010267 Rev A. **3.** Smith+Nephew 2021.FAST-FIX FLEX- Surgeon Surveys. Internal Memo. **4.** Metcalf MH, Barrett GR. Prospective evaluation of 1485 meniscal tear patterns in patients with stable knees. *Am J Sports Med.* 2004;32(3):675-680. **5.** Smith+Nephew 2021.Competitive, FAST-FIX FLEX Dimensional Analysis. Internal Report. 15010919 Rev A. **6.** Smith+Nephew 2020. Biomechanical Testing, FAST-FIX FLEX. Internal Report. 15010180 Rev A.

Smith & Nephew, Inc., 150 Minuteman Road Andover, MA 01810, [www.smith-nephew.com](https://www.smith-nephew.com), US Customer Service: +1 800 343 5717 <sup>o</sup>Trademark of Smith+Nephew.  
©2021 Smith+Nephew. All rights reserved. Printed in USA. 29391 V1 0521



**ISAKOS**  
**CONGRESS**  
**2021**

  
**GLOBAL**  
Nov 27 - 28

# The World Invites **YOU** to ***ISAKOS 2021: Global***



[isakos.com/2021](https://isakos.com/2021) • [#ISAKOS2021](https://twitter.com/ISAKOS2021)